

Prostate MRI – an update for the referring urologist

Marcin Czarniecki, Maciej Jakuciński, Leszek Królicki

Bródnowski Mazovian Hospital, Department of Diagnostic, Warsaw, Poland

Citation: Czarniecki MB, Jakuciński M, Królicki L. Prostate MRI – an update for the referring urologist. *Cent European J Urol.* 2016; 69: 162-169.

Article history

Submitted: Sept. 23, 2015

Accepted: Nov. 22, 2015

Published online: Jan. 22, 2016

Corresponding author

Marcin Czarniecki

Bródnowski Mazovian
Hospital

8, Kondratowicza Street

00-660 Warsaw, Poland

phone: +48 602 21 6646

m.czarniecki@brodnowski.pl

Introduction Prostate MRI is a new and important tool which has a role in prostate cancer guidelines worldwide. The amount of articles published and studies currently taking place on the subject requires urologists to understand how the examination is performed and its possible applications. This article explains prostate MRI and standardized reporting schemes, as well as its applications according to patients' staging and history.

Material and methods The use of prostate MRI prior to biopsy, MRI-guided biopsy and its use in active surveillance, surgery staging and planning, as well as in cases with biochemical recurrence are discussed.

Results The application of prostate MRI are not limited to initial diagnosis, but also has a developing role in biopsy and planning further treatment. Recently, its diagnostic applications have been included in EAU prostate cancer guidelines and new applications are in development.

Conclusions Practicing urologists are seeing an emerging role of MRI in prostate cancer. Its current and future applications may have an impact on patient care, which mandates healthcare professionals to be vigilant about the method's new developments.

Key Words: prostate ↔ MRI ↔ mpMRI ↔ detection ↔ review

INTRODUCTION

Prostate cancer is the most common malignancy with an incidence >200 men per 100,000 in Western Europe, and the second most common cause of death [1]. The current screening methods using Prostate Specific Antigen (PSA), Digital Rectal Exam (DRE), and TRUS-guided random biopsy still result in up to 35% of cancers being missed. Many of the detected cancers are deemed clinically insignificant, having little or no impact on life expectancy [2, 3].

Multiparametric MRI (mp-MRI) has an emerging role in the diagnostic protocol of prostate cancer detection and staging. With the March 2015 update of the European Association of Urology (EAU) Guidelines on Prostate Cancer, there is a Grade A recommendation for prostate mp-MRI to be performed for local staging in high-risk localized or locally advanced disease. Moreover, a Grade B recommendation exists for MRI-targeted biopsy in previously negative biopsied patients or in planning nerve-sparing radical prostatec-

tomy [4]. These are applications that already have an established role in prostate cancer diagnostic guidelines. This paper will discuss the various applications of mp-MRI according to different treatment pathways and to disease stage at diagnosis and patient predicted risk. It will examine the applications of prostate mp-MRI prior to biopsy, MR-guided biopsy, its role in active surveillance, and biochemical recurrence.

mp-MRI of the prostate

MRI is a safe and non-invasive diagnostic method. Recently, great advancements in the field have been made with its use being incorporated in urological guidelines in Europe and the USA. Over the past 5 years in PubMed, using the keyword search of "prostate MRI", the number of academic literature doubled from 266 in 2009 to 610 in 2014. The growing interest in this diagnostic method will mean that urologists will need a thorough knowledge of when to use it, as well as its limitations.

Currently, prostate mp-MRI is performed on an MRI with a field strength $\geq 1.5T$, with or without an endorectal coil [5, 6, 7]. The protocol is based on T2-weighted imaging (T2WI), diffusion weighted imaging (DWI), and dynamic contrast enhancement (DCE) (Figure 1). Other sequences such as MR spectroscopy have recently shown benefit in cancer detection, but are not routinely recommended due to their high cost and the difficulty in performing the studies and interpreting their results [8, 9].

T2WI with its high contrast and resolution is ideal for identifying zonal anatomy, which aids in correct TNM staging. On T2WI prostate cancer appears dark (hypointense), indicating a lower density of water molecules and a more tightly bound cell structure. On its own, findings in T2WI are insufficient for accurate prostate cancer characterization, which have led to the development of a multi-parametric approach.

Diffusion weighted imaging (DWI) is a sequence which enables the quantification of random Brownian motion of water molecules in tissue. This principle is altered in hypercellular tissue, where it leads to a restriction in diffusion. Changing gradient strengths and pulse lengths, which together are termed as the b value of the image series, can alter DWI results. In prostate mp-MRI, it is currently recommended to use a high b-value ($b > 1400$), as it has shown to identify cancerous lesions with a higher accuracy [7]. The limitations of DWI include an increased acquisition time with higher b values, a limited value in evaluating the transition zone (BPH nodules also demonstrate restricted diffusion), as well as high artifact susceptibility.

Dynamic contrast enhancement (DCE) is a sequence that uses gadolinium-containing contrast injected during sequencing and quantifies blood flow parameters through tissue. Areas of increased vascularity typical for cancer can thus be identified. Rapid image acquisition with a temporal resolution under 15 seconds allows for optimal interpretation of contrast enhancement. With a multitude of parameters that may be measured, it is currently recommended to assess the images qualitatively for early contrast enhancement [7]. The sequence may produce false positive results in the case of inflammation or in BPH nodules. Due to its long acquisition time and temporal acquisition it is susceptible to motion artifacts.

A standardized reporting technique is currently recommended to identify prostatic lesions. According to previously established reporting scales developed for the breast (BI-RADS) or liver (LI-RADS), PI-RADS (Prostate Imaging Reporting And Data System) is used for the prostate. A revised edition has been published in January 2015, and is referred to as PI-RADSv2. Lesion scoring is based on a five-point

scale for the T2-weighted and Diffusion Weighted Images with 1 being highly unlikely that clinically significant disease is present and 5 being highly suggestive of clinically significant disease. The reporting technique evaluates the prostate in a systematic manner, dividing the prostate according to its anatomy, including the peripheral zone, transition zone, central zone and anterior fibromuscular stroma. Additionally, the prostate is divided along the long axis into three regions – the apex, mid-gland, and base for mapping purposes.

Using the multiparametric approach, DWI is considered the dominant diagnostic sequence for the peripheral zone where the 5-point scale is used to score the diffusion restriction. Conversely, T2WI is used primarily for transition zone assessment. Additionally, DCE is utilized qualitatively to determine whether there is early focal enhancement, which may radiologically upstage a given lesion from PI-RADS 3 to PI-RADS 4 [7]. According to PI-RADSv2, prostate biopsy should be considered in PI-RADS 4 or 5 lesions, but other factors including local expertise, treatment preferences and the patient's clinical and laboratory history must be considered [7]. A recent study has identified the added benefit of standardized reporting in prostate mp-MRI – detection of extra-prostatic involvement specificity increases from 24.5% to 59.5% with an overall improvement of accuracy to 62.7% [10]. Most importantly, it is recommended that the reporting radiologist should be a subspecialized urologist with at least 3 years experience, performing > 50 exams/year [11].

It is worth mentioning that other reporting schemes have been developed by the National Cancer Institute (NCI MP-MRI), Standards of Reporting for MRI-targeted Biopsy Studies (START) which is used in MRI guided biopsies, as well as the Likert grading. As of date, PI-RADS system is most widely used and validated.

Prostate MRI prior to biopsy

Traditionally, a prostate cancer detection protocol includes serum PSA concentration, DRE and a random TRUS biopsy. This pathway leads to a biopsy detection rate of 25–39% if using a 10-core biopsy scheme [3, 12, 13, 14]. The biopsy detection rates increase with the number of biopsy cores from a sextant to a 12-core, as well as in saturation biopsies with up to 50-cores being taken [15]. However, over 70% of detected prostate cancers are deemed clinically insignificant (Gleason score 6 (3+3), without extracapsular extension (ECE), less than 10% of tumor volume), suggesting that the path towards better detection rates is not necessarily through increasing the number of cores sampled [16]. A superior

method of finding clinically significant cancers and differentiating them from indolent ones is needed. A meta-analysis of mp-MRI (n = 526) followed by biopsy has shown mp-MRI to have a sensitivity and specificity of 74 and 88% respectively, with a negative predictive value ranging from 65 to 94% [17]. Another large systematic review demonstrated

that the addition of a targeted MRI biopsy together with a systematic one increases the detection rate, especially in the repeat biopsy setting and less so in the initial biopsy [18]. The PROMIS trial is currently under way which is evaluating the role of mp-MRI prior to biopsy. If it is found that a large proportion of significant cancers will be detected prior

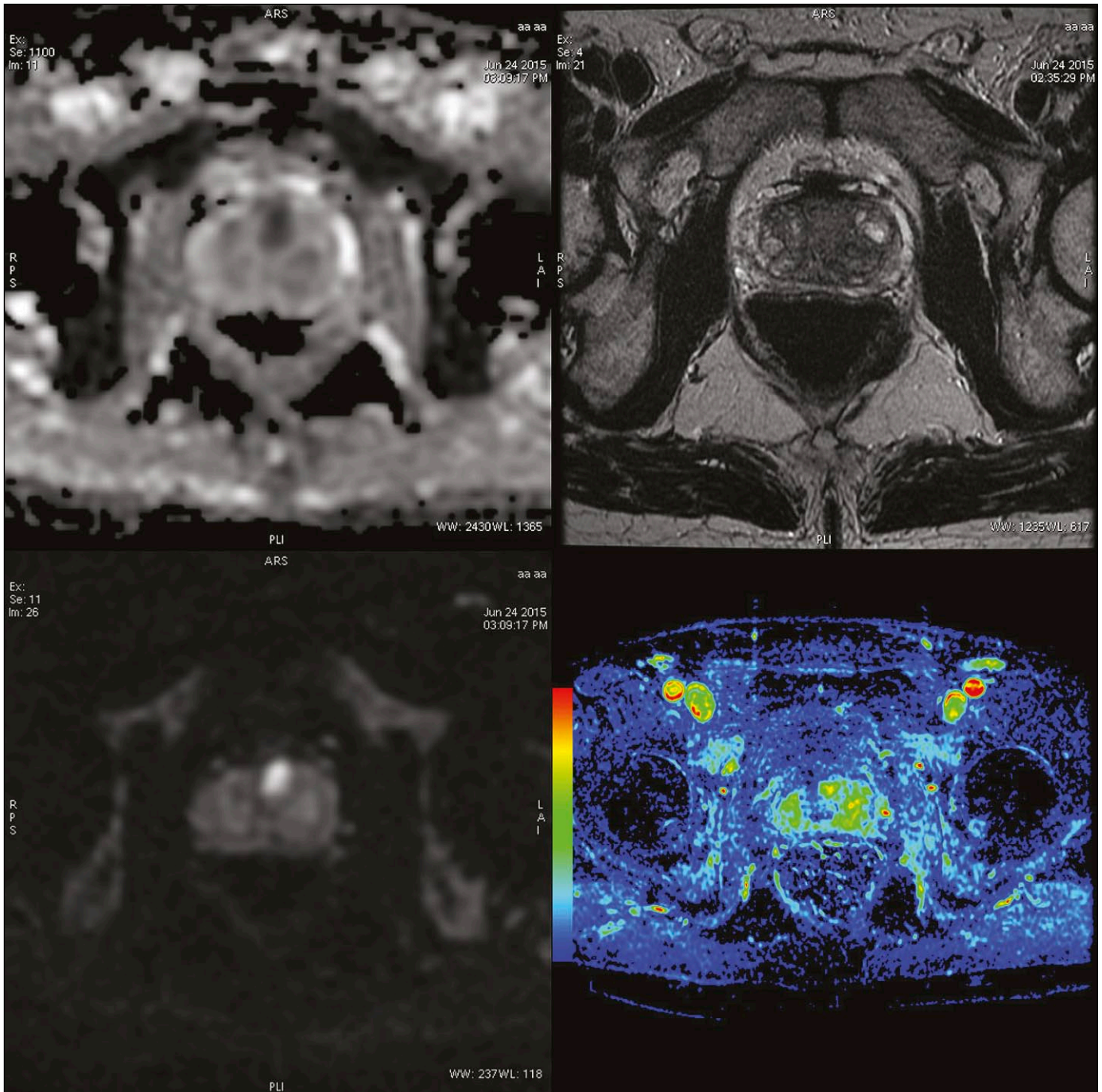


Figure 1. Clockwise: ADC map, T2WI, Dynamic contrast enhancement (maximum slope of increase), DWI ($b = 1400$). The set of images lets us appreciate the use of a multiparametric approach – the lesion on the border of the anterior fibromuscular stroma and transition zone is easily appreciated in DWI/ADC and DCE series, but inconspicuous on T2WI.

to biopsy, mp-MRI may have a pivotal role in initial diagnosis [19].

Suspicious lesions identified during mp-MRI may detect a higher percentage of intermediate to high-grade tumors compared to random biopsies with the use of fewer cores [20]. With over 1,300,000 TRUS-guided biopsies happening per year in the United States [21], the main concern for a larger application of prostate mp-MRI in biopsy-naive patients is cost and available infrastructure. The inclusion of pre-biopsy mp-MRI into future guidelines with all of its implications on a large scale is currently being evaluated, partly by the ongoing PROMIS trial in the UK.

mp-MRI-guided prostate biopsy

The cancer detection rate for TRUS-guided biopsies is highly variable depending on the number of biopsy cores obtained, biopsy approach, operator experience, as well as prostate size and location of the tumor [12, 13, 15, 22, 23, 24]. Regarding the use of mp-MRI, currently the applications of mp-MRI in biopsy can either be in real-time or the images can be fused in post-processing at TRUS (Figure 2). Current EAU guidelines suggest MR guided biopsies when a clinical suspicion of PCa persists despite negative TRUS biopsies [4]. This recommendation is primarily due to the finding that cancer can be detected with fewer cores sampled when using an MRI targeted approach, when compared to saturation and perineal biopsies [24]. Bore MRI-guided biopsies have

not shown to have an added benefit when compared to MRI-TRUS fusion biopsies with a saturation biopsy [25]. MRI-TRUS fusion-guided prostate biopsies have shown to improve cancer detection, especially in cases with lesions located in the anterior region, the apex and in enlarged prostates [23, 26, 27] (Figure 3). MR-guided biopsies have shown to be most beneficial in previously identified lesions on mp-MRI that are located in regions other than the peripheral zone (apex, anterior fibromuscular stroma).

So far, there is little evidence of a clear superiority of MRI-guided biopsies over standard TRUS biopsy and MRI lab capacity must be taken under consideration. Promising results demonstrated that increased detection rates of significant PCa were obtained with the combination of a systematic biopsy and a targeted biopsy, compared to a systematic biopsy alone, as is currently recommended by the EAU [18, 25].

Prostate mp-MRI in active surveillance

One of the current hurdles of prostate cancer management is the risk and challenge of overdiagnosis and overtreatment of low-risk disease, with incurring costs and patient morbidity [28]. Limited benefit of radical prostate surgery in patients without high-risk disease was first revealed in the Prostate Intervention Versus Observation Trial (PIVOT) [29]. Active surveillance (AS) was considered as a possible alternative in low-volume and low-grade disease. A better method than PSA screening was sought, with mp-MRI being considered a viable adjunct. Due to the high specificity (97%) and negative predictive value (90%) of standardized mp-MRI, unnecessary PSA measurements and re-biopsies may be avoided or reduced. It has been shown in pathology specimens that patients on an active surveillance protocol can have correctly classified index lesions monitored by mp-MRI [30].

A study comparing immediate and delayed prostatectomy with an active surveillance protocol showed that delaying surgery more than 6 months does not significantly increase the pathological grade of cancer [31]. Undoubtedly, more AS studies using mp-MRI will be published in the near future. Patient selection for active surveillance must be performed with sound clinical judgment, with mp-MRI in conjunction with targeted biopsies currently considered as indispensable. A retrospective analysis comparing the D'Amico, Epstein and Cancer of the Prostate Risk Assessment (CAPRA) with mp-MRI showed that the D'Amico criteria misclassified 30% of the lesions, the Epstein criteria 12% and CAPRA 41%, mostly due to underestimation. With the addition of mp-

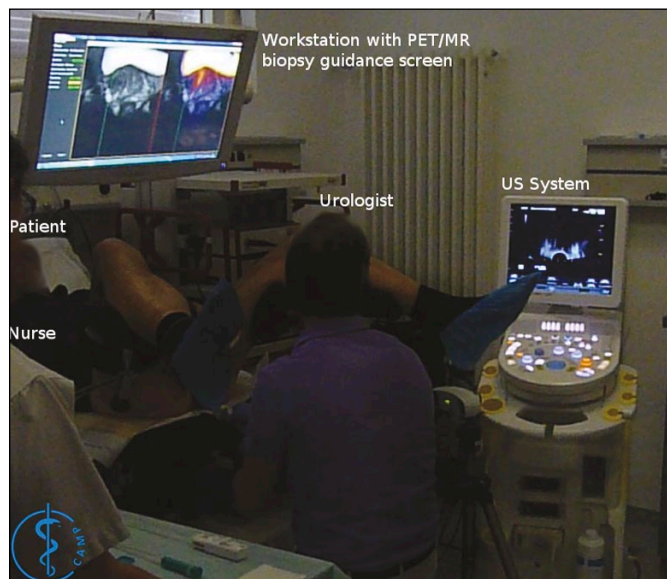


Figure 2. MR/US fusion guided biopsy. This image shows a prepared workstation during an MR/US fusion biopsy. The previously acquired MR and PET/MR is visible on the overhead screen and the live US image to the right.

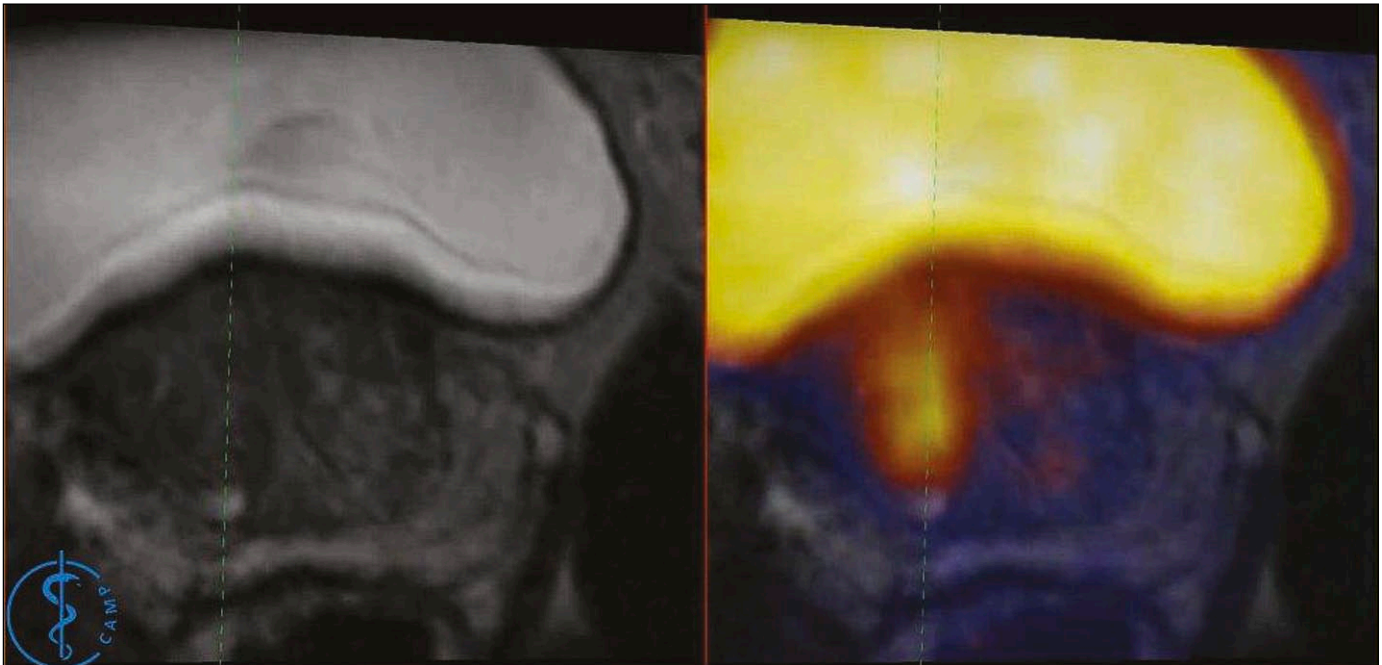


Figure 3. Screenshot of the overhead screen in Figure 2. The dotted green lines superimposed on the MR and PET images correspond to the projected biopsy direction provided by the US system using a 2D transrectal probe. PET/MR images may be used as in this example to help identify the biopsied lesion more accurately, but are not required.

MRI in the diagnostic protocol, 87% of misclassified patients were reclassified using the D'Amico criteria with an increase in active treatment stratification sensitivity to 92% in conjunction with the CAPRA system [32].

Once qualified for AS, patient surveillance is a major challenge. Mp-MRI has a role in monitoring identified lesions, significantly reducing the number of biopsies. A meta-analysis has shown that mp-MRI has moderate accuracy in disease reclassification in AS patients, especially in lesions larger than 10 mm in diameter [33]. Moreover, at intermediate and long-term (up to 15 years) follow-up, a study performed among 819 survivors has shown that there is no added benefit of definitive intervention over AS in patients stratified as having a favorable risk (Gleason ≤ 7 (3+4), PSA 10–20 ng/mL) [34]. It seems that mp-MRI will have an important role in AS protocol patients, but currently no definitive role is established.

Prostate mp-MRI in surgery planning and staging

Due to the superior contrast resolution of MRI (when compared to CT or US), anatomical details necessary for surgery planning can be identified. Prostate mp-MRI has a high negative predictive value (NPV) for extracapsular extension (ECE), with studies reporting from 57% to 97.7%, which is relevant

for treatment planning [35, 36]. For this reason, mp-MRI can be performed to qualify the patient for radical surgical treatment, as well as to prepare for nerve-sparing surgery [37, 38]. Post-surgical pathological exams show that micro-invasion detection remains a challenge for mp-MRI reporting, and this must be taken under consideration when planning surgery. An additional benefit arises from a second opinion by a subspecialized urologist, which may be considered in challenging cases [35, 39]. Apart from surgery planning, mp-MRI use may be increasingly found in radiotherapy treatment planning and in MR guided brachytherapy [40].

Prostate mp-MRI in biochemical recurrence

Following radical prostatectomy, up to 20% of patients are later found to have biochemical recurrence [41]. Local recurrence detection remains elusive for the practicing radiologist, but new techniques are currently being investigated. The EAU guidelines recommend PET scanning with the use of choline, with the application of PSMA being a new and experimental ligand [4]. Prostate MRI has the highest sensitivity in biochemical recurrence when a multiparametric approach is used, with the combined use of DCE and T2WI having a sensitivity of 97% [42]. Prostate mp-MRI also has a role in differentiating between local and

distant metastases, with the DCE sequence being the most useful indicator of local recurrence. A meta-analysis showed a sensitivity of 85% and specificity of 95% for DCE in detection of local recurrence following radical prostatectomy [43, 44]. T2WI and DWI sequences are inferior in imaging local recurrence, as post-procedural fibrosis is difficult to differentiate from recurrence in patients following a radical prostatectomy. Recurrence is usually unifocal and at the site of the previously identified lesion in biochemical failure after surgery and radiation therapy. Mp-MRI may also be used in detection of local metastasis to pelvic lymph nodes and bone. To exclude nodal and skeletal metastases, the protocol is often expanded to include non-pelvic lymph nodes, including the para-aortic and common iliac nodes. However, ESUR guidelines from 2012 recommend limiting additional abdominal sequences to high-risk patients due to its low yield and high rate of incidental findings [10, 45]. It is worthy to mention the evolving use of ultrasmall superparamagnetic iron oxide particles (USPIO) in lymphotropic nanoparticle-enhanced MRI for the detection of metastatic lymph nodes, with high sensitivity (65–92%) and specificity (93–98%), including non-enlarged lymph nodes [46, 47]. This contrast may have a meaningful role in determining lymphatic spread in the future, but it is currently experimental and available in only a few institutions.

CONCLUSIONS

Currently, methods of prostate cancer diagnosis are evolving from the previous approach of clinical examination, PSA and random TRUS biopsy. Magnetic Resonance Imaging has empowered the urologist with a tool to identify suspected lesions, providing the opportunity to perform targeted biopsies. These targeted biopsies may be performed under direct in-bore MRI guidance or by MRI-TRUS fusion imaging. MRI allows urologists to better stratify the patient with regards to biopsy grade and tumor extent, as well as treatment planning. The urologist should develop an understanding with his radiologist, as prostate mp-MRI has an increasing role in prostate cancer characterization, detection, and management. Standardized reporting methods (PI-RADS), help build a common language between the radiologist and the urologist, which is essential for proper patient management and care.

CONFLICTS OF INTEREST

The authors declare no conflicts of interest.

ACKNOWLEDGMENTS

I would like to thank Prof. Dr. Nassir Navab and Dr. Benjamin Frisch from Technische Universität München for supplying images of their MR/US fusion biopsy system. More information is available at: <http://campar.in.tum.de/>

References

1. Arnold M, Karim-Kos H, Coebergh J, et al. Recent trends in incidence of five common cancers in 26 European countries since 1988: Analysis of the European Cancer Registry Observatory. *Eur J Cancer*. 2015; 51: 1164-1187.
2. Roehl KA, Antenor JA V, Catalona WJ. Serial biopsy results in prostate cancer screening study. *J Urol*. 2002; 167: 2435-2439.
3. Cormio L, Scattoni V, Lorusso F, et al. Prostate cancer detection rates in different biopsy schemes. Which cores for which patients? *World J Urol*. 2014; 32: 341-346.
4. Mottet N, Bellmunt J, Briers E, et al. Guidelines on Prostate Cancer. European Association of Urology 2015.
5. Chernyak V, Flusberg M, Kurteva T, Ghavamian R, Rozenblit AM. Accuracy of prostate measurements on MRI with and without an endorectal coil. *Clin Imaging*. 2015; 39: 85-88.
6. Hoeks CCM a, Barentsz JJO, Hambrock T, et al. Prostate cancer: multiparametric MR imaging for detection, localization, and staging. *Radiology*. 2011; 261: 46-66.
7. ACR American College of Radiology. PI-RADS v2 Prostate Imaging and Reporting and Data System: Version 2. 2015; Available from: <http://www.acr.org/Quality-Safety/Resources/PIRADS>
8. Weinreb JC, Blume JD, Coakley FV, et al. Prostate cancer: sextant localization at MR imaging and MR spectroscopic imaging before prostatectomy--results of ACRIN prospective multi-institutional clinicopathologic study. *Radiology*. 2009; 251: 122-133.
9. Mowatt G, Scotland G, Boachie C, et al. The diagnostic accuracy and cost effectiveness of magnetic resonance spectroscopy and enhanced magnetic resonance imaging techniques in aiding the localisation of prostate abnormalities for biopsy: A systematic review and economic evaluation. *Health Technol Assess*. 2013; 17: 1-281.
10. Schieda N, Quon JS, Lim C, et al. Evaluation of the European Society of Urogenital Radiology (ESUR) PI-RADS scoring system for assessment of extra-prostatic extension in prostatic carcinoma. *Eur J Radiol*. 2015; 84: 1843-1848.
11. Barentsz JO, Richenberg J, Clements R, et al. ESUR prostate MR guidelines 2012. *Eur Radiol*. 2012; 22: 746-757.
12. Pallwein L, Mitterberger M, Struve P, et al. Comparison of sonoelastography guided biopsy with systematic biopsy: Impact on prostate cancer detection. *Eur Radiol*. 2007; 17: 2278-2285.
13. Brock M, von Bodman C, Palisaar RJ, et al. The impact of real-time elastography guiding a systematic prostate biopsy to improve cancer detection rate:

- a prospective study of 353 patients. *J Urol.* 2012; 187: 2039-2043.
14. King CR, McNeal JE, Gill H, Presti JC. Extended prostate biopsy scheme improves reliability of Gleason grading: implications for radiotherapy patients. *Int J Radiat Oncol Biol Phys.* 2004; 59: 386-391.
 15. Scattoni V, Zlotta A, Montironi R, Schulman C, Rigatti P, Montorsi F. Extended and saturation prostatic biopsy in the diagnosis and characterisation of prostate cancer: a critical analysis of the literature. *Eur Urol.* 2007; 52: 1309-1322.
 16. Pietzak EJ, Resnick MJ, Mucksavage P, et al. Multiple Repeat Prostate Biopsies and the Detection of Clinically Insignificant Cancer in Men With Large Prostates. *Urology.* 2014; 84: 380-385.
 17. Pokorny MR, De Rooij M, Duncan E, et al. Prospective study of diagnostic accuracy comparing prostate cancer detection by transrectal ultrasound-guided biopsy versus magnetic resonance (MR) imaging with subsequent mr-guided biopsy in men without previous prostate biopsies. *Eur Urol.* 2014; 66: 22-29.
 18. Van Hove A, Savoie PH, Maurin C, et al. Comparison of image-guided targeted biopsies versus systematic randomized biopsies in the detection of prostate cancer: A systematic literature review of well-designed studies. *World J Urol.* 2014; 32: 847-858.
 19. El-Shater Bosaily A, Parker C, Brown LC, et al. PROMIS- Prostate MR imaging study: A paired validating cohort study evaluating the role of multi-parametric MRI in men with clinical suspicion of prostate cancer. *Contemp Clin Trials.* 2015; 42: 26-40.
 20. Willis SR, Ahmed HU, Moore CM, et al. Multiparametric MRI followed by targeted prostate biopsy for men with suspected prostate cancer: a clinical decision analysis. *BMJ Open.* 2014; 4: e004895.
 21. Bostwick DG, Liu L, Brawer MK, Qian J. High-grade prostatic intraepithelial neoplasia. *Rev Urol.* 2004; 6: 171-179.
 22. Jambor I, Kähkönen E, Taimen P, et al. Prebiopsy multiparametric 3T prostate MRI in patients with elevated PSA, normal digital rectal examination, and no previous biopsy. *J Magn Reson Imaging.* 2015; 41: 1394-1404.
 23. Nix JW, Turkbey B, Hoang A, et al. Very distal apical prostate tumours: Identification on multiparametric MRI at 3 Tesla. *BJU Int.* 2012; 110: E694-700.
 24. Nelson AW, Harvey RC, Parker RA, Kastner C, Doble A, Gnanapragasam VJ. Repeat Prostate Biopsy Strategies after Initial Negative Biopsy: Meta-Regression Comparing Cancer Detection of Transperineal, Transrectal Saturation and MRI Guided Biopsy. *PLoS One.* 2013; 8: e57480.
 25. Arsov C, Rabenalt R, Blondin D, et al. Prospective Randomized Trial Comparing Magnetic Resonance Imaging (MRI)-guided In-bore Biopsy to MRI-ultrasound Fusion and Transrectal Ultrasound-guided Prostate Biopsy in Patients with Prior Negative Biopsies. *Eur Urol.* 2015; 68: 713-720.
 26. Volkin D, Turkbey B, Hoang AN, et al. Multiparametric magnetic resonance imaging (MRI) and subsequent MRI/ultrasonography fusion-guided biopsy increase the detection of anteriorly located prostate cancers. *BJU Int.* 2014; 114: E43-49.
 27. Schouten MG, Hoeks CM a., Bomers JGR, et al. Location of Prostate Cancers Determined by Multiparametric and MRI-Guided Biopsy in Patients With Elevated Prostate-Specific Antigen Level and at Least One Negative Transrectal Ultrasound-Guided Biopsy. *AJR Am J Roentgenol.* 2015; 205: 57-63.
 28. Chou R, Croswell JM, Dana T, Bougatsos C, Blazina I, Fu R. Screening for prostate cancer: a review of the evidence for the U.S. Preventive Services Task Force. *Ann Intern Med.* 2011; 155: 762-771.
 29. Wilt TJ, Brawer MK, Barry MJ, et al. The Prostate Cancer Intervention Versus Observation Trial:VA/NCI/AHRQ Cooperative Studies Program #407 (PIVOT): Design and baseline results of a randomized controlled trial comparing radical prostatectomy to watchful waiting for men with clinically localized prostate cancer. *Contemp Clin Trials.* 2009; 30: 81-87.
 30. Mullins JK, Bonekamp D, Landis P, et al. Multiparametric magnetic resonance imaging findings in men with low-risk prostate cancer followed using active surveillance. *BJU Int.* 2013; 111: 1037-1045.
 31. Filippou P, Welty CJ, Cowan JE, Perez N, Shinohara K, Carroll PR. Immediate Versus Delayed Radical Prostatectomy: Updated Outcomes Following Active Surveillance of Prostate Cancer. *Eur Urol.* 2015; 68: 458-463.
 32. Turkbey B, Hareesh M, Aras O, et al. Prostate Cancer: Can Multiparametric MR Imaging Identify Patients Who Are Candidates for Active Surveillance? *Radiology.* 2013; 268: 144-152.
 33. Guo R, Cai L, Fan Y, Jin J, Zhou L, Zhang K. Magnetic resonance imaging on disease reclassification among active surveillance candidates with low-risk prostate cancer: a diagnostic meta-analysis. *Prostate Cancer Prostatic Dis.* 2015; 18: 221-228.
 34. Klotz L, Vesprini D, Sethukavalan P, et al. Long-Term Follow-Up of a Large Active Surveillance Cohort of Patients with Prostate Cancer. *J Clin Oncol.* 2015; 33: 272-277.
 35. Cerantola Y, Valerio M, Kawkabani Marchini A, Meuwly JY, Jichlinski P. Can 3T multiparametric magnetic resonance imaging accurately detect prostate cancer extracapsular extension? *J Can Urol Assoc.* 2013; 7: E699-703.
 36. LARGERON JP, GALONNIER F, VEDRINE N, et al. Multiparametric 3T MRI in the routine staging of prostate cancer. *Prog Urol. France.* 2014; 24: 145-153.
 37. Park BH, Jeon HG, Jeong BC, et al. Influence of magnetic resonance imaging in the decision to preserve or resect neurovascular bundles at robotic assisted laparoscopic radical prostatectomy. *J Urol.* 2014; 192: 82-88.
 38. Ogura K, Maekawa S, Okubo K, et al. Dynamic endorectal magnetic resonance imaging for local staging and detection of neurovascular bundle involvement of prostate cancer: correlation with histopathologic results. *Urology.* 2001; 57: 721-726.
 39. Wibmer A, Vargas HA, Donahue TF, et al. Diagnosis of Extracapsular Extension of Prostate Cancer on Prostate MRI: Impact of Second-Opinion Readings by Subspecialized Genitourinary Oncologic Radiologists. *AJR Am J Roentgenol.* 2015; 205: W73-78.
 40. Tanderup K, Viswanathan AN, Kirisits C, Frank SJ. Magnetic Resonance Image Guided Brachytherapy. *Semin Radiat Oncol.* 2014; 24: 181-191.
 41. Moul JW. Prostate Specific Antigen Only Progression of Prostate Cancer. *J Urol.* 2000; 163: 1632-1642.

42. Roy C, Foudi F, Charton J, et al. Comparative sensitivities of functional MRI sequences in detection of local recurrence of prostate carcinoma after radical prostatectomy or external-beam radiotherapy. *AJR Am J Roentgenol.* 2013; 200: W361-368.
43. Rouvière O, Valette O, Grivolat S, et al. Recurrent prostate cancer after external beam radiotherapy: value of contrast-enhanced dynamic MRI in localizing intraprostatic tumor-correlation with biopsy findings. *Urology.* 2004; 63: 922-927.
44. Haider MA, Chung P, Sweet J, et al. Dynamic Contrast-Enhanced Magnetic Resonance Imaging for Localization of Recurrent Prostate Cancer After External Beam Radiotherapy. *Int J Radiat Oncol Biol Phys.* 2008; 70: 425-430.
45. McEvoy SH, Lavelle LP, Purcell YM, et al. Should abdominal sequences be included in prostate cancer MR staging studies? *Eur J Radiol.* 2015; 84: 1019-1022.
46. Thoeny HC, Triantafyllou M, Birkhaeuser FD, et al. Combined Ultrasmall Superparamagnetic Particles of Iron Oxide-Enhanced and Diffusion-Weighted Magnetic Resonance Imaging Reliably Detect Pelvic Lymph Node Metastases in Normal-Sized Nodes of Bladder and Prostate Cancer Patients. *Eur Urol.* 2009; 55: 761-769.
47. Fortuin AS, Smeenk RJ, Meijer HJM, Witjes AJ, Barentsz JO. Lymphotropic nanoparticle-enhanced MRI in prostate cancer: Value and therapeutic potential. *Curr Urol Rep.* 2014; 15: 389. ■