



# Herpes Simplex Mastitis in an Adolescent Woman: Clinical and Ultrasound Features

사춘기 여성의 단순 포진 유선염: 임상 및 초음파 영상 소견

Seung Kwan Kim, MD<sup>1</sup> , Bo Kyoung Seo, MD<sup>1\*</sup> , Hwa Eun Oh, MD<sup>2</sup> 

Departments of <sup>1</sup>Radiology, <sup>2</sup>Pathology, Korea University Ansan Hospital, Korea University College of Medicine, Ansan, Korea

Herpetic mastitis is extremely rare, and its imaging findings remain unclear. We report a case of herpes simplex mastitis in an adolescent woman and describe the clinical and ultrasound features. The patient showed unilateral nipple and areolar skin thickening and axillary lymphadenopathy on B-mode ultrasonography. Doppler ultrasonography revealed multiple linear and branching blood flows in the areolar area. The lesion was verified as herpes simplex mastitis via a skin biopsy. This report shows that the radiologic features of herpes simplex mastitis may be similar to those of Paget's disease because of localized nipple and areolar skin thickening and increased vascularity.

**Index terms** Herpes Simplex Virus; Breast; Ultrasonography

## INTRODUCTION

Herpes simplex virus (HSV) causes various diseases ranging from mild uncomplicated mucocutaneous infection to life-threatening conditions. The most common site of HSV infection is the skin and mucosal membrane, especially in the oral and genital areas (1). The breast is a rare location for HSV infection, and only one previous case report has described the imaging findings of HSV mastitis (2). Herein, we report a case of HSV mastitis in an adolescent woman and describe its clinical and ultrasound (US) features. We evaluated the breast lesion by using B-mode and Doppler ultrasonography. To our knowledge, the vascular US features of HSV mastitis have not been previously reported.




Received January 16, 2019  
 Revised June 17, 2019  
 Accepted September 30, 2019

\*Corresponding author  
 Bo Kyoung Seo, MD  
 Department of Radiology,  
 Korea University Ansan Hospital,  
 Korea University  
 College of Medicine,  
 123 Jeokgeum-ro, Danwon-gu,  
 Ansan 15355, Korea.

Tel 82-31-412-5229  
 Fax 82-31-412-5224  
 E-mail seoboky@korea.ac.kr

This is an Open Access article distributed under the terms of the Creative Commons Attribution Non-Commercial License (<https://creativecommons.org/licenses/by-nc/4.0>) which permits unrestricted non-commercial use, distribution, and reproduction in any medium, provided the original work is properly cited.

### ORCID iDs

Seung Kwan Kim   
<https://orcid.org/0000-0002-9287-0956>  
 Bo Kyoung Seo   
<https://orcid.org/0000-0002-9512-5361>  
 Hwa Eun Oh   
<https://orcid.org/0000-0002-7000-1872>

## CASE REPORT

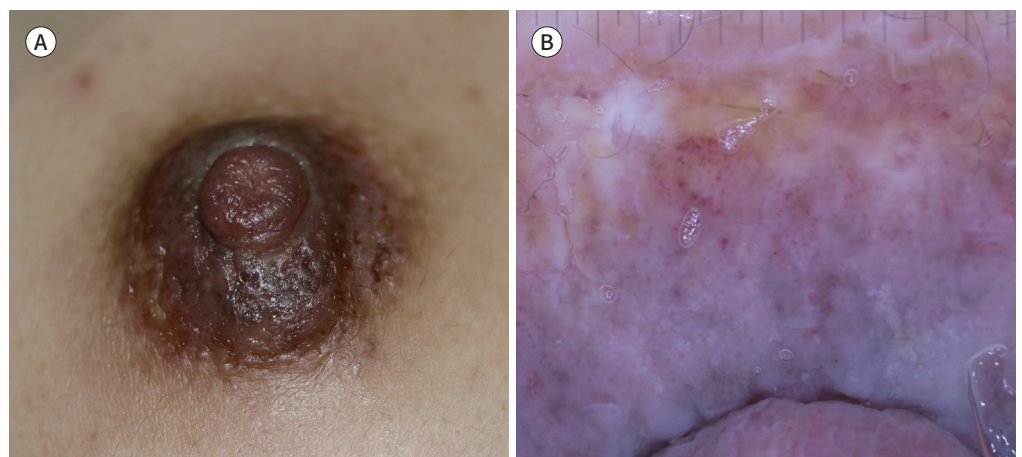
A 17-year-old nulligravida adolescent woman presented to a breast surgeon with a 1-year history of clear nipple discharge and itching on the right nipple and areola. She received topical steroid treatment at a local clinic, but her symptoms did not improve. She had no other history of breast disease or a family history of breast cancer. She was otherwise healthy and did not take any medication. A physical examination of the right breast revealed an eczematous oozing patch and tiny vesicles on the right nipple and areolar area (Fig. 1A, B). Several ipsilateral axillary lymph nodes were palpable. The patient did not present any similar symptoms in her left breast. Considering her young age, initial imaging was performed using ultrasonography rather than mammography.

On US examination, the right periareolar skin was thickened and hypoechoic (Fig. 1C). The lesion extent was 25.0 mm, and the skin thickness was 3.5 mm. Increased vascularity was detected on color Doppler ultrasonography (Fig. 1D). Multiple branching blood flows were also noted in the areolar area. Multiple enlarged lymph nodes less than 20 mm in size were present in the right axilla. These lymph nodes showed cortical thickening (Fig. 1E). On the basis of the US findings, we considered the patient had an uncommon breast infection or Paget's disease. We excluded allergic contact dermatitis because topical steroid application did not improve her clinical symptoms.

A skin punch biopsy of the areolar area revealed a dense neutrophilic exudate with overlying sloughed epithelial cells containing viral inclusions, suggesting herpetic infection (Fig. 1F). The patient was treated with oral famciclovir for 18 days. After treatment, the symptoms completely resolved. A posttreatment skin punch biopsy revealed that the infection had completely resolved. The patient also had a painful erythematous oozing patch in the oral cavity and the left third finger. Considering this fact, the nipple and areolar lesions may have been caused by HSV autoinoculation.

**Fig. 1.** Herpes simplex mastitis in a 17-year-old adolescent, presenting with a 1-year history of clear nipple discharge and itching on the right nipple and areola.

**A, B.** Photograph of the right nipple (**A**) and dermoscopic image of the right periareolar area (**B**) reveal an eczematous oozing patch and tiny vesicles.



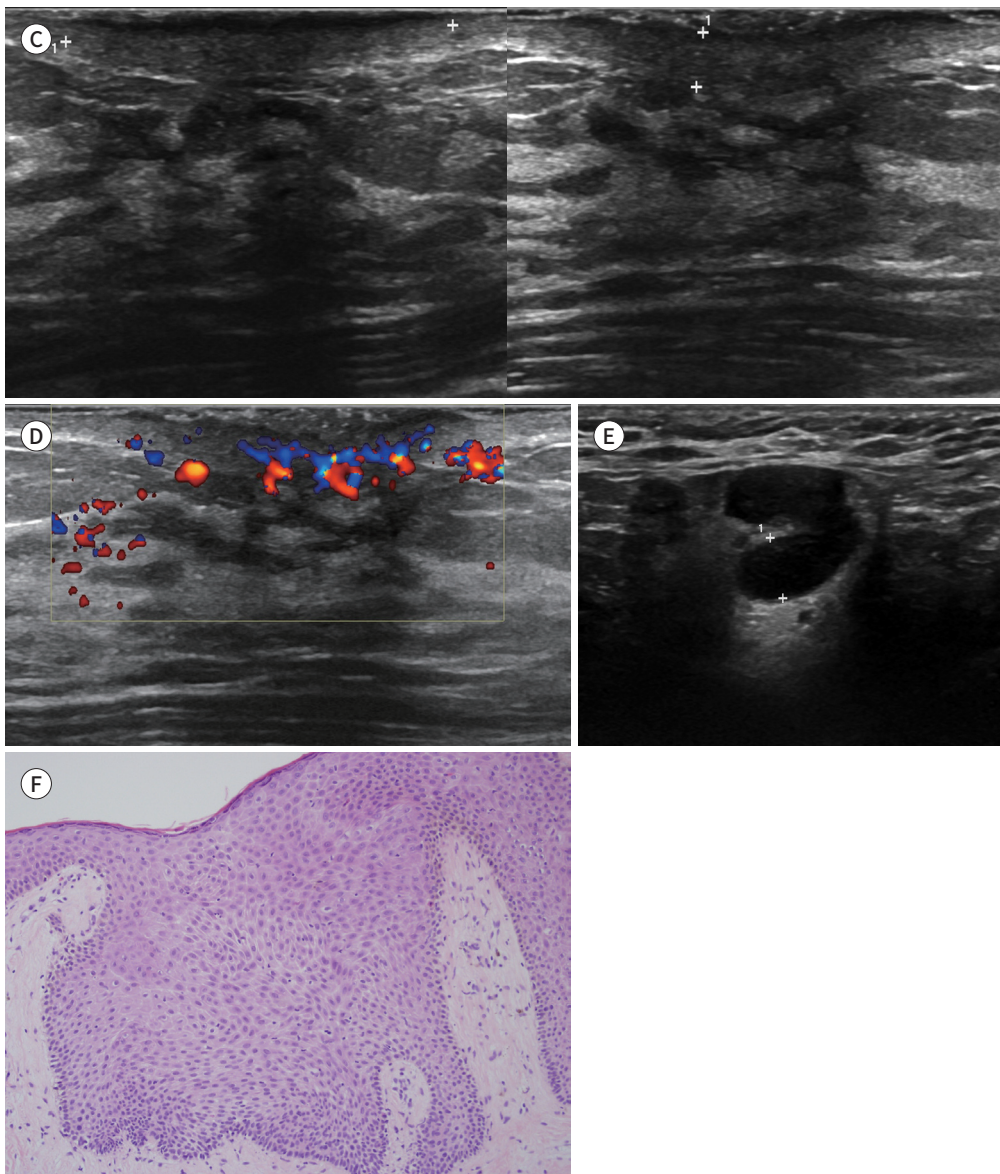
**Fig. 1.** Herpes simplex mastitis in a 17-year-old adolescent, presenting with a 1-year history of clear nipple discharge and itching on the right nipple and areola.

**C.** Ultrasonography shows localized hypoechoic skin thickening in the right periareolar area. The lesion extent is 25.0 mm, and the skin thickness is 3.5 mm.

**D.** Color Doppler ultrasonography shows multiple linear and branching blood flows in the right periareolar skin.

**E.** Ultrasonography of the right axilla reveals multiple enlarged lymph nodes with cortical thickening.

**F.** Hematoxylin and eosin staining ( $\times 40$ ) performed during a pathologic examination shows a dense neutrophilic exudate with overlying sloughed epithelial cells containing viral inclusions.



## DISCUSSION

HSV infection of the breast is very rare. The majority of herpetic breast infections are related to HSV-1 infection, and HSV-2 infection is exceptional (2-8). The common clinical features of a herpetic breast infection are pruritus and painful swelling with dermatologic manifesta-

tions, including swelling, erythema, small vesicles, and excoriation. Moreover, unilateral breast infections are more common. The lesion is usually confined to the nipple-areolar complex and periareolar area (6). Nevertheless, a few cases of cutaneous dissemination to the whole breast have been reported (2, 3).

Prior reports revealed three sources of HSV transmission to the breast. The most frequent etiology of HSV mastitis is an infant-maternal transmission during breastfeeding (3, 5). In non-lactating women, HSV mastitis can occur via autoinoculation or oral sexual contact (4, 7, 8). Autoinoculation may occur from recurrent orolabial herpetic infections in the patients themselves. Considering these transmission modes, the nipple-areolar complex and periareolar area can be vulnerable to HSV mastitis.

Few reports have documented the imaging findings of HSV mastitis. In a case report, Soo and Ghate (2) reported that HSV mastitis showed diffuse asymmetry and skin thickening on mammography and skin thickening and axillary lymphadenopathy on ultrasonography. A physical examination revealed excoriation at the nipple tip and diffuse peau d'orange breast skin edema, mimicking inflammatory breast cancer or another mastitis etiology. Unlike the patient in the prior report, our patient showed a more localized infection, confined to the nipple and areola, which is a more frequent form of herpetic breast infection than is the disseminated form. In our patient, ultrasonography revealed localized hypoechoic skin thickening at the nipple and areola. We also performed color Doppler ultrasonography, which revealed multiple linear and branching blood flows in the localized skin thickening at the nipple and areola. To our knowledge, these Doppler US findings have not been previously reported.

The differential diagnosis of localized hypoechoic skin thickening in the nipple-areolar complex is Paget's disease as well as various benign processes, such as breast eczema, allergic contact dermatitis, or irritant dermatitis (9). Breast eczema typically occurs bilaterally. Paget's disease of the nipple-areolar complex is characterized by the presence of neoplastic cells in the epidermis. It shows unilateral skin changes and is associated with a breast mass or calcifications (10). Distinguishing HSV mastitis clinically and radiologically from Paget's disease is difficult. However, skin thickening is a major radiological finding in HSV mastitis, and a mass, calcification, or ductal dilatation is rare. Although a pathologic examination is necessary to exclude a malignant lesion such as Paget's disease, HSV mastitis should be included in the differential diagnosis of unilateral nipple and areolar skin thickening with increased vascularity, especially when the patient has other skin lesions suggestive of herpetic infection.

In conclusion, HSV infection of the nipple and areolar area is an uncommon entity that may easily be misdiagnosed. The radiological findings of HSV mastitis are similar to those of Paget's disease because of localized skin thickening and hypervascularity. Although tissue biopsy is essential to rule out malignant processes and to confirm the diagnosis, HSV mastitis should be included in the differential diagnosis of unilateral skin thickening in the nipple-areolar complex in women, especially when symptoms do not improve after topical steroid application.

#### Author Contributions

Conceptualization, S.B.K.; investigation, K.S.K.; methodology, S.B.K.; resources, K.S.K., O.H.E.; supervision, S.B.K.; validation, K.S.K.; visualization, K.S.K.; writing—original draft, K.S.K.; and writing—review & editing, S.B.K.

## Conflicts of Interest

The authors have no potential conflicts of interest to disclose.

## REFERENCES

1. Whitley RJ, Roizman B. Herpes simplex virus infections. *Lancet* 2001;357:1513-1518
2. Soo MS, Ghate S. Herpes simplex virus mastitis: clinical and imaging findings. *AJR Am J Roentgenol* 2000; 174:1087-1088
3. Barrett ME, Heller MM, Stone HF, Murase JE. Primary herpes simplex virus infection of the nipple in a breastfeeding woman. *Cutis* 2016;97:E10-E11
4. Brown H, Kneafsey P, Kureishi A. Herpes simplex mastitis: case report and review of the literature. *Can J Infect Dis* 1996;7:209-212
5. Sealander JY, Kerr CP. Herpes simplex of the nipple: infant-to-mother transmission. *Am Fam Physician* 1989;39:111-113
6. Toussaint A, Simonson C, Valla C. Herpes mastitis: diagnosis and management. *Breast J* 2016;22:335-338
7. Whitley RJ, Nahmias AJ, Visintine AM, Fleming CL, Alford CA. The natural history of herpes simplex virus infection of mother and newborn. *Pediatrics* 1980;66:489-494
8. Yoshida M. Herpetic pharyngitis with mammary and genital herpes due to sexual contact. *Acta Derm Venereol* 1999;79:250
9. Nicholson BT, Harvey JA, Cohen MA. Nipple-areolar complex: normal anatomy and benign and malignant processes. *Radiographics* 2009;29:509-523
10. Lim HS, Jeong SJ, Lee JS, Park MH, Kim JW, Shin SS, et al. Paget disease of the breast: mammographic, US, and MR imaging findings with pathologic correlation. *Radiographics* 2011;31:1973-1987

## 사춘기 여성의 단순 포진 유선염: 임상 및 초음파 영상 소견

김승관<sup>1</sup> · 서보경<sup>1\*</sup> · 오화은<sup>2</sup>

유방에서 발생하는 헤르페스 감염은 매우 드물며 영상 소견 또한 잘 알려져 있지 않다. 본 증례 보고는 사춘기 여성 환자에서 발생한 헤르페스 유선염의 증례로 임상 소견 및 초음파 영상 소견을 기술하였다. B-mode 초음파에서는 일측성의 유륜 피부 두께 증가 및 액와부 림프절 종대의 소견을 보였고 도플러 초음파 상에서는 분지하는 양상의 선형 혈류 증대가 관찰되었다. 유륜 피부 생검을 통하여 헤르페스 감염으로 확진되었다. 헤르페스 유선염의 영상 소견은 국소적인 유두와 유륜 피부 비후와 혈류 증가로 유방의 Paget 병과 유사할 수 있으므로 감별이 필요하다.

고려대학교 의과대학 안산병원 <sup>1</sup>영상의학과, <sup>2</sup>병리학과