

Eccrine porocarcinoma: A rare case of an in situ tumor with lymph node metastases



Anna Catharina van den Brand, MD,^a Jeffrey Damman, MD, PhD,^b
 Floris H. Groenendijk, MD, PhD,^b and Rick Waalboer-Spuij, MD, PhD^a
Rotterdam, The Netherlands

Key words: Eccrine porocarcinoma; in situ; metastasis; molecular analysis.

INTRODUCTION

Eccrine porocarcinoma (EPC) is a rare skin malignancy that represents around 0.01% of all skin tumors.^{1,2} There is a wide range of clinical presentations of this neoplasm such as papules, plaques, and nodules. Most tumors appear in the head and neck region or on the lower extremities, but all body parts can be involved. EPC is frequently clinically misdiagnosed as squamous cell carcinoma or Bowen disease because the tumors have similar clinical presentations. Therefore, histopathologic examination prior to therapy is required.

EPC is known for its high recurrence and metastatic rate of both 20%. Metastases are mostly found in the regional lymph nodes and mortality among patients with EPC with nodal metastasis is high (67%). The survival period for patients with distant metastasis is reported to be 5 to 24 months.¹

At this moment, no therapy exists as the gold standard because of the rarity of the disease, although surgery (wide local excision or Mohs micrographic surgery) is the common treatment for local disease. In case of metastatic and/or recurrent disease, it is suggested to add chemotherapy and/or radiotherapy. There is no consistency about which chemotherapy should be added due to the rarity of the disease.^{1,2}

Here we present a patient with EPC in situ with lymph node metastases.

CASE REPORT

A 58-year-old man was referred by his general practitioner to the dermatology outpatient clinic of our

Abbreviation used:

EPC: eccrine porocarcinoma

hospital with a skin lesion on his right hip. The lesion existed for 11 years, and 2 previous biopsies performed by the general practitioner both showed Bowen disease. The lesion was subsequently repeatedly treated with cryotherapy without complete response. A few weeks before his first visit to our department, the lesion increased in size and thickness. No other skin lesions were present and the medical history was negative for any other skin disease.

Besides the skin lesion, 18 months earlier the patient had biopsy-proven lymph node metastases of the right groin, parailiac, and para-aortic right. The lymph node biopsies showed a non-small cell carcinoma of unknown primary origin. The tumor cells were initially found positive for CKAE1/AE3, CK7, EMA, GATA3, and p40, and negative staining was found for SOX10, CD15, and OCT4. Based on this immunohistochemical profile, the case was signed out as a non-small cell carcinoma of unknown primary origin. Based on the p40⁺ and GATA3⁺ staining, a suggestion of metastatic poorly differentiated squamous cell carcinoma or urothelial carcinoma was made. Extensive clinical workup in search for a primary tumor with computed tomography, positron emission tomography, and cystoscopy failed to detect a primary tumor. The patient was subsequently treated with chemotherapy (cisplatin-etoposide and carboplatin-etoposide).

From the Departments of Dermatology^a and Pathology,^b Erasmus University Medical Center.

Funding sources: None.

Conflicts of interest: None disclosed.

Correspondence to: Rick Waalboer-Spuij, MD, PhD, Department of Dermatology, Erasmus MC University Medical Centre, Postbus 2040, 3000 CA, Rotterdam, the Netherlands. E-mail: r.waalboer@erasmusmc.nl.

JAAD Case Reports 2020;6:42-5.

2352-5126

© 2019 by the American Academy of Dermatology, Inc. Published by Elsevier, Inc. This is an open access article under the CC BY-NC-ND license (<http://creativecommons.org/licenses/by-nc-nd/4.0/>).

<https://doi.org/10.1016/j.jidcr.2019.10.020>

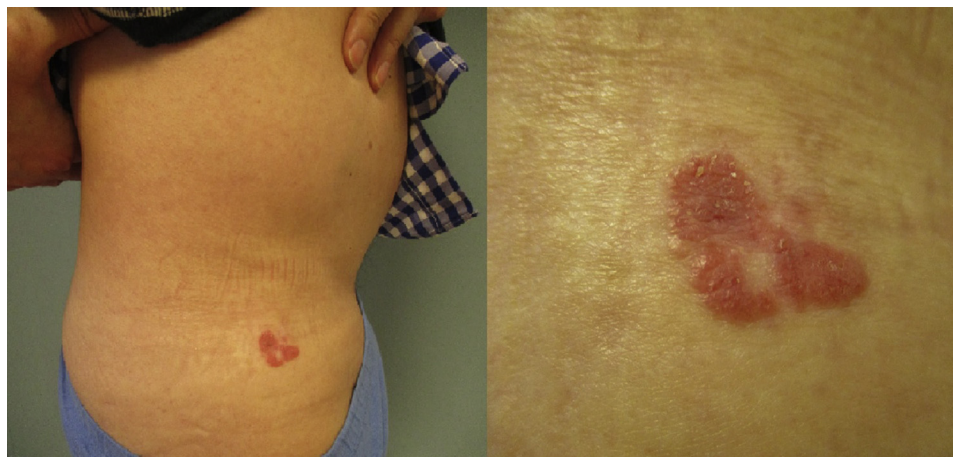

Fig 1. Close-up of the lesion on the right hip of the patient.

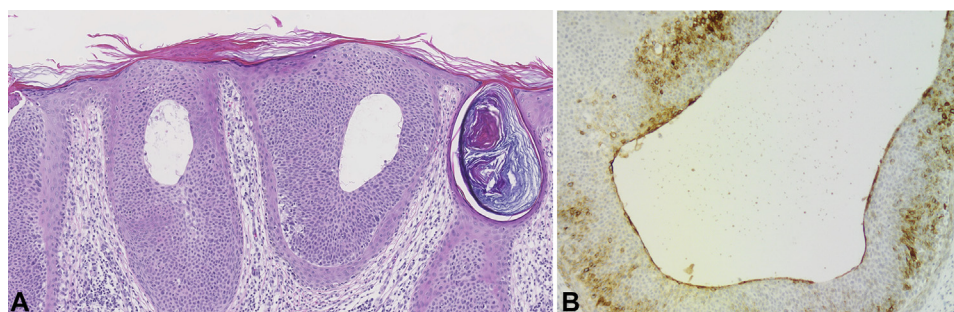


Fig 2. Porocarcinoma in situ. **A**, The epidermis shows an intraepidermal proliferation of expansile epithelial nests with cystic foci of ductal differentiation lined by an inner cuticle layer and composed of poroid cells showing nuclear polymorphism and nuclear hyperchromasia. **B**, EMA staining shows a positive inner EMA-positive cuticle layer on cystic foci of ductal differentiation.

At the time of dermatologic total body inspection, we noticed an erythematous nummular superficial plaque with central hyperkeratosis on the patient's right hip (Fig 1). No other skin lesions were seen.

A diagnostic excision of the whole lesion was performed. Histopathologic examination found an intraepidermal proliferation with large expansile epithelial nests with central comedonecrosis. The epithelial nests were composed of poroid cells showing nuclear polymorphism and nuclear hyperchromasia. In areas, the proliferation showed cystic foci of ductal differentiation with presence of an inner EMA-positive cuticle layer (Fig 2, A and B). Also, abortive duct differentiation was focally observed in the form of intracytoplasmic lumina. P53 showed an aberrantly high expression in lesional cells. Altogether, the histopathologic features are consistent with eccrine porocarcinoma in situ.

Although invasive growth was not found, we reasoned that the previously diagnosed lymph

node metastases could be metastases of the porocarcinoma in situ. Both the earlier biopsies of the skin lesion and the earlier lymph node biopsies were reviewed. In the skin biopsies, the diagnosis of a porocarcinoma in situ was confirmed instead of the previously diagnosed Bowen disease. Review of the lymph node biopsies confirmed the metastases of a non-small cell carcinoma. In retrospect, however, the tumor cells in both biopsies focally showed abortive duct differentiation with the presence of an intracytoplasmic lumina (Fig 3, A). The luminal cuticular layer was highlighted by epithelial membrane antigen (EMA) staining that confirmed the ductal differentiation (Fig 3, B). Additional molecular analysis using targeted next-generation sequencing of both the porocarcinoma in situ and the metastasis found an identical hotspot TP53 exon 7 missense mutation (c.743G>A,p.R248Q (NM 000546)) with a variant allele frequency of 77% in the porocarcinoma in situ and 17% in the lymph node metastasis

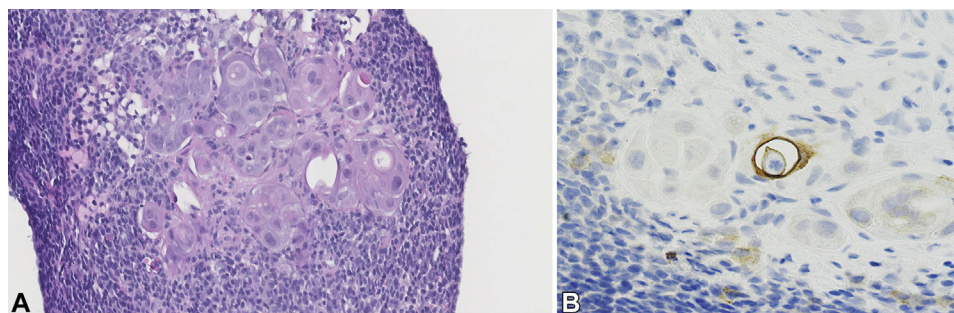


Fig 3. Lymph node metastasis shows fields of epithelial cells with cytonuclear atypia and focal duct differentiation with presence of an eosinophilic inner cuticle layer (A) highlighted with EMA (B).

(estimated tumor cell percentages 80% and 40%, respectively). This hotspot mutation has previously been identified in porocarcinoma; however, this hotspot mutation is also commonly found in other tumors.³ Single-nucleotide polymorphism analysis showed loss of the wild-type TP53 allele in both tumors. Furthermore, strong aberrant nuclear p53 immunohistochemical staining was present in both lesions supporting our molecular findings. Importantly, single-nucleotide polymorphism analysis identified additional chromosomal losses (chromosome 3p, 10q, and 13q) that were shared by both lesions.

Because of the similar histopathologic findings of the porocarcinoma in situ and the lymph node metastases, together with an identical molecular profile, it is highly suggestive that both lesions represent the same entity.

Unfortunately, the lymph node metastases progressed under chemotherapeutic treatment, and the patient died of metastatic disease half a year after the EPC in situ was diagnosed.

DISCUSSION

There are several cases described in which an EPC originated from the site of a pre-existing Bowen disease.⁴⁻⁶ There are also cases described of lymph node metastases with unknown primary tumor that appeared to be metastasis of an eccrine porocarcinoma.⁷ The uniqueness in this case is that the patient was previously repeatedly given a diagnosis of Bowen disease, which appeared to be a porocarcinoma in situ and the primary tumor of lymph node metastases. This case demonstrates the importance of molecular analysis as a tool in search for the primary tumor.

Several possibilities exist for how an in situ carcinoma could cause lymph node metastases. The primary tumor most likely regressed from infiltrative to in situ from chemotherapy, as

previously described in EPC.⁸ Another possibility is that the innate or the adaptive immune system was activated (upon metastasis) and caused spontaneous regression of the invasive component of the primary tumor.^{9,10} A third option is the chance that the invasive component was sampled in the earlier biopsies and/or the latter skin excision but not detected by light microscopy, as not all tissue is routinely analyzed. In case there was an invasive component at that time, it could be gone as a result of the previous treatments with cryotherapy.

Here we report a rare case of an eccrine porocarcinoma in situ that metastasized to the regional lymph nodes. We recommend to critically re-assess the patient's clinical history and findings when there is a metastatic disease with an unknown primary tumor and a superficial or in situ lesion.

REFERENCES

1. Nazemi A, Higgins S, Swift R, In G, Miller K, Wysong A. Eccrine porocarcinoma: new insights and a systematic review of the literature. *Dermatol Surg.* 2018;44(10):1247-1261.
2. Salih AM, Kakamad FH, Baba HO, et al. Porocarcinoma; presentation and management, a meta-analysis of 453 cases. *Ann Med Surg (Lond).* 2017;20:74-79.
3. Harms PW, Hovelson DH, Cani AK, et al. Porocarcinomas harbor recurrent HRAS-activating mutations and tumor suppressor inactivating mutations. *Hum Pathol.* 2016;51:25-31.
4. Thuruthil RR, Jayalakshmy PS, Sukumar V. A case of recurrent eccrine porocarcinoma with regional lymph nodal metastasis, arising on a bowen's disease patch. *Indian J Surg.* 2015; 77(Suppl 1):182-184.
5. Lowney AC, Mc Aleer MA, O'Connor K, Fitzgibbon JF, Bourke JF. Eccrine porocarcinoma arising within an area of Bowen disease. *Clin Exp Dermatol.* 2012;37(2):136-138.
6. Hoshina D, Akiyama M, Hata H, Aoyagi S, Sato-Matsumura KC, Shimizu H. Eccrine porocarcinoma and Bowen's disease arising in a seborrheic keratosis. *Clin Exp Dermatol.* 2007; 32(1):54-56.
7. Günhan O, Karşlıoğlu Y, Alömeroğlu M, Berberoğlu U. Eccrine porocarcinoma: a case with an obscure primary tumor diagnosed from lymph node metastasis. *Am J Dermatopathol.* 2007;29(2):176-179.

8. Aaribi I, Mohtaram A, Ben Ameer El Youbi M, et al. Successful management of metastatic eccrine porocarcinoma. *Case Rep Oncol Med.* 2013;2013:282536.
9. Thomas JA, Badini M. The role of innate immunity in spontaneous regression of cancer. *Indian J Cancer.* 2011;48(2):246-251.
10. Mansfield AS, Heikkila P, von Smitten K, Vakkila J, Leidenius M. Metastasis to sentinel lymph nodes in breast cancer is associated with maturation arrest of dendritic cells and poor co-localization of dendritic cells and CD8+ T cells. *Virchows Arch.* 2011;459(4):391-398.