

Impact of prior biliary stenting on diagnostic performance of endoscopic ultrasound for mesenteric vascular staging in patients with head of pancreas and perampullary malignancy

Kofi W Oppong ,^{1,2} Manu K Nayar ,¹ Noor L H Bekkali,³ Pardeep Maheshwari,¹ Beate Haugk,⁴ Antony Darne,⁴ Derek M Manas,^{1,5} Jeremy J French,^{1,5} Steven White,^{1,5} Gourab Sen,^{1,5} Sanjay Pandanaboyana,^{1,5,6} Richard M Charnley,^{1,5} John S Leeds ^{1,6}

To cite: Oppong KW, Nayar MK, Bekkali NLH, *et al.* Impact of prior biliary stenting on diagnostic performance of endoscopic ultrasound for mesenteric vascular staging in patients with head of pancreas and perampullary malignancy. *BMJ Open Gastro* 2022;**9**:e000864. doi:10.1136/bmjgast-2021-000864

Received 18 December 2021
Accepted 13 February 2022

ABSTRACT

Objective The diagnostic performance of endoscopic ultrasound (EUS) for stratification of head of pancreas and perampullary tumours into resectable, borderline resectable and locally advanced tumours is unclear as is the effect of endobiliary stents. The primary aim of the study was to assess the diagnostic performance of EUS for resectability according to stent status.

Design A retrospective study was performed. All patients presenting with a solid head of pancreas mass who underwent EUS and surgery with curative intent during an 8-year period were included. Factors with possible impact on diagnostic performance of EUS were analysed using logistic regression.

Results Ninety patients met inclusion criteria and formed the study group. A total of 49 (54%) patients had an indwelling biliary stent at the time of EUS, of which 36 were plastic and 13 were self-expanding metal stents (SEMS). Twenty patients underwent venous resection and reconstruction (VRR). Staging was successfully performed in 100% unstented cases, 97% plastic stent and 54% SEMS, $p < 0.0001$. In successfully staged patients, sensitivity, specificity, accuracy, positive predictive value (PPV) and negative predictive value (NPV) for classification of resectability were 70%, 70%, 70%, 42% and 88%. For vascular involvement (VI), sensitivity, specificity, accuracy, PPV and NPV were 80%, 68%, 69%, 26% and 96%. Increasing tumour size OR 0.53 (95% CI, 0.30 to 0.95) was associated with a decrease in accuracy of VI classification.

Conclusions EUS has modest diagnostic performance for stratification of staging. Staging was less likely to be completed when a SEMS was in situ. Staging EUS should ideally be performed before endoscopic retrograde cholangiopancreatography and biliary drainage.

INTRODUCTION

Pancreatic protocol CT scan is the initial suggested imaging test in patients presenting with suspected pancreatic cancer (PC), endoscopic ultrasound (EUS) being recommended

Summary box

What is already known about this subject?

▶ Endoscopic ultrasound (EUS) staging of pancreatic malignancy is indicated when pancreatic protocol CT scan does not identify a mass or staging is equivocal.

What are the new findings?

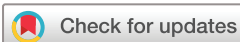▶ Indwelling self-expanding metal stents (SEMS) prevents EUS vascular staging in a significant proportion of cases. Plastic stents do not prevent staging or impair diagnostic performance when EUS staging is successfully carried out.

How might it impact on clinical practice in the foreseeable future?

▶ The findings of the study support the performance of EUS staging before endoscopic retrograde cholangiopancreatography (ERCP) and stenting with SEMS. If ERCP and biliary stenting are performed before staging, EUS consideration should be given to placing a plastic stent.

if diagnosis remains unclear and/or tissue sampling required.¹ EUS was reported to have a sensitivity of 72% and specificity of 89% in a systematic review² in determining vascular involvement with more recent studies documenting lower diagnostic performance. However, many of the studies are from an earlier era of pancreatic surgery when venous resection and reconstruction (VRR) was not systematically employed and have assessed purely dichotomously against criteria of resectable or unresectable or vascular involvement/no vascular involvement.

With modern surgical techniques, vascular involvement in itself is not a contraindication



© Author(s) (or their employer(s)) 2022. Re-use permitted under CC BY-NC. No commercial re-use. See rights and permissions. Published by BMJ.

For numbered affiliations see end of article.

Correspondence to

Dr Kofi W Oppong;
kofi.oppong@nhs.net



to surgery, which is dependent on the vessel(s) involved and whether VRR is feasible. Pancreatectomy with arterial resection is rarely recommended. However today, with improved surgical techniques, VRR is routinely performed with acceptable outcomes.³ The concept of resectable, borderline resectable and locally advanced tumours continues to evolve and has been codified.^{4,5} The performance of EUS in categorising accurately between resectable/borderline resectable and locally advanced tumours is arguably of greater importance than a simple classification of vessel involvement or not given the different treatment strategies.

A tumour-free resection margin in excess of 1 mm is an important independent predictor of long-term survival.^{3,6} Additionally, while tethering of tumour to vessels at the time of surgery requires VRR, this may be caused by a fibro-inflammatory reaction rather than tumour invasion. Histological involvement is diagnosed when tumour invades the smooth muscle of the media of the vessel, with or without invasion of the intima;⁷ such invasion is possibly associated with a worse prognosis compared with involvement of adventitia alone⁸ although the evidence is conflicting.⁹ The need for VRR therefore does not always equate to histological vascular involvement. Several studies have documented that self-expanding metal stents (SEMS) are superior to plastic stents for preoperative drainage and palliation.^{10–12} Consequently, SEMS are increasingly preferred to plastic stents. However, the presence of a biliary stent may impair accurate EUS staging of vessel involvement, due to postacoustic shadowing and reverberations which may be more marked with metal stents. A number of studies as depicted in table 1 have previously investigated the effect of biliary stents on EUS staging with conflicting results.^{13–15} Furthermore, previous studies of EUS staging have not

assessed against surgery, histological vessel involvement and resection margin concurrently or comprehensively accounted for other potential influencing factors such as indwelling stents. The aim of this study was to assess the diagnostic performance of EUS classification of resectability, histological vascular involvement and resection margin involvement accounting for potential influencing variables.

PATIENTS AND METHODS

The cohort included consecutive adult patients with pancreatic ductal adenocarcinoma (PDAC), ampullary adenocarcinoma and distal bile duct carcinoma who underwent EUS staging and subsequent surgery with curative intent between January 2010 and December 2017 inclusive at the Freeman Hospital. The study was a retrospective analysis of prospectively maintained databases. Patients with a biliary stent constituted the intervention group versus a control group of patients without stents. A minimum of 12-month follow-up was available. EUS procedures were performed by four experienced endosonographers. All clinical information and the reports of any prior imaging were available at the time of the EUS procedure. All patients were managed by a dedicated pancreaticobiliary multidisciplinary team. Variables included in analysis were: presence of a biliary stent, stent type if present, tumour size, increased experience (as represented by passage of time), age, sex, interval in weeks between EUS assessment and surgery.

EUS procedure

All procedures were performed under conscious sedation using combinations of intravenous midazolam and pethidine, with standard cardiorespiratory monitoring. Pentax

Table 1 Previous studies which specifically investigated the impact of stent presence on staging

Authors	Year	EUS type	Cancer location	Stent, n (type)	Comments
Cannon <i>et al</i> , ²⁹ N=50	1998	Radial	Ampulla	25 (PS)	Overall accuracy 78%. T staging reduced from 84% to 72% by stent. All patients underwent surgery.
Fusaroli <i>et al</i> , ¹⁴ N=65	2006	Radial	Head of pancreas	19 (PS)	T stage correct in 85% unstented and 47% with stents. Patients with stents 6.55 times more likely to be incorrectly T staged. All patients underwent surgery.
Bao <i>et al</i> , ¹³ N=76	2007	Linear	Head of pancreas	36 (not stated)	Overall sensitivity 57%, specificity 67%, PPV 61% and NPV 63% for EUS assessment of venous involvement in determining positive resection margin or locally advanced and unresectable at surgery. In 27 patients without stent, were 79%, 69%, 73% and 75% respectively.
Shami <i>et al</i> , ¹⁵ N=55	2008	Linear	Pancreas	28 (SEMS)	Overall staging not just T or vascular stage assessed. EUS correctly staged 52% of patients without SEMS compared with 46% of patients with SEMS. Surgical exploration in 65% and resection in 25% of patients. Main reason for inaccurate staging was failure to identify metastatic disease.

EUS, endoscopic ultrasound; NPV, negative predictive value; PPV, positive predictive value; PS, plastic stent; SEMS, self-expandable metal stents.

linear echoendoscopes (Pentax, Slough, UK) and Hitachi ultrasound workstations (Hitachi Medical Systems, Wellingborough, UK) were used. Lesion assessment and staging, including the use of colour Doppler, was performed when the mass lesion was identified. During the procedure, tumour relationship to major vessels including the coeliac axis (CA), superior mesenteric vein (SMV), superior mesenteric artery (SMA), hepatic artery (HA) and portal vein (PV) was routinely recorded.

Exclusion criteria included EUS performed solely for tissue sampling, patients who underwent neoadjuvant chemotherapy (NAT) following EUS, patients in whom an attempt at resection was precluded by identification during surgery of metastatic disease and an interval between EUS and surgery greater than 60 days.

EUS reports were categorised as indicating resectable, borderline resectable or locally advanced tumors as per National Comprehensive Cancer Network clinical practice guideline vascular criteria.⁵ A report was classified as indicating resectable disease if there was no evidence of any vascular involvement (VI). Reports were classified as borderline resectable, that is, neither clearly resectable nor clearly unresectable, if there were any of the following features: (1) tumour involvement and/or narrowing of the lumen of the PV/SMV, over a short section. (2) Short segment involvement of the HA, without extension to the CA. (3) Tumour abutment of the SMA less than 180°.

Reports were classified as indicating locally advanced if there were any of the following features: (1) greater than 180° SMA encasement, (2) any CA involvement, (3) unreconstructible SMV/PV involvement and (4) aortic invasion or encasement.

Resection without VRR was required for EUS classification of resectable to be accurate. Correct classification as borderline required either VRR or unresectability due to vascular invasion. Correct classification as locally advanced required failure to perform a pancreaticoduodenectomy due to vascular invasion and consideration for palliative chemotherapy.

For the purposes of calculating diagnostic performance of VI EUS examinations categorised as resectable were classified as negative and examinations categorised as borderline or unresectable were classified as positive.

The surgical operation notes and histology reports were reviewed. Surgical gold standard was based on the intraoperative assessment by the surgeon. If the PV and/or SMV were found to be involved by obvious tumour or an indeterminate inflammatory/malignant process then VRR was performed. If venous involvement was too extensive for reconstruction or there was invasion of the coeliac, superior mesenteric or common HA the tumour was deemed unresectable.

Resection specimens were prepared and reported as per the Royal College of Pathology guidelines 2010.¹⁶ Histology reports were reviewed, and the resection margin (R) classification of the resection specimen noted and where a vessel had been resected the extent of tumour invasion within the vessel wall noted. Tumour

involvement of the vessel wall media was required for classification as histological vascular invasion.

Primary objective

The primary objective was: to determine the diagnostic performance of EUS classification of resectability among patients with malignancy involving the head of pancreas and periampullary region undergoing pancreaticoduodenectomy.

Secondary objectives

The secondary objectives were: (1) to determine the impact of the presence of indwelling biliary stents on the ability to perform EUS staging. (2) To determine diagnostic performance of EUS assessment of vascular involvement as a predictor for histological vessel wall invasion using the pathology report as the gold standard. (3) To determine diagnostic performance of EUS assessment of vascular involvement as a predictor for histologically positive margins using the pathology report as the gold standard.

General statistical analysis

Continuous variables are reported as mean and SD if normally distributed and the median and IQR otherwise. Comparisons of continuous variables between groups were made using analysis of variance if the values followed the normal distribution and the Kruskal-Wallis test otherwise. Categorical data were compared between groups using the χ^2 test. MedCalc statistical software V.20 (MedCalc Software Ltd, Ostend, Belgium; <https://www.medcalc.org>; 2021) was used.

Multivariable analysis

The outcome variable was whether the patients were accurately staged which was considered as a binary measure (yes/no). All analyses were performed using logistic regression. The analysis was performed in two stages. First, the separate association between each factor and the outcome was examined separately in a series of univariable analyses. Subsequently, a multivariable analysis was performed. The OR and 95% CI of each outcome were calculated. For the continuous variables, the ORs indicate the relative change in the odds of correct staging for a 1-unit increase in each factor (unless otherwise indicated). A backwards selection procedure was used to retain only the significant variables in the final analysis.

RESULTS

Baseline

During the study period, 158 patients underwent surgery with curative intent for a suspected malignant head of pancreas mass, having had prior EUS. A total of 68 patients were excluded and 90 patients formed the study group. A total of 76 patients in the study group had a histological diagnosis of PDAC, 7 had cholangiocarcinoma and 7 had ampullary adenocarcinoma. **Figure 1** details patient flow including reasons for exclusion. A total of 41 patients had no stent, 36 had a plastic stent and

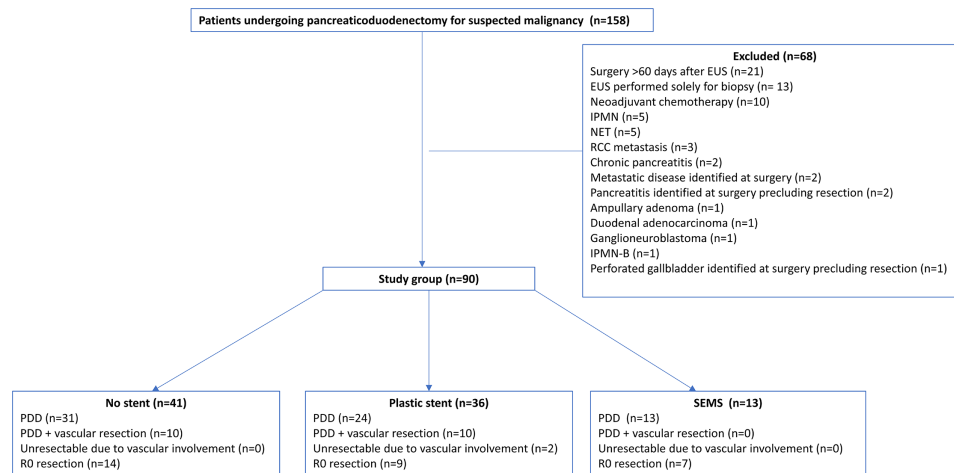


Figure 1 Flow diagram of patients included into the final analysis detailing surgical and histological outcomes. IPMN, intraductal papillary mucinous neoplasm; IPMN-B, IPMN bile duct; NET, neuroendocrine tumour; PDD, pancreaticoduodenectomy; RCC, renal cell carcinoma.

13 had a SEMS. A total of 68 patients underwent pancreaticoduodenectomy alone, 20 pancreaticoduodenectomy with VRR and 2 were unresectable due to vascular involvement. Baseline characteristics and per stent status are depicted in [table 2](#). In seven patients (six SEMS and one plastic), vascular staging was unable to be performed due to ultrasound artefact caused by the stent; consequently, there was a statistically significantly smaller proportion of SEMS cases successfully staged (53.8%) compared with no stent (100%) or plastic stent (97.2%).

EUS assessment

[Table 3](#) details the relationship between EUS staging and surgical and histological outcomes. Of the 83 patients who were successfully staged, 50 were assessed as resectable of which all underwent resection and 6 required VRR of which 2 (33%) had histological vessel invasion. A total of 30 patients were assessed as borderline, 12 of these required VRR and 1 was unresectable. Of the VRR cases, 7 (58%) had histological vessel invasion. Three patients were assessed as unresectable of which two underwent VRR and one was unresectable. Overall 44/50 (88%) assessed as resectable were correctly categorised compared with 14/33 (42%) assessed as borderline or unresectable, $p < 0.0001$.

[Table 4](#) details the overall diagnostic performance for resectability, histological vessel wall invasion and resection margin. For resectability using surgical assessment as the gold standard, sensitivity and specificity were 70%. The negative predictive value for vascular involvement was high (88%) but with a poor positive predictive value of 42.4%. On univariable analysis ([table 5](#)), stent status, sex, age, size of tumour, year of procedure and interval between EUS and surgery were not associated with accuracy of staging. This did not change on multivariable analysis.

Of the 20 patients who underwent VRR, 10 had histological evidence of invasion of the media. Diagnostic performance of EUS for histological vessel wall involvement is detailed in [table 3](#). Sensitivity was good (80%) and negative predictive value was very good (96%). On univariable analysis, stent status, sex, age, size of tumour, year of procedure and interval between EUS and surgery were not associated with an effect on staging ([table 6](#)). However, on multivariable analysis, tumour size OR 0.53 (95% CI 0.30 to 0.95) and year OR 1.26 (95% CI 1.01 to 1.59) were associated with effect on staging, indicating reduced accuracy with increasing tumour size and improved accuracy with the passage of time during the study.

Table 2 Baseline characteristics according to stent status

Characteristic	All, n=90	No stent, n=41	Plastic stent, n=36	SEMS, n=13	P value
Median age, years (IQR)	68 (60–74)	68 (59–73)	67 (59–73)	73 (64–75)	0.26
Male gender, n (%)	50 (56%)	20 (49%)	24 (67%)	6 (46%)	0.22
Median size tumour, mm (IQR)	26 (20–31)	28 (23–36)	25 (20–30)	28 (18–32)	0.11
PDAC, n (%)	75 (83%)	34 (81%)	32 (89%)	9 (69%)	0.26
Vascular resection, n (%)	20 (23%)	10 (24%)	10 (28%)	0	0.09
Interval between EUS and surgery, mean days (SD)	32 (14.3)	33 (13.2)	31 (15.9)	31 (13.9)	0.84
EUS staging successfully performed, n (%)	83 (92.2%)	41 (100%)	35 (97.2%)	7 (53.8%)	<0.0001

EUS, endoscopic ultrasound; PDAC, pancreatic ductal adenocarcinoma; SEMS, self-expanding metal stent.

Table 3 Correlation of EUS assessment with surgical outcome, resection margins and vessel wall invasion

EUS assessment	Surgical outcome				NCCN staging accuracy, %	Proportion resected, n (%)	R0, n (%)	Resected vessel invaded, n (%)
	Stent status, n (%)	PDD, n	PDD+VRR, n	Unresectable, n				
Resectable (n=50)	No stent, 25 (50%)	22	3	0	22/25 (88%)	25/25 (100%)	8/25 (32%)	1/3 (33%)
	PS, 19 (38%)	16	3	0	16/19 (84%)	19/19 (100%)	6/19 (32%)	1/3 (33%)
	SEMS, 6 (10%)	6	0	0	6/6 (100%)	6/6 (100%)	3/6 (50%)	
Total		44	6	0	44/50 (88%)	50/50 (100%)	17/50 (34%)	2/6 (33%)
Borderline (n=30)	No stent, 15 (50%)	9	6	0	6/15 (40%)	15/15 (100%)	6/15 (40%)	4/6 (67%)
	PS, 14 (47%)	7	6	1	6/14 (43%)	13/14 (93%)	3/14 (21%)	3/6 (50%)
	SEMS, 1 (3%)	1	0	0		1/1 (100%)	0	
Total		17	12	1	13/30 (43%)	29/30 (97%)	9/29 (31%)	7/12 (58%)
Unresectable (n=3)	No stent, 1 (33%)	0	1	0	0%	1/1 (100%)	0	0
	PS, 2 (67%)	0	1	1	1/2 (50%)	1/2 (50%)	0	1/1 (100%)
	SEMS, 0 (0%)	0	0	0				
Total		0	2	1	1/3 (33%)	2/3 (67%)	0	1/2 (50%)
Unable to assess (n=7)	No stent, 0 (0%)							
	PS, 1 (14%)	1	0	0		1/1 (100%)	0	
	SEMS, 6 (86%)	6	0	0		6/6 (100%)	4/6 (67%)	
Total		7	0	0		7/7 (100%)	4/7 (57%)	

EUS, endoscopic ultrasound; NCCN, National Comprehensive Cancer Network; PDD, pancreaticoduodenectomy; PS, plastic stent; SEMS, self-expanding metal stent; VRR, venous resection and reconstruction.

Of the 81 patients successfully staged and undergoing resection, R0 resection was achieved in 30 (34.1%). The diagnostic performance of EUS for involved margin (R1) resection is detailed in table 4. Overall diagnostic performance was poor with sensitivity of 40% and negative predictive value (NPV) of 34%. There was no association on univariable or multivariable analysis.

DISCUSSION

In the present study, 54% of patients undergoing pancreaticoduodenectomy for suspected PC had an indwelling biliary stent and EUS staging was significantly less likely to be possible when a SEMS was present (54%) compared with plastic (97%) or no stent (100%). When EUS staging

was successfully performed, the presence of a stent, whether plastic or SEMS, did not adversely affect staging performance although the number of SEMS was low. The overall accuracy of classification of resectability was 70%. Categorisation as resectable was significantly more accurate (88%) than categorisation as borderline resectable or unresectable (42%).

CT scan is the recommended baseline test for diagnosis and staging^{17 18} of suspected PC. The role of EUS currently is primarily for tissue sampling but has a role if a mass is not detected^{18 19} or when vascular involvement is equivocal on CT scan;^{20 21} therefore, its diagnostic performance and any factors that might impair this are important to know. In a previous, study we demonstrated

Table 4 EUS diagnostic performance: surgical reference vascular involvement, histological reference vascular involvement and positive resection margin

Criterion	Sensitivity, % (95% CI)	Specificity, % (95% CI)	Accuracy, % (95% CI)	PPV, % (95% CI)	NPV, % (95% CI)
Surgery (n=83)	70.0 (45.7 to 88.1)	69.8 (56.9 to 80.7)	69.9 (58.8 to 79.5)	42.4 (31.5 to 54.1)	88.0 (78.4 to 93.6)
Histological vessel wall involvement (n=81)	80.0 (44.4 to 97.4)	67.6 (55.4 to 78.2)	69.1 (57.9 to 78.9)	25.8 (18.0 to 35.4)	96.0 (87.3 to 98.8)
R1 resection (n=81)	40.0 (27.0 to 54.1)	65.4 (44.3 to 82.8)	48.2 (36.9 to 59.5)	70.9 (56.8 to 81.9)	34.0 (26.5 to 42.3)

Surgical margin <1 mm.

EUS, endoscopic ultrasound; NPV, negative predictive value; PPV, positive predictive value.

Table 5 Factors associated with correct EUS staging using univariable analysis

Variable	Category	Correct, n/N (%)	OR (95% CI)	P value
Age	–	–	1.04 (0.99 to 1.09)	0.10
Gender	Male	34/45 (75.6%)	1	0.22
	Female	24/38 (63.1%)	0.55 (0.21 to 1.42)	
Time (years)	–	–	1.12 (0.92 to 1.37)	0.26
Stent type	No stent	28/41 (68.3%)	1	0.59
	Metal	6/7 (85.6%)	2.78 (0.3 to 25.5)	
	Plastic	24/35 (69%.0)	1.01 (0.38 to 2.67)	
Tumour size (mm)*	–	–	0.65 (0.39 to 1.08)	0.09
EUS to surgery (days)	–	–	1.00 (0.96 to 1.03)	0.95

*OR given for a 10-unit increase in predictor variable.
EUS, endoscopic ultrasound.

that SEMs use had a negative impact on tissue diagnosis in pancreatic head masses²²

The literature on EUS staging in PC is extensive. A meta-analysis of 20 studies and 726 cases of PC showed that EUS for T1–T2 staging has a sensitivity and specificity of 0.72 and 0.90, respectively. Sensitivity and specificity for T3–T4 staging were 0.90 and 0.72, respectively.²³ Another meta-analysis²⁴ of 29 studies and 1330 patients reported sensitivity of 85% and specificity of 91% for vascular invasion and sensitivity and specificity for resectability of 90% and 86%, respectively. A systematic review by Yang *et al* reported pooled sensitivity and specificity of 72% and 89% for vascular invasion.² However, many of the included studies in these systematic reviews and meta-analysis were from an era when tumours were staged simply as resectable or unresectable and EUS assessment of vascular involvement did not attempt to discriminate between borderline resectable, resectable and locally advanced. Additionally, few studies have addressed the issue of true vascular invasion as opposed to inflammatory adherence. A small study by Aslanian *et al*²⁵ that did assess histological evidence of venous invasion reported sensitivity of 50% and NPV of 82%. A more recent study by Clanton *et al*²⁶

investigated diagnostic performance of EUS for histological venous invasion and <1 mm resection margin. They reported poor sensitivity for both venous invasion 14.3% and resection margin 18%, respectively, in a cohort of patients similar to our study who had upfront resection. Interestingly, after NAT sensitivity was 87% and 81%, respectively. Patients in the NAT group had a significantly lower T stage of tumour and they hypothesised that the improvement occurred because of downstaging with reduction in size and reduction in peritumoural inflammation. Following NAT, CT staging is more difficult and less accurate as standard CT criteria for predicting vascular invasion, based on the amount of tumour-vessel contact, are no longer valid.²⁷ In the present study, patients did not undergo repeat EUS after NAT and were therefore excluded from analysis, the results of the study by Clanton *et al*²⁶ however support further investigation of the role of post NAT EUS staging.

In our study, tumour size OR 0.53 (95% CI 0.30 to 0.95) was found to be inversely related to accuracy of staging suggesting that with increase in tumour size the vascular relationship becomes more difficult to assess.

Table 6 Factors associated with correct assessment of histological vascular involvement using univariable analysis

Variable	Category	Correct, n/N (%)	OR (95% CI)	P value
Age	–	–	1.04 (0.99 to 1.09)	0.10
Gender	Male	33/43 (76.7%)	1	0.11
	Female	23/38 (60.5%)	0.46 (0.18 to 1.21)	
Time (years)	–	–	1.20 (0.98 to 1.48)	0.07
Stent type	No stent	28/41 (68.3%)	1	0.56
	Metal	6/7 (85.6%)	2.78 (0.3 to 25.5)	
	Plastic	22/33 (66.7%)	0.93 (0.34 to 2.46)	
Tumour size (mm)*	–	–	0.67 (0.40 to 1.10)	0.11
EUS to surgery (days)	–	–	1.01 (0.98 to 1.05)	0.24

*OR given for a 10-unit increase in predictor variable.
EUS, endoscopic ultrasound.

We also found that progression of time as measured by year of procedure was associated with an improvement in staging performance this likely reflects several factors including increasing experience and improvements in EUS technology.

Endoscopic retrograde cholangiopancreatography (ERCP) is often performed at an early stage during the management of patients with biliary obstruction and a head of pancreas mass. EUS expertise is not widely available²⁸ in contrast to ERCP and therefore EUS assessment often occurs after biliary drainage. Few studies to date have addressed the specific issue of whether the presence and/or nature of a biliary stent has a deleterious effect on EUS vascular staging. An early study by Cannon *et al* restricted to ampullary tumours and using radial EUS reported a non-statistically significant reduction in accuracy of T staging from 84% to 72% in patients with plastic stents.²⁹ Fusaroli *et al* investigated the impact of plastic stents on mechanical radial EUS staging of suspected PC in 65 patients, 19 of whom had a stent and found a significant impact on T staging accuracy, 47% versus 85%.¹⁴ The impact was primarily in down classification of the actual T stage. The authors postulated that acoustic reverberation and shadowing due to the biliary stents impaired the EUS recognition of the outer margin of the tumour, making it more difficult to assess invasion into the SMA. A subsequent study by Shami *et al* among patients with and without SEMs (28 and 27, respectively) using linear echoendoscopes reported no impact of SEMs on overall staging accuracy, SEMs 46% versus no-SEMs 52%. However, in this study, only 65% of patients underwent surgery and the main reason for inaccurate staging was failure to identify metastatic disease.¹⁵ Bao *et al*¹³ investigated the ability of linear EUS and CT scan to predict a margin negative (R0) resection and the need for venous resection in patients undergoing pancreaticoduodenectomy. In this study of 76 patients, 47 (62%) were resectable at surgery with 17 (22%) undergoing vascular reconstruction. When all cases were analysed, vascular involvement on EUS had a sensitivity of 57% in determining positive resection margin or locally advanced and unresectable disease at resection. In the 27 patients without a stent, sensitivity was significantly better at 79%. The authors postulated that biliary stenting potentially diminishes EUS accuracy by contributing to local inflammation and adenopathy. The nature of the stents as plastic or SEMs was not specified. The study reported an impressive R0 resection rate of 70% but did not describe the histological methodology used. Global consensus is lacking on the definitions of R0 and R1 resection margin status and the definition requiring a free margin of 1 mm or more (as used in the present study) is not universally in use.⁶ As a consequence owing to different definitions for R0 versus R1 margin status, the reported rates of R0 resections in PDAC vary between 15% and 83%.³⁰ For PDAC, it is now generally accepted that standardised, rigorous histological examination of the resection specimen results in much higher incomplete resection rates and

exceed 80% when using R1<1 mm.³¹ In the present study, R0 resection was achieved in 37%. Due to the aforementioned variation in defining an R0 resection, it is difficult to directly compare our result with previous studies.

Additionally, while most tumours in the present study were PDAC, there were a small number of ampullary and bile duct carcinomas, the R0 rate for ampullary carcinomas and bile duct carcinomas tends to be higher. EUS performed poorly in margin involvement. However, intuitively it is not surprising that EUS is not predictive of surgical margin achieved as this is an outcome with many contributing factors. PDAC is characterised by highly infiltrative and discontinuous growth that is often only visible microscopically and not even at detailed macroscopic assessment of the resection specimen.

In our study, staging assessment could not be made in 6 of the 14 patients with a SEMs and 1 of the 36 patients with a plastic stent. However, where staging could be performed, the presence of a stent did not influence staging accuracy, assessment of histological vascular invasion or resection margins. Only a minority of patients presenting with PC are suitable for surgical resection with a reported resection rate of 9.8% in England.³² Ensuring the highest quality staging and thus selection for surgery is critical. Inaccurate staging has a significant impact with overstaged individuals being denied potentially curative surgery, while understaged individuals will undergo futile surgery.

This study has a number of strengths which include the restriction to patients who underwent surgery and the inclusion of variables that could potentially affect staging performance in multivariable analysis. A potentially significant limitation of the study is its retrospective design with the possibility of selection bias as regards which patients were undergoing EUS staging. However, we believe this is mitigated by the fact that as per unit policy, all procedures were categorised as for staging unless explicitly stated in the report that staging was not required and the procedure was solely for tissue sampling. Additional limitations include the small number of patients in the metal stent group, exclusion of a significant proportion of patients because of long interval to surgery, the use of NAT chemotherapy without repeat EUS prior to surgery and reflecting normal clinical practice endosonographers who were not blinded to the results of any prior imaging.

In summary, the presence of a biliary metal stent prevented EUS staging in a significant proportion of patients with pancreaticobiliary malignancies. Measured against borderline resectability criteria, EUS demonstrated modest sensitivity in line with values previously reported for dichotomous assessment of vascular invasion or not and very good NPV. Diagnostic performance for histological vessel wall involvement was good, while EUS showed poor performance for predicting resection margins.

The finding that metal biliary stents impair EUS staging requires confirmation in prospective studies. In conclusion, EUS has value in vascular staging of

pancreaticobiliary malignancies but should preferably be performed before placement of a SEMS.

Author affiliations

¹HPB Unit, Freeman Hospital, Newcastle upon Tyne, UK

²Translational and Clinical Research Institute, Newcastle University, Newcastle upon Tyne, UK

³Gastroenterology, Oxford University Hospitals NHS Foundation Trust, Oxford, UK

⁴Department of Cellular Pathology, Newcastle upon Tyne Hospitals NHS Foundation Trust, Royal Victoria Infirmary, Newcastle upon Tyne, UK

⁵Department of Surgery, Newcastle upon Tyne Hospitals NHS Foundation Trust, Freeman Hospital, Newcastle upon Tyne, UK

⁶Population Health Sciences Institute, Newcastle University, Newcastle upon Tyne, UK

Contributors KWO: conception and design; collation, analysis and interpretation of the data; drafting of the article; critical revision of the article for important intellectual content, final approval and guarantor of the article. NLHB, MKN, JSL and PM: collation and interpretation of the data, drafting of the article; critical revision of the article for important intellectual content and final approval of the article. BH, AD, RC, DMM, JJF, GS, SP and SW: critical revision of the article for important intellectual content and final approval of the article

Funding The authors have not declared a specific grant for this research from any funding agency in the public, commercial or not-for-profit sectors.

Competing interests None declared.

Patient consent for publication Not applicable.

Ethics approval This study involves human participants. As per UK National Health Service research ethics guidance, ethical approval from an institutional review body was not required for this study. Institutional authorisation to hold a prospective patient database for use for service evaluation was obtained. As mentioned above, the study was a retrospective study that was performed as a service evaluation of routine clinical practice. Written informed consent was obtained from all patients prior to the procedure.

Provenance and peer review Not commissioned; externally peer reviewed.

Data availability statement All data relevant to the study are included in the article or uploaded as supplementary information.

Open access This is an open access article distributed in accordance with the Creative Commons Attribution Non Commercial (CC BY-NC 4.0) license, which permits others to distribute, remix, adapt, build upon this work non-commercially, and license their derivative works on different terms, provided the original work is properly cited, appropriate credit is given, any changes made indicated, and the use is non-commercial. See: <http://creativecommons.org/licenses/by-nc/4.0/>.

ORCID iDs

Kofi W Opong <http://orcid.org/0000-0002-7381-7412>

Manu K Nayar <http://orcid.org/0000-0002-1196-3406>

John S Leeds <http://orcid.org/0000-0002-5140-6225>

REFERENCES

- O'Reilly D, Fou L, Hasler E, *et al*. Diagnosis and management of pancreatic cancer in adults: a summary of guidelines from the UK National Institute for health and care excellence. *Pancreatol* 2018;18:962–70.
- Yang R, Lu M, Qian X, *et al*. Diagnostic accuracy of EUS and CT of vascular invasion in pancreatic cancer: a systematic review. *J Cancer Res Clin Oncol* 2014;140:2077–86.
- Navez J, Bouchart C, Lorenzo D, *et al*. What should guide the performance of venous resection during pancreaticoduodenectomy for pancreatic ductal adenocarcinoma with venous contact? *Ann Surg Oncol* 2021;28:6211–22.
- Tempero MA, Malafa MP, Chiorean EG, *et al*. Pancreatic adenocarcinoma, version 1.2019. *J Natl Compr Canc Netw* 2019;17:202–10.
- Tempero MA, Arnoletti JP, Behrman S, *et al*. Pancreatic adenocarcinoma. *J Natl Compr Canc Netw* 2010;8:972–1017.
- Strobel O, Hank T, Hinz U, *et al*. Pancreatic cancer surgery. *Ann Surg* 2017;265:565–73.
- Campbell F, Cairns A, Duthie AFR. Dataset for the histopathological reporting of carcinomas of the pancreas, ampulla of Vater and common bile duct, 2019. Available: <https://www.rcpath.org/uploads/assets/34910231-c106-4629-a2de9e9ae6f87ac1/G091-Dataset-for-histopathological-reporting-of-carcinomas-of-the-pancreas-ampulla-of-Vater-and-common-bile-duct.pdf>
- Fukuda S, Oussoultzoglou E, Bachellier P, *et al*. Significance of the depth of portal vein wall invasion after curative resection for pancreatic adenocarcinoma. *Arch Surg* 2007;142:172–9.
- Ratnayake CBB, Shah N, Loveday B, *et al*. The impact of the depth of venous invasion on survival following pancreaticoduodenectomy for pancreatic cancer: a meta-analysis of available evidence. *J Gastrointest Cancer* 2020;51:379–86.
- Moss AC, Morris E, Mac Mathuna P. Palliative biliary stents for obstructing pancreatic carcinoma. *Cochrane Database Syst Rev* 2006:CD004200.
- Tol JAMG, van Hooft JE, Timmer R, *et al*. Metal or plastic stents for preoperative biliary drainage in resectable pancreatic cancer. *Gut* 2016;65:1981–7.
- Almadi MA, Barkun A, Martel M. Plastic vs. Self-Expandable metal stents for palliation in malignant biliary obstruction: a series of meta-analyses. *Am J Gastroenterol* 2017;112:260–73.
- Bao PQ, Johnson JC, Lindsey EH, *et al*. Endoscopic ultrasound and computed tomography predictors of pancreatic cancer resectability. *J Gastrointest Surg* 2008;12:10–16.
- Fusaroli P, Manta R, Fedeli P, *et al*. The influence of endoscopic biliary stents on the accuracy of endoscopic ultrasound for pancreatic head cancer staging. *Endoscopy* 2007;39:813–7.
- Shami VM, Mahajan A, Sundaram V, *et al*. Endoscopic ultrasound staging is adversely affected by placement of a self-expandable metal stent: fact or fiction? *Pancreas* 2008;37:396–8.
- Campbell F, Foulis AK VC. Standards and datasets for reporting cancers dataset for the histopathological reporting of carcinomas of the pancreas, ampulla of Vater and common bile duct may 2010, 2010. Available: https://www.cmcanceralliance.nhs.uk/application/files/1715/4815/6399/dataset_pancreas_may10.pdf
- Lutz MP, Zalcborg JR, Ducreux M, *et al*. 3Rd St. Gallen EORTC gastrointestinal cancer conference: consensus recommendations on controversial issues in the primary treatment of pancreatic cancer. *Eur J Cancer* 2017;79:41–9.
- Tempero MA, Malafa MP, Al-Hawary M, *et al*. Pancreatic adenocarcinoma, version 2.2017, NCCN clinical practice guidelines in oncology. *J Natl Compr Canc Netw* 2017;15:1028–61.
- Cieslak KP, van Santvoort HC, Vleggaar FP, *et al*. The role of routine preoperative EUS when performed after contrast enhanced CT in the diagnostic work-up in patients suspected of pancreatic or periampullary cancer. *Pancreatol* 2014;14:125–30.
- Tellez-Avila FI, Chavez-Tapia NC, López-Arce G, *et al*. Vascular invasion in pancreatic cancer: predictive values for endoscopic ultrasound and computed tomography imaging. *Pancreas* 2012;41:636–8.
- Glazer ES, Rashid OM, Klapman JB, *et al*. Endoscopic ultrasonography complements computed tomography in predicting portal or superior mesenteric vein resection in patients with borderline resectable pancreatic carcinoma. *Pancreatol* 2017;17:130–4.
- Bekkali NLH, Nayar MK, Leeds JS, *et al*. Impact of metal and plastic stents on endoscopic ultrasound-guided aspiration cytology and core histology of head of pancreas masses. *Endoscopy* 2019;51:1044–50.
- Li J-H, He R, Li Y-M, *et al*. Endoscopic ultrasonography for tumor node staging and vascular invasion in pancreatic cancer: a meta-analysis. *Dig Surg* 2014;31:297–305.
- Nawaz H, Fan CY, Kloke J, *et al*. Performance characteristics of endoscopic ultrasound in the staging of pancreatic cancer: a meta-analysis. *JOP* 2013;14:484–97.
- Aslanian H, Salem R, Lee J, *et al*. EUS diagnosis of vascular invasion in pancreatic cancer: surgical and histologic correlates. *Am J Gastroenterol* 2005;100:1381–5.
- Clanton J, Oh S, Kaplan SJ, *et al*. Does mesenteric venous imaging assessment accurately predict pathologic invasion in localized pancreatic ductal adenocarcinoma? *HPB* 2018;20:925–31.
- Zins M, Matos C, Cassinotto C. Pancreatic adenocarcinoma staging in the era of preoperative chemotherapy and radiation therapy. *Radiology* 2018;287:374–90.
- Kalaitzakis E, Panos M, Sadik R, *et al*. Clinicians' attitudes towards endoscopic ultrasound: a survey of four European countries. *Scand J Gastroenterol* 2009;44:100–7.
- Cannon ME, Carpenter SL, Elta GH, *et al*. EUS compared with CT, magnetic resonance imaging, and angiography and the influence of biliary stenting on staging accuracy of ampullary neoplasms. *Gastrointest Endosc* 1999;50:27–33.



- 30 Chandrasegaram MD, Goldstein D, Simes J, *et al*. Meta-Analysis of radical resection rates and margin assessment in pancreatic cancer. *Br J Surg* 2015;102:1459–72.
- 31 Pine JK, Haugk B, Robinson SM, *et al*. Prospective assessment of resection margin status following pancreaticoduodenectomy for pancreatic ductal adenocarcinoma after standardisation of margin definitions. *Pancreatology* 2020;20:537–44.
- 32 Cancer Research UK. Pancreatic cancer diagnosis and treatment statistics. Available: <http://www.cancerresearchuk.org/health-professional/cancer-statistics/statistics-by-cancer-type/pancreatic-cancer/diagnosis-and-treatment#heading-Two> [Accessed 14 Oct 2017].