

## The Prevalence of Lower Eyelid Fornix Fat Prolapse: A Diagnostic Measure of Involutional Entropion

Varajini Joganathan<sup>1</sup>, FRCOphth, FEBO; Chandrashekhara Rai<sup>1</sup>, MS, FRCS  
Mohamed Farag Khalil Ibrahim<sup>2</sup>, FRCS; Bijan Beigi<sup>1</sup>, FRCOphth

<sup>1</sup>Norfolk and Norwich University Hospitals NHS Trust, Colney Lane, Norwich, NR4 7UY, United Kingdom

<sup>2</sup>Department of Ophthalmology, Oculoplastic Unit, Faculty of Medicine, Minia University, Minya, Egypt

### Abstract

**Purpose:** In our experience, lower lid involutional entropion is commonly associated with inferior fornix fat prolapse and non-eversion of the tarsal plate. We aimed to assess the prevalence of this sign as an early diagnostic indicator of lower lid involutional entropion in symptomatic and control groups.

**Methods:** Prospective, comparative, observational case series. Fornix fat prolapse and failure of tarsal eversion in patients with involutional entropion were studied. Fornix fat prolapse was assessed by pulling the lower lid margin to the inferior orbital rim and comparing the meniscus of the protruding fat. The absence of tarsal eversion and lid laxity were also assessed. Patients were reassessed following correction using radiofrequency entropion surgery.

**Results:** Sixty eyes of 50 Caucasian patients with involutional entropion underwent entropion correction. Fornix fat prolapse was found preoperatively in 83.3% (50 eyes), with complete reversal of fat prolapse in 76% (38 eyes) over a mean follow-up of 18.9 months, after successful surgery ( $P < 0.01$ ). None of the 100 eyes (50 patients) in the control group showed fornix fat prolapse or absence of lower lid tarsal eversion ( $P < 0.01$ ).

**Conclusion:** There is high prevalence of fornix fat prolapse and failure of tarsal eversion (BB sign) in involutional entropion, with reversal after successful eyelid surgery. The absence of fornix fat prolapse in normal controls suggests that this is an important, underlying anatomical etiology, with diagnostic and prognostic value.

**Keywords:** Entropion; Fornix Fat Prolapse; Involutional; Lid Laxity; Tarsal Eversion

*J Ophthalmic Vis Res* 2018; 13 (4): 458-460

### INTRODUCTION

Involutional lower eyelid entropion is attributed to many causes of ageing changes in the lid and

orbit,<sup>[1-3]</sup> resulting in variable degrees of horizontal and vertical lid laxity. Inferior fornix fat prolapse and non-eversion of the inferior tarsal plate have been found consistently and with a high degree of association in our previous study.<sup>[4]</sup> Furthermore, we observed an association of fornix fat prolapse with failure of tarsal eversion.

Eyelid assessments that predominantly test vertical laxity, such as the eyelid excursion test, have not been

#### Correspondence to:

Bijan Beigi, FRCOphth. Norfolk and Norwich University Hospitals NHS Trust, Colney Lane, Norwich, NR4 7UY, United Kingdom.

E-mail: bb@mrbeigi.com

Received: 03-08-2017

Accepted: 24-01-2018

This is an open access journal, and articles are distributed under the terms of the Creative Commons Attribution-NonCommercial-ShareAlike 4.0 License, which allows others to remix, tweak, and build upon the work non-commercially, as long as appropriate credit is given and the new creations are licensed under the identical terms.

For reprints contact: reprints@medknow.com

**How to cite this article:** Joganathan V, Rai C, Ibrahim MF, Beigi B. The prevalence of lower eyelid fornix fat prolapse: A diagnostic measure of involutional entropion. *J Ophthalmic Vis Res* 2018;13:458-60.

#### Access this article online

Quick Response Code:



Website:  
www.jovr.org

DOI:  
10.4103/jovr.jovr\_164\_17

found to be specific in determining underactivity of lower lid retractors and hence the likelihood of developing involutional entropion.<sup>[5]</sup>

Horizontal lid laxity is reportedly an important factor in the etiology of involutional entropion; however, its prominence is variable among those with involutional entropion.<sup>[6]</sup>

We hypothesized that fornix fat prolapse is accompanied by tarsal non-eversion (BB Sign) and would be an early diagnostic indicator of lower lid involutional entropion. We set out to assess its relevance by studying the incidence of fornix fat prolapse in patients with involutional entropion before and after entropion surgery, and to compare these findings in patients with normal eyelids.

## METHODS

Fifty-eight consecutive patients with involutional entropion, who were listed for radiofrequency entropion surgery over a 5-year period, were prospectively studied. An age- and sex-matched control group was enrolled for the same study.

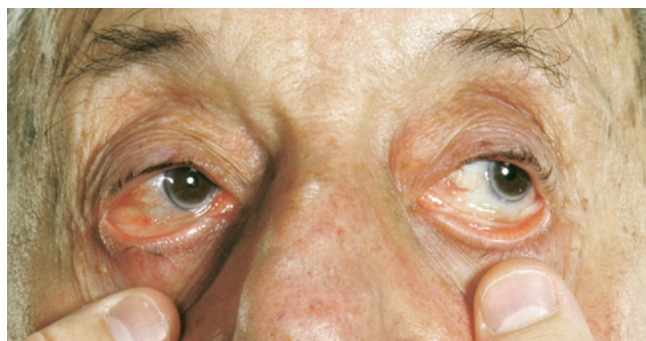
Patients with other causes of entropion, intermittent entropion, ocular trauma, and previous ocular adnexal surgery were excluded.

Radiofrequency wave therapy is a novel technique introduced in our department that allows strengthening of the lower border of the tarsus by causing fibrosis of tissues. Treatment is carried out using a radiofrequency probe. The electrode is introduced subcutaneously through 3 small incision sites to the lower border of the tarsus. The tissue is cut and coagulated deep under the skin to fuse the anterior and posterior lamellae of the lower eyelid. Attempt is made to avoid causing a superficial skin burn. (This procedure is being reported separately.)

Fornix fat prolapse was assessed by pulling the lower lid margin to the level of the inferior orbital rim without any pressure on the globe, and comparing the meniscus of the protruding fat in each fornix while observing for tarsal eversion. Lower fornix fat pad height (FFH) <2 mm was considered grade 1 and FFH  $\geq$ 2 mm was grade 2 [Figure 1]. Particular effort was made to avoid pressure on the globe during this examination and to cause fornix fat to prolapse. Simultaneous lower lid tarsal eversion was recorded.

Grading was conducted by 3 members of the Ocular Adnexal Unit (Consultant and Fellows). The test was repeated 3 times before assessment conclusion. (In relevant cases, this was repeated at 1 month, 6 months, 1 year, and 2 years following surgery).

Data were analyzed using the Chi-square test to compare the grades of BB sign between lids with involutional entropion and those of normal controls.



**Figure 1.** A patient with right entropion. Pulling the lower lid margin to the level of the inferior orbital rim and comparing the meniscus of the protruding fat in each fornix. Grade 2 (>2mm) in the right lower eye lid is demonstrated. Note the non-eversion of the right tarsal plate relative to the everted position in the left eye.

## RESULTS

Sixty eyes of 28 female and 30 male Caucasians, mean age of 81.1 years (range, 62-99 years), with involutional entropion were assessed.

Fifty-six patients had unilateral entropion and 2 had bilateral entropion correction. All patients showed inversion of the eyelid on the affected side after instillation of topical anesthetic drops.

A total of 83.3% (50 eyes) were found to have fornix fat prolapse and failure of tarsal eversion preoperatively (29% grade 1, 71% grade 2 fornix fat prolapse). After successful surgery, there was complete reversal of fat prolapse and normal tarsal eversion in 76% (38 eyes), over a mean follow-up of 18.9 months [Table 1]. All patients with fornix fat prolapse showed absence of tarsal eversion ( $P < 0.01$ ). None of the patients in this cohort required repeat treatment for recurrence of entropion and no complications were noted.

In the 56 patients with unilateral entropion, 22% of the fellow eyes showed increased FFH. Grade 1 was predominantly observed in these cases on the non-entropic side compared with predominantly Grade 2 in the entropic side [Table 2].

None of the 100 eyes (50 patients, 31 females and 19 male Caucasians with mean age of 73.4 years) in the age-matched control group showed a BB sign ( $P < 0.01$ ).

## DISCUSSION

Our study showed a high prevalence of fornix fat prolapse and lower lid tarsus non-eversion in involutional lower lid entropion, with significant reversal of the sign after successful eyelid surgery. The occasional small degree of fornix fat prolapse in the non-entropic, fellow eye could be explained by bilateral ageing and early signs of entropion development in the fellow eye.

**Table 1. Comparison of fornix fat prolapse, pre- and post-operatively (postoperative mean follow-up of 18.9 months)**

Clinical findings	Preoperative FFP	Postoperative FFP
Fornix fat prolapse (FFP)	83.3% (50/60)	24.1% (12/50)
Fornix fat height (FFH)		
Grade 1	29% (14/50)	83% (10/12)
Grade 2	71% (36/50)	17% (2/12)
P	<0.001	<0.001

FFP, fornix fat prolapse; FFH, fornix fat height

**Table 2. Comparison of different grades of fornix fat height in 56 unilateral lower eye lid entropion cases**

Clinical findings	Entropic eye	Nonentropic fellow eye
FFP	89.3% (50/56)	19.6% (11/56)
Tarsal noneversion	92.9% (52/56)	3.57% (2/56)
FFH		
Grade 1	30.0% (15/50)	72.7% (8/11)
Grade 2	70.0% (35/50)	27.3% (3/11)
P	<0.001	<0.001

FFP, fornix fat prolapse; FFH, fornix fat height

We did not observe fornix fat prolapse in 10 patients with involutional entropion. These patients showed remarkable non-inversion of the tarsal plate and fat atrophy. We postulate significant periocular fat atrophy and retractor dehiscence to be the predominant factors causing involutional entropion in this cohort of patients. As a result, the tarsal position when the eyelid is pulled down is more significant.

Our finding of the absence of this sign in normal controls suggests this to be an important, underlying anatomical etiology, with diagnostic and prognostic value pre-and postoperatively, when evaluating patients with involutional entropion.

We previously described fornix fat prolapse as a measure or sign of involutional entropion.<sup>[4]</sup> However, we noted the association of tarsal position and called it the BB sign. We report a strong association of the BB sign with involutional entropion.

Our previous observation of unilateral entropion showed the BB sign as the only significant difference between the eye with entropion and the normal side. We have found this sign useful in diagnosis of involutional entropion, especially in patients without manifest symptoms at presentation. Furthermore, we have used this as a tool to assess the outcome of surgery and as evidence of future recurrence.

In summary, our findings demonstrate the significant usefulness of fornix fat prolapse and failure of tarsal eversion in assessing patients with established involutional entropion as well as those who present with early ageing changes leading to involutional entropion. We proposed a diagnostic sign with prognostic value. Our findings probably represent the outcome of lower lid retractor dehiscence supporting the lower border of the tarsus and lower fornix.

### Financial support and sponsorship

Nil.

### Conflicts of interest

There are no conflicts of interest.

### REFERENCES

1. Beigi B, Loaan P, Eustace P, Farrell M. Clinical research: Ragged-red fibres in orbicularis oculi muscle and their significance. *Orbit* 1993;13:113-117.
2. Bashour M, Harvey J. Causes of involutional ectropion and entropion – Age-related tarsal changes are the key. *Ophthalmic Plast Reconstr Surg* 2000;16:131-141.
3. Marshall JA, Valenzuela AA, Strutton GM, Sullivan TJ. Anterior lamella actinic changes as a factor in involutional eyelid malposition. *Ophthalmic Plast Reconstr Surg* 2006;22:192-194.
4. Beigi B, Kashkouli MB, Shaw A, Murthy R. Fornix fat prolapse as a sign for involutional entropion. *Ophthalmology* 2008;115:1608-1612.
5. Wright M, Bell D, Scott C, Leatherbarrow B. Everting suture correction of lower lid involutional entropion. *Br J Ophthalmol* 1999;83:1060-1063.
6. Nowinski TS. Orbicularis oculi muscle extirpation in a combined procedure for involutional entropion. *Ophthalmology* 1991;98:1250-1256.