

3D surgical planning including patient-specific drilling guides for tibial plateau fractures

a prospective feasibility study

Cite this article:

Bone Jt Open 2024;5(1):
46–52.

DOI: 10.1302/2633-1462.
51.BJO-2023-0130.R1

Correspondence should be
sent to N. Assink [n.assink@
umcg.nl](mailto:n.assink@umcg.nl)

N. Assink,^{1,2} K. ten Duis,¹ J. P. M. de Vries,³ M. J. H. Witjes,² J. Kraeima,² J. N. Doornberg,^{1,4} F. A. A. IJpma¹

¹Department of Trauma Surgery, University of Groningen, University Medical Center Groningen, Groningen, Netherlands

²3D Lab, University of Groningen, University Medical Center Groningen, Groningen, Netherlands

³Department of Surgery, University Medical Center Groningen, Groningen, Netherlands

⁴Flinders University, Adelaide, Australia

Aims

Proper preoperative planning benefits fracture reduction, fixation, and stability in tibial plateau fracture surgery. We developed and clinically implemented a novel workflow for 3D surgical planning including patient-specific drilling guides in tibial plateau fracture surgery.

Methods

A prospective feasibility study was performed in which consecutive tibial plateau fracture patients were treated with 3D surgical planning, including patient-specific drilling guides applied to standard off-the-shelf plates. A postoperative CT scan was obtained to assess whether the screw directions, screw lengths, and plate position were performed according to the preoperative planning. Quality of the fracture reduction was assessed by measuring residual intra-articular incongruence (maximum gap and step-off) and compared to a historical matched control group.

Results

A total of 15 patients were treated with 3D surgical planning in which 83 screws were placed by using drilling guides. The median deviation of the achieved screw trajectory from the planned trajectory was 3.4° (interquartile range (IQR) 2.5 to 5.4) and the difference in entry points (i.e. plate position) was 3.0 mm (IQR 2.0 to 5.5) compared to the 3D preoperative planning. The length of 72 screws (86.7%) were according to the planning. Compared to the historical cohort, 3D-guided surgery showed an improved surgical reduction in terms of median gap (3.1 vs 4.7 mm; $p = 0.126$) and step-off (2.9 vs 4.0 mm; $p = 0.026$).

Conclusion

The use of 3D surgical planning including drilling guides was feasible, and facilitated accurate screw directions, screw lengths, and plate positioning. Moreover, the personalized approach improved fracture reduction as compared to a historical cohort.

Take home message

- This study is among the first clinical studies to evaluate the application of 3D-printed surgical drilling guides in combination with conventional plates in tibial plateau fracture surgery.
- The use of 3D surgical planning including drilling guides during the operation was

feasible, and facilitated accurate screw directions, screw lengths, and plate positioning according to the preoperative 3D surgical planning.

Introduction

Tibial plateau fractures are among the most challenging fractures to treat. Surgical treatment of these fractures usually consists of open reduction and internal fixation using plates and screws.^{1,2} Ideal plate positioning and screw trajectories benefit fracture fixation and stability of the construct.³ The introduction of anatomical shaped variable angle-locking compression plates (VA-LCPs) enables variable angle screw trajectories (diverging up to 30°) to ensure adequate fracture fixation and articular support.⁴ With this concept, screw trajectories can be adjusted until these fit patient-specific fracture morphology.⁵ Based on 2D perioperative fluoroscopy, however, it can be hard to determine and verify the optimal screw positions relative to the fracture fragments.

Over the last few years, innovative 3D technologies have been increasingly used for the surgical treatment of tibial plateau fractures.⁶ Virtual or 3D-printed models of a fracture could aid in understanding complex fracture patterns and plan surgical treatment.^{7,8} In addition, surgeries could be virtually preplanned, and surgical guides can be designed to translate a virtual surgical plan to the actual surgical procedure.⁹ Recently, we developed an innovative workflow for the clinical application of 3D-printed drilling guides which envelop conventional 'off-the-shelf' implants to aim the screws in the predetermined directions.⁹ This personalized surgical approach enabled execution of the preoperative plan and helped to attain predetermined osteosynthesis plate and screw positions. In this study, our concept of surgical guides will be applied in combination with VA-LCP proximal tibia plates, potentially ensuring optimal screw placement.

We hypothesized that 3D virtual surgical planning in combination with 3D-printed surgical guides facilitates optimal screw directions and improved fracture reduction as compared to conventional surgery. The aim of this study is to assess whether 3D-guided surgery can be used to facilitate optimal screw trajectories in tibial plateau fracture surgery. We assessed the feasibility and accuracy of this innovative procedure through a prospective clinical cohort study and compared results with a historical cohort.

Methods

Study design

A prospective feasibility study was performed in which consecutive patients treated surgically for a tibial plateau fracture with an anterolateral VA-LCP plate between January 2021 and April 2023 were included. Patients aged > 18 years with the availability of a CT scan with a slice thickness of < 1 mm were eligible for 3D-assisted treatment. Excluded were patients who had open fractures, pathological fractures, or were treated nonoperatively. The intervention consisted of 3D surgical planning including the design, production, and clinical application of patient-specific drilling guides. A matched historical control group (conventional group) consisted of consecutive patients who were operated with standard VA-LCP plates (i.e. without 3D planning and surgical guides) within the two years before

the introduction of 3D-assisted surgery (2019 to 2020). Written informed consent was obtained from all patients. The University Medical Center Groningen institutional review board approved the study procedures, and the research was performed in accordance with the relevant guidelines and regulations (NL72543.042.20./201900879). Patients did not receive any reimbursement for participation. This study is reported following the STROBE guidelines.¹⁰

Preoperative fracture characteristics

All preoperative CT scans at the time of the injury were assessed by two blinded observers (FFAIJ, NA). The observers consisted of an attending orthopaedic trauma surgeon (> ten years of experience) and technical physician (> five years of experience). CT scans were assessed in the axial, sagittal, and coronal planes to measure the initial displacement in terms of gap and step-off according to previously described methods,^{11,12} and to determine the fracture classification according to the AO/OTA classification system.¹³ Patient characteristics were retrieved from the electronic patient file.

3D surgical planning and guide design (intervention group)

Mimics Medical software (version 23.0; Materialise, Belgium) was used to create a 3D model of the tibial plateau fracture based on the CT data. A segmentation process was performed using a preset bone threshold (Hounsfield Units \geq 226). All fracture fragments were identified and separated to individual masks, by combining both region growing and split mask functions. Subsequently, the fragments were checked and, if needed, manually separated from adjacent fragments. Virtual fracture reduction was performed, in which all fracture fragments were moved back to their anatomical position. This process was supported with the (mirrored) contralateral side or template of a healthy tibia. Together with the treating surgeon, the virtual fracture reduction was verified, and optimal position of the plate and screw trajectories were predetermined. Plate and screw trajectories were digitally positioned within the 3D software.

The drilling guides were designed to perfectly envelop the VA-LCP lateral plates (DePuy Synthes, USA). The drilling guides consisted of multiple cylindrical tubes in which a stainless-steel drill sleeve (316 L, 25 mm in length, with an inner diameter of 2.9 mm for a 2.8 mm drill) could be inserted to guide the drill bit. After the designing process (3-Matic 15.0; Materialise), the guides were 3D-printed by selective laser sintering using polyamide 12 (PA12) and sterilized for usage during the operation. The 3D surgical planning and guide design process is depicted in [Figure 1](#).

3D-assisted surgery

All surgeries were performed by attending orthopaedic trauma surgeons with several years of experience. 3D-assisted surgery included a virtual surgical planning ([Figure 2](#)), including a 3D-printed patient-specific drilling guide. Depending on the fracture characteristics, either an anterolateral approach or a combined two-incision anterolateral and medial approach was performed. In case of bicondylar fractures, the double plating technique was used, in which first the medial plateau was reconstructed and fixated. Then, lateral fragments were reduced and the VA-LCP plate was positioned and screws were placed with

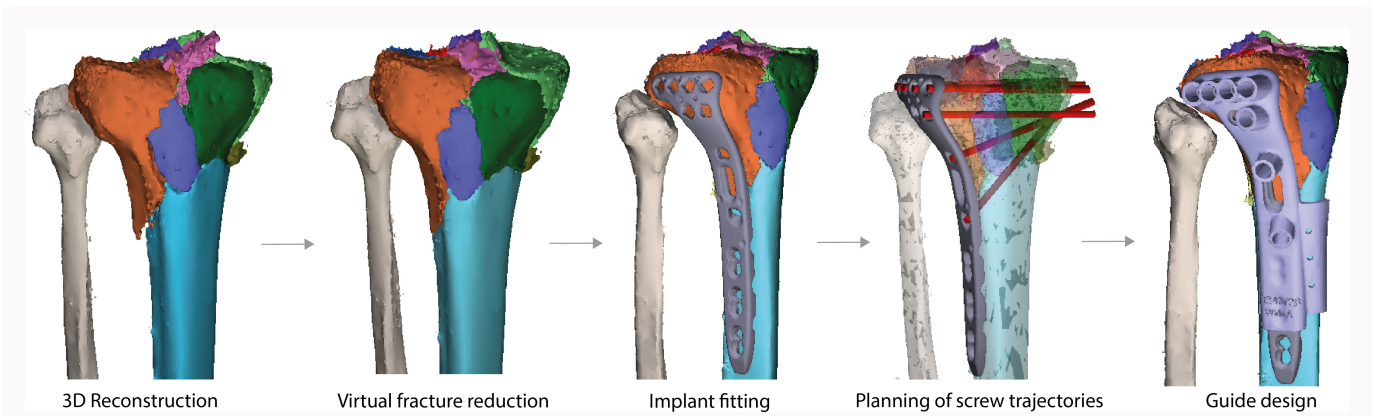


Fig. 1

Process of 3D surgical planning including patient-specific drilling guide design. First, a 3D reconstruction is created from the initial CT scan in which all fragments are identified and assigned a different colour. Then, virtual fracture reduction is performed, after which a plate is digitally fitted and screw trajectories (red bars) are predetermined. Finally, the drilling guide is designed to envelop the variable angle-locking compression plate (VA-LCP) to guide the drill bit and screw in the planned trajectories. To position the plate at the intended location, bone-supporting extensions were added to the design of the guide. The guide is subsequently 3D-printed and used during the operation to convert the virtual plan to the patient.

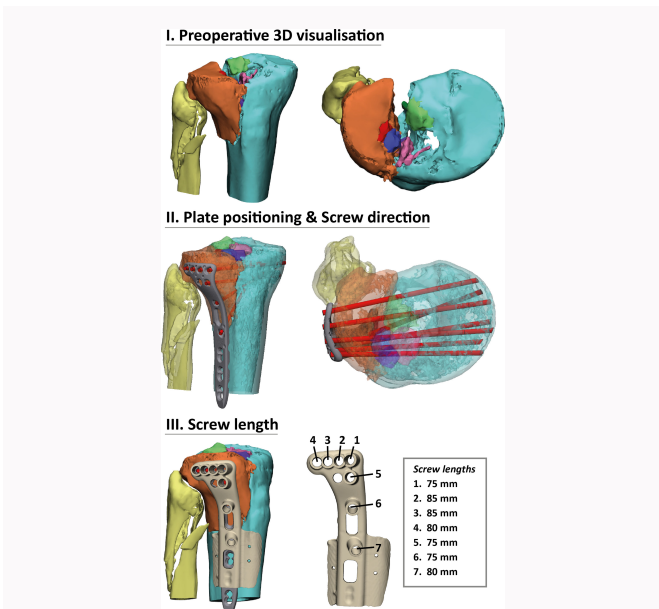


Fig. 2

3D virtual surgical planning including visualization of the fracture (I), visualization of the planned position of the plate and directions of screws (II), and the lengths of the screws (III). A 3D-printed guide that fits on top of the plate (III) is used to translate the preoperative plan (e.g. guiding plate position, screw directions, screw lengths) to the actual operative procedure.

our patient-specific drilling guide (Figure 3). In case of a lateral fracture only, fracture reduction was performed through an anterolateral approach and positioning of the plate, and screws were again executed with the aid of the patient-specific drilling guide. Screw lengths were chosen according to the preoperative planning.

Postoperative assessment of 3D-guided surgery

All patients underwent a postoperative CT scan within two weeks after surgery. The CT data were used to generate a postoperative 3D model of the reconstructed tibial plateau with the implants and screws in situ. In order to assess

the accuracy of the screw placements, the postoperative 3D model of the implant with screws was aligned with the preoperative planning of the position of the implant. The difference between the achieved and obtained screw direction were assessed by measuring the angle between those screw trajectories (Figure 4). The difference between the planned and obtained entry point was determined by measuring the Euclidean distance between these entry points. Quality of the fracture reduction was assessed by measuring the residual intra-articular incongruence (maximum gap and step-off) on the postoperative CT scan in both the 3D-guided group (intervention) and the conventional group (control).

Conventional treatment (control group)

The control group was treated surgically with standard VA-LCP plates without 3D visualization and 3D-printed guides during surgery. Treatment in these patients was according to the standard of care.

Patient demographic data

Between January 2021 and April 2023, a total of 15 patients were treated for their tibial plateau fracture by using our 3D planned method including surgical guides. In addition, results of a control group, consisting of patients treated for similar fractures in the years before introduction of 3D-guided tibial plateau fracture surgery, were evaluated. Table 1 depicts the patient characteristics of both groups. Both groups were quite similar in terms of age, sex, American Society of Anesthesiologists (ASA) grade,¹⁴ and fracture classification.

Quality of fracture reduction

Patients in both the intervention and control group underwent a postoperative CT scan in order to assess quality of the surgical intervention. Fracture reduction was assessed in terms of maximum residual gap and step-off. Assessment was performed independently by two blinded observers, and the average of both measurements for each patient was used for the analysis.

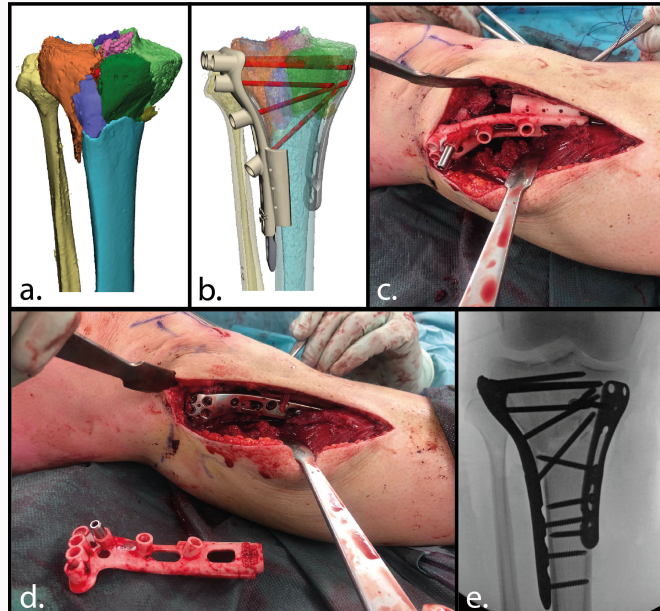


Fig. 3

3D-assisted surgery in case 3. a) Preoperative 3D visualization of the fracture. b) Virtual surgical planning. c) Intraoperative use of the 3D-printed surgical drilling guides. Screw trajectories are drilled through the stainless-steel drill sleeve. d) Osteosynthesis plate after screw placement. e) Fluoroscopic image of the achieved surgical result.

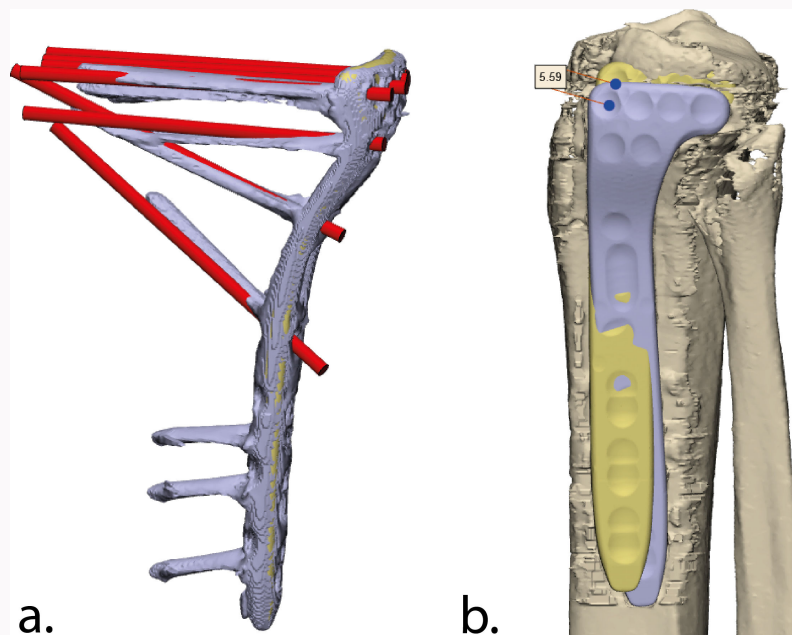


Fig. 4

Postoperative assessment of the accuracy of the screw placement. a) The difference between the achieved (purple) and obtained (red) screw directions were assessed by measuring the angle between those screw trajectories. b) The planned (yellow) and obtained (purple) position of the implant. The difference between the planned and the obtained screw entry points were determined for all screws by measuring the Euclidean distance between these entry points.

Statistical analysis

Statistical analysis was performed using SPSS (version 23; IBM, USA). Continuous variables were presented as mean and standard deviation (SD) for normally distributed data, and median and interquartile range (IQR) if not normally distributed. A p-value of less than 0.05 was considered statistically significant. Descriptive statistics were used to describe the study population. Mann-Whitney U and chi-squared test were

performed to assess differences in baseline characteristics and quality of the reduction between intervention and control group.

Results

Accuracy of guided screw insertion

A total of 83 screws were placed through the guided method. The median deviation of the achieved screw trajectory from

Table I. Patient characteristics.

Characteristic	Intervention (n = 15)	Control (n = 15)	p-value
Median age, yrs (IQR)	55 (44 to 59)	61 (59 to 65)	0.006*
Female, n (%)	10 (66.7)	11 (73.3%)	0.690†
ASA grade, n (%)			0.549†
I	3 (20)	3 (20)	
II	11 (73.3)	9 (60)	
III	1 (6.7)	3 (20)	
AO/OTA classification, n (%)			0.587†
B3	7 (46.7)	7 (46.7)	
C1	1 (6.6)	0 (0)	
C3	7 (46.7)	8 (53.5)	
Median days until surgery (IQR)	10 (8 to 13)	8 (7 to 11)	0.101*

*Mann-Whitney U test.

†Chi-squared test.

ASA, American Society of Anesthesiologists; IQR, interquartile range.

the planned trajectory was 3.4° (2.5° to 5.4°), whereas the median difference between planned and achieved position of the entry point was 3.0 mm (IQR 2.0 to 5.5). In total, for 11 out of 83 screws (13.3%) the actual screw length used was slightly shorter than the originally planned screw length. This occurred because the inserted screws were blocked by the screws placed freehand from the medial plate on the opposite side (Table II; see Supplementary Material 1 for example). Placement of a slightly shorter screw did not result in any clinical consequences.

Fracture reduction

Initial fracture displacement did not show a significant difference between the patients who underwent 3D planned surgery (intervention) and the control group (Table III). 3D planned tibial plateau fracture surgery showed an improved surgical reduction in terms of median gap (3.1 vs 4.7 mm; $p = 0.13$) and step-off (2.9 vs 4.0 mm; $p = 0.03$) compared to the control group.

Discussion

Operative treatment of tibial plateau fractures is usually complex due to fracture comminution, displacement in multiple directions, limited exposure, and soft-tissue injuries. Moreover, achieving optimal plate and screw positions might be challenging, and the achieved position is hard to verify with fluoroscopy. Preoperative planning is crucial to achieve optimal results in tibial plateau fracture surgery: ‘plan your operation, and operate your plan’ is one of the adages in surgery. In this study, we developed and presented the next level of surgical planning in tibial plateau fracture surgery. This is one of the first clinical studies in which we literally plan our operation in 3D, and operate our plan by using 3D-printed drilling guides in combination with regular tibial

Table II. Accuracy of the screw placement.

Parameter	Value
Screws placed, n	83
Median screw angulation, ° (IQR)	3.4 (2.5 to 5.4)
Median screw entry point, mm (IQR)	3.0 (2.0 to 5.5)
Correct screw length, n (%)	72 (86.7)

IQR, interquartile range.

plates. In summary, this personalized approach facilitates accurate screw directions, screw lengths, and plate positioning according to the preoperative 3D surgical planning. Moreover, it improved fracture reduction as compared to a historical cohort.

Over the past years, several innovative 3D technologies have been introduced for the surgical treatment of tibial plateau fractures as described in an extensive review about this topic.⁶ These include two preliminary attempts of 3D-printed screw guides to facilitate guided screw placement.^{15,16} First, Huang et al¹⁵ used 3D-printed templates in six patients to insert several Kirschner (K)-wires, which mark the preferred screw directions. After placing K-wires, this template was removed and a locking plate was placed along the K-wires, which were subsequently exchanged for screws. Although they use the concept of guided surgery, their basic K-wire templates differ substantially from our patient-specific drilling guides. Their preliminary results show a deviation between planned and achieved screw trajectories of 6.34° (SD 3.42°) and 4.68° (SD 3.94°) in the coronal (x-y) and transverse (x-z) plane, respectively. Second, Nie et al¹⁶ used 3D-printed templates to facilitate screw osteosynthesis. These templates were designed to fit the shape of the bone and to guide K-wire placement. After K-wires were removed, screws were inserted and plates were placed alongside the screws. Additionally, this technique differed substantially since they only facilitate ‘out-of-plate’ screw placement. Their method was applied in only four patients, and the achieved accuracy was not assessed. Our method adds to these previous reports, because our surgical guides were designed to envelop the plate as well as guide the position of the implant due to press-fit extensions on the guide. In addition, stainless-steel drill sleeves could be inserted to directly guide the drill bit in contrary to the previous reported methods of drilling K-wires which indirectly guide screw placement. Our technique leads to accurate screw placement with a median deviation of the screw trajectories of only 3.4° (IQR 2.5° to 5.4°) and median deviation of the screw entry point (i.e. plate position) of only 3.0 mm (IQR 2.0 to 5.5). This degree of accuracy is sufficient, since this could be accounted for in the 3D preoperative planning, and the screws did not penetrate the joint. Moreover, this study included both an intervention and historic control group of 15 patients. As compared to this historic cohort, our 3D-guided workflow showed an improved fracture reduction.

Surgeons may wonder how 3D-guided surgery benefits the operative results, and what it takes to implement it in their own hospital. The improved surgical results in the 3D-guided patients could be explained by the detailed preoperative

Table III. Initial fracture displacement and quality of the articular reduction in terms of median gap and step-off in the intervention as compared to the control group. Data are presented as medians and interquartile ranges.

Fracture displacement as measured on CT scans	Intervention (n = 15)	Control (n = 15)	p-value*
Preoperative gap, mm	9.7 (4.9 to 13.2)	7.9 (6.9 to 11.8)	0.713
Preoperative step-off, mm	9.9 (5.6 to 11.9)	6.7 (5.3 to 14.8)	0.744
Postoperative gap, mm	3.1 (1.8 to 4.7)	4.7 (3.0 to 5.4)	0.126
Postoperative step-off, mm	2.9 (1.8 to 3.7)	4.0 (3.3 to 5.0)	0.026

*Mann-Whitney U test.

3D planning in combination with the accurate intraoperative translation of the plan by using a patient-specific drill guide. The positive effects of 3D planning and surgical guides on patients' outcome in orthopaedic trauma care have been previously described.^{7,17} The 3D workflow as described in the current study requires some efforts including segmentation of the bone fragments, virtual fracture reduction, planning of the implants and screws, and finally the design of the surgical guides. Therefore, it requires several multidisciplinary moments in which the (3D) surgical plan is discussed before surgery, potentially leading to an improved understanding of the fracture morphology and treatment strategy. In order to facilitate this 3D workflow, specialized 3D software, technical physicians skilled in the software, and dedicated surgeons are needed. This workflow starts with a 3D segmentation of the fracture, after which the fracture is reduced and a proposal for implant position and screw direction is made (which usually takes 1 to 2 hours). The proposed plan is discussed and altered based on the preferences of the surgeons, after which the surgical guide is designed (a process which takes 30 to 60 minutes). After the design of the surgical guide is approved in another multidisciplinary meeting, the approved design will be fabricated (costs €50 to €200). In our study, this was done by an external printing facility which complies with EU safety regulations, and takes three to four days including returning the printed guides by mail. Lastly, after receiving the 3D-printed guides, they were sterilized within our own hospital sterilization unit, which takes another day, leading to a total of five to six days' process time for the whole 3D workflow. Due to swelling of the knee after the injury, surgery is generally extended for about seven days following the injury. Considering a timeframe of five to six days for the whole 3D workflow, this process was deemed feasible.

One of the limitations of this study is that it is a case-control study instead of a randomized controlled trial. Ideally, patients should be randomized into either the intervention or the control group. However, the goal of this pilot study was to show the feasibility of an innovative 3D workflow. Another limitation of our proposed method is that in the 3D surgical planning, anatomical reduction of the fracture is assumed. Prior to the use of our 3D guides, the fracture needs to be reduced. However, the complexity of the fracture does not always allow for perfect anatomical reduction in practice. Therefore, accurate positioning of the implant with the enveloped surgical drilling guide appeared to be to most challenging part of our 3D workflow. Yet, despite these challenges, achieved surgical reduction was sufficient

in all cases for executing the 3D surgical planning. Lastly, widespread clinical implementation of this workflow depends of the presence of the required resources. Personnel skilled in 3D software are required, as is a printing facility that complies with regional safety regulations. In this study, 3D printing costs varied between €50 and €200. In addition, the designing, printing, and sterilization usually takes around five to six days. Yet, in most cases this timeframe was feasible, as the delay in surgery due to surrounding soft-tissue swelling associated with tibial plateau fractures provides an opportunity for the completion of the 3D surgical work-up.

In summary, this is among the first clinical studies to evaluate the application of 3D-printed surgical drilling guides in combination with conventional plates in tibial plateau fracture surgery. The use of 3D surgical planning including drilling guides during the operation was feasible, and facilitated accurate screw directions, screw lengths, and plate positioning according to the preoperative 3D surgical planning. Moreover, 3D surgical planning improved fracture reduction as compared to a historical cohort.

Supplementary material

Exemplary case in which the 3D-guided inserted screws are blocked by the screws placed freehand from the medial plate on the opposite site.

References

1. **Tscherne H, Lobenhoffer P.** Tibial plateau fractures. Management and expected results. *Clin Orthop Relat Res.* 1993;292:87–100.
2. **Prat-Fabregat S, Camacho-Carrasco P.** Treatment strategy for tibial plateau fractures: an update. *EFORT Open Rev.* 2016;1(5):225–232.
3. **Kääb MJ, Frenk A, Schmeling A, Schaser K, Schütz M, Haas NP.** Locked internal fixator: sensitivity of screw/plate stability to the correct insertion angle of the screw. *J Orthop Trauma.* 2004;18(8):483–487.
4. **Hoekstra H, Vanhees J, van den Berg J, Nijs S.** Extended lateral column tibial plateau fractures. How do we do it? *Injury.* 2018;49(10):1878–1885.
5. **McGonagle L, Cordier T, Link BC, Rickman MS, Solomon LB.** Tibia plateau fracture mapping and its influence on fracture fixation. *J Orthop Traumatol.* 2019;20(1):12.
6. **Assink N, Reininga IHF, Ten Duis K, et al.** Does 3D-assisted surgery of tibial plateau fractures improve surgical and patient outcome? A systematic review of 1074 patients. *Eur J Trauma Emerg Surg.* 2022;48(3):1737–1749.
7. **Tack P, Victor J, Gemmel P, Annemans L.** 3D-printing techniques in a medical setting: a systematic literature review. *Biomed Eng Online.* 2016;15(1):115.

8. Lal H, Patralekh MK. 3D printing and its applications in orthopaedic trauma: a technological marvel. *J Clin Orthop Trauma*. 2018;9(3):260–268.
9. Meesters AML, Assink N, Ten Duis K, et al. Accuracy of patient-specific drilling guides in acetabular fracture surgery: a human cadaver study. *J Pers Med*. 2021;11(8):763.
10. von Elm E, Altman DG, Egger M, et al. The Strengthening the Reporting of Observational Studies in Epidemiology (STROBE) statement: guidelines for reporting observational studies. *Bull World Health Organ*. 2007;85(11):867–872.
11. Assink N, El Moumni M, Kraeima J, et al. Radiographic predictors of conversion to total knee arthroplasty after tibial plateau fracture surgery: results in a large multicenter cohort. *J Bone Joint Surg Am*. 2023;105-A(16):1237–1245.
12. Vaartjes TP, Assink N, Nijveldt RJ, et al. Functional outcome after nonoperative management of tibial plateau fractures in skeletally mature patients: what sizes of gaps and stepoffs can be accepted? *Clin Orthop Relat Res*. 2022;480(12):2288–2295.
13. Meinberg EG, Agel J, Roberts CS, Karam MD, Kellam JF. Fracture and Dislocation Classification Compendium-2018. *J Orthop Trauma*. 2018;32 Suppl 1:S1–S170.
14. Saklad M. Grading of patients for surgical procedures. *Anesthesiol*. 1941;2(3):281–284.
15. Huang H, Hsieh M-F, Zhang G, et al. Improved accuracy of 3D-printed navigational template during complicated tibial plateau fracture surgery. *Australas Phys Eng Sci Med*. 2015;38(1):109–117.
16. Nie W, Gu F, Wang Z, Wu R, Yue Y, Shao A. Preliminary application of three-dimension printing technology in surgical management of bicondylar tibial plateau fractures. *Injury*. 2019;50(2):476–483.
17. Yammine K, Karbala J, Maalouf A, Daher J, Assi C. Clinical outcomes of the use of 3D printing models in fracture management: a meta-analysis of randomized studies. *Eur J Trauma Emerg Surg*. 2022;48(5):3479–3491.

Author information

N. Assink, MSc, Technical Physician, Department of Trauma Surgery, University of Groningen, University Medical Center Groningen, Groningen, Netherlands; 3D Lab, University of Groningen, University Medical Center Groningen, Groningen, Netherlands.

K. ten Duis, MD, Consultant in Trauma surgery
F. F. A. Ijpma, MD, PhD, Consultant in Trauma Surgery
 Department of Trauma Surgery, University of Groningen, University Medical Center Groningen, Groningen, Netherlands.

J. P. M. de Vries, MD, PhD, Professor and Consultant in Vascular Surgery, Department of Surgery, University Medical Center Groningen, Groningen, Netherlands.

M. J. H. Witjes, MD, PhD, Professor and Consultant in Maxillofacial Surgery

J. Kraeima, PhD, Technical Physician
 3D Lab, University of Groningen, University Medical Center Groningen, Groningen, Netherlands.

J. N. Doornberg, MD, PhD, Professor and Consultant in Orthopaedic & Trauma Surgery, Department of Trauma Surgery, University of Groningen, University Medical Center Groningen, Groningen, Netherlands; Flinders University, Adelaide, Australia.

Author contributions

N. Assink: Conceptualization, Data curation, Formal analysis, Funding acquisition, Investigation, Methodology, Project administration, Resources, Validation, Visualization, Writing – original draft.

K. ten Duis: Conceptualization, Investigation, Writing – review & editing.

J. P. M. de Vries: Conceptualization, Methodology, Resources, Supervision, Writing – review & editing.

M. J. H. Witjes: Conceptualization, Methodology, Software, Supervision, Writing – review & editing.

J. Kraeima: Conceptualization, Methodology, Software, Supervision, Writing – review & editing.

J. N. Doornberg: Conceptualization, Investigation, Writing – review & editing.

F. F. A. Ijpma: Conceptualization, Data curation, Funding acquisition, Investigation, Methodology, Project administration, Resources, Supervision, Validation, Writing – original draft.

Funding statement

The authors received no financial or material support for the research, authorship, and/or publication of this article.

ICMJE COI statement

A research grant was obtained from Stichting de Cock-Hadders, Netherlands.

Data sharing

The datasets generated and analyzed in the current study are not publicly available due to data protection regulations. Access to data is limited to the researchers who have obtained permission for data processing. Further inquiries can be made to the corresponding author.

Ethical review statement

Medical Center Groningen institutional review board approved the study procedures and the research was performed in accordance with the relevant guidelines and regulations (NL72543.042.20./201900879).

Open access funding

The open access fee for this article was self-funded.

© 2024 Assink et al. This is an open-access article distributed under the terms of the Creative Commons Attribution Non-Commercial No Derivatives (CC BY-NC-ND 4.0) licence, which permits the copying and redistribution of the work only, and provided the original author and source are credited. See <https://creativecommons.org/licenses/by-nc-nd/4.0/>