

Learning From Controversy: Contemporary Surgical Management of Aortic Valve Endocarditis

Francesco Nappi¹ , Sanjeet Singh Avtaar Singh^{2,3} 
and Irina Timofeeva⁴

¹Department of Cardiac Surgery, Centre Cardiologique du Nord de Saint-Denis, Paris, France.

²Department of Cardiac Surgery, Golden Jubilee National Hospital, Glasgow, UK. ³Institute of Cardiovascular and Medical Sciences, University of Glasgow, Glasgow, UK. ⁴Department of Imaging, Centre Cardiologique du Nord de Saint-Denis, Paris, France.

Clinical Medicine Insights: Cardiology
Volume 14: 1–17
© The Author(s) 2020
Article reuse guidelines:
sagepub.com/journals-permissions
DOI: 10.1177/1179546820960729



ABSTRACT: Aortic valve replacement is the commonest cardiac surgical operation performed worldwide for infective endocarditis (IE). Long-term durability and avoidance of infection relapse are goals of the procedure. However, no detailed guidelines on prosthesis selection and surgical strategies guided by the comprehensive evaluation of the extension of the infection and its microbiological characteristics, clinical profile of the patient, and risk of infection recurrence are currently available. Conventional mechanical or stented xenografts are the preferred choice for localized aortic infection. However, in cases of complex IE with the involvement of the root or the aortomitral continuity, the use of homograft is suggested according to the surgeon and center experience. Homograft use should be counterbalanced against the risk of structural degeneration. Prosthetic biroot or prosthetic valved conduit (mechanical and bioprosthetic) are also potentially suitable alternatives. Further development of preservation techniques enabling longer durability of allogenic substitutes is required. We evaluate the current evidence for the use of valve substitutes in aortic valve endocarditis and propose an evidence-based algorithm to guide the choice of therapy. We performed a systematic review to clarify the contemporary surgical management of aortic valve endocarditis.

KEYWORDS: Aortic valve endocarditis, surgical aortic valve replacement, homograft, Ross procedure, guidelines

RECEIVED: January 18, 2020. **ACCEPTED:** August 30, 2020.

TYPE: Review

FUNDING: The author(s) received no financial support for the research, authorship, and/or publication of this article.

DECLARATION OF CONFLICTING INTERESTS: The author(s) declared no potential conflicts of interest with respect to the research, authorship, and/or publication of this article.

CORRESPONDING AUTHOR: Francesco Nappi, Department of Cardiac Surgery, Centre Cardiologique du Nord, 36 Rue des Moulins Gémeaux, Saint-Denis, Paris 93200, France. Email: francesconappi2@gmail.com

Introduction

Aortic valve endocarditis (AVE) is the commonest infectious heart disease in adults, accounting for over half of 40 000 to 50 000 new cases of infective endocarditis (IE) annually in the United States alone.¹ IE is implicated in 20% of hospital deaths and up to 60% of patients who undergo surgery for prosthetic AVE develop complications due to the formation of root abscesses and valve dehiscence.^{1,2} Although infectious injury of one or more leaflets is the most common complication of native AVE, the extension of pathogens to other contiguous structures close to the aortic valve (AV) such as the aortic root, left ventricular outflow tract down to the mitral valve, called infectious aortopathy, is also present in approximately 64% of affected persons.^{3,4} Evidence to date suggests that the pattern of infectious disease in patients with aortic valve involvement is diverse, possibly reflecting the heterogeneity in age, sex, pathogens implicated, prosthetic valve endocarditis (PVE), alongside clinical and surgical features.^{1,2,5-7}

Surgical treatment of aortic valve endocarditis today is generally performed using conventional mechanical and stented xenograft prosthesis or cryopreserved aortic homograft while aortic valve repair is limited to well-circumscribed infectious injuries.^{3,4,8-10} However, the literature does not provide sufficient data for a systematic approach to AVE operations due to the lack of randomized trials classified as Class Ia level A or B, which may guide the timing and choices of the ideal substitute for infectious aortic valve disease.⁸⁻¹³

We performed an analysis of several reports in which different surgical strategies were compared for the treatment of aortic valve endocarditis and its complications to overcome limitations of individual observational studies in detecting differences in clinical outcomes, beginning with our own experience of valve surgery. We subsequently discuss the current evidence for different surgical strategies and propose evidence-based algorithms to aid the decision-making process behind the most suitable substitute during aortic valve endocarditis operations.

The Clinical Manifestation and the Effect of Therapy

Anatomical consideration

In heart infections, the surgeon is confronted with the potentially complicated distortion of structures which may cause handling to be tricky. The aortic valve apparatus includes the valve leaflets, annulus, sinus of Valsalva with left and right coronary ostia, and sinotubular junction. These components are assembled in the aortic root which together constitute a sophisticated structure. The 3 aortic-valve leaflets, each semilunar in appearance, are located within a small dilatation of the proximal aorta linked with each cusp, called aortic sinuses or the sinuses of Valsalva. These are designated, in respect of the corresponding coronary ostia (left, right, and non-coronary sinuses). Each leaflet is connected to the wall of the aorta by the outward edges of its semicircular border, with the fixing



extremity between each cusp named a commissure. 1.3% of the population worldwide have bicuspid aortic valves that typically consists of 2 unequally sized leaflets.¹⁴ The aortic cusps insert on the circumference of the aortic annulus, is incongruous to the mitral annulus and the fibrous trigones.

Anatomically, the aorta is divided into the ascending aorta, which is approximately 5 cm in length with a diameter ranging between 20 to 37 mm,¹⁵ aortic arch, thoracic aorta, and abdominal aorta. The ascending aorta includes the aortic root and the tubular portion that begins from the sinotubular junction in the aortic root and ends at the origin of the brachiocephalic or innominate artery. The competence of the aortic valve relies on the coordinated interaction of the aortic root apparatus. During diastole, the living dynamism of the aortic root prevents the valve leaflets from inverting into the left ventricle.

Methods

We designed a systematic review and conducted an electronic search of Pub Med, EMBASE, and Cochrane database from January 2001 to December 2019, using the terms “infective endocarditis,” “heart valve endocarditis,” “left side endocarditis,” “aortic valve endocarditis,” “heart valve prosthesis,” “allograft,” “autograft,” “aortic valve replacement,” and “aortic valve repair” was conducted. We assessed a large number of publications from 2001¹⁶ (Table 1) and 2019¹⁷ (Table 2) in patients who received the use of homograft, Ross operation, conventional mechanical, stented xenograft or stentless prosthesis or who received an aortic valve repair for infective aortic valve replacement. In detail, pertinent abstracts were reviewed and the related articles were examined. References for all selected studies were crosschecked. The lack of RCTs within this subject matter has refocused the present review on data from unmatched observational series, propensity-matched observational series, meta-analyses, registries, and editorials. Guidelines, professional society recommendations, registries, editorials, and prior systematic reviews were considered as additional references.

It is important to note that the weight of the evidence for the various substitutes for AVE was dissimilar. Unmatched observational series and propensity-matched series included around 4111 patients for xenograft prosthesis (XP), 2454 for aortic homograft (Ao-H), 665 for the mechanical prosthetic (MP), and a few hundred for Ross operations and aortic valve repairs (Tables 1 and 2; Figure 1).

Pathophysiology

Microbiology

Although aortic-valve endocarditis is characterized predominantly by adhesion of pathogens to abnormal or damaged endothelium of leaflets and annulus alone, the involvement of the aortic root, ascending aorta and arch is possible. In fact, the normal endothelial lining of the heart is resistant to the adhesion of germs but a defect in this resistance allows bacteria, especially gram-positive, to adhere to the damaged

endothelium. The adhesion mechanism to the aortic endothelium is mediated by specific surface adhesins that are proteins dedicated in intercede with the attachment of proteins of the host extracellular matrix. This process is facilitated by fibrin and platelet microthrombi.⁴⁸

The particular aggressiveness of Gram-positive bacteria is also because they lack an external membrane but instead have a thick surrounding peptidoglycan; making them less sensitive to serum-induced killing. After the bacterial adhesion during colonization, bacterial proliferation cycles are associated with local thrombotic processes, recruitment of monocytes, and inflammation, leading to the formation of mature vegetation.⁴⁹ The production of a biofilm that is typical of many of the infectious microorganisms (including staphylococci, streptococci, and enterococci with other rarer pathogens, such as *Candida* species and *Pseudomonas aeruginosa*), allow bacterial incorporation into a polysaccharide extracellular slime-like matrix. The specificity of biofilms among other things favors cell-to-cell communication and synchronized gene expression that promotes the assembly and maturation of pathogens. Once arisen, the biofilm protects the bacteria from the host's immune system, reduces antimicrobial efficacy, while shielding the organisms. The characteristics of the constituting biofilm are now recognized as a virulent trait in the development of infections related to the pathogenic staphylococcal species (Figure 2).

Clinical features

Patients with moderate-to-severe aortic regurgitation from AVE are often symptomatic and at imminent risk of clinical deterioration. The increasing severity of aortic regurgitation subjects an increased volume load on the left ventricle, which when continuously sustained over time, results in a cascade of ventricular dilatation, hypertrophy, neurohumoral activation, and finally, heart failure. In addition, the coupled mitral regurgitation exacerbating heart failure increases the mean left atrial pressure that consequently causes left atrial enlargement, atrial fibrillation, pulmonary congestion, and pulmonary hypertension.

The purpose of surgical correction for AVE is to restore the integrity of a competent aortic valve. There are 2 options for surgical correction of severe aortic regurgitation due to infectious disease of AV: in most cases, the surgical default is valve replacement but rarely, valve repair.

Clinical Evidence

Patients characteristics

During the 20th century, we noted a shift in the risk profile and demographic characteristics of the patients alongside the microbiology of infectious endocarditis. All these determinants relate to the development of antibiotic treatment, the decline of rheumatic heart disease, and medical advances.⁵⁰ Therefore, the

Table 1. Observational studies and propensity matched comparing the allogenic and autologous substitute with conventional prosthesis.

AUTHOR (REF.)	TOTAL SAMPLE (N)	NUMBER OF PATIENTS/ ENDOCARDITIS	MEAN FOLLOW-UP/MONTHS	NUMBER OF AORTIC VALVE SUBSTITUTE IMPLANTED OR REPAIR	MAIN FINDINGS
Nappi et al <i>JTCVS</i> ⁴	210	118	162	Ao-H (210) χ Ao/Mitr-H (11)	Similar survival at 15 years Ao-H (61.3%) versus stented xenograft (62.1%) and versus mechanical prosthesis (60.6%) 15 years freedom from reoperation structural valve degeneration (SVD) 89.4% Freedom from IE 98.1% at 20 years. MACCEs freedom from event at 15 years 50.6%
Schaefer et al <i>PLoS One</i> ¹⁸	#154	35	48.7	SFS (77) (IE 19) XP (77) (IE 16)	30-day mortality (SFS 3/77; 3.9% vs CP 4/77; 5.2%; <i>P</i> = .699). All-cause mortality (SFS 20.8% vs CP 14.3%; <i>P</i> = .397) SVD (5.2% SFS vs 0% CP; <i>P</i> = .04) Reoperation due to SVD or prosthetic valve endocarditis (PVE) (9.1% SFS vs 1.3% CP; <i>P</i> = .04) Inferior survival after NVE in re-do surgery in SFS group (HR: 7.63, CI: 1.65 ± 35.25, <i>P</i> = .009)
Ratschiller et al <i>Semin Thorac Cardiovasc Surg</i> ¹⁹	190	190	144	Ross Operation	30 days mortality for the total study population of 2.1%. Survival 93.8% (95% confidence interval [CI]: 90.2-97.7) at 10 years and 86.1% (95% CI: 78.8-94.0) at 20 years. Freedom from reoperation on the auto- and homograft 94.1% (95% CI : 83.6-100.0) at 5 years, 87.4% (95% CI: 72.4-100.0) at 10 years, and 71.5% (51.1-100.0) at 15 years Lower incidence of reoperation for autograft endocarditis 0.4%
Kim et al <i>JTCVS</i> ²⁰	#304	304	29.4	Ao-H (86) MP (79) XP (139)	Similar survival between valve substitute. Odds ratio 1.61; 95% confidence interval [CI], 0.73-3.40, <i>P</i> = .23 (HR 1.10; 95% CI, 0.62-1.94, <i>P</i> = .75). Reinfection 7.7%. No difference in freedom from reinfection rates (<i>P</i> = .65). CAH did not significantly affect reinfection (HR 1.04; 95% CI, 0.49-2.18, <i>P</i> = .93)
Kim et al <i>JTCVS</i> ²¹	#436	*IVDU 78 Non-IVDU 358	29.4	Ao-H (86) MP (99) XP (206)	Similar survival between group (IVDU vs Non IDVU). (IHR), 0.78; 95% CI, 0.44-1.37). No difference between valve substitute. Lower operative mortality in IVDUs (odds ratio, 0.25; 95% confidence interval [CI], 0.06-0.71). Better valve-related complications in IVDUs (HR, 3.82; 95% CI, 1.95-7.49; <i>P</i> < .001) for higher rates of reinfection (HR, 6.20; 95% CI, 2.56-15.00; <i>P</i> < .001).
Perrotta et al <i>Ann Thorac Surg</i> ²²	84	84	65	Ao-H (56) MP (20) XP (12)	10 years similar survival. CAH 58% versus conventional prosthesis 75% (<i>P</i> = .17). Higher incidence of reoperation for infection relapse in mechanical or xenograft valve prosthesis (12.9%) than CHA (0%) (<i>P</i> = .006). Lower incidence of reoperation for SVD in CAH at 10 years (5.3%)
Arabkhami et al <i>JTCVS</i> ²³	353	115	137	Ao-H (115)	20 years survival 40.0% at (95% CI, 32%-50%). 20 years predicted competing-risks analysis 31% death without reoperation, 39% reoperation, and 30% alive without reoperation. Low incidence of infection relapse (3.96%) and reoperation (2.26%)
Flameng et al <i>Ann Thorac Surg</i> ²⁴	69	69	96	Ao-H (69)	10 years survival 73%. 10 years freedom of reoperation 74%. Lower incidence of infection relapse and reoperation for IE (4.34%). Higher incidence of reoperation for SVD (18.84%)
Bourguignon et al <i>Ann Thorac Surg</i> ²⁵	2559	111	79	XP (111) (CP bioprosthesis)	15 and 20 years survival 31.1% and 14.4% (95% CI). IE early 0.11%; late 0.38%/[95% CI 0.30%-0.48%]. 10 and 20 years freedom from SVD 94.2%, 48.5%. MST 19.7 years (95% CI 18.5%-21.1%). 20 years freedom from reoperation (60-70 years) 59.6% Cumulative risk of reoperation for SVD HR 0.93 (95% CI 0.92-0.94; <i>P</i> < .001)

(Continued)

Table 1. (Continued)

AUTHOR (REF.)	TOTAL SAMPLE (N)	NUMBER OF PATIENTS/ ENDOCARDITIS	MEAN FOLLOW-UP/MONTHS	NUMBER OF AORTIC VALVE SUBSTITUTE IMPLANTED OR REPAIR	MAIN FINDINGS
Johnston et al <i>Ann Thorac Surg</i> ²⁶	12569	450	68	XP (450) (CP bioprosthesis)	76% probability of death before explant for SVD and endocarditis at 20years. Few probabilities of explanation for SVD (5.4%) and endocarditis (1.4%) at 20years.
Chiang et al <i>JAMA</i> ²⁷	#2002	16	128	MP (9) XP (7)	No difference in 30-day mortality XP (3%) versus MP (3%) ($P = .49$) No difference survival ($P = .74$); 15-year survival XP (60.6%-95% CI, 56.3%-64.9%) versus MP (62.1%-95% CI, 58.2%-66.0%), HR 0.97 (95% CI, 0.83-1.14), 15years reoperation XP (12.1%) versus MP (6.9%) (95% CI, 8.8%-15.4% vs 95% CI, 4.2%-9.6%. HR: 0.52; 95% CI, 0.36-0.75)
Hussain et al <i>JTCVS</i> ²⁸	#775	537	84	Ao-H (357) MP (25) XP (139)	30days mortality 7% for aortic valve and 14% for aortic and mitral valve IE. Survival at 5years 75% Rate of recurrence of infection 5.1%
Fukushima et al <i>JTCVS</i> ²⁹	840	101	420	Ao-H (101)	35years survival 66%. 35years reoperation rate for SVD 33.9%. 2 pts with CAH for more than 30years. Lower incidence of infection relapse and reoperation for IE. Early reinfection 0.2%. Late relapse of IE 5.5%
Senage et al <i>Circulation</i> ³⁰	617	“ “	44	XP (617) Mitroflow (models 12A/ LX)	5years survival 69.6% (95% CI, 65.7-73.9). Early SVD. 1-, 2-, and 5-year 0.2% (95% confidence interval [CI], 0.0-0.6), 0.8% (95% CI, 0.0-1.6), and 8.4% (95% CI, 5.3-11.3). 5-year SVD-free survival 91.6% (95% confidence interval [CI], 88.7-94.7). 13 patients accelerated SVD
Glaser et al <i>Ann Thorac Surg</i> ³¹	1219	8	50	XP (CP 864) XP (Mosaic 365)	No difference 8years survival CP (63%) versus Mosaic (57%) ($P = .971$). (IHR), 0.85; 95% confidence interval [CI], 0.65-1.11). No difference in reoperation ($P = .745$). Lower incidence of IE recurrence
Grubitzsch et al <i>JTCVS</i> ³²	149	96	48	MP (11) XP (80) Ross Procedure (5)	Early death 31.5%. Late death 7.38% Overall and event-free survivals at 10 years were 75% \pm 3.8% and 64% \pm 4.0% Freedom from recurrent infection and reoperation at 10 years were 81% \pm 3.6% and 91% \pm 2.6%
Kowert et al <i>Eur J Cardiothorac Surg</i> ³³	363	363	100	Ao-H (363)	Early death 8.9%. Survival 1 year (86%) and 5years (77.4%). Mean time between homograft implantation and redo operation 8.4 \pm 3.6 years Early and late recurrent endocarditis 9% (prior IE)
Manne et al <i>Ann Thorac Surg</i> ³⁴	428	282	12	Ao-H (173) MP (24) XP (84) Ross operation (1) Ao-R (12)	Higher 30-day mortality PVE versus NVE (13% vs 5.6%; $P < .01$) No difference in survival NVE versus PVE (35% vs 29%; $P = .19$). Higher 30days mortality and 1 year mortality for <i>Staphylococcus aureus</i> infection (15% vs 8.4%; $P < .05$) and (28% vs 18%; $P = .02$) Few reoperation for persistent infection or relapse (2.4%)
Mayer et al <i>Eur J Cardiothorac Surg</i> ³⁵	100	100	31	MP (10) XP (51) Ross operation (6) Ao-R (33)	Similar 30-day mortality Ao-R 9% versus Ao-Rpl 18% ($P = .37$). Better survival Ao-R (88%) versus Ao-Rpl (65%) ($P = .047$) Higher rate of reoperation Ao-R (35%) versus Ao-Rpl (10%) ($P = .021$)

(Continued)

Table 1. (Continued)

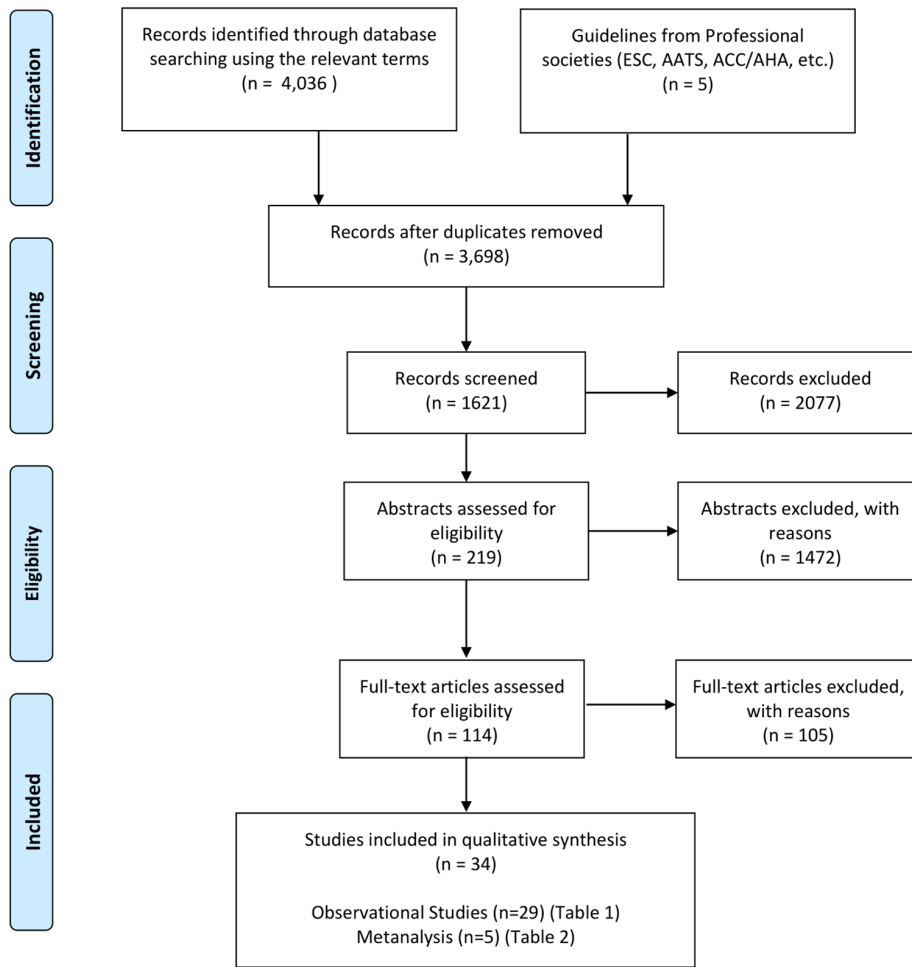
AUTHOR (REF.)	TOTAL SAMPLE (N)	NUMBER OF PATIENTS/ ENDOCARDITIS	MEAN FOLLOW-UP/MONTHS	NUMBER OF AORTIC VALVE SUBSTITUTE IMPLANTED OR REPAIR	MAIN FINDINGS
Bekkers et al <i>Eur J Cardiothorac Surg</i> ³⁶	262	96	102	Ao-H (96)	30-day mortality 5.7%. Survival 77.0% (95% confidence interval (CI) 71%-83%) at 10 years, and 65.1% (95% CI 57%-74%) at 14 years. Survival after re-operation 87.1% at 1 year and 79.3% at 9 years Freedom from allograft re-operation 82.9% at 10 years and 55.7% (SE 5.7%) at 14 years. SVD 18.5% and infection relapse 0.7%
Musci et al <i>JTCVS</i> ³⁷	1136	1136	62	Ao-H (221)	10 years survival 47.3% ± 5.6%. Lower incidence (5.4%) of infection relapse and reoperation for IE. Lower incidence of reoperation for SVD 8.6%
El-Hamamsy et al <i>Lancet</i> ³⁸	216	15	122	Ao-H (108) Ross (108)	Freedom from endocarditis 97% in the autograft versus 82% in the homograft at 13 years (P = .002). Freedom from CEP endocarditis, stroke, bleeding, or thrombosis 96% versus 82% at 13 years (P = .075)
Nguyen et al <i>Eur J Cardiothorac Surg</i> ³⁹	167	167	60	Ao-H (77) MP (109) XP(31)	30 day mortality XP (19.4%), Ao-H (7.4%), MP (10.1%) (P = .27) XP lower overall 5-year survival ≤65 years (adjusted HR 4.14 (1.27-13.45), P = .018) but not > 65 years (adjusted HR: 1.45 (0.35-5.97), P = .60). No difference between Ao-H and MP (HR (0.46, 95% CI (0.15-1.42), P = .18)
Klieverik et al <i>Ann Thorac Surg</i> ⁴⁰	138	138	96	Ao-H (106) MP (32)	Higher 30-day mortality for CAH (P = .25). No difference in survival at 15 years (CAH 59% ± 6% and MP 66% ± 9% (P = .68) and freedom from recurrent infection (P = .29). Higher rates of reoperation for CAH (P = .02)
David et al <i>JTCVS</i> ⁴¹	357	7	91	SPV (T-SPV) bioprosthesis (St Jude Medical, Inc, St Paul, Min) (357)	12 years survival 64%. 12 years freedom from SVD 69% (P = .002). Higher incidence of infection relapse (10% of redo aortic valve replacement).
David et al <i>JTCVS</i> ³	383	383	73	Ao-H (18) NMP (214) XP (133)	15 years survival 44%. Relapse of IE independent predictors of death (HR 2.2, 95% CI 1.2-3.9). 15 years freedom from recurrent IE 86% for all patients without difference between type of valve implanted. 15 years freedom from reoperation 70%
Yankah et al <i>EJCTS</i> ⁴²	816	816	60	Ao-H (182)	10 years survival 91%. Lower incidence of early (2.7%) and late (3.6%) infection relapse and reoperation for IE (P = .0001). 10-13 years freedom from reoperation for SVD 85%
Lytle et al <i>Ann Thorac Surg</i> ⁴³	Φ 103	103	51	Φ Ao-H (103)	30-day mortality 3.9%. Survival at 10 years 56%. Few recurrent PVE at ≥2 years (peaked at 9 months)
Moon et al <i>Ann Thorac Surg</i> ¹⁶	#306	306	183	Ao-H (20) MP (65) XP (221)	20 years survival 46% mechanical, 41% stented xenograft, 58% CAH; P > .27. Lower risk of infection relapse without group difference. 5 years 2.1% mechanical prosthesis, 2.3% stented xenograft, and 3.6% CAH; P > .88. After 5 years 0.5% mechanical prosthesis, 1.1% stented xenograft and 3.1% CAH; P > .25. 10 and 15 years freedom from reoperation for mechanical prosthesis 74.6%; 10 and 15 years freedom from reoperation for xenograft prosthesis 56.6%, 22.6% P > .64.

Propensity Score. * IVDU= intravenous drug user. Of total N=436 Valve repair was performed in N=45; χ Ao/Mitr-H = Cryopreserved mitro-aortic homograft replacement.

Table 2. Systemic review, meta-analysis and registries reporting the use of aortic homograft, Ross operation, conventional prosthesis and aortic valve repair.

AUTHOR (REF.)	TOTAL SAMPLE (N)	NUMBER OF PATIENTS/ ENDOCARDITIS	FOLLOW-UP/ MONTHS	NUMBER OF AORTIC VALVE SUBSTITUTE IMPLANTED	MAIN FINDINGS
Rimmer et al <i>Heart, Lung and Circulation</i> ¹⁷	7, 762 (11 papers)	<10%	Maximum 10 years	AV repair in 9 papers AVR versus AV repair in 2 papers	Long-term studies comparing AV repair versus AVR have not been published so there is insufficient evidence on the effectiveness of aortic valve repair. In the short follow up, AV repair techniques have evolved, focusing on function rather than normal anatomy, and long-term mortality and reoperation rates have proven to have no difference. However, AV repair is rarely used in AV endocarditis
Wang et al <i>Ann Thorac Surg</i> ⁴⁴	42,305	“ “	Mean times to valve failure (MTTF)	Medtronic Porcine (9,619) Edwards Porcine (3,886) Sorin Pericardial (6,632) Edwards Pericardial (22,177)	Sorin pericardial showed higher SVD risk; $P < .001$ for all other 3 valve type (lower risk-adjusted MTF). No significant differences in SVD risk among the other 3 valve types ($P = .716$).
Foroutan et al <i>BMJ</i> ⁴⁵	53,884	“ “	Cumulative incidence of Death and SVD at 10, 15, and 20 years	Xenograft (53,884)	Survival 89.7%, 78.4%, 57.0%, 39.7%, and 24.7% at 2, 5, 10, 15, and 20 10, 15, and 20 years freedom from SVD 94.0%, 81.7%, 52% at (evaluated for 7603 pts). SVD increases rapidly after 10 years, and particularly after 15 years.
Savage et al <i>Ann Thorac Surg STS database</i> ⁴⁶	11,560 8,491 prior 3,139 reoperative	11,560	2005-2011	Ao-H (588) XP (5396) MP (2144) Other (293)	AVR prior 88.5% versus reoperative 58.7%; RR prior 7.2% versus reoperative 29.9% Prior operation XP increased (57%-67%). MP decreased (30% vs 24%) Ao-H decreased (9% vs 6%) $P < .001$. Reoperation XP increased (38%-52%) MP decreased (20% vs 17%) Ao-H decreased (38% vs 28%) $P < .001$. Ao-H most used in reoperation
†Reece et al <i>Ann Thorac Surg STS database</i> ⁴⁷	2,188	#307	1994-2010	Ross (1094) Non Ross (1094)	Ross higher perioperative complications and operative mortality (2.7% versus 0.9%; $P [.001]$. Ross versus No Ross OR 3.00 (95% CI, 1.47-6.11; $P = .002$)

AV = aortic valve; † = PM; # All Ross operation.



From: Moher D, Liberati A, Tetzlaff J, Altman DG, The PRISMA Group (2009). Preferred Reporting Items for Systematic Reviews and Meta-Analyses: The PRISMA Statement. PLoS Med 6(7): e1000097. doi:10.1371/journal.pmed1000097

Figure 1. PRISMA Diagram showing selection of observational studies, systematic reviews and meta-analysis included in study.

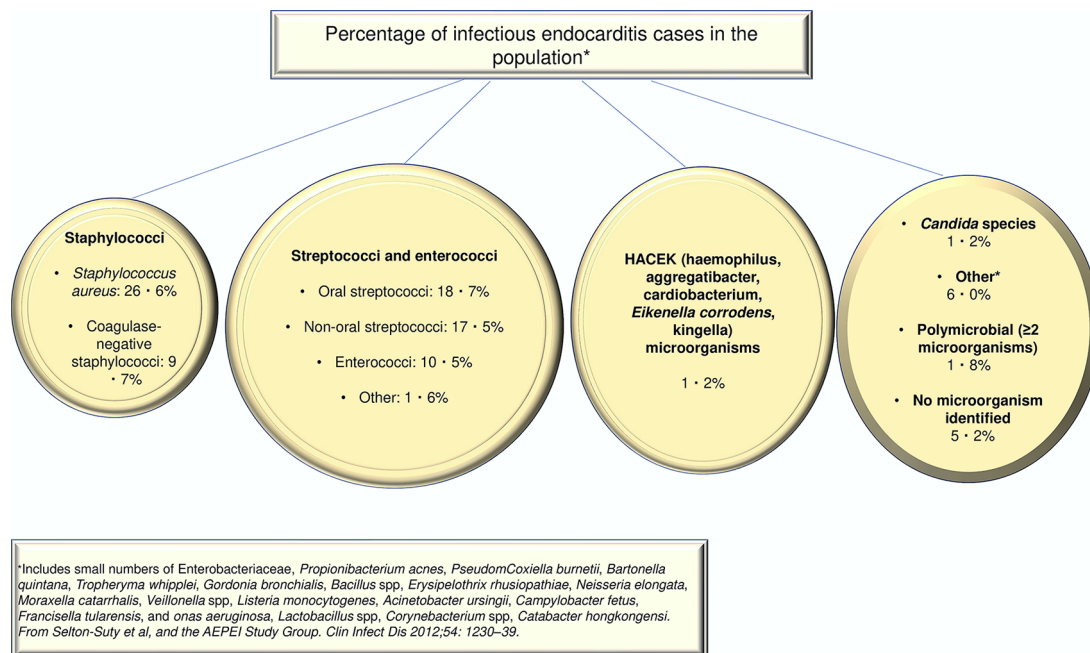


Figure 2. Show the percentage of cases of infective endocarditis caused by different microorganisms from a cohort of French population of 497 patients. From Selton-Suty et al, and the AEPEI Study Group. Clin Infect Dis 2012;54: 1230-39.

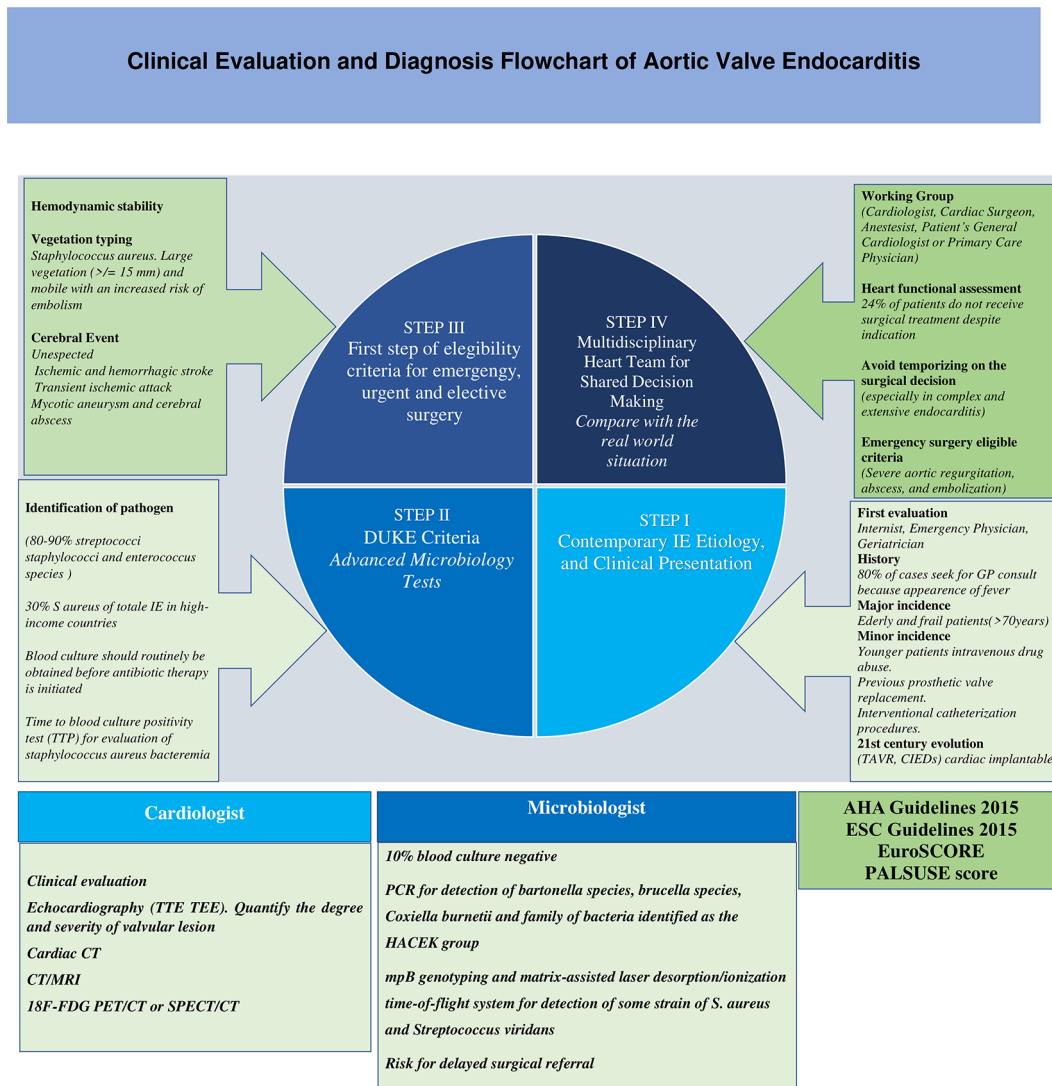


Figure 3. Clinical evaluation and diagnosis flowchart of aortic valve endocarditis.

category of patients undergoing surgical treatment of aortic endocarditis underwent a paradigm shift.^{51,52} Aortic valve endocarditis occurred mainly in young or middle-aged adults with underlying rheumatic heart disease or congenital heart disease, thus comprising a substantial proportion of patients affected in the pre-antibiotic era. The shift revealed other causes: prosthetic valve replacement, hemodialysis, indwelling venous catheters, immunosuppression and intravenous drug use (IV) have become the main risk factors.⁵² In high-income countries, AVE occurs in older patients who are frailer with multiple comorbidities. From an epidemiological perspective, staphylococci recently became the most frequent causative pathogen, overtaking oral streptococci (Figures 2 and 3).^{53,54}

In the 21st century, epidemiological studies demonstrated an IE incidence increment of $>25\%$ and a further change in demographics. Advances in cardiology such as the emergence of cardiac implantable electronic devices (CIED) and transcatheter valve replacements are radically changing the management of patients. Transcatheter valve replacements, however,

may result in higher rates of IE compared to surgically implanted prosthetic valves.⁸

Management

Early suspicion is essential during the preoperative phase of aortic endocarditis as some concerning indications for surgery are missed by attending physicians in 1 out of 6 patients as outlined in a recent study.⁵⁵ Early recognition and diagnosis help the decision-making process for the multidisciplinary team to focus solely on the emergency surgical criteria and on the clinical guidelines to be tailored to the patients' presenting complications (Figure 3).

Recent microbiological progress has helped facilitate this process through the association between infective endocarditis and the death of patients in the presence of *Staphylococcus aureus* bacteremia. Positive blood cultures with early time to positivity (TTP), which is a parameter normally available in automated blood culture systems, maybe an early indicator of the infectious

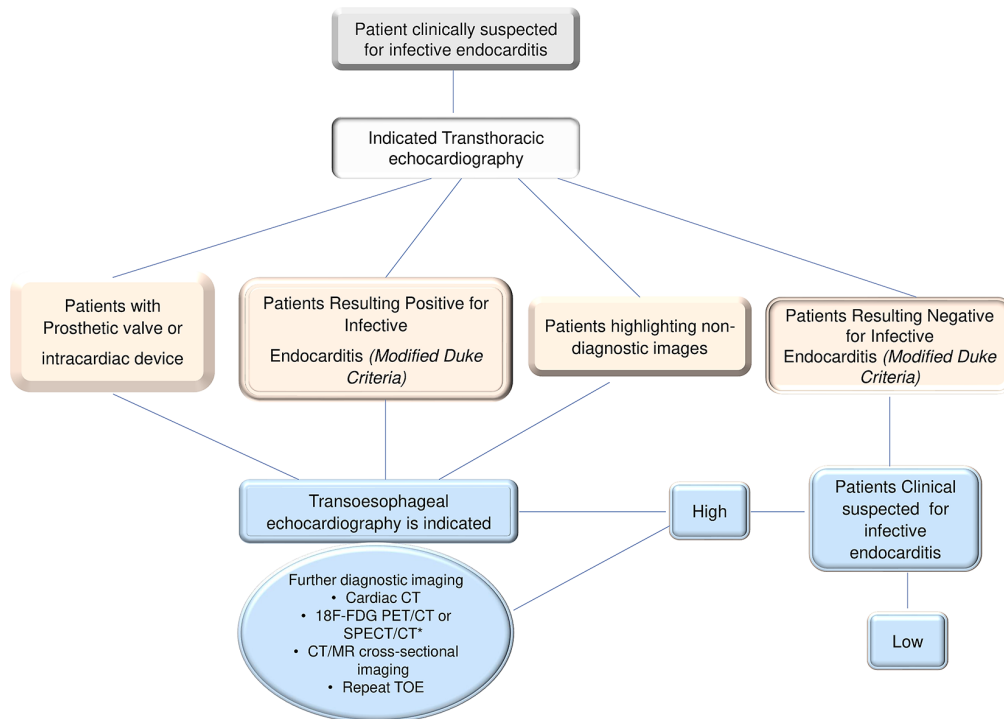


Figure 4. Shows an algorithm for the use of echocardiography in patients with suspected aortic valve endocarditis. To note that transthoracic echocardiography (TTE) is indicated as the initial investigation of choice for suspected AVE because it is accessible, quick, and safe. Patients who have a prosthetic valve or who previously received a cardiac device will usually require additional imaging with the use of transesophageal echocardiography (TOE). TOE must always be done even if TTE is diagnostic because TOE is an examination by image better for the detection of complications. In patients who have a negative TTE but a highly clinically suspected for aortic valve endocarditis, TOE is suggested and might need to be repeated at 7 to 10 days to confidently exclude the diagnosis. From Habib et al. *Eur J Echocardiogr* 2010; 11: 202-219. Abbreviations: AVE, aortic valve endocarditis; FDG-PET/CT, positron emission tomography with 2-deoxy-2-[fluorine-18] fluoro- D-glucose integrated with computed tomography; SPECT/CT, single-photon emission computed tomography integrated with computed tomography; TOE, transesophageal echocardiography; TTE, transthoracic echocardiography.

load in patients with systemic infections.⁵⁶ Thus, discussions and decision-making within the heart team can help disseminate the best current knowledge to address the surgical treatment of aortic valve endocarditis before the patient's condition worsens.

However, surgery is only part of the treatment as the heart team is also involved in the choices regarding anticoagulant therapy, optimal antibiotic treatment, and postoperative follow-up.⁵⁷⁻⁶³ Internal medicine and emergency physicians should use Duke's Criteria⁶⁴ to initiate the referral to minimize delays the surgical intervention. Patients with heart failure symptoms can easily be managed with appropriate medical treatment. Some patients may present with evidence of severe acute regurgitation or obstruction, resistant pulmonary edema and/or cardiogenic shock which usually indicate a more aggressive and wide infective colonization of the heart structure (Figure 3).^{13,65,66}

Sometimes, the time to reach a diagnosis is prolonged due to the difficulty in identifying a causative pathogen. Evidence for this clinical scenario is represented when the IE sustained by predominantly intracellular microorganisms, such as *C. burnetii*, *Bartonella* species, or *T. whipplei*, whereby exposure and the status of the immune response of the host become key determinants.⁶⁷ The difficulty of identifying the pathogen can result in a delay in surgical correction which increases the intraoperative risk in these severely compromised group.^{13,65,68,69}

The TTP test provides reliable information in patients with *S. aureus* bacteremia, on the risk of IE and prognosis. For example, a short TTP is an independent predictor of death and is a great tool for the recognition of patients who require specific attention.⁵⁶

Patients with AVE should have a careful assessment of symptoms and undergo electrocardiography (primarily to evaluate cardiac rhythm) and transthoracic echocardiography to assess the morphology and severity of AV regurgitation, as well as left ventricular size and function. Patients should be offered transesophageal echocardiography if the diagnosis remains doubtful (Figure 4).⁷⁰

There is a wide spectrum of neurological complications during infective endocarditis. Several studies recommend rapid and effective diagnostic and therapeutic interventions. Sixty percent of patients have symptoms identified as ischemic and hemorrhagic strokes, which often precede the diagnosis of infective endocarditis, thereby raising the dilemma of the risk of neurological injuries versus the timing of intervention.⁷¹⁻⁷⁴ Possible events associated with the presence of infectious foci include silent cerebral embolism which is recurrent in 50% of patients, transient ischemic attack, mycotic aneurysm, and cerebral abscess; all of which deserve prompt investigation.⁷⁴ Another criterion for early intervention is the presence of

vegetations due to *S. aureus* infection, which may be large, prominently mobile, and often involve patients with complex valve endocarditis and infected loci of pathogen located within the mitral valve. The localization of abscess is crucial to guide the surgery. In the experienced hands of diagnostic imaging experts, it helps provide a clear picture of the valve status (vegetations, valve function) and the risk of embolism (ie, mobile vegetation, evidence of previous septic embolism).^{65,71-74} Above all, the presence of vegetations from *Staphylococcus aureus* colonization > 10 mm is indicative of a progressive risk of embolic events requiring emergency surgery (Figure 3). Instead, in cases of established cerebral localization of septic emboli with hemorrhagic evolution, surgery should be postponed and CT scan or 18F-FDG PET/CT or SPECT/CT, as well as MR perfusion scans, should be performed to evaluate the progression of the lesion as per guidelines (Figures 3 and 4).^{65,74,75} Once the indication for surgery is established, the anesthetist should perform a thorough assessment to provide the best possible outcome with a degree of hemodynamic stability of the patient.⁹ The final aim of this coordinated multidisciplinary approach should be to guarantee an early referral to specialized centers and to avoid temporizing surgical intervention, especially in complex and extensive endocarditis.^{2,9,65,76}

Patients who have symptomatic aortic regurgitation and left ventricular dysfunction (ejection fraction, <60%), dilatation (left ventricular end-systolic dimension, >40 mm), or at risk for septic embolization and uncontrolled infection should be offered emergency or urgent surgery.⁹ Likewise, asymptomatic patients without left ventricular dysfunction or dilatation but with large vegetation (>20 mm) especially in those located on the mitral valve should be considered for emergency surgery due to the higher risk of neurological complications. Asymptomatic patients with small lesions with no or mild aortic regurgitation should be observed until the development of symptoms or aortomitral regurgitation and considered for elective surgical correction of AVE.⁹ Most studies, however, show a sizable proportion (25%-60%) of IE patients presenting with complex lesions and periannular abscess formation.^{2-4,9,20,21,65}

The goal of the multidisciplinary team is to provide the best possible treatment for patients requiring difficult medical and surgical management. The involvement of the perfusionist may be essential especially in cases of extracorporeal circulation prior to surgery. In our experience, no didactic leadership is necessary, much less the one that identifies the principal actor in the cardiac surgeon. It is the patient who takes center stage and can be treated according to his/her status in medical or cardiology wards, however, in case of deterioration intensive care environments are recommended.

Evidence from trial and observational studies

At the time of writing, there were no randomized trials that compared the different substitutes in surgery for aortic valve due to infective endocarditis. Evidence from observational

studies, however, strongly suggest that surgical intervention is valuable.^{3,4,9,10} One such study evaluated the impact of early surgery on long-term outcomes in 304 consecutive adult patients who active IE involving the aortic valve, Aortic Homografts (Ao-H) [n=86 (28.3%)], conventional stented xenograft (XP) [n=139 (45.7%)] and mechanical prostheses (MP) [n=29 (26.0)].²⁰ The patients who received an Ao-H had a higher incidence of prosthetic valve endocarditis (58.1% vs 28.8%, $P=.002$) and methicillin-resistant *Staphylococcus* infection (25.6% vs 12.1%, $P=.002$), compared to those who surgical correction was performed using conventional prostheses. After propensity-score analyses to adjust baseline characteristics, the choice of a homograft did not significantly affect early death (odds ratio 1.61; 95% confidence interval [CI], 0.73-3.40, $P=.23$), overall death (hazard ratio 1.10; 95% CI, 0.62-1.94, $P=.75$), or reinfection (hazard ratio 1.04; 95% CI, 0.49-2.18, $P=.93$).

In another report,²² 87 patients with surgical correction for prosthetic valve endocarditis (PVE) were studied. The choice of substitute was aortic homograft in 56 (64%) patients, mechanical prosthesis (MPs) in 20 (23%), and a bioprosthesis in 11 (13%), respectively. During a median follow-up period of 5.5 years, overall cumulative survival was 65% at 10 years without any statistically significant differences at 10 years survival between patients with homografts or conventional prosthesis (58% and 75%, respectively; $P=.17$). Surgical correction using Ao-H was independently associated with a reduced risk of infection relapse ($P=.006$) compared to conventional valves.

In a study from France,³⁹ aortic valve replacement for AVE was performed using xenograft prosthesis, mechanical prosthesis, and homograft in 167 consecutive patients who were followed-up for 5 years. A significant survival benefit was noted for patients who underwent AVR using MP as compared with those who received XP (5-year survival, HR; 2.39, 95% confidence interval (95% CI), 1.09-5.21; $P=.029$), which persisted after adjustment for baseline in patients <65 years old (HR 4.14 (1.27-13.45), $P=.018$) but not in patients >65 years old (HR: 1.45 (0.35-5.97), $P=.60$). When evaluating patients who received homografts and those who underwent surgical correction of AVE with mechanical prostheses, no differences were noted for 5-year mortality (HR 0.46, 95% CI (0.15-1.42), $P=.18$).

To the best of our knowledge, there are also currently no randomized trials comparing the use of Ao-H and MPs as a substitute in the setting of AV infection. However, data from observational studies including 138 patients (106 Ao-H; 32MPs) suggest that the use of mechanical prostheses had comparable rates of midterm survival (66% vs 59.6%; $P=.68$) and freedom from recurrent infection with the use of homografts ($P=.02$).⁴⁰ Conversely, in a report from the Deutsches Herzzentrum Berlin, 1163 patients who underwent a primary or secondary operation for AVE between 1986 and 2007 were studied (follow-up mean 5.2 ± 0.4 years, maximum 18.4 years).³⁷ Of these, 221 patients received a homograft aortic root

replacement for native valve endocarditis (NVE) (45%) in 99 cases and prosthetic valve endocarditis (PVE) (55%) in 122. The severity of lesions was noted by periannular abscess development in 189 patients (86%), and by aortoventricular dehiscence in 120 (63.5%) of recipients of Ao-H.

Among patients who underwent surgical treatment of NVE with homograft, the survival at 10 years was $47.3 \pm 5.6\%$ which was higher compared to those who had PVE because the latter developed a greater tendency toward abscess formation ($P = .29$). SVD was a complication that required reoperation in 8.6% of patients, more for those aged <40 years whereas reoperation for recurrent endocarditis was noted in 5.4% of homograft recipients.³⁷ The mortality rate due to reintervention at 1 year was not negligible at 16.1%.

The Ross operation may still be preferred in special circumstances, such as in young patients, women with childbearing potential, and other contraindications to lifelong anticoagulation therapy.^{8,77,78} The use of autograft for surgical correction of AVE is a complex surgical procedure that is indicated for extensive destruction of the leaflet and annulus. In such cases, the Ross operation may be a suitable alternative to the use of homograft due to the increased risk of prosthetic-valve deterioration also for its biomechanical behavior made favorable by the fact of being in the presence of living tissue.^{79,19,38,80,81-86} One randomized trial comparing autologous versus allogenic tissue in aortic valve surgery included 216 young adult patients (mean age 39 years), with follow-up duration exceeding a mean of 11 years, and reported a significantly better survival rate for patients undergoing Ross procedure than those whose AV replacement was managed with the use of a homograft (95% vs 78%; hazard ratio, 0.22; $P = .006$).³⁸ It highlighted the beneficial effect on long-term outcomes after the use of pulmonary artery (PA) in 43% of patients who had previous cardiac surgery. The survival rates at 13 years in patients who underwent the Ross procedure were equal to that of the general British population adjusted for age, sex, and failure with the use of bioprosthetic valves.

We reported an overall survival of $91.0 \pm 4.0\%$ at 16 years for the whole cohort of reinforced and non-reinforced Ross procedures, with a mean survival of 18.4 years (95% CI 18.0-18.81).⁸⁰ Freedom from Ross-related reintervention rate was $92.5 \pm 4.3\%$ at 15 years for the whole cohort ($88.3 \pm 5.4\%$ (non-reinforced Ross) vs $96.7 \pm 3.3\%$ (reinforced Ross)). Mean freedom from reoperation was 18.2 years (95% CI 17.7-18.7) in the nonreinforced group and 15.6 years (95% CI 15.1-16.2) in the reinforced group ($P = .233$).

Complication

Relapse of infection. Relapse of infection is the primary concern in patients who have previously undergone a surgical operation for complex aortic valve infective endocarditis, which may be associated with extension into the mitro-aortic curtain and/or evidence of fistula formation into a cardiac chamber or

pericardium.^{3,4,9,10,65,20,21,37} Surgeons at Harvard have pointed out its severity, reporting a high incidence among intravenous drug users and non-users.^{20,21} Many studies highlight the role of structural valve deterioration as a reason for aortic homograft and conventional stented xenograft versus mechanical prostheses^{36,33}; however, the evidence has proven that concerns relating to SVD are inconsistent in the first decade after post-implantation of Ao-H compared to conventional valves.^{4,23,87,29,88,89} Furthermore, the extension to a single valve leaflet does not exclude the annular involvement which often requires radical debridement with complete clearance of necrotic tissue, vegetation, and foreign material.^{4,65,66,20,21,89,90} Unfortunately, the de facto "simplest solution" may not always lead to the best long-term results. The reoperation for a relapsing infection carries a higher mortality than the reoperation for structural valve deterioration or dysfunction of an aortic homograft inserted in aortic root position. Active endocarditis, often the cause of recurrence^{4,66,20,21,89} is a statistically significant univariable risk factor for increased early and late mortality as shown by studies with short^{20,21} and long-term follow-up (over 20 years).^{4,23,29,87-89} As far as PVE is concerned, the use of Ao-H appears indisputable, unlike NVE whereby the preference for conventional prosthesis and synthetic material is still predominant (Figure 5).⁴⁶

Structural valve deterioration. The second surgical consideration when choosing the valve substitute in AVE is durability over time and the risk of a redo operation. This remains the watershed area for decision making with regards to the choice of a homograft compared to conventional stented xenograft or mechanical prosthesis. The homograft surgery itself is technically demanding with an intrahospital mortality of between 2% and 5.5% in elective surgery^{4,23,29,91} that is acceptable when compared with other prostheses³³ as reported in the literature. There is increased mortality in emergency surgery either for SVD or relapse of infection.^{4,33,91}

The risk of reoperation for SVD of aortic homograft must be compared to the durability of a bioprosthetic valve as an alternative to allogenic tissue. Very recent meta-analyses including all types of available aortic stented/non-stented xenografts (porcine and pericardial) revealed that SVD commonly starts 8 years after surgery, with a greatly increased rate of SVD after 10 years which is comparable with the duration of the allogenic tissue.^{44,45} Likewise, the St Jude Toronto SPV stentless aortic bioprosthesis (St Jude Medical), although promising excellent results for hemodynamics and durability up to 5 years of implantation, demonstrated a high rate of SVD within 8 years due to the increased mechanical stress on the cusps and late dilatation of the sinotubular junction.⁴¹ Second-generation porcine Hancock II valves (Medtronic) have long-term outcomes including actuarial survival rates without SVD at 10 years (95%), 15 years (75%), and 20 years (49%).⁹² The Carpentier-Edwards Perimount (Edwards Lifesciences) pericardial valve in the aortic position showed an actuarial freedom from SVD at 15 and 20 years of 79% and 54%, respectively,

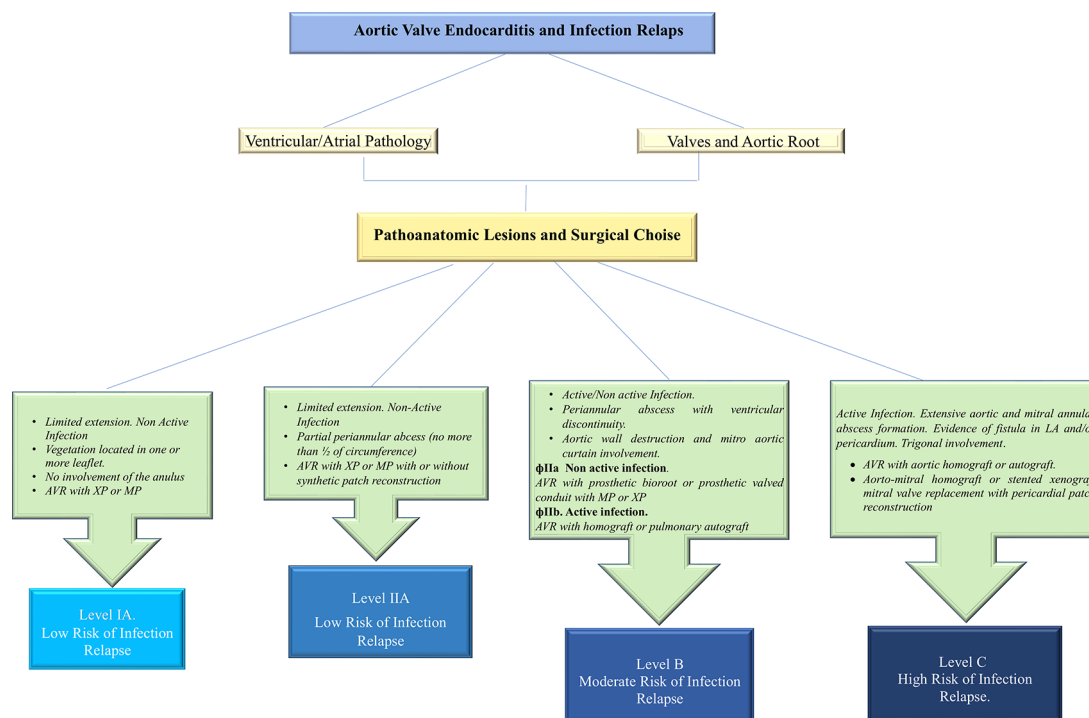


Figure 5. Algorithm to assess risk of infection relapse. Risk categories are identified on the basis of the anatomopathological characteristics of the infection, the magnitude of surgical demolition and reconstruction and the materials used. Abbreviations: AVR, aortic valve replacement; MP, mechanical prosthesis.

with an expected valve durability (median survival time without SVD) of 19 years.^{25,93}

Concerns arise from the use of new biological prostheses in the setting of aortic infective endocarditis due to the limited data available for long-term follow-up reported in the literature. Clinical and echocardiographic evidence have shown only medium-term results which therefore do not confer complete reliability for newer generation pericardial valves. Mitroflow bioprosthesis (models 12A/LX; LivaNova), have a mean time to SVD only of 3.8 ± 1.4 years.³⁰ St Jude Trifecta aortic bioprosthesis, showed 6-year actuarial freedom from SVD and freedom from reoperation of 95% and 96%, respectively,⁹⁴ although some reports of early Trifecta failure were described.⁹⁵ Only short-term effectiveness in durability for the surgical sutureless bioprosthetic LivaNova Perceval and Edwards Intuity valves are available.^{96,97} However, occasional reports of Perceval leaflet fluttering and early failure have also been described.⁹⁸

Discussion

Aortic-valve replacement is performed with either isolated mechanical or bioprosthetic or combined with aortic root replacement using a mechanical or biological conduit. It should be noted however, there are several drawbacks to aortic-valve replacement; lifelong anticoagulation treatment and the risk of thromboembolism with conventional mechanical prosthesis or the risk of prosthetic-valve deterioration and failure with the use of bioprosthetic valves; and the risk of relapse of infection with onset of prosthetic-valve endocarditis (PVE) for either. In

addition, infection migration to involve the mitral valve through the mitro-aortic continuity may partially or completely affect leaflets with loss of anchoring to the annulus, worsening the hemodynamic compromise in a vicious spiral. As a result, there is compounding damage to the heart structures necessitating extirpative surgery. The objectives of aortic-valve repair are to obtain a proper line of coaptation of leaflets, to preserve the aortic annulus from the development of abscess and to limit the extension of root infection.^{2,8,9}

There is a paucity of data available in the literature to allow a systematic approach to plan timing and choice of valves due to the lack of randomized studies categorized in Class Ia level of evidence (LOE) A or B.^{3,4,9-13,43,90,99-101} To date, only 1 randomized trial⁹⁹ has been published comparing patients who underwent early expedited surgery (within 48 hours) versus those who received medical therapy for severe left-sided IE (ie, large vegetations). The enrolled patients had no indications for emergency surgical correction of endocarditis, thereby resulting in a significantly lower in-hospital mortality or systemic embolization rate in the recipients who underwent surgery versus those who underwent conventional medical treatment (3% vs 23%). The results highlighted that, despite the increased intra-operative risk, early surgery in the case of IE with large vegetations resulted in a reduction of the composite endpoints of death from any cause and embolic events by effectively decreasing the risk of systemic embolism. The patients who underwent surgical correction for IE showed a hospital survival of 90%, and better outcomes within 30 days for NVE than for PVE (5.6% vs 13%) with similar long-term outcomes (35% vs

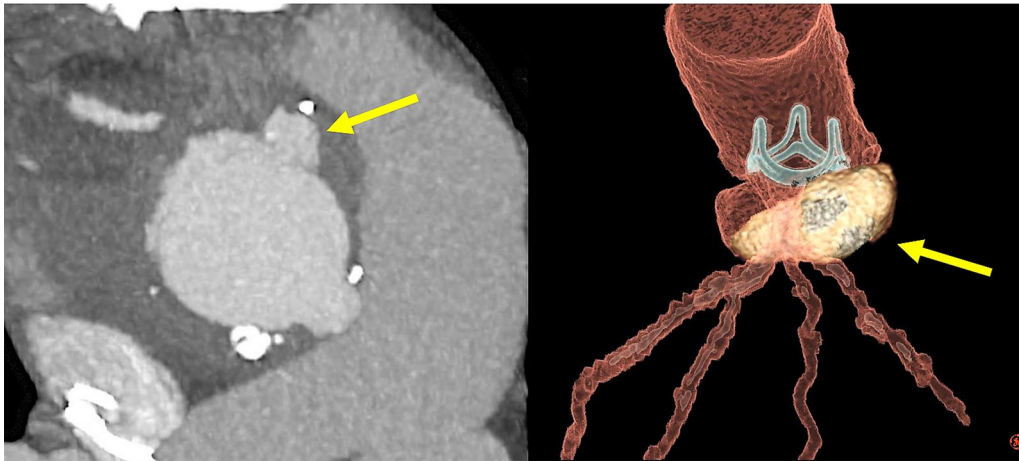


Figure 6. Aortic root abscess. Left: axial computed tomographic image showing the aortic root abscess. Right: a 3D volume rendered image of prosthetic valve endocarditis showing extensive root abscess.

29%).¹⁰² The infection sustained by *Staphylococcus aureus* conferred a significantly higher mortality compared with other pathogens.⁹⁹

Before the advent of advanced antibiotic therapy, aortic and/or mitral valve surgery was largely adopted for surgical correction of streptococcal infections. Aortic valve replacement with mechanical prosthesis may still be the preferred option even in patients with advancing age, combined or complex surgical procedure, or multiple comorbidities.⁹ In such cases, aortic valve repair³⁵ or reconstruction¹⁰³ may be a suitable alternative to replacement. In particular, women of childbearing age who intend to pursue a family or people in general who have contraindications to anticoagulation should be counseled on the benefits aortic valve repair, reconstruction, or even the use of aortic homografts.¹⁰⁴ Pivotal series from centers with proven experience demonstrate good outcomes in terms of mortality (intraoperative from 2.5% to 5.5%) and durability (up to 23 years) when aortic homografts are used as valvular substitutes in endocarditis.^{23,29,105} More recently the investigators highlighted positive results at 27-year follow-up after surgery using aortic homografts, underlining the importance of allogenic tissue in infection of the heart with low incidence of reoperations for infection relapse (2.2%).²³ Other widely cited historical series favorably express the use of Ao-H in the set of infected fields.^{37,42} One of these studies reported 13 years' experience with homografts in endocarditis, showing excellent clinical performance, long-term durability, and a low rate of reinfection with a late mortality rate of 7.9%. Patient survival after post-hospital discharge was 97% at 1 year and 91% at 10 years.¹⁶ Similarly, homograft aortic root replacement in active infective endocarditis with periannular abscess formation showed favorable early and long-term results with significantly better survival in native valve endocarditis than prosthetic valve endocarditis.³⁷ One study showed similar risk during reoperation itself for mechanical valves, bioprosthetic, and homografts¹⁰⁵ unlike the findings of other studies.^{3,4,65,20,21}

The use of aortic valve repair is limited and is preferable in native endocarditis caused by highly sensitive streptococci in which a small vegetation (<10 mm) is present on 1 leaflet of the aortic valve without the involvement of the annulus.¹⁹ The goal of repairing the aortic valve is aimed at restoring an adequate area of coaptation of the leaflets in diastole with complete movement of the leaflets. The surgeon removes the vegetation (vegetomy) respecting the neckline on the leaflet and generally associating the use of a pericardial patch to reinforce the leaflet subjected to strong stress. This procedure can also be used in the simple perforation of the leaflets. However, the use of repair is not recommended in the presence of vegetation located near the commissures especially when fenestrations exist. Instead, the small vegetation located on the free edge of the leaflet can be removed by reinforcing it with the use of a Goretex CV5 suture. Referring to the Acar technique of replacing the anterior mitral valve leaflet using the autologous pericardium treated with glutaraldehyde, the Ozaki procedure⁸⁰ takes advantage of the same principle of using the autologous pericardial patch to replace the aortic valve leaflets. This technique is limited to the localization of infection on the aortic valve only without involvement of the ring. Aortic valve repair has a high rate of reoperation despite being limited to experienced surgeons. The heart team plays an important role here, to help counsel patients about the decision-making process. Specifically, the rate of re-intervention, be it transcatheter valve therapy (TVT) or reoperation should be highlighted.

Several observational studies have shown that extensive and radical surgery is necessary in a large number of patients with IE and with homografts or mechanical valves and xenografts were used in similar complex endocarditis^{5,16,20,21,65} (Figure 6). One study reported a rate of abscess formation between 9% and 60%,⁸⁹ which is higher than the mean frequency (25%-30%) reported by other international studies^{3,10,23,29,43,106} indicating the severity of the disease treated in this cohort. Surgeons

at Harvard reported, in a large number of patients with complex valve endocarditis, the preferential use of mechanical valve prosthesis as a substitute for the infected aortic valve compared to the stented xenograft (40.5% vs 29.5%).^{20,21} This trend was also confirmed with the simultaneous involvement of the mitral valve using mechanical valves for surgical correction (38% vs 18.7%).^{20,21} These data seem to reinforce the tendency of some centers, which have long noted an association between mechanical valves and improved long-term survival.^{3,10}

Bucking this trend, we reported the use of homografts as a replacement for aortic and mitral valve diseased in 56.2% and 21% of patients who developed abscess formation.^{4,65,66,87,89,90} Sometimes in the presence of aggressive IE with extension to the aorto-mitral junction and mitral valve, we opted for a double homograft.^{4,89,107} In two-thirds of recipients, we performed a monobloc implant while one third received a separate bloc with partial mitral homograft insertion.¹⁰⁷ The technique of implantation has provided good results even in the presence of fragile tissue due to the presence of infection.^{4,89,107} We believe that endocarditis treatment should be guided by principles of avoidance of infection recurrence and functional valve outcomes. Although some reports^{3,20,21} praised the long-term outcomes of mechanical valves, subjecting patients to life-long anticoagulation which carries significant risks cannot be neglected. Additionally, the population normally afflicted by endocarditis is relatively young and often keen to return to an active lifestyle, making oral anticoagulation a potentially significant impairment to their quality of life. In female patients, anticoagulation effectively excludes their childbearing potential altogether.

Our propensity to utilize allogeneic tissues for extensive infections involving the heart structure, either in native or prosthetic valves, is supported by an innovative German study.¹⁰⁸ The authors have shown that Ao-H has antibacterial activity despite long-term conservation (5 years). Antibiotic combinations (gentamicin, vancomycin, metronidazole, piperacillin, flucloxacillin, tobramycin, meropenem, colistin, and the anti-fungal amphotericin-B) applied during cryopreserved aortic homograft (CAH) processing have a significant influence on their infection resistance. Homograft tissue of the ascending aorta revealed a significantly enhanced resistance against staphylococcal bacteria (*S. epidermidis* and *S. aureus*) with less bacterial contamination compared with homograft aortic valves. More effective resistance was noted against *P. aeruginosa* using flucloxacillin and *E. coli* using meropenem and colistin.¹⁰⁸ Application of antibiotics after thawing CAH led to a significant decrease in the recurrence of infections¹⁰⁹ that conventional prostheses or Dacron grafts have not yet clearly demonstrated, although the risk of vascular graft infection is reduced by pretreating the prostheses with antibiotics.¹¹⁰ The antibiotic/fibrin combined compound had a net effect of the delayed release of antibiotics to aid early prevention of infection relapse.¹¹⁰ Furthermore, new suggestions on effective concentrations of β -lactam antibiotics may enhance this action

thus providing additional immunity to recurrence.¹¹¹ The favorable response of allogeneic tissue to antibiotics has been documented^{23,29} where 21% and 25% of recurrent endocarditis in Ao-H were successfully treated medically without surgical re-intervention.

Selection of the type of graft to use for active endocarditis should be driven by the resistance to infection, as re-do surgery in cases of re-infection is particularly challenging and carries significant risks. Particular attention to technical details is required when using Ao-H such as allograft friability and anastomotic failure caused by inappropriate mechanical stress.¹¹² Reinfection of synthetic prostheses or prosthetic materials, normally employed in cases of complex endocarditis when a homograft is not used, is even more daunting and technically demanding than in reinfection of an implanted homograft.^{4,23,29,66,88,89} In this context, the safety and effectiveness of Ao-H over conventional prosthesis on the recurrence of infection has been widely reported in several observational studies,^{4,23,29,43,101,113,114} albeit with a difference in resistance to infection found between the valve and aortic wall of Ao-H.¹⁰⁸ Between 2% and 5.3% of patients with relapse or recurrence of infection following aortic valve, endocarditis surgery occur within the first year.^{16,29} Recent reports showed a low recurrence of endocarditis in homograft even in complex cases with extensive injury of heart structure.^{24,29} The largest controlled series showed a rate of freedom from allograft infection at 10 years post-implantation of 88% in active endocarditis during implantation versus 95% in patients without a history of endocarditis.^{29,88}

As a rule of thumb, endocarditis surgery should be dictated by 3 factors, the patient, the surgeons' experience/center experience, and the extent of the infection. A highly experienced surgeon/center well versed in aortic valve repair techniques may offer a young patient with aortic valve endocarditis limited to a single leaflet and no annular involvement would be an ideal candidate for a repair procedure, however, an older patient on anti-epileptics with extensive annular involvement may be best treated with a homograft/bioprostheses after debridement. The role of the heart team has to be emphasized with the 3 factors balanced out to specify the best possible outcome for each individual patient.

Conclusion

The major findings of this review noted that surgical correction of aortic valve endocarditis ranged around 55% per year and in high-income nations, most of the patients involved were >60 years. There is a general preference for biological prostheses^{18,26,31} as the primary intervention over mechanical prostheses^{27,115} and homografts or autograft.^{28,32,34,47} Aortic valve repair is indicated in selected cases and the use of the TAVR is not recommended in current guidelines.^{17,116-118} Homografts were more commonly used in NVE with extensive annular destruction or abscess formation, in extirpative heart surgery and prosthetic valve endocarditis. In the previous decade,

allogenic tissue was used in 7% of primary interventions and up to 32% for secondary intervention. Historical series of patients receiving allogenic tissue for AVR showed a lower incidence of infection relapse at up to 25 years follow-up. The role of shared decision making amongst the heart team is crucial to establish the timing of surgery. It may play an even more decisive role in the coming years with an increased number of TAVI procedures and implantable cardiac devices. Endocarditis has over the years changed its spots; perhaps it is time we change the tools at our disposal.

Author Contributions

All authors contributed equally to this article.

ORCID iDs

Francesco Nappi  <https://orcid.org/0000-0002-9705-5360>

Sanjeet Singh Avtaar Singh  <https://orcid.org/0000-0003-4320-0734>

REFERENCES

- Cahill TJ, Baddour LM, Habib G, et al. Challenges in infective endocarditis. *J Am Coll Cardiol*. 2017;69:325-344.
- Habib G, Hoen B, Tornos P, et al. Guidelines on the prevention, diagnosis, and treatment of infective endocarditis (new version 2009): the task force on the prevention, diagnosis, and treatment of infective endocarditis of the European Society of Cardiology (ESC). Endorsed by the European Society of Clinical Microbiology and Infectious Diseases (ESCMID) and the International Society of Chemotherapy (ISC) for infection and cancer. *Eur Heart J*. 2009;30:2369-2413.
- David TE, Gavra G, Feindel CM, Regesta T, Armstrong S, Maganti MD. Surgical treatment of active infective endocarditis: a continued challenge. *J Thorac Cardiovasc Surg*. 2007;133:144-149.
- Nappi F, Nenna A, Petitti T, et al. Long-term outcome of cryopreserved allograft for aortic valve replacement. *J Thorac Cardiovasc Surg*. 2018;156:1357-1365 e6.
- Hoen B, Duval X. Infective endocarditis. *N Engl J Med*. 2013;369:785.
- Curlier E, Hoen B, Alla F, et al. Relationships between sex, early valve surgery and mortality in patients with left-sided infective endocarditis analysed in a population-based cohort study. *Heart*. 2014;100:1173.
- Collins JA, Zhang Y, Burke AP. Pathologic findings in native infective endocarditis. *Pathol Res Pract*. 2014;210:997-1004.
- Nishimura RA, Otto CM, Bonow RO, et al. 2017 AHA/ACC focused update of the 2014 AHA/ACC guideline for the management of patients with valvular heart disease: a report of the American college of cardiology/American heart association task force on clinical practice guidelines. *Circulation*. 2017;135:e1159-e1195.
- Chairs ASToIECGWC, Petterson GB, Coselli JS, et al. 2016 the American Association for Thoracic Surgery (AATS) consensus guidelines: surgical treatment of infective endocarditis: executive summary. *J Thorac Cardiovasc Surg*. 2017;153:1241-1258 e29.
- Jassar AS, Bavaria JE, Szeto WY, et al. Graft selection for aortic root replacement in complex active endocarditis: does it matter? *Ann Thorac Surg*. 2012;93:480-487.
- Bando K. Does type of prosthesis affect long-term outcomes after aortic valve replacement for infective endocarditis? how should we properly answer this question? *J Thorac Cardiovasc Surg*. 2017;153:829-830.
- Bando K. Proposal for building an infrastructure for international randomized, control trials and a comprehensive registry of infective endocarditis. *J Thorac Cardiovasc Surg*. 2018;155:73-74.
- Nappi F, Spadaccio C. Keep fumbling around in the dark when it comes to infective endocarditis, or produce new, reliable data to redesign the guidelines? *J Thorac Cardiovasc Surg*. 2018;155:75-76.
- Siu SC, Silversides CK. Bicuspid aortic valve disease. *J Am Coll Cardiol*. 2010;55:2789-2800.
- Anderson RH, Lal M, Ho SY. Anatomy of the aortic root with particular emphasis on options for its surgical enlargement. *J Heart Valve Dis*. 1996;5:S249-S257.
- Moon MR, Miller DC, Moore KA, et al. Treatment of endocarditis with valve replacement: the question of tissue versus mechanical prosthesis. *Ann Thorac Surg*. 2001;71:1164-1171.
- Rimmer L, Ahmad MU, Chaplin G, Joshi M, Harky A. Aortic valve repair: where are we now? *Heart Lung Circ*. 2019;28:988-999. doi: 10.1016/j.hlc.2019.02.007. Epub March 4, 2019. Review. Erratum in: *Heart Lung Circ*. 2019;28:e151.
- Schaefer A, Dickow J, Schoen G, et al. Stentless vs. stented bioprosthesis for aortic valve replacement: a case matched comparison of longterm follow-up and subgroup analysis of patients with native valve endocarditis. *PLoS one*. 2018;13:e0191171.
- Ratschiller T, Sames-Dolzer E, Paulus P, et al. Long-term evaluation of the Ross procedure in acute infective endocarditis. *Semin Thorac Cardiovasc Surg*. 2017;29:494-501.
- Kim JB, Ejiogor JI, Yammine M, et al. Are homografts superior to conventional prosthetic valves in the setting of infective endocarditis involving the aortic valve? *J Thorac Cardiovasc Surg*. 2016;151:1239-1248.e2.
- Kim JB, Ejiogor JI, Yammine M, et al. Surgical outcomes of infective endocarditis among intravenous drug users. *J Thorac Cardiovasc Surg*. 2016;152:832-841.e1.
- Perrotta S, Jeppsson A, Fröjd V, Svensson G. Surgical treatment of aortic prosthetic valve endocarditis: a 20-year single-center experience. *Ann Thorac Surg*. 2016;101:1426-1432.
- Arabhkani B, Bekkers JA, Andrinopoulou E-R, Roos-Hesslink JW, Takkenberg JJM, Bogers AJJC. Allografts in aortic position: insights from a 27-year, single-center prospective study. *J Thorac Cardiovasc Surg*. 2016;152:1572-1579.e3.
- Flameng W, Daenen W, Jashari R, Herijgers P, Meuris B. Durability of homografts used to treat complex aortic valve endocarditis. *Ann Thorac Surg*. 2015;99:1234-1238.
- Bourguignon T, Bouquiaux-Stablo AL, Candolfi P, et al. Very long-term outcomes of the carpentier-edwards perimount valve in aortic position. *Ann Thorac Surg*. 2015;99:831-837.
- Johnston DR, Soltesz EG, Vakil N, et al. Long-term durability of bioprosthetic aortic valves: implications from 12,569 implants. *Ann Thorac Surg*. 2015;99:1239-1247.
- Chiang YP, Chikwe J, Moskowitz AJ, Itagaki S, Adams DH, Egorova NN. Survival and long-term outcomes following bioprosthetic vs mechanical aortic valve replacement in patients aged 50 to 69 years. *JAMA*. 2014;312:1323-1329.
- Hussain ST, Shrestha NK, Gordon SM, et al. Residual patient, anatomic, and surgical obstacles in treating active left-sided infective endocarditis. *J Thorac Cardiovasc Surg*. 2014;148:981-988. e4.
- Fukushima S, Tesar PJ, Pearse B, et al. Long-term clinical outcomes after aortic valve replacement using cryopreserved aortic allograft. *J Thorac Cardiovasc Surg*. 2014;148:65-72.e2.
- Senage T, Le Tourneau T, Foucher Y, et al. Early structural valve deterioration of mitroflow aortic bioprosthesis: mode, incidence, and impact on outcome in a large cohort of patients. *Circulation*. 2014;130:2012-2020.
- Glaser N, Franco-Cereceda A, Sartipy U. Late survival after aortic valve replacement with the perimount versus the mosaic bioprosthesis. *Ann Thorac Surg*. 2014;97:1314-1320.
- Grubitzsch H, Schaefer A, Melzer C, et al. Outcome after surgery for prosthetic valve endocarditis and the impact of preoperative treatment. *J Thorac Cardiovasc Surg*. 2014;148:2052-2059.
- Kowert A, Vogt F, Beiras-Fernandez A, Reichart B, Kilian E. Outcome after homograft redo operation in aortic position. *Eur J Cardiothorac Surg*. 2012;41:404-408.
- Manne MB, Shrestha NK, Lytle BW, et al. Outcomes after surgical treatment of native and prosthetic valve infective endocarditis. *Ann Thorac Surg*. 2012;93:489-493.
- Mayer K, Aicher D, Feldner S, Kunihara T, Schafers HJ. Repair versus replacement of the aortic valve in active infective endocarditis. *Eur J Cardiothorac Surg*. 2012;42:122-127.
- Bekkers JA, Klieverik LM, Raap GB, Takkenberg JJ, Bogers AJ. Re-operations for aortic allograft root failure: experience from a 21-year single-center prospective follow-up study. *Eur J Cardiothorac Surg*. 2011;40:35-42.
- Musci M, Weng Y, Hübler M, et al. Homograft aortic root replacement in native or prosthetic active infective endocarditis: twenty-year single-center experience. *J Thorac Cardiovasc Surg*. 2010;139:665-673.
- El-Hamamsy I, Eryigit Z, Stevens LM, et al. Long-term outcomes after autograft versus homograft aortic root replacement in adults with aortic valve disease: a randomised controlled trial. *Lancet (London, England)*. 2010;376:524-531.
- Nguyen DT, Delahaye F, Obadia J-F, et al. Aortic valve replacement for active infective endocarditis: 5-year survival comparison of bioprostheses, homografts and mechanical prostheses. *Eur J Cardiothorac Surg*. 2010;37:1025-1032.

40. Klieverik LMA, Yacoub MH, Edwards S, et al. Surgical treatment of active native aortic valve endocarditis with allografts and mechanical prostheses. *Ann Thorac Surg.* 2009;88:1814-1821.
41. David TE, Feindel CM, Bos J, Ivanov J, Armstrong S. Aortic valve replacement with Toronto SPV bioprosthesis: optimal patient survival but suboptimal valve durability. *J Thorac Cardiovasc Surg.* 2008;135:19-24.
42. Yankah AC, Klose H, Petzina R, Musci M, Siniawski H, Hetzer R. Surgical management of acute aortic root endocarditis with viable homograft: 13-year experience. *Eur J Cardiothorac Surg.* 2002;21:260-267.
43. Lytle BW, Sabik JF, Blackstone EH, Svensson LG, Petterson GB, Cosgrove DM, 3rd. Reoperative cryopreserved root and ascending aorta replacement for acute aortic prosthetic valve endocarditis. *Ann Thorac Surg.* 2002;74:S1754-S1757; discussion S92-S99.
44. Wang M, Furnary AP, Li HF, Grunkemeier GL. Bioprosthetic aortic valve durability: a meta-regression of published studies. *Ann Thorac Surg.* 2017;104:1080-1087.
45. Foroutan F, Guyatt GH, O'Brien K, et al. Prognosis after surgical replacement with a bioprosthetic aortic valve in patients with severe symptomatic aortic stenosis: systematic review of observational studies. *BMJ.* 2016;354:i5065.
46. Savage EB, Saha-Chaudhuri P, Asher CR, Brennan JM, Gammie JS. Outcomes and prosthesis choice for active aortic valve infective endocarditis: analysis of the society of thoracic surgeons adult cardiac surgery database. *Ann Thorac Surg.* 2014;98:806-814.
47. Reece TB, Welke KF, O'Brien S, et al. Rethinking the Ross procedure in adults. *Ann Thorac Surg.* 2014;97:175-181.
48. Patti JM, Allen BL, McGavin MJ, Hook M. MSCRAMM-mediated adherence of microorganisms to host tissues. *Annu Rev Microbiol.* 1994;48:585-617.
49. Werdan K, Dietz S, Löffler B, et al. Mechanisms of infective endocarditis: pathogen-host interaction and risk states. *Nat Rev Cardiol.* 2014;11:35-50.
50. Seckeler MD, Hoke TR. The worldwide epidemiology of acute rheumatic fever and rheumatic heart disease. *Clin Epidemiol.* 2011;3:67-84.
51. Slipeczuk L, Codolosa JN, Davila CD, et al. Infective endocarditis epidemiology over five decades: a systematic review. *PLoS One.* 2013;8:e82665.
52. Prendergast BD. The changing face of infective endocarditis. *Heart.* 2006;92:879-885.
53. Selton-Suty C, Celard M, Le Moing V, et al. Preeminence of staphylococcus aureus in infective endocarditis: a 1-year population-based survey. *Clin Infect Dis.* 2012;54:1230-1239.
54. Murdoch DR, Corey GR, Hoen B, et al. Clinical presentation, etiology, and outcome of infective endocarditis in the 21st century: the international collaboration on endocarditis-prospective cohort study. *Arch Intern Med.* 2009;169:463-473.
55. Iung B, Doco-Lecompte T, Chocron S, et al. Cardiac surgery during the acute phase of infective endocarditis: discrepancies between European society of cardiology guidelines and practices. *Eur Heart J.* 2016;37:840-848.
56. Siméon S, Le Moing V, Tubiana S, et al. Time to blood culture positivity: an independent predictor of infective endocarditis and mortality in patients with staphylococcus aureus bacteraemia. *Clin Microbiol Infect.* 2019;25:481-488.
57. Baddour LM, Wilson WR, Bayer AS, et al. Infective endocarditis: diagnosis, antimicrobial therapy, and management of complications: a statement for healthcare professionals from the committee on rheumatic fever, endocarditis, and Kawasaki disease, council on cardiovascular disease in the young, and the councils on clinical cardiology, stroke, and cardiovascular surgery and anesthesia, American heart association: endorsed by the infectious diseases society of America. *Circulation.* 2005;111:e394-e434.
58. Gould FK, Denning DW, Elliott TSJ, et al. Guidelines for the diagnosis and antibiotic treatment of endocarditis in adults: a report of the working party of the British society for antimicrobial chemotherapy. *J Antimicrob Chemother.* 2011;67:269-289.
59. Morris AJ, Drinković D, Pottumarthy S, MacCulloch D, Kerr AR, West T. Bacteriological outcome after valve surgery for active infective endocarditis: implications for duration of treatment after surgery. *Clin Infect Dis.* 2005;41:187-194.
60. Chan KL, Tam J, Dumesnil JG, et al. Effect of long-term aspirin use on embolic events in infective endocarditis. *Clin Infect Dis.* 2008;46:37-41.
61. Pepin J, Tremblay V, Bechar D, et al. Chronic antiplatelet therapy and mortality among patients with infective endocarditis. *Clin Microbiol Infect.* 2009;15:193-199.
62. Snygg-Martin U, Rasmussen RV, Hassager C, Bruun NE, Andersson R, Olaison L. The relationship between cerebrovascular complications and previously established use of antiplatelet therapy in left-sided infective endocarditis. *Scand J Infect Dis.* 2011;43:899-904.
63. Anavekar NS, Tleyjeh IM, Anavekar NS, et al. Impact of prior antiplatelet therapy on risk of embolism in infective endocarditis. *Clin Infect Dis.* 2007;44:1180-1186.
64. Li JS, Sexton DJ, Mick N, et al. Proposed modifications to the Duke criteria for the diagnosis of infective endocarditis. *Clin Infect Dis.* 2000;30:633-638.
65. Nappi F, Spadaccio C, Dreyfus J, Attias D, Acar C, Bando K. Mitral endocarditis: a new management framework. *J Thorac Cardiovasc Surg.* 2018;156:1486-1495 e4.
66. Nappi F, Spadaccio C, Acar C. Use of allogeneic tissue to treat infective valvular disease: has everything been said? *J Thorac Cardiovasc Surg.* 2017;153:824-828.
67. Brouqui P, Raoult D. Endocarditis due to rare and fastidious bacteria. *Clin Microbiol Rev.* 2001;14:177-207.
68. Isaksson J, Rasmussen M, Nilson B, et al. Comparison of species identification of endocarditis associated viridans streptococci using rnpB genotyping and 2 MALDI-TOF systems. *Diagn Microbiol Infect Dis.* 2015;81:240-245.
69. N'Guyen Y, Duval X, Revest M, et al. Time interval between infective endocarditis first symptoms and diagnosis: relationship to infective endocarditis characteristics, microorganisms and prognosis. *Ann Med.* 2017;49:117-125.
70. Habib G, Badano L, Tribouilloy C, et al. Recommendations for the practice of echocardiography in infective endocarditis. *Eur J Echocardiogr.* 2010;11:202-219.
71. Selton-Suty C, Delahaye F, Tattevin P, et al. Symptomatic and asymptomatic neurological complications of infective endocarditis: impact on surgical management and prognosis. *PLoS one.* 2016;11:e0158522.
72. Sonnevill R, Mirabel M, Hajage D, et al. Neurologic complications and outcomes of infective endocarditis in critically ill patients: the ENDOcardite en REAnimation prospective multicenter study. *Crit Care Med.* 2011;39:1474-1481.
73. Thuny F, Avierinos JF, Tribouilloy C, et al. Impact of cerebrovascular complications on mortality and neurologic outcome during infective endocarditis: a prospective multicentre study. *Eur Heart J.* 2007;28:1155-1161.
74. Duval X, Iung B, Klein I, et al. Effect of early cerebral magnetic resonance imaging on clinical decisions in infective endocarditis: a prospective study. *Ann Intern Med.* 2010;152:497-504, w175.
75. Tubiana S, Duval X, Alla F, et al. The VIRSTA score, a prediction score to estimate risk of infective endocarditis and determine priority for echocardiography in patients with staphylococcus aureus bacteremia. *J Infect.* 2016;72:544-553.
76. Iung B, Doco-Lecompte T, Chocron S, et al. Cardiac surgery during the acute phase of infective endocarditis: discrepancies between European society of cardiology guidelines and practices. *Eur Heart J.* 2016;37:840-848.
77. Nappi F, Spadaccio C, Chello M, Acar C. The Ross procedure: underuse or under-comprehension? *J Thorac Cardiovasc Surg.* 2015;149:1463-1464.
78. Nappi F, Avtaar Singh SS, Spadaccio C, Acar C. Ross operation 23 years after surgery: it should not be a "forgotten" option. *J Card Surg.* 2020;35:952-956.
79. Mazina A, El-Hamamsy I, Verma S, et al. Ross procedure in adults for cardiologists and cardiac surgeons: JACC state-of-the-art review. *J Am Coll Cardiol.* 2018;72:2761-2777.
80. Nappi F, Nenna A, Larobina D, et al. Simulating the ideal geometrical and biomechanical parameters of the pulmonary autograft to prevent failure in the Ross operation. *Interact Cardiovasc Thorac Surg.* 2018;27:269-276.
81. Nappi F, Spadaccio C, Al-Attar N, Acar C. The Ross procedure at the crossroads: lessons from biology: is Dr Ross's dream concluded? *Int J Cardiol.* 2015;178:37-39.
82. Spadaccio C, Nappi F, Al-Attar N, et al. Old myths, new concerns: the long-term effects of ascending aorta replacement with dacron grafts. Not all that glitters is gold. *J Cardiovasc Transl Res.* 2016;9:334-342.
83. Nappi F, Carotenuto AR, Cutolo A, et al. Compliance mismatch and compressive wall stresses drive anomalous remodelling of pulmonary trunks reinforced with dacron grafts. *J Mech Behav Biomed Mater.* 2016;63:287-302.
84. Nappi F, Spadaccio C, Fraldi M, et al. A composite semiresorbable armoured scaffold stabilizes pulmonary autograft after the Ross operation: Mr Ross's dream fulfilled. *J Thorac Cardiovasc Surg.* 2016;151:155-164.e1.
85. Nappi F, Fraldi M, Spadaccio C, et al. Biomechanics drive histological wall remodeling of neo-aortic root: a mathematical model to study the expression levels of ki 67, metalloproteinase, and apoptosis transition. *J Biomed Mater Res A.* 2016;104:2785-2793.
86. Spadaccio C, Montagnani S, Acar C, Nappi F. Introducing bioresorbable scaffolds into the show. A potential adjunct to resuscitate Ross procedure. *Int J Cardiol.* 2015;190:50-52.
87. Nappi F. CRT-721 the cryopreserved mitral homograft valve: 19 Years experience. *JACC Cardiovasc Interv.* 2014;7:S58.
88. O'Brien MF, Harrocks S, Stafford EG, et al. The homograft aortic valve: a 29-year, 99.3% follow up of 1,022 valve replacements. *J Heart Valve Dis.* 2001;10:334-344; discussion 5.
89. Olivito S, Lalande S, Nappi F, et al. Structural deterioration of the cryopreserved mitral homograft valve. *J Thorac Cardiovasc Surg.* 2012;144:313-320, 20.e1.

90. Nappi F, Spadaccio C. Simplest solutions are not always the cleverest: can we stitch in an infected annulus? should we rethink the current guidelines? *J Thorac Cardiovasc Surg.* 2017;154:1899-1900.
91. Joudinaud TM, Baron F, Raffoul R, et al. Redo aortic root surgery for failure of an aortic homograft is a major technical challenge. *Eur J Cardiothorac Surg.* 2008;33:989-994.
92. Garrido-Olivares L, Maganti M, Armstrong S, David T. Aortic valve replacement with hancock II bioprosthesis with and without replacement of the ascending aorta. *Ann Thorac Surg.* 2011;92:541-547.
93. Bourguignon T, El Khoury R, Candolfi P, et al. Very long-term outcomes of the carpentier-edwards perimount aortic valve in patients aged 60 or younger. *Ann Thorac Surg.* 2015;100:853-859.
94. Goldman S, Cheung A, Bavaria JE, Petracek MR, Groh MA, Schaff HV. Midterm, multicenter clinical and hemodynamic results for the trifecta aortic pericardial valve. *J Thorac Cardiovasc Surg.* 2017;153:561-569.e2.
95. Kalra A, Rehman H, Ramchandani M, et al. Early trifecta valve failure: report of a cluster of cases from a tertiary care referral center. *J Thorac Cardiovasc Surg.* 2017;154:1235-1240.
96. Fischlein T, Meuris B, Hakim-Meibodi K, et al. The sutureless aortic valve at 1 year: a large multicenter cohort study. *J Thorac Cardiovasc Surg.* 2016;151:1617-1626.e4.
97. Kocher AA, Laufer G, Haverich A, et al. One-year outcomes of the surgical treatment of aortic stenosis with a next generation surgical aortic valve (TRITON) trial: a prospective multicenter study of rapid-deployment aortic valve replacement with the EDWARDS INTUITY Valve System. *J Thorac Cardiovasc Surg.* 2013;145:110-115; discussion 5-6.
98. Durand E, Tron C, Eltchaninoff H. Emergency transcatheter aortic valve implantation for acute and early failure of sutureless pericardial aortic valve. *Can J Cardiol.* 2015;31:1204.e13-1205.
99. Kang DH, Kim YJ, Kim SH, et al. Early surgery versus conventional treatment for infective endocarditis. *N Engl J Med.* 2012;366:2466-2473.
100. Nappi F, Spadaccio C, Chello M. Aortic homografts: should we really lose the opportunity? *J Thorac Cardiovasc Surg.* 2019;157:e245-e246.
101. Kirklin JK. Challenging homografts as the holy grail for aortic valve endocarditis. *J Thorac Cardiovasc Surg.* 2016;151:1230-1231.
102. Kang DH, Lee S, Kim YJ, et al. Long-term results of early surgery versus conventional treatment for infective endocarditis trial. *Korean Circ J.* 2016;46:846-850.
103. Ozaki S, Kawase I, Yamashita H, et al. A total of 404 cases of aortic valve reconstruction with glutaraldehyde-treated autologous pericardium. *J Thorac Cardiovasc Surg.* 2014;147:301-306.
104. Nappi F, Singh SSA, Lusini M, Nenna A, Gambardella I, Chello M. The use of allogenic and autologous tissue to treat aortic valve endocarditis. *Ann Transl Med.* 2019;7:68.
105. Mokhles MM, Rajeswaran J, Bekkers JA, et al. Capturing echocardiographic allograft valve function over time after allograft aortic valve or root replacement. *J Thorac Cardiovasc Surg.* 2014;148:1921-1928.e3.
106. Elgharably H, Hussain ST, Shrestha NK, Blackstone EH, Pettersson GB. Current hypotheses in cardiac surgery: biofilm in infective endocarditis. *Semin Thorac Cardiovasc Surg.* 28:56-59.
107. Acar C. Monobloc or separate aortic and mitral homografts? *J Thorac Cardiovasc Surg.* 2006;132:442-443; author reply 3.
108. Steffen V, Marsch G, Burgwitz K, Kuehn C, Teebken OE. Resistance to infection of long-term cryopreserved human aortic valve allografts. *J Thorac Cardiovasc Surg.* 2016;151:1251-1259.
109. Camiade C, Goldschmidt P, Koskas F, et al. Optimization of the resistance of arterial allografts to infection: comparative study with synthetic prostheses. *Ann Vasc Surg.* 2001;15:186-196.
110. Kuehn C, Graf K, Mashaqi B, et al. Prevention of early vascular graft infection using regional antibiotic release. *J Surg Res.* 2010;164:e185-e191.
111. Zander J, Maier B, Zoller M, et al. Effects of biobanking conditions on six antibiotic substances in human serum assessed by a novel evaluation protocol. *Clin Chem Lab Med.* 2016;54:265-274.
112. Vogt PR, Brunner-LaRocca HP, Lachat M, Ruef C, Turina MI. Technical details with the use of cryopreserved arterial allografts for aortic infection: influence on early and midterm mortality. *J Vasc Surg.* 2002;35:80-86.
113. Vogt PR. Arterial allografts in treating aortic graft infections: something old, something new. *Semin Vasc Surg.* 2011;24:227-233.
114. Yap CH, Yui M. Allograft aortic valve replacement in the adult: a review. *Heart Lung Circ.* 2004;13:41-51.
115. Brennan JM, Edwards FH, Zhao Y, et al. Long-term safety and effectiveness of mechanical versus biologic aortic valve prostheses in older patients: results from the society of thoracic surgeons adult cardiac surgery national database. *Circulation.* 2013;127:1647-1655.
116. Wong CHM, Chan JSK, Sanli D, Rahimli R, Harky A. Aortic valve repair or replacement in patients with aortic regurgitation: a systematic review and meta-analysis. *J Card Surg.* 2019;34:377-384.
117. Moriyama N, Laakso T, Biancari F, et al. Prosthetic valve endocarditis after transcatheter or surgical aortic valve replacement with a bioprosthesis: results from the finn valve registry. *EuroIntervention.* 2019;15: e500-e507.
118. Bashir M, Harky A, Bleetman D, et al. Aortic valve replacement: are we spoiled for choice? *Semin Thorac Cardiovasc Surg.* 2017;29:265-272.