

Conchal Excision Techniques in Otoplasty: A Literature Review

Adrian Georg Mogl*
 Alen Palackic, MD*†
 Janos Cambiaso-Daniel, MD*
 Robert P. Duggan, BS†
 Monica Vappiani, MD‡
 Camilla Giraudi§
 Edoardo Raposio, MD, PhD‡
 Dario Bertossi, MD¶
 Alessandro Gualdi, MD, PhD§

Background: Prominent ears are a common congenital deformity of the head and neck. Correcting concha hypertrophy is an important step in otoplasty. Despite the risk of postoperative deformity due to the sharp edges created by excision, removing a section of cartilage is sometimes the only method to obtain a satisfying and long-lasting result. Multiple conchal excision techniques have been reported in the literature, with significant differences in approach, outcome evaluation, and complication classification. The objective was to review cartilage excision-based otoplasty procedures to offer plastic surgeons' insights into current data on outcomes and complications of conchal excision techniques.

Methods: We conducted a literature search through the MEDLINE, EMBASE, Scopus, and Cochrane databases. Prospective and retrospective studies on otoplasty, including revision surgeries and conchal excision techniques involving concha cartilage resection, were included. Articles with no outcomes data, review articles, case reports, expert opinion or comment, and nonclinical studies were excluded.

Results: There were a total of four manuscripts that fulfilled our criteria. Three out of four authors preferred posterior access that separates the skin excision from the cartilage excision. Following resection, cartilage edges can be approximated by placing cartilage sutures, or they can be allowed to collapse spontaneously. Although only two authors employed a systematic classification for complications, all the articles reviewed indicated a low complication rate and excellent postoperative cosmetic outcomes.

Conclusion: Although the techniques and principles stated in the literature varied to some extent, the outcomes of all studies reviewed were comparable. (*Plast Reconstr Surg Glob Open* 2022;10:e4381; doi: [10.1097/GOX.0000000000004381](https://doi.org/10.1097/GOX.0000000000004381); Published online 15 June 2022.)

INTRODUCTION

Prominent ears are a common congenital deformity of the head and neck region, affecting up to 5% of the population. Although this deformity has no physiological consequences, surgical correction is frequently requested due to its social significance. Patients with prominent

ears reportedly are more prone to developing psychosocial problems related to their appearance, including psychological distress, emotional trauma, and behavioral disorders.¹⁻³

The anatomic origin of prominent ears centers on the underdevelopment of the antihelical fold and overdevelopment of the conchal wall, either independently or in combination.^{4,5} According to La Trenta et al,⁶ three anatomical goals must be kept in mind during corrective prominent ears surgery: (i) production of a smooth, rounded, and well-defined antihelical fold; (ii) a conchoscaphal angle of 90 degrees; and (iii) conchal reduction or reduction of the conchomastoidal angle (Fig. 1). In recent decades, establishing the correct shape of the antihelical fold became the primary focus, minimizing the role of conchal hypertrophy in causing ear protrusion.⁷ Through a variety of suturing and excisional techniques, conchal cartilage manipulation is commonly part of otoplasty. These techniques, in particular, have the advantage of producing long-lasting results but risk less-predictable results with the potential for producing sharp cartilaginous edges or ridges, which could lead to postoperative

From the *Division of Plastic, Aesthetic and Reconstructive Surgery, Department of Surgery, Medical University of Graz, Graz, Austria; †Department of Surgery, University of Texas Medical Branch, Galveston, Tex.; ‡IRCCS Ospedale Policlinico San Martino, DISC, University of Genova, Italy; §University Vita-Salute San Raffaele, Milan, Italy; and ¶Department of Maxillo-Facial Surgery, University of Verona, Verona, Italy.

Received for publication December 16, 2021; accepted April 27, 2022.

Drs. Mogl and Palackic contributed equally to this work.

Copyright © 2022 The Authors. Published by Wolters Kluwer Health, Inc. on behalf of The American Society of Plastic Surgeons. This is an open-access article distributed under the terms of the [Creative Commons Attribution-Non Commercial-No Derivatives License 4.0 \(CCBY-NC-ND\)](https://creativecommons.org/licenses/by-nc-nd/4.0/), where it is permissible to download and share the work provided it is properly cited. The work cannot be changed in any way or used commercially without permission from the journal.

DOI: [10.1097/GOX.0000000000004381](https://doi.org/10.1097/GOX.0000000000004381)

Disclosure: The authors have no financial interest to declare in relation to the content of this article.

deformity.^{8,9} In addition, the standard complications of any invasive surgery, such as infections, hematomas, or abnormal scarring, can occur. Cartilage-sparing otoplasty is an alternative approach where ear contouring is achieved through permanent or absorbable sutures, by fixing the concha to the mastoid. Furthermore, from the many different techniques that have been published, only a handful have had a scientific basis, with data on follow-up, outcomes, and complications. Therefore, this article aims to provide insights into outcomes and complications of otoplasty procedures using conchal excision techniques to describe the risk-benefit ratio of conchal excision-based otoplasty.

SEARCH STRATEGY AND SELECTION CRITERIA

A literature search was performed across MEDLINE, EMBASE, Scopus, and Cochrane databases in March 2021 using following Mesh terms: “otoplasty OR prominent,” “ear surgery OR prominent ear correction,” AND “complications OR outcomes.” We selected only English language manuscripts published since 2001. Prospective and retrospective studies on otoplasty, including revision surgeries and conchal excision techniques involving concha cartilage resection, were included. Articles reporting surgical technique exclusively with no outcomes data, review articles, case reports, expert opinion or comment, and nonclinical studies were excluded (Fig. 2).¹⁰⁻¹³

Results

A total of 24 full text articles of potentially relevant studies were identified using the above-mentioned Mesh terms. Of these, eight studies were excluded for not

Takeaways

Question: By reviewing the literature on the outcomes and complications of cartilage-cutting conchal reduction, what is the risk-benefit ratio of this type of technique?

Findings: Although the techniques and principles detailed in the literature differ to some extent, all of the studies we examined achieved low complication rates and excellent postoperative aesthetic results.

Meaning: If a surgeon is skilled enough in the technique, cartilage cutting otoplasty might be preferred over cartilage-sparing otoplasty.

reporting outcomes or complications. Thirteen studies were excluded for not using conchal cartilage resection and three studies had nonextractable data on complications and outcomes following conchal cartilage resection and were excluded. The remaining four selected articles were reviewed in detail. We explored the different surgical approaches, the outcomes for each approach, and the complications that followed (Fig. 3).

Analgesia

All procedures were performed using local anesthesia; however, while Bauer et al and Obadia et al describe infiltrating the ears with a lidocaine and epinephrine solution, Gualdi et al noted that using local anesthetic with adrenalin for the internal area of the ear is not recommended because it raises the risk that superficial cutaneous necrosis may occur.^{10,12,13} Furthermore, bilateral great auricular nerve blocks with bupivacaine can also be performed for postoperative analgesia.¹⁰

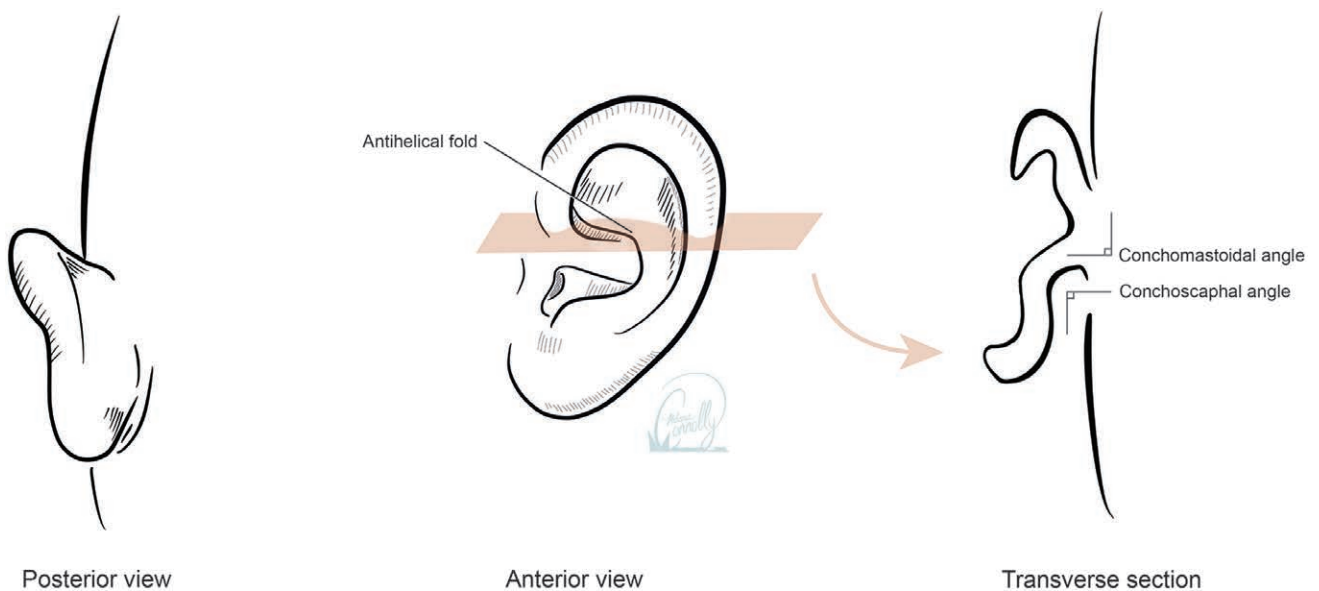


Fig. 1. Overview of the ear and transverse section. Transverse section illustrating the conchomastoidal and conchoscaphal angles. A conchoscaphal angle of 90 degrees and the reduction of the conchomastoidal angle correct prominent ear deformities. Reprinted with permission from UTMB. © 2021 The Board of Regents of the University of Texas System. Copyright used with the permission of The Board of Regents of the University of Texas System through The University of Texas Medical Branch.

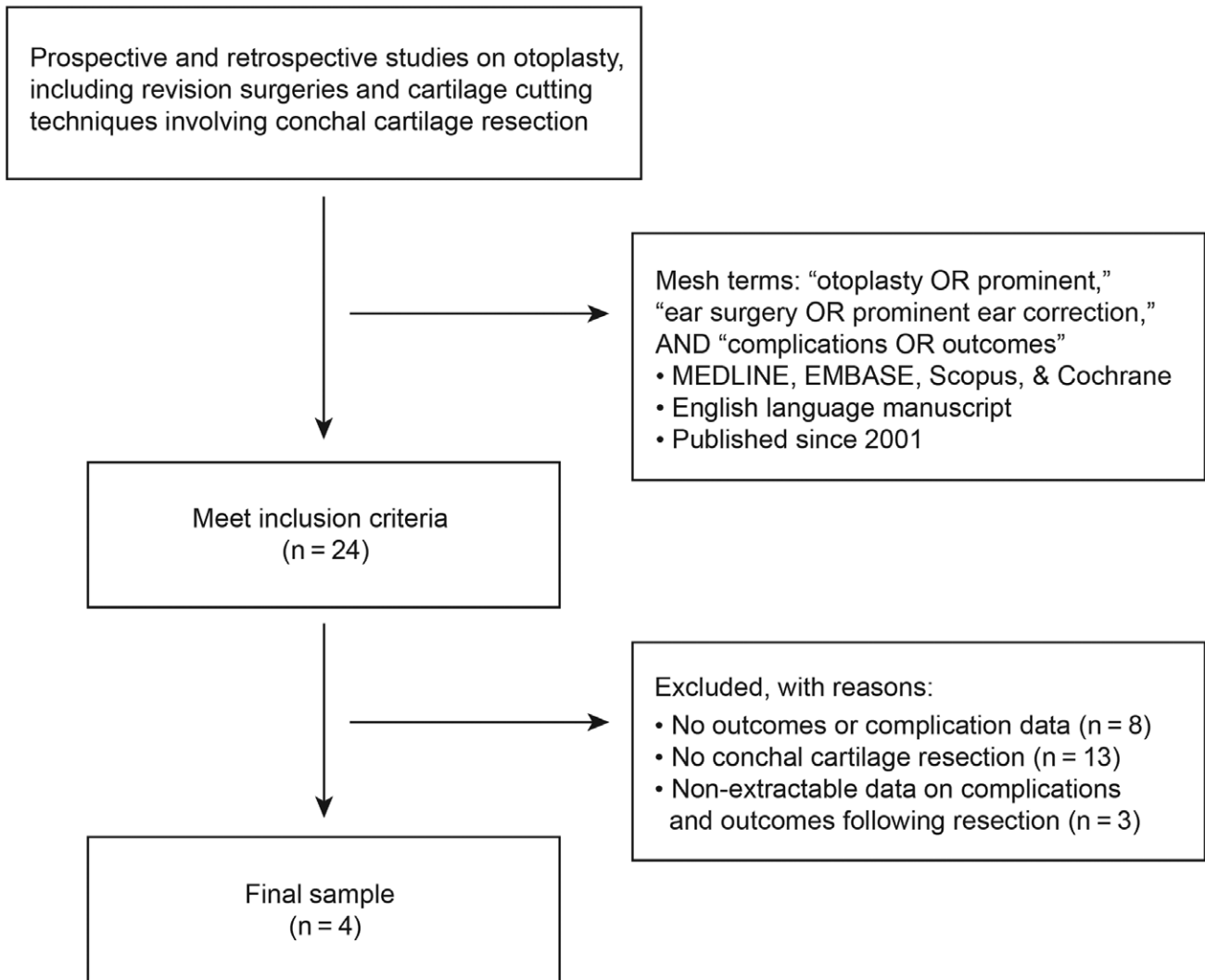


Fig. 2. Flow chart illustrating search strategy, inclusion, and exclusion criteria.

Surgical Techniques

All studies included techniques involving conchal cartilage resection to correct conchal hypertrophy.¹⁰⁻¹³

Incision

Only the study by Bauer et al details an anterior approach with a direct chondrocutaneous excision.¹⁰ Three authors performed conchal reduction through a posterior incision after dissection and removal of a small segment of skin.¹¹⁻¹³

For the anterior approach, Bauer et al use an anterior incision within the concha at the point where the lateral conchal floor meets the posterior conchal wall. This incision runs through the anterior skin and conchal cartilage but stops just short of the posterior conchal skin. After that, the authors utilize sharp dissection to remove soft tissue and skin from the posterior surface of the conchal bowl.¹⁰ Finally, to allow for tension-free skin closure, a crescent moon-shaped chondrocutaneous portion is removed, as well as more cartilage than skin (Fig. 4).¹⁰ Bauer et al

are the only authors who report using nylon suture to approximate the edges after cartilage removal.¹⁰

For the posterior approach, after the local anesthetic was administered, an incision is made between the conchal and mastoidal skin with a no. 15 scalpel.¹³ The medial incision is made 3 mm from the postauricular sulcus and extends from the conchae cyma to the intertragal sulcus.^{12,13} This distance must be maintained to ensure sufficient skin to reattach the two skin margins afterward.¹³ Preoperatively, the size of the incision, and thus the amount of cartilage that must be removed, is determined by applying digital pressure to the antihelix while assessing the excess of conchal cartilage.¹³ Gualdi et al advise prior otoplasty experience for this procedure and emphasize that the lateral section of the incision should be kept 5–10 mm away from the medial incision. This produces a skin incision that is no more than 5–10 mm in width. After the skin is cautiously removed, while excising the cartilage, the edges must be rounded and less sharp to avoid future complications and unappealing results. The demarcated

Authors	Bauer et al	Kompatscher et al	Obadia et al	Gualdi et al
Year	2002	2004	2013	2018
Anesthesia	General & local anesthesia with adrenalin into anterior & posterior auricular surface	Local anesthesia	General anesthesia & local anesthesia with adrenalin into posterior area of pinna & mastoid	Local anesthesia; retro auricular with adrenalin; internal auricular area without adrenalin
Incision	Anterior	Posterior	Posterior	Posterior
Cartilage Resection	Crescent-shape segment	Crescent-shape segment	Crescent-shape segment	Bilobed shape plus two equilateral triangles approach
Postoperative Care	Bacitracin ointment, gauze + fluff dressings & gauze head wrap	Not specified by authors	Bolster dressing & head bandage dressing for 4–5 days postoperative	Bolster dressing & head bandage dressing for 7 days postoperative
Number of Patients	47	14	58	60
Average Age	7.2 years	10 years	16 years	24.3 years
Follow-up Period	6 months–7 years	>6 months	>12 months	17.2 months
Outcome Assessment	Patient-parent questionnaire after 6 & 12 months	VAS, Strasser's grading system	Visual analog scale ranging from 1 (very poor) to 10 (excellent)	Patient questionnaire containing five questions ranging from 1 (very poor) to 5 (very good) after 12 months
Outcome	Satisfactory outcome for all patients	<ul style="list-style-type: none"> • VAS rating: 71% score 1–2 • VAS surgeon rating: 21% score 1–2 • Strasser grading system: 80% asymmetry, 57% protruding upper pole, 50% general under-correction 29% protruding ear lobe 	Average plastic surgeon rating: 7.68 Average lay observer rating: 8.24 Average patient rating: 8.84	Average score: 4.72
Classification for Complications	No classification	No classification	Classification into early complication (<15 days postoperative) or late complications (>15 days postoperative) and major complications	Clavien Dindo classification
Complications	3 (6.4%) relapses with secondary correction	1 case of hematoma	6 patients (10%) with a complication 1 early complication (hematoma) No major complications	Grade I: 2.5% Grade IIIa: 0.83%

Fig. 3. Overview of articles meeting inclusion criteria. Surgical approach, conchal resection technique, and postoperative care are detailed. Patient demographics and outcomes are also reported.

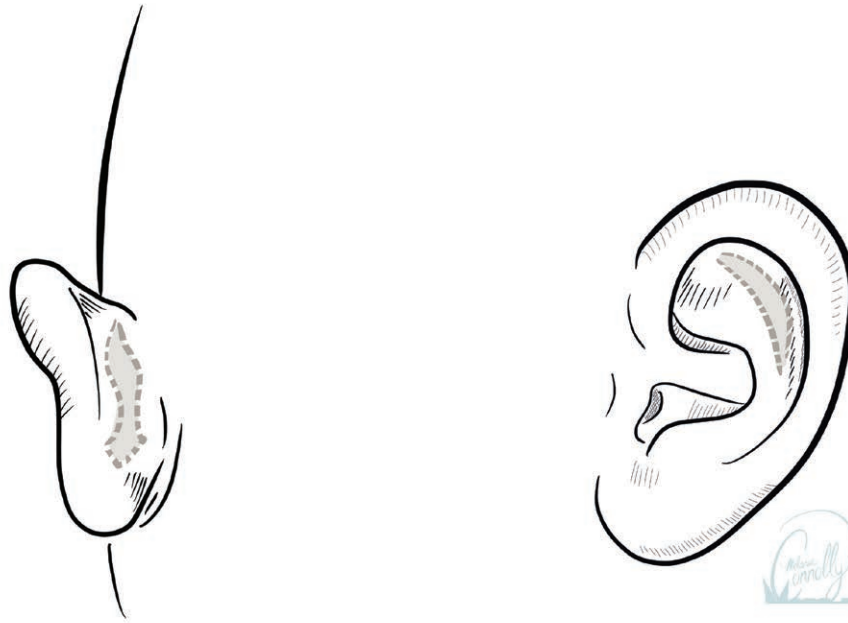
piece of extra concha cartilage can then be removed using a precise subperichondrial dissection of the cartilage from the anterior concha skin.¹³

Cartilage Resection

In all the articles, cartilage is resected as a crescent-shape segment (Fig. 5) except in one case, where the conchal reduction is achieved by resecting a

bilobed-shape piece of cartilage plus two equilateral triangles.^{10–13} For crescent-shape segment resections, the posterior auricular muscle is cut, the premastoid tissue removed, and the caudal part of the helix dissected and removed.¹²

Obadia et al explain that the cartilage is incised on its backside, retaining the anterior skin. The external boundary of the concha is traced with hypodermic needles, and



Bauer, posterior approach

Bauer, anterior approach

Fig. 4. This figure illustrates the Bauer approach. The “squid-shaped” skin incision pattern described by Bauer et al (left), allowing for suture placement to correct for lower pole prominence. Anterior incision described by Bauer et al (right) made at the junction of the lateral conchal floor and the posterior conchal wall. Depression of the helix highlights the chondral section to be removed through this incision. Reprinted with permission from UTMB. © 2021 The Board of Regents of the University of Texas System. Copyright used with the permission of The Board of Regents of the University of Texas System through The University of Texas Medical Branch.

the cartilage on its posterior face is sliced while the anterior skin is preserved. Subcutaneous dissection is then performed on the anterior side of the concha in the subperichondrial plane while the crescent-shaped piece of cartilage is resected (Fig. 6).

In Gualdi et al’s “bilobed shape plus two equilateral triangles approach” (Fig. 7),¹³ the excess concha cartilage is removed with a sharp dissector, with special care taken not to harm the skin of the anterior concha, as inadvertent dissection could compromise the skin’s dermal perfusion and increase the risk of skin necrosis. Scissors are then used to perform two parallel subperichondrial dissections of the implantation of the auricular cartilage on the skull, one cranial and one caudal. Caudal dissection is performed in the direction of the intertragic notch, while cranial dissection is performed in the direction of the conchae cyma. These techniques isolate the superior and inferior insertions of the auricular cartilage from the skull and the skin of the anterior concha, allowing the cranial and caudal triangular (the equilateral triangles) cartilage resection to be completed, causing the ear pavilion to collapse mechanically (Fig. 7).¹³ This collapse of the cartilage allows the surgeon to fix the new position of the ear in place and reduces the likelihood of recurrences.

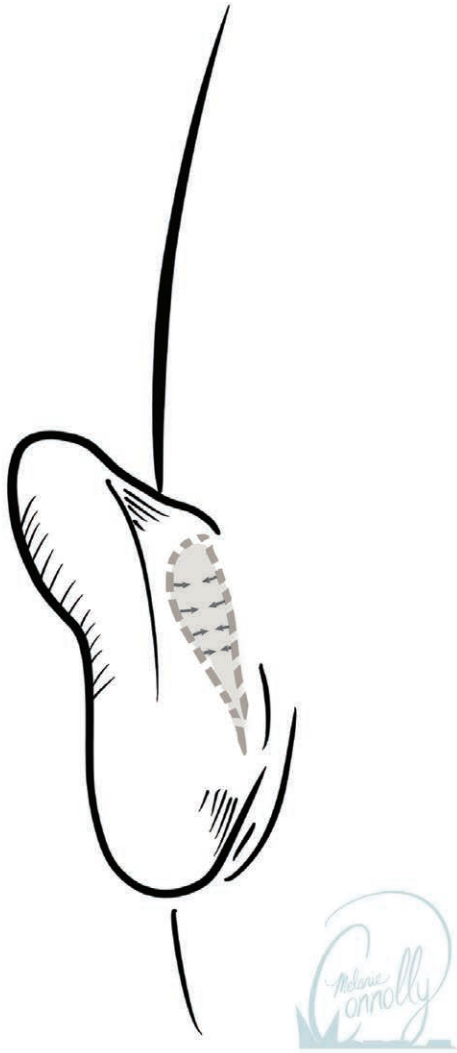
When the shape of the antihelix needs to be improved, a supraperichondrial dissection of the posterior antihelix is performed with scissors, through the same incision. The scalpel is used to make a cartilage incision at the cranial edge of the scaphoid fossa, allowing anterior dissection of the antihelix from the skin.¹³

Sutures

Bauer et al described closing the posterior squid-shaped defect with 5-0 chromic sutures after multiple helical sulcus and scapha to mastoid sutures are placed, generating a smooth antihelical fold. Finally, based on the appropriate contour, shape, and projection of the lobule, the author explains altering the placement of the initial suture in the diamond-shaped inferior region of the squid. A running 5-0 chromic suture is then used to complete the remaining skin closure.¹⁰

To address the resulting dead space, Obadia et al connect the concha to the mastoid periosteum with absorbable sutures (PDS 4.0; Ethicon, Johnson & Johnson Company, Cincinnati, Ohio), and an intradermal absorbable 4.0 running suture is used to close the skin.¹² Next, bolster dressings of petroleum gauze are tied over the antihelix reliefs and the concha with U-shaped transfixing sutures to reduce the risk of hematoma formation (Fig. 6).¹²

Gualdi et al described placing sutures on the anterior skin, piercing through skin and cartilage posteriorly on both ends of the excision defect and then sutured anteriorly. They employed 3-0 Prolene sutures for a less painful and easy removal, producing less traction throughout the procedure to prevent cartilage relocation. After that, the skin was closed using an absorbable 4-0 Monocryl (Ethicon) running suture after thorough hemostasis. Finally, the authors describe using three nonabsorbable sutures (3-0 Prolene; Ethicon, Inc., Somerville, N.J.) to secure bolster dressings made from dental cotton rolls to the ear, two in the concha and one perpendicular to the



Converse, posterior approach

Fig. 5. Illustration of the resection of a pear-shaped segment. The incision is made through the cartilage along the anterior and posterior limits of the pear-shaped segment. Then excess cartilage from the concha and the helix is excised. Reprinted with permission from UTMB. © 2021 The Board of Regents of the University of Texas System. Copyright used with the permission of The Board of Regents of the University of Texas System through The University of Texas Medical Branch.

newly created antihelical fold, to fill any dead space produced by the operation.¹³

Outcome and Follow-up

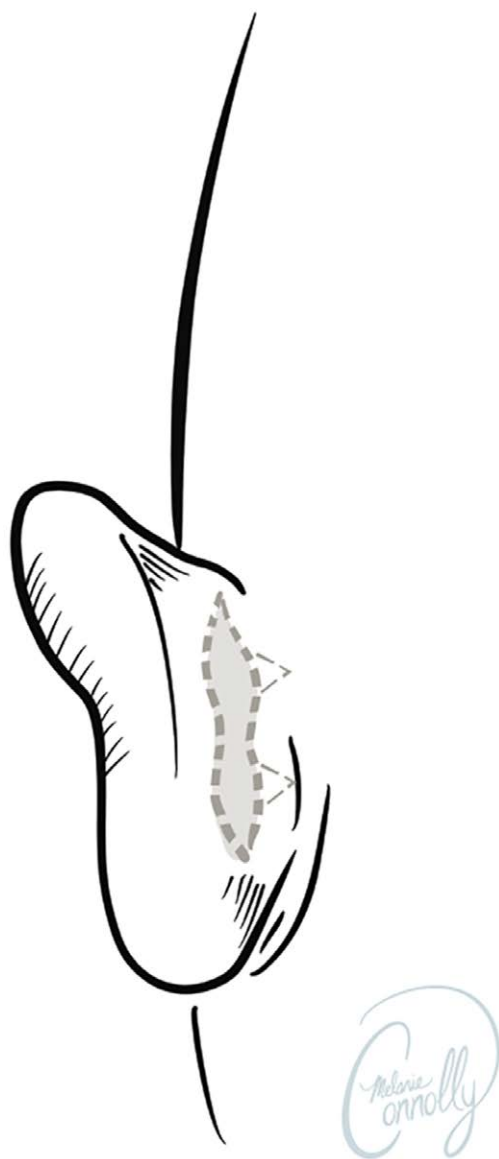
The follow-up period for the otoplasty procedures was at least 6 months in all studies, ranging from 6 months to 7 years. There was no consistent methodology for measuring surgical outcomes across the studies. The most common metric used was the visual analog scale.¹¹⁻¹³ One article did not report statistical results from patients and their parents regarding satisfaction with the surgery.¹⁰



Obadia, posterior approach

Fig. 6. Illustration of the Obadia approach. The posterior face is sliced while the anterior skin is preserved. Subcutaneous dissection is then performed on the anterior side of the concha in the subperichondrial plane, while the crescent-shaped piece of cartilage is resected. The concha is transfixed with U-shaped sutures to reduce the risk of hematoma formation. Reprinted with permission from UTMB. © 2021 The Board of Regents of the University of Texas System. Copyright used with the permission of The Board of Regents of the University of Texas System through The University of Texas Medical Branch.

Bauer et al¹⁰ performed 87 otoplasties on 47 patients (40 bilateral cases and seven unilateral cases) between January 1993 and August 2000. The average age of the patients was 7.2 years, with girls outnumbering boys (27 to 20). The authors reported a follow-up period ranging from 6 months to 7 years, with postoperative examinations at 2 weeks, 6 weeks, 3 months, and 6 months, and



Gualdi, posterior approach

Fig. 7. Illustration of the Gualdi approach with a “bilobed shape plus two equilateral triangles approach.” The bilobed-shaped excision first removes the excess concha hypertrophy, while the two equilateral triangles weaken the structure, causing the rest of the cartilage to collapse. This removes the “memory effect” from the cartilage, allowing the surgeon to fix the new position in place. The sutures are placed on the anterior skin, piercing through skin and cartilage posteriorly on both ends of the excision defect and then sutured anteriorly. Reprinted with permission from UTMB. © 2021 The Board of Regents of the University of Texas System. Copyright used with the permission of The Board of Regents of the University of Texas System through The University of Texas Medical Branch.

yearly examinations after that. All patients had a satisfactory outcome, as determined by questioning both patients and parents 6 months following surgery and again at the 1-year follow-up visit.¹⁰

Kompatscher et al¹¹ analyzed their surgical results using three different methods. As in the two previous studies, they used a visual analog scale ranging from 1 (excellent) to 5 (bad): the results show that in 71% of cases, patients gave a score of 1–2, whereas an independent observer surgeon gave a score of 1–2 in only 21% of cases. Another parameter was the assessment of two-ear symmetry after surgery: in this study, they measured the three cephaloauricular distances (superior, medial, and inferior) and compared differences between the right and left ear. The resulting differences were not significant.¹¹ The third method concerned evaluating unsatisfactory results or imperfections using Strasser’s grading system.¹⁴ Asymmetry was the most encountered flaw (80%), while the protruding ear lobe was the least appreciated (29%).¹¹

Obadia et al¹² examined 67 otoplasties from January 2004 to September 2010, ultimately excluding nine from their analysis. The authors noted the age at the time of the treatment, as well as any postoperative complications in the remaining population of 58 patients. Early (before postoperative day 15) and late (after postoperative day 15) complications, as well as major (requiring reoperation or postoperative antibiotics) and minor complications (requiring conservative treatment), were defined. Preoperative and postoperative images were evaluated by three lay observers and three plastic surgeons who were not involved in the procedure. On a visual analog scale ranging from 1 (very poor) to 10 (excellent), they rated the intervention’s overall aesthetic outcome. The authors then categorized the outcomes as unsatisfactory (score range: 1–5), satisfactory (score range: 6–7), or very satisfactory (score range: 8–10). The three plastic surgeons and the three lay observers reported no global aesthetic outcome score of less than 4. Plastic surgeons gave the results an average score of 7.68, lay observers gave them an average score of 8.24, and patients gave them an average score of 8.84.¹²

Gualdi et al¹³ included 60 patients (36 male and 24 female) with an average age of 24.3 years who had bilateral prominent ear correction with double triangular cartilage excision otoplasty. The average postsurgery follow-up time was 17.2 months.

Patient-reported outcomes were assessed with a questionnaire given 12 months after surgery. The questionnaire contained five questions graded on a linear scale from 1 (very poor) to 5 (very good). Ear symmetry, ear protrusion (angle to the skull), rehabilitation time, satisfaction with the result, and the decision for surgery were all addressed in the survey. All patients were pleased, particularly with the outcome, which scored 4.72 on average. On average, the operative time per ear was approximately 30 minutes, and sutures were removed 8 days after surgery.¹³

Complications

All four articles described the complications that occurred, following the otoplasty procedure using a conchal-excision based approach. Bauer et al¹⁰ report three complications requiring surgical intervention; all early partial upper-pole relapses during the first two months,

addressed with replacement scapha to mastoid sutures given under local anesthesia. There were no infections, auditory canal abnormalities, hematomas, keloids, or unsightly scars, and no late prominent recurrences.¹⁰

Kompatscher et al report a single hematoma that was treated conservatively.¹¹

The two other studies by Obadia et al¹² and Gualdi et al¹³ have used a systematic classification of complications.

Obadia et al¹² classified the complications as “early complications (before postoperative day 15) or late complications (postoperative day 15 or later) and as major complications (requiring reoperation or postoperative antibiotics) or minor complications (requiring conservative treatment).” They report that the only early complication was a small hematoma, which was punctured in the clinic and did not recur. Among the late complications was one case of external otalgia 2 months after the procedure, one case of inflammatory reaction due to absorbable suture, one case of delayed healing of the posterior incision requiring prolonged dressing use, one case of painful unilateral syndrome at three months resolving within the year, and one case of an ear compression wound. In total, six patients experienced a complication (10%). Moreover, the authors observed no severe complications (eg, extended necrosis or chondritis). There were no surgical revisions or recurrences reported. Three of the patients in this group had previously undergone otoplasty at a different facility to correct prominent ears. The recurrence was bilateral in two patients after Stenström otoplasty (one with keloid scars). The third patient’s recurrence was unilateral after anterior blind rasping and Mustardé otoplasty. One year after receiving the surgical technique described here, these three patients have had no recurrences. The keloid scars were eliminated during the procedure and have not resurfaced.¹²

Gualdi et al are the only ones that used the Clavien-Dindo classification, which consists of seven grades (I, II, IIIa, IIIb, IVa, IVb, and V). Grade I would include “any deviation from the normal postoperative course without the need for pharmacological treatment or surgical, endoscopic and radiological interventions”¹⁵ and grade V would be the patient’s death.¹⁵ In their report, three of the 120 ears (2.5%) experienced superficial cutaneous necrosis of the anterior concha after surgery, which reportedly resolved in 2 weeks.¹³ Furthermore, one ear (0.8%) required reoperation under local anesthesia due to inadequate pinna rotation. There were no reports on infections, hematomas, hypertrophic scars, allergic reactions, or paresthesia’s. According to the Clavien-Dindo classification, 2.5% of patients experienced a grade I complication, whereas 0.83% experienced a grade IIIa complication.¹³

DISCUSSION

This comprehensive review aimed to detail conchal excision-based otoplasty procedures with their follow-ups, outcomes, and complications. Various techniques for correcting prominent ears have been described over the years, and they are traditionally divided into cartilage

cutting and cartilage-sparing techniques. The former allows for cartilage removal and/or scoring. The correction achieved with these techniques is more permanent, but they are thought to be more prone to postoperative deformity due to the sharp edges created when the cartilage is cut. Cartilage-sparing techniques do not deal with conchal excess but achieve ear contouring through permanent or absorbable suture. This more conservative approach eliminates the potential for exposure of cut cartilage edges but risks a higher rate of recurrence.¹⁶ Correction of concha hypertrophy is a critical step in otoplasty. At times, the only way to achieve a satisfactory and long-lasting result is to remove a segment of cartilage, despite the risks.⁵

In this review, we discovered that three out of four authors prefer posterior access that separates the skin excision from the cartilage excision. Despite the authors’ preferences and criticism of the anterior approach to the concha as a potential source of keloid scars, there is no evidence of the superiority of one approach over the other in the literature.⁵

Following resection, cartilage edges can be approximated by placing cartilage sutures, as described by Bauer et al, or they can be allowed to collapse spontaneously, as documented by Gualdi et al.^{10,13} Both techniques produced satisfactory results, as evidenced by the authors’ reported outcome data.^{10,13} The main benefit of a cartilage-sparing otoplasty is that it is less prone to complications and has a lower risk of postoperative deformities.

A consistent classification system for complications, however, has yet to be introduced. While Bauer et al and Kompatscher et al used no systematic classification system, Obadia et al used their own, separating early, late, minor, and major complications, whereas Gualdi et al chose to use the Clavien-Dindo classification.

With this, Gualdi et al are among the first authors to utilize the aforementioned categorization in an aesthetic study. If future aesthetic surgery studies consider using the Clavien-Dindo classification system to compare the complication rates of different techniques adequately and systematically, as proposed by Gualdi et al, it will allow the literature describing various otoplasty techniques to be analyzed uniformly in an attempt to create a standard of patient care in the correction of prominent ears.¹³ All articles that were reviewed reported a low complication rate and excellent postoperative aesthetic results.

SUMMARY

With its long-lasting results, otoplasty using conchal excision is a reliable method for correcting prominent ears, showing high patient satisfaction rates and few complications. Although the techniques and principles described in the literature differ to some extent, all studies reviewed produced comparable results in outcomes and complications. In conclusion, the reviewed articles suggest that if a surgeon is skilled enough in the technique, conchal excision otoplasty might be preferred over cartilage-sparing otoplasty.

Janos Cambiaso-Daniel, MD

Auenbruggerplatz 29

8036 Graz

Austria

E-mail: j.cambiaso.daniel@gmail.com

ACKNOWLEDGMENT

We thank Melanie Connolly for creating the images.

REFERENCES

1. Temel M. Consolidative technique otoplasty: comprehensive approach in combining techniques. *Aesthetic Plast Surg.* 2016;40:822–831.
2. Macgregor FC. Ear deformities: social and psychological implications. *Clin Plast Surg.* 1978;5:347–350.
3. Bradbury ET, Hewison J, Timmons MJ. Psychological and social outcome of prominent ear correction in children. *Br J Plast Surg.* 1992;45:97–100.
4. Adamson PA, Strecker HD. Otoplasty techniques. *Facial Plast Surg.* 1995;11:284–300.
5. Janis JE, Rohrich RJ, Gutowski KA. Otoplasty. *Plast Reconstr Surg.* 2005;115:60e–72e.
6. La Trenta G. Otoplasty. In: Rees TD, LaTrenta GS, eds. *Aesthetic Plastic Surgery*. 2nd ed. Philadelphia, Pa.: Saunders; 1994: 891–921.
7. Bauer BS, Margulis A, Song DH. The importance of conchal resection in correcting the prominent ear. *Aesthet Surg J.* 2005;25:72–79.
8. Ordon A, Wolfswinkel E, Shauly O, et al. Aesthetic otoplasty: principles, techniques and an integrated approach to patient-centric outcomes. *Aesthetic Plast Surg.* 2019;43:1214–1225.
9. Schneider AL, Sidle DM. Cosmetic otoplasty. *Facial Plast Surg Clin North Am.* 2018;26:19–29.
10. Bauer BS, Song DH, Aitken ME. Combined otoplasty technique: chondrocutaneous conchal resection as the cornerstone to correction of the prominent ear. *Plast Reconstr Surg.* 2002;110:1033–1140; discussion 1041.
11. Kompatscher P, Schuler CH, Clemens S, et al. The cartilage-sparing versus the cartilage-cutting technique: a retrospective quality control comparison of the Francesconi and converse otoplasties. *Aesthetic Plast Surg.* 2003;27:446–453.
12. Obadia D, Quilichini J, Hunsinger V, et al. Cartilage splitting without stitches: technique and outcomes. *JAMA Facial Plast Surg.* 2013;15:428–433.
13. Gualdi A, Cambiaso-Daniel J, Gatti J, et al. Double triangular cartilage excision otoplasty. *Plast Reconstr Surg.* 2018;141:348e–356e.
14. Strasser EJ. An objective grading system for the evaluation of cosmetic surgical results. *Plast Reconstr Surg.* 1999;104:2282–2285.
15. Dindo D, Demartines N, Clavien PA. Classification of surgical complications: a new proposal with evaluation in a cohort of 6336 patients and results of a survey. *Ann Surg.* 2004;240:205–213.
16. Handler EB, Song T, Shih C. Complications of otoplasty. *Facial Plast Surg Clin North Am.* 2013;21:653–662.