



Exposing the glenoid in shoulder arthroplasty

Laurent Nové-Josserand¹

- Glenoid exposure should offer frontal access to the glenoid to allow the ancillary tools to be used freely and thus facilitate the good positioning of the glenoid implant.
- The two classically recognized approaches for shoulder arthroplasty are the deltopectoral and the transdeltoid approach.
- The axillary nerve is the most important anatomical structure in the glenoid, passing down the anterior part of the subscapularis, the inferior pole of the joint and the deep face of the deltoid muscle.
- Inferior glenohumeral release is the key step that allows the humerus to be retracted back or downwards thereby exposing the glenoid face on.
- In difficult and stiff cases, once pectoralis major release, osteophyte resection and posterior capsulectomy have been performed, a compression fracture, produced by using a retractor to push against the upper extremity of the humerus, can provide the extra few millimetres of space required to use the ancillary tools without hindrance.

Keywords: shoulder; arthroplasty; glenoid exposure; deltopectoral approach; transdeltoid approach

Cite this article: *EFORT Open Rev* 2019;4
DOI: 10.1302/2058-5241.4.180057

Introduction

Total shoulder arthroplasty is a reliable procedure with better outcomes than hemi-arthroplasty in terms of pain, subjective results, quality of life, strength and range of motion, even in the long term.¹ Glenoid exposure is the main difficulty involved and glenoid loosening remains a major problem for anatomical prostheses, whose survival rate has been assessed as 89% at ten years and 70% at twenty years.² These are the reasons why hemi-arthroplasty has often been preferred to treat osteoarthritis and explains why total arthroplasty is contraindicated in patients with a high risk of glenoid loosening: i.e. those at risk of early loosening because of rotator cuff tear; young, active patients with a risk of early wear from overuse; or those whose glenoid bone stock is too poor to secure the

prosthesis fixation. Glenoid exposure is also required for reverse shoulder arthroplasty and glenoid-associated complications are not uncommon, often because of poor implantation due to inadequate surgical exposure.^{3,4}

Anatomical considerations

The two classically recognized approaches for shoulder arthroplasty are the deltopectoral approach and the transdeltoid approach. In both cases, the glenoid is exposed following the same surgical principles, which require good anatomical knowledge because of its deep location. The glenoid's relationships with the different rotator cuff tendons and with the nerves, in particular the axillary nerve, are all important to know. The axillary nerve passes obliquely down the anterior face of the subscapularis muscle, before crossing the inferior pole of the glenohumeral joint (Fig. 1). In this location, the distance between the axillary nerve and the glenoid is in the range of 10 to 25 mm.⁵ This separation increases when the arm is placed in abduction or external rotation. Posteriorly, the axillary nerve crosses the scapulohumeral foramen and runs posteriorly to anteriorly along the undersurface of the deltoid muscle, which it supplies. It passes 5 cm to 7 cm from the lateral edge of the acromion, closer when the arm is abducted. The suprascapular nerve passes medially 15 mm to 20 mm from the superior edge of the glenoid cavity. The more medial anatomical structures are the musculocutaneous nerve, which crosses the conjoint tendon, and then the brachial plexus with the axillary vessels.

Key steps

The aim of glenoid exposure is to provide direct frontal access to the articular surface of the glenoid, allowing the ancillary tools to be used freely and ensuring the glenoid prosthesis is implanted under the best possible conditions and increase its survival rate. The approach proceeds in three successive steps:

First: arthrotomy by opening the rotator cuff. In the deltopectoral approach, an anterior arthrotomy is performed by opening the subscapularis muscle. This step is

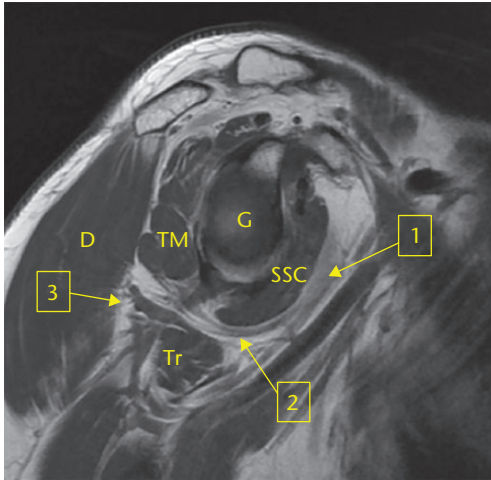


Fig. 1 Sagittal MR image of the shoulder, showing the anatomical relationships of the axillary nerve. The axillary nerve passes down the anterior part of the subscapularis muscle (SSC, arrow 1) and past the inferior pole of the glenoid (G, arrow 2) before reaching the deep face of the deltoid muscle (D, arrow 3). TM: teres minor; Tr: Triceps.

not justified in the transdeltoid approach because of the existing rotator cuff tear or fracture.

Second: resection of the humeral head to approach the glenoid and open the surgical space.

Third: reclining the humerus to allow a frontal approach to the glenoid cavity. In the deltopectoral approach, the humerus is pushed back, while in the transdeltoid approach, it is pushed down. This important step can only be performed once the inferior glenohumeral ligament is cut, as this is the anatomical structure that stabilizes the glenohumeral joint through a strong link between the humerus and the glenoid. The release of the lower part of the glenohumeral joint is the key step that allows the humerus to be dislocated and retracted to expose the glenoid face on.

Pre-operative planning

Pre-operative planning is important to identify conditions that may hinder the approach to the glenoid. Patients should be interviewed and receive a clinical work-up checking for a history of traumatic injury, open or arthroscopic surgery, and/or excessive joint stiffness or ankylosis. Pre-operative imaging examinations are performed, consisting of a frontal radiograph and MRI or a CT scan for horizontal analysis, searching for:

- glenoid wear in the frontal plane particularly superiorly, with a medial offset of the glenohumeral joint line;
- excessive glenoid retroversion, caused by asymmetric posterior erosion of the glenoid or dysplasia (type B or C in the Walch classification) (Fig. 2);⁶

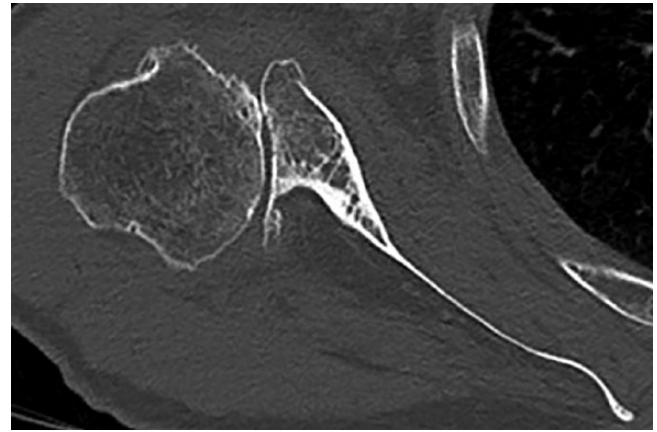


Fig. 2 Osteoarthritis with posterior subluxation. Transverse CT image. The posterior subluxation of the humeral head is associated with substantial posterior erosion of the glenoid (type C in the Walch classification), making glenoid exposure through the deltopectoral approach difficult.

- inferior, anterior or posterior glenoid osteophytes;
- poor glenoid bone stock;
- rotator cuff tears, which are a contra-indication for an anatomical prosthesis because of the risk of glenoid loosening. Reverse arthroplasty may be preferable in these cases.

Ultimately, the best approach depends on the aetiology, the outcome of the pre-operative clinical and radiological work-up, and the patient's co-morbidity factors and age.

Patient positioning

The 'beach chair' position is used for both the deltopectoral and transdeltoid approaches, with the patient's head held securely upright in a neutral position. The patient is placed on the edge of the operating table to free the shoulder and allow full and unhindered arm movements in all directions.^{7,8} A pad placed behind the spine of the scapula can be used to push the glenoid forwards, a position that makes posterior retractors easier to use by improving their support. Glenoid exposure is facilitated by the patient's muscles relaxing under anaesthesia.⁷

Deltopectoral approach

The skin is incised linearly and obliquely from the point of the coracoid process to the deltoid V, with a slight lateral offset to reduce the volume of soft tissue to retract. The cephalic vein is left laterally against the deltoid muscle. The coracoid apophysis and the conjoint tendon are identified and the clavipectoral fascia is incised. The sub-acromiodeltoid space is released to facilitate the subsequent mobilization of the humerus.^{7,8} This step is particularly

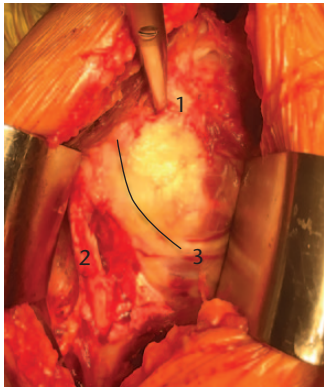


Fig. 3 Deltopectoral approach. Operative view of the subscapularis and its borders: the superior edge revealed by the scissors (1), the lateral edge with the brachial biceps (2), and the inferior edge with the horizontal anterior axillary vessels (3). Vertical tenotomy begins 1 cm from the lateral edge and follows the anatomical neck of the humerus (black line).

important in the presence of fibrosis, from prior surgery or traumatic injury, which eliminates this slip plane. The anterior bursa between the conjoint and subscapularis tendons is released with the arm adducted to loosen the conjoint tendon. The axillary nerve can be observed here at the anterior and/or inferior part of the subscapularis. Finally, if the joint is very stiff, the pectoralis major tendon can be partially or completely cut.^{7,8}

This exposure of the subscapularis allows the anterior arthrotomy to be performed. The arm is placed in external rotation with the elbow at the side, which reveals all the subscapularis and the surrounding structures: the bicipital groove laterally, the horizontal part of the subscapularis tendon above and the anterior axillary vessels at the inferior border (Fig. 3). The subscapularis opening can be performed according to preference, by vertical tenotomy, peeling the tendon away from the lesser tuberosity or osteotomy of the lesser tuberosity.⁹

Tenotomy

Vertical tenotomy, from top to bottom, should be performed about 1 cm from the humeral insertion of the subscapularis onto the lesser tuberosity.⁸ The inferior part curves medially around the humeral head and stops at the anterior axillary vessels, which are sutured. This preserves the inferior muscle fibres of the subscapularis and protects the axillary nerve. The tendon is repaired by direct or trans-osseous suture.

Peeling of lateral tenotomy

Peeling involves lifting the subscapularis tendon away completely from the lesser tuberosity, leaving the lower

part untouched, as does the tenotomy. Repair involves trans-osseous sutures beneath the bicipital groove. This technique facilitates healing by increasing the contact area between the tendon and the bone. It also stretches the subscapularis, which allows a better recovery of external rotation.

Osteotomy

Osteotomy of the lesser tuberosity is performed using a chisel or an oscillating saw, starting from the bottom of the bicipital groove and moving parallel to the subscapularis up to the anatomical neck of the humerus and over the entire lesser tuberosity. The arm is placed in adduction and internal rotation, which moves the axillary nerve away and relaxes the brachial plexus. The lesser tuberosity is reinserted using trans-osseous sutures beneath the bicipital groove.

The subscapularis is released in all three cases so that it can be moved freely. The upper part of the tendon is released beneath the coracoid apophysis. Depending on the stiffness of the joint, anterior capsulotomy is performed by section or resection of the middle glenohumeral ligament. The superficial face of the subscapularis should be released carefully given its proximity to the axillary nerve and its nerve supply on the anterior surface of the muscle should be preserved. The subscapularis is finally pushed back into the subscapular fossa using a retractor.

Inferior glenohumeral release is the key step that allows the humerus to be dislocated and retracted to facilitate the frontal exposure of the glenoid cavity. An appropriate intra-articular retractor (Trillat or Fukuda type) is placed on the posterior border of the cavity, tensioning the inferior glenohumeral ligament by pushing back the humeral head. The inferior capsuloligamentous plane is separated from the inferior plane of the subscapularis muscle, preserved in the previous step to protect the axillary nerve. The inferior capsuloligamentous plane is cut under visual control using dissecting scissors, towards the glenoid cavity and then along the inferior border of the cavity after making contact with the bone (Fig. 4).¹⁰ The inferior fibres of the subscapularis muscle protect the axillary nerve and keep it at a distance. This procedure can be made difficult by an inflamed synovium or blood in the joint.

The humerus is dislocated anteriorly with the arm in abduction, external rotation and the humeral head is then cut. Any retractors placed beneath the conjoint tendon must be removed before dislocating because they risk stretching the brachial plexus. Resecting the humeral osteophytes and releasing the inferior glenohumeral ligament from the neck of the humerus make it easier to move the humerus posteriorly, particularly when the joint is very stiff. The humerus is pushed back by placing a Hohmann retractor in the posterior part of the glenoid cavity.

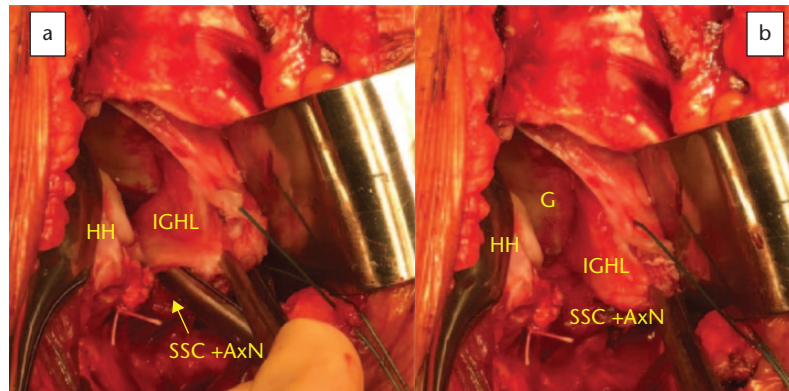


Fig. 4 Deltopectoral approach. Operative view during an inferior capsulotomy. (a) The humeral head (HH) is pushed back, tensioning the inferior glenohumeral ligament (IGHL), which is separated from the inferior part of the subscapularis muscle (SSC + axillary nerve) by the scissors. The axillary nerve (Ax N) is hidden and protected by the remaining lower part of the subscapularis muscle. (b) After cutting down to the glenoid (G), the undersurface of the subscapularis muscle is observed below, protecting the axillary nerve.

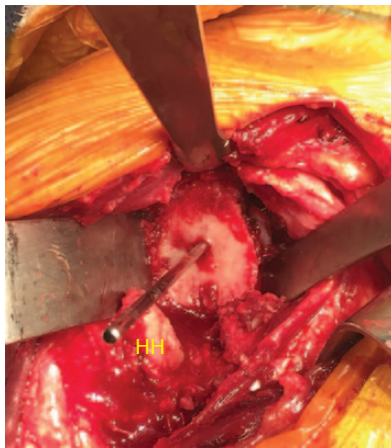

Fig. 5 Deltopectoral approach. Frontal operative view of the glenoid with a central pin. The posterior retractor (on the left) pulls the upper extremity of the humerus (HH) backwards, compressing the lesser tuberosity and completing the exposure of the glenoid.

The exposure of the inferior pole of the glenoid is optimized by placing the arm in internal rotation and slight abduction. The retractors should be re-positioned at this stage in the anterior and posterior scapular fossae. The full exposure of the glenoid is completed by placing a Hohmann retractor at the two poles of the glenoid, the inferior one protecting the axillary nerve. The humerus is pushed back by the retractor in the infraspinatus fossa (Fig. 5).⁷ The quality of the exposure depends on how easy it is to retract the humerus, facilitated by the inferior glenohumeral ligament release.

Special case of type B glenoids with posterior wear

Asymmetric posterior erosion of the glenoid (type B or C in the Walch classification) can make exposure difficult.¹⁰

Under these conditions, a complete circumferential capsulotomy has to be performed, along with a complete inferior capsulotomy up to the humerus with ablation of the inferior humeral and glenoid osteophytes. Exposure is optimized by abducting and rotating the humerus internally. If this is insufficient, a compression fracture can in some cases be provoked in the anterior part of the humerus at the lesser tuberosity by placing a retractor in the posterior scapular fossa against the humeral head. This compression fracture provides the extra space required to freely use the ancillary tools (Fig. 5). This ‘facilitating’ fracture does not reduce the primary stability of the humeral implant. Nevertheless, the procedure should be carefully controlled and requires a certain level of experience to avoid provoking a separation fracture, which complicates the surgery.

Advantages and disadvantages/indications for the deltopectoral approach

The deltopectoral approach has many advantages. It allows both anatomical and reverse prostheses to be implanted, in patients with and without rotator cuff tears, with traumatic or degenerative injuries, as an initial or revision procedure. The deltoid muscle is preserved. The inferior pole of the glenoid is well exposed, which is crucial for the good positioning of the glenoid implant, particularly in reverse arthroplasty. It is the preferred approach in cases of severe stiffness or glenohumeral ankylosis.

The deltopectoral approach also has disadvantages. The posterior part of the glenoid is only partially exposed when it is worn. This can lead to interference between the posterior retractor and the ancillary tools, making them more difficult to use. A badly positioned glenoid implant is more likely to come loose. This is why reverse arthroplasty should be considered in patients with severe glenoid retroversion. Glenohumeral instability can result

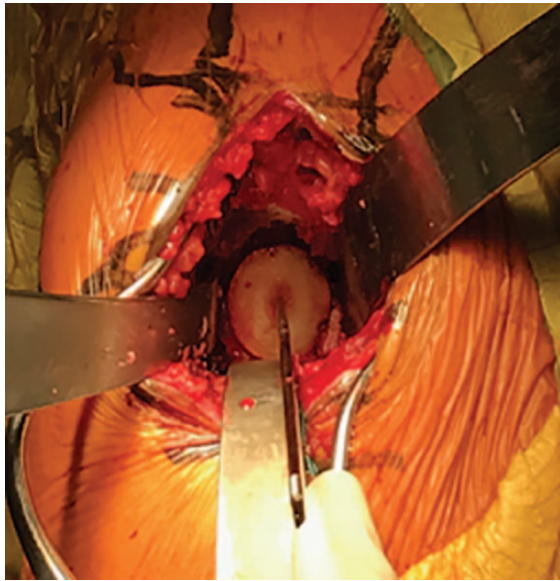


Fig. 6 Superolateral transdeltoid approach. Frontal operative view of the glenoid with a central pin. The inferior retractor pulls the (hidden) upper extremity of the humerus downwards, offering a complete exposure of the glenoid.

from inferior glenohumeral release⁴ or incomplete subscapularis healing, which can also lead to secondary glenoid loosening. The re-rupture rate after tenotomy varies substantially between studies with ultrasound assessment and is often asymptomatic.⁹ Peeling and tuberosity osteotomy have therefore been proposed as alternative techniques.⁹ Comparisons of the different techniques have not identified any as being superior.⁹ In spite of good osteotomy healing, progressive post-operative fatty infiltration of the subscapularis can lead to negative clinical outcomes. A subscapularis-sparing deltopectoral approach has therefore been proposed, either by passing through the subscapularis muscle, or by arthrotomy at the rotator interval.¹¹

Superolateral transdeltoid approach

A longitudinal skin incision of 5 cm to 9 cm is performed laterally from the anterolateral corner of the acromion or the acromioclavicular joint down along the deltoid muscle fibres between the anterior and lateral bundles.¹²⁻¹⁴ The deltoid muscle is likewise cut in the fibre direction between the anterior and lateral bundles. The deltoid is carefully raised at the acromion, subperiosteally or using bone chips to facilitate healing. The inferior part of the incision has to be performed with great care to avoid damaging the axillary nerve in the substance of the deltoid. The two muscle bundles are sutured using a stay suture to protect the nerve. A Hohmann retractor is placed on the coracoid process stretching forwards and another behind the humerus. A bursectomy has to be performed to free

the bursal plane between the deep face of the deltoid and the superior extremity of the humerus and make the humerus mobile. The condition of the rotator cuff is assessed, with a complete rupture of the superior part revealing the joint directly. Tenodesis of the long head of the biceps tendon is performed if the tendon is present. The anterior part of the joint and the subscapularis are exposed by positioning the humerus in flexion and external rotation. Extension and internal rotation expose the posterior part of the joint and the infraspinatus and teres minor tendons. The humerus is dislocated upwards and forwards with the arm extended. The humeral head is osteotomized. The amount resected should be sufficient to directly expose the glenoid cavity.³ Classically the humeral cut should extend to the inferior part of the glenoid while remaining compatible with the humeral implant.¹² Release proceeds with a circumferential resection of the labrum and a circumferential capsulotomy in contact with the bone, as in the deltopectoral approach, and is completed by cutting and resecting the coracohumeral and middle glenohumeral ligaments and releasing the subscapularis. The same procedure is carried out for the posterior labrum and the infraspinatus and teres minor muscles, if present. If the upper extremity of the humerus is fractured, the greater tuberosity is retracted back and the lesser tuberosity forwards, if necessary after performing a tenotomy in the rotator interval along the anterior border of the supraspinatus to separate the tuberosities.¹⁵

The inferior labrum and inferior capsule are resected from the bone. Placing a specific retractor beneath the inferior pole of the glenoid improves exposure by lowering the upper extremity of the humerus. The key to achieving sufficient lowering, thereby facilitating access to the glenoid, is the inferior release of the glenohumeral joint (Fig. 6).³ This should be performed carefully to avoid damaging the nearby axillary nerve at the inferior pole of the glenoid.¹⁴ The inferior nerve is generally not exposed at this stage of the intervention. If the exposure is inadequate, an additional humeral cut can be performed. However, excessive bone cutting is a risk factor for post-operative prosthesis instability by humeral shortening. In difficult cases, the same method described above can be used, namely carefully provoking a compression fracture using the inferior retractor to push against the upper extremity of the humerus. This provides the extra few millimetres of space required to use the ancillary tools without hindrance.

Advantages and disadvantages of and indications for the transdeltoid approach

The advantages of the transdeltoid approach are the ease of access to the glenoid cavity through the rotator cuff tear, the good glenoid exposure, particularly of the

posterior part, the sparing of the subscapularis muscle and the very low risk of implant instability.¹² It is the first-choice approach for traumatic injuries and in patients with degenerative diseases and massive rotator cuff tears.

The transdeltoid approach presents several disadvantages. Poor healing or damage to the axillary nerve at the bottom of the incision can result in deltoid muscle injury. The exposure of the inferior part of the glenoid, which is important for the positioning of the glenoid implant in reverse arthroplasty, is in some cases limited. Severe joint stiffness and the presence of inferior humeral and glenoid osteophytes are factors that further complicate the procedure. Insufficient retraction of the humerus prevents the direct use of the ancillary tools and increases the risk of mal-positioning the glenoid implant with a superior tilt, leading to poor clinical outcomes and/or secondary loosening.^{3,4,12} Fractures of the acromion (well tolerated) and of the spine of the scapula (poorly tolerated) have been reported.¹²

Conclusions

Glenoid exposure is a key step in total shoulder arthroplasty. This procedure should offer frontal access to the glenoid to allow the ancillary tools to be used freely and thus facilitate the good positioning of the glenoid implant. In both the deltopectoral and the transdeltoid approach, releasing the inferior part of the glenohumeral joint is the crucial step that ensures the humerus is mobile enough to adequately expose the glenoid. For reverse arthroplasty, comparisons of the deltopectoral and transdeltoid approach have not shown the superiority of either, highlighting the advantages and disadvantages of both.¹⁶ In this context and after careful pre-operative analysis, the best choice between the two approaches depends on the surgeon's experience.

AUTHOR INFORMATION

¹Ramsay Générale de Santé, Hôpital Privé Jean Mermoz, Centre Orthopédique Santy, Lyon, France.

Correspondence should be sent to: Dr Laurent Nové-Josserand, Centre Orthopédique Santy, 24 Avenue Paul Santy, 69008 Lyon, France.

Email: lnovejosserand.md@orthosanty.fr

ICMJE CONFLICT OF INTEREST STATEMENT

The author reports royalties from 3S Ortho.

FUNDING STATEMENT

No benefits in any form have been received or will be received from a commercial party related directly or indirectly to the subject of this article.

LICENCE

© 2019 The author(s)

This article is distributed under the terms of the Creative Commons Attribution-Non Commercial 4.0 International (CC BY-NC 4.0) licence (<https://creativecommons.org/licenses/by-nc/4.0/>) which permits non-commercial use, reproduction and distribution of the work without further permission provided the original work is attributed.

REFERENCES

- Sandow MJ, David H, Bentall SJ.** Hemiarthroplasty vs total shoulder replacement for rotator cuff intact osteoarthritis: how do they fare after a decade? *J Shoulder Elbow Surg [Am]* 2013;22:877-885.
- Raiss P, Ruckner T, Rickert M, Walch G.** Longitudinal observational study of total shoulder replacement with cement: fifteen to twenty-year follow-up. *J Bone Joint Surg [Am]* 2014;96-A:198-205.
- Laver L, Garrigues GE.** Avoiding superior tilt in reverse shoulder arthroplasty: a review of the literature and technical recommendations. *J Shoulder Elbow Surg* 2014;23:1582-1590.
- Boileau P.** Complications and revision of reverse total shoulder arthroplasty. *Orthop Traumatol Surg Res* 2016;102:533-543.
- Yoo JC, Kim JH, Ahn JH, Lee SH.** Arthroscopic perspective of the axillary nerve in relation to the glenoid and arm position: a cadaveric study. *Arthroscopy* 2007;23:1271-1277.
- Bercik MJ, Kruse K II, Yalozis M, et al.** A modification to the Walch classification of the glenoid in primary glenohumeral osteoarthritis using three-dimensional imaging. *J Shoulder Elbow Surg* 2016;25:1601-1606.
- Birmingham P, Sperling JW, Craig E.** Glenoid exposure in shoulder arthroplasty. *Tech Shoulder Elbow Surg* 2010;11:92-96.
- Gadea F, Bouju Y, Berhouet J, Bacle G, Favard L.** Deltopectoral approach for shoulder arthroplasty: anatomic basis. *Int Orthop* 2015;39:215-225.
- Rollins MD, Lapner PLC.** Surgical approach and dealing with the subscapularis in primary shoulder arthroplasty. *Tech Shoulder Elbow Surg* 2016;17:7-10.
- Mesiha M, Boileau P, Walch G.** Technique for reverse total shoulder arthroplasty for primary glenohumeral osteoarthritis with a biconcave glenoid. *JBJS Essential Surg Tech* 2013;3:e21.
- Lafosse L, Schnaser E, Haag M, Gobezie R.** Primary total shoulder arthroplasty performed entirely thru the rotator interval: technique and minimum two-year outcomes. *J Shoulder Elbow Surg* 2009;18:864-873.
- Molé D, Wein F, Dézaly C, Valenti P, Sirveaux F.** Surgical technique: the anterosuperior approach for reverse shoulder arthroplasty. *Clin Orthop Relat Res* 2011;469:2461-2468.
- Matsen FA III, Boileau P, Walch G, Gerber C, Bicknell RT.** The reverse total shoulder arthroplasty. *J Bone Joint Surg [Am]* 2007;89-A:660-667.
- Harrel KL, Puskas BL, Andersen J, Frankle M.** Reverse shoulder arthroplasty in the management of irreparable rotator cuff tears without arthritis. *JBJS Essential Surg Tech* 2011;1:e12.
- Grubhofer F, Wieser K, Meyer DC, et al.** Reverse total shoulder arthroplasty for acute head-splitting, 3- and 4-part fractures of the proximal humerus in the elderly. *J Shoulder Elbow Surg* 2016;25:1690-1698.
- Lädemann A, Lubbeke A, Collin P, et al.** Influence of surgical approach on functional outcome in reverse shoulder arthroplasty. *Orthop Traumatol Surg Res* 2011;97:579-582.