




# Symptomatic Cerebellar Cyst Formation after Foramen Magnum Meningioma Removal: A Case Report

Sho Hanai<sup>1</sup>  Kiyoyuki Yanaka<sup>1</sup> Kuniyuki Onuma<sup>1</sup> Kazuhiro Nakamura<sup>1</sup> Michihide Kajita<sup>1</sup>  
Hitoshi Aiyama<sup>1</sup> Eiichi Ishikawa<sup>2</sup>

<sup>1</sup> Department of Neurosurgery, Tsukuba Memorial Hospital, Kaname, Tsukuba, Ibaraki, Japan

<sup>2</sup> Department of Neurosurgery, Faculty of Medicine, University of Tsukuba, Amakubo, Tsukuba, Ibaraki, Japan

Address for correspondence Eiichi Ishikawa, MD, PhD, Department of Neurosurgery, Faculty of Medicine, University of Tsukuba, 1-1-1 Tennodai, Tsukuba, Ibaraki 305-8575, Japan (e-mail: e-ishikawa@md.tsukuba.ac.jp).

Asian J Neurosurg 2024;19:531–535.

## Abstract

**Background** Symptomatic cerebellar cyst formation after surgery is rare and the mechanism remains unknown. We describe a cerebellar cyst that gradually expanded, becoming symptomatic, after the removal of a foramen magnum meningioma and discuss the mechanism of cyst formation.

**Case Description** A 76-year-old woman with a tumor at the foramen magnum was treated by posterior fossa craniotomy and C1 hemilaminectomy. The patient suddenly developed cerebellar symptoms and consciousness disturbance approximately 1 week into an otherwise good postoperative course. Imaging showed a subcutaneous pseudomeningocele in the occipital region and cerebellar cyst formation. After resolution by fenestration of the cerebellar cyst and duraplasty, the patient's symptoms gradually improved. No tumor or cerebellar cyst recurrence has been detected in over 5 years since the surgery.

**Conclusion** Postoperative pseudomeningocele appeared crucial for cerebellar cyst formation. Postoperative development of symptomatic cerebellar cysts is rare but should be recognized as a serious, sometimes life-threatening, postoperative complication of posterior fossa surgery.

## Keywords

- ▶ cerebrospinal fluid
- ▶ craniotomy
- ▶ cyst
- ▶ one-way valve
- ▶ pseudomeningocele

## Introduction

Early complications after craniotomy include postoperative hemorrhage, cerebral edema, and epilepsy but pseudomeningocele may also commonly occur after posterior fossa surgery and spinal surgery.<sup>1,2</sup> It is characterized by epidural retention of cerebrospinal fluid (CSF) that leaks subcutaneously from the surgical wound but is rarely associated with cyst formation. While pseudomeningocele can be symptom-

atic, causing cosmetic problems, meningitis, or compression of the brain/nerve tissue, most cases are asymptomatic.<sup>3</sup>

Postoperative cyst formation in the brain parenchyma is a rare complication,<sup>4</sup> particularly in the cerebellum, and the formative mechanism is unknown. Here, we report a case of life-threatening cerebellar cyst formation after foramen magnum meningioma removal in which a pseudomeningocele in the posterior neck area formed postoperatively and appeared to associate with cyst formation. We also review the relevant

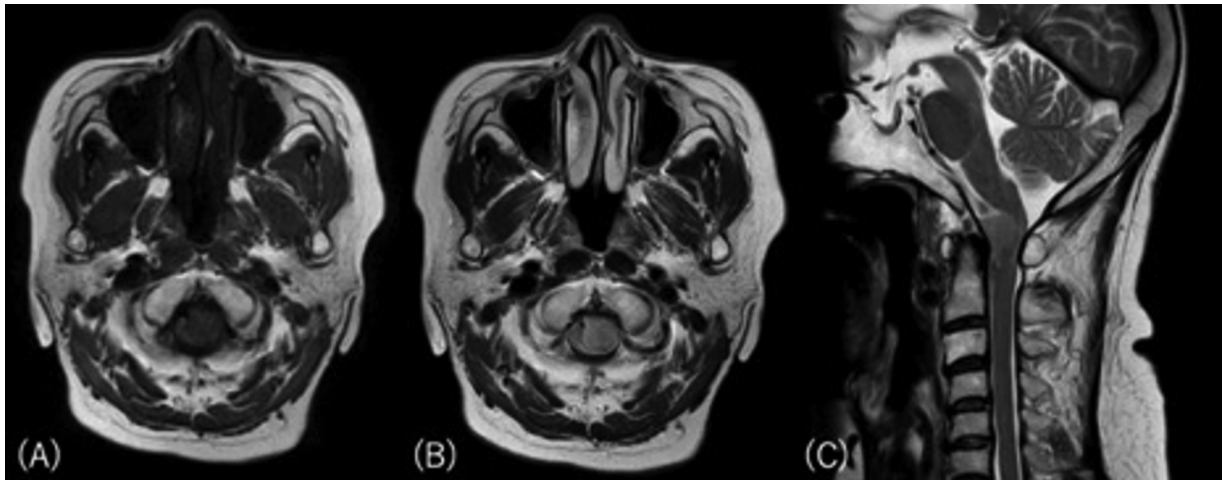
article published online  
July 11, 2024

DOI <https://doi.org/10.1055/s-0043-1776300>.  
ISSN 2248-9614.

© 2024. Asian Congress of Neurological Surgeons. All rights reserved.

This is an open access article published by Thieme under the terms of the Creative Commons Attribution-NonDerivative-NonCommercial-License, permitting copying and reproduction so long as the original work is given appropriate credit. Contents may not be used for commercial purposes, or adapted, remixed, transformed or built upon. (<https://creativecommons.org/licenses/by-nc-nd/4.0/>)

Thieme Medical and Scientific Publishers Pvt. Ltd., A-12, 2nd Floor, Sector 2, Noida-201301 UP, India



**Fig. 1** T1- (A) and T2-weighted (B, C) magnetic resonance images on admission, showing a round mass compressing the spinal cord at the foramen magnum.

literature and discuss potential mechanisms of cerebellar cyst formation.

### Case Description

A 76-year-old woman presented to her primary care physician with complaints of motor paresis of the left lower extremity for the previous 2 months. She was referred to us after imaging showed a mass in the foramen magnum.

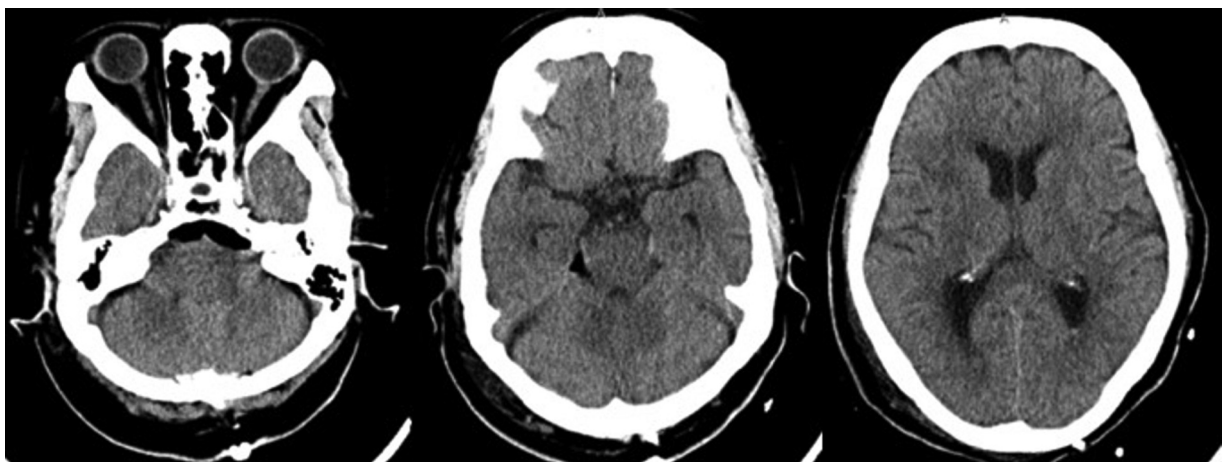
On admission, the patient was alert and well-oriented, with tetraparesis predominantly on the left side and gait disturbance. Laboratory tests were normal, except for a pattern of moderate renal failure (serum creatinine was 1.46 mg/dL and estimated glomerular filtration rate was 27.3). Magnetic resonance (MR) imaging revealed a mass in the foramen magnum that was compressing the spinal cord (→Fig. 1) but contrast enhancement studies were not performed due to the renal failure. The preoperative diagnosis was foramen magnum meningioma.

The patient underwent suboccipital craniotomy and C1 hemilaminectomy. The dura was opened slightly curvilinearly from the cerebellum to the superior margin of the

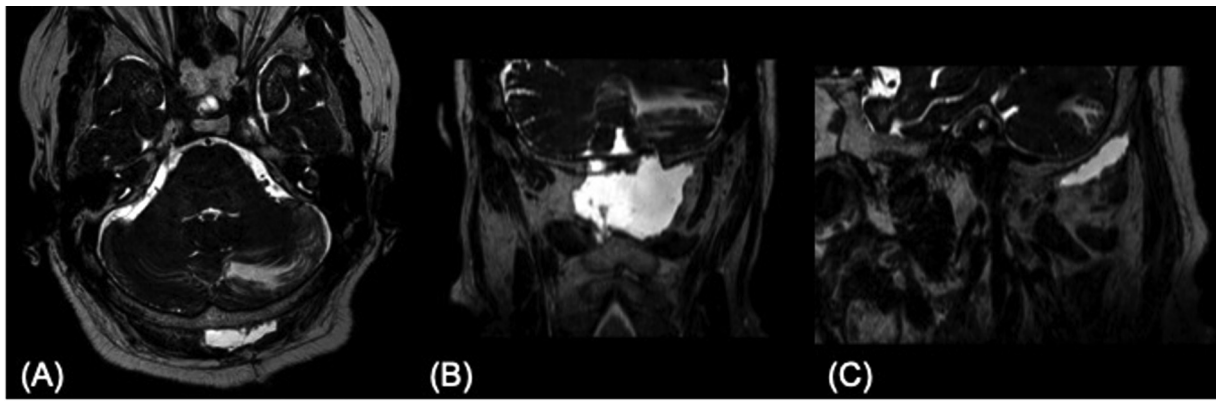
C2 lamina. The tumor originated from the dura in the anterior surface of the foramen magnum and was removed entirely via a transcondylar approach. The intraoperative course was uneventful and the dura mater was sutured with 4-0 nonabsorbable, sterile, surgical braided thread before fibrin glue spray was applied.

Computed tomograms on the first postoperative day showed no abnormalities or postoperative hemorrhaging or hydrocephalus (→Fig. 2). Postoperative recovery was good but, on the 7th postoperative day, the previously alert patient started complaining of mild dizziness and headache. Imaging studies showed a subcutaneous pseudomeningocele in the occipital region and cyst formation along the folia of the cerebellum (→Fig. 3). On the 8th postoperative day, the patient became comatose and computed tomograms showed a further enlarged cerebellar cyst compressing the brain stem and fourth ventricle, causing hydrocephalus (→Fig. 4).

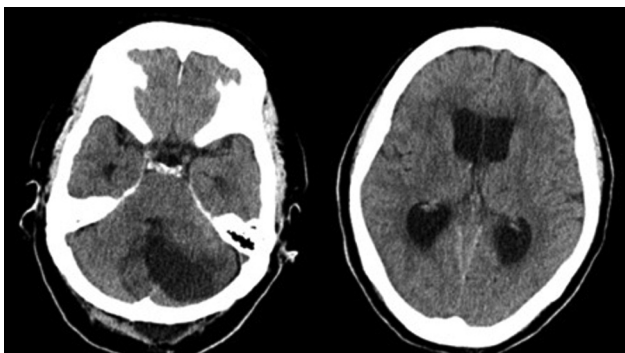
The patient underwent emergency surgery to achieve decompression of the brain stem by fenestrating the cerebellar cyst. Intraoperative findings showed a small gap in the dural suture over the cerebellum, allowing subcutaneous CSF to



**Fig. 2** Computed tomogram images taken on the 1st day after surgery showing there were no cerebellar hemorrhage or hydrocephalus.



**Fig. 3** Heavy T2 volume isotropic turbo spin echo acquisition magnetic resonance images of axial (A), coronal (B), and sagittal (C) taken on the 7th day after surgery showed there was cyst formation along the folia.



**Fig. 4** Computed tomogram images taken on the 8th day after surgery showed the cyst enlargement and worsening hydrocephalus.

enter the dura. A fenestration was made in the cerebellar cyst and CSF outflow was confirmed. The dura was again sutured watertight and fibrin glue spray was applied. Finally, a Valsalva maneuver was performed to ensure no CSF leakage.

After fenestration and duraplasty, the patient's symptoms gradually improved. The pathological diagnosis of the tumor was transitional meningioma. The patient underwent rehabilitation and was discharged 7 weeks postoperatively with only mild ataxia. No recurrence of the tumor or the cerebellar cyst has occurred for 5 years after surgery.

## Discussion

Postoperative symptomatic cyst formation in the cerebrum is occasionally encountered,<sup>5</sup> but cerebellar cysts are extremely rare. When arteriovenous malformations are managed with gamma knife surgery, cyst formation has been reported to be one of the most common complications.<sup>6</sup> Meanwhile, cases of cysts developing and enlarging in the same area after brain tumor resection have also been reported.<sup>5,7</sup> While the exact cause is unknown, multiple mechanistic factors have been proposed for intraparenchymal cyst formation depending on the clinical cause. Possible causes include increased permeability of the injured vessels, liquefaction due to coagulation necrosis, and breakdown of the blood-brain barrier.<sup>6</sup> With these putative causes, the mechanism may be the formation of a "valve"-like structure formed by repositioned brain tissue,

oxidized regenerated cellulose used for hemostasis, and arachnoid membrane in the roof area of the tumor resection cavity, creating a one-way flow of CSF to form the cyst.<sup>7</sup>

In our case, pseudomeningocele occurred postoperatively, a rare event since postoperative incidence is reported as 4.5% after neurological procedures.<sup>3</sup> These lesions are primarily occipital, with few supratentorial lesions reported. Pseudomeningocele formation is mainly from inadequate closure of the dura mater<sup>8</sup> that allows extradural accumulation of CSF and cystic enlargement.<sup>4</sup> There are scarce studies on how pseudomeningocele accumulates CSF within the brain parenchyma. However, since the dura mater was not sutured watertight in this case, postoperative epidural leakage may have been causative; the CSF that accumulated subcutaneously due to the one-way valve effect probably formed the pseudomeningocele.<sup>9</sup> However, the limited subcutaneous space and intraoperative glue applied to the dura prevented the pseudomeningocele from expanding, further increasing local epidural pressure. This acted as a high-pressure pump, propelling epidural CSF along the dural defect toward the cerebellum, spreading along the folia, and forming and expanding the cyst.

To our knowledge, only 12 cases of cerebellar cyst formation after neurosurgical procedures have been reported, including our patient (→ **Table 1**). Most cases were female (M: F = 4:8) and aged between 44 and 76 (average age of 57.9) years. Eight of these 12 cases were complicated by pseudomeningocele. These reports, similarly to ours, concluded that dural defects and small tears in the arachnoid and parenchyma of the cerebellum affect the one-way valve mechanism, causing CSF to accumulate in the cyst.<sup>3,4,8,9</sup> This emphasizes the CSF connection between the pseudomeningocele and the cyst, similar to our case.

Manley and Dillon reported three cases of cerebellar cysts after lumbar drainage for postoperative pseudomeningocele.<sup>10</sup> Those cases were characterized by the rapid formation of cysts after lumbar drainage, differing from our case in which the cyst expanded gradually. They speculated that the sudden pressure change in the posterior fossa caused by lumbar drainage was responsible for cerebellar cyst formation. On the other hand, four cases of simple cysts without complications of pseudomeningocele have been reported, with Wait et al mentioning

**Table 1** Summary of reported cases of the postprocedural symptomatic cerebellar cyst

Author/year	Case no.	Age/sex	Primary disease	Symptoms	Cerebellar cyst development	Pseudomeningocele	Treatment
Manley and Dillon 2000 <sup>10</sup>	1	63/M	Trigeminal neuralgia	Cerebellar symptoms	2 h	(+)	Cyst puncture
	2	48/F	Posterior fossa meningioma	Cerebellar symptoms	12 h	(+)	Shunt removal
	3	56/M	Epidermoid cyst	Cerebellar symptoms, coma	3 d	(+)	Lumber drainage clamping
Wait et al 2006 <sup>11</sup>	4	45/F	Pineal cyst	Cerebellar symptoms, headache	2 mo	(-)	Cyst fenestration
de Jong et al 2012 <sup>8</sup>	5	59/F	Cerebellar metastasis	Cerebellar symptoms, headache	3 mo	(+)	Cyst fenestration, duraplasty
	6	47/F	Cerebellar spongioblastoma	Cerebellar symptoms, headache	Several months	(+)	Cyst fenestration
Chiang and Lin 2015 <sup>3</sup>	7	69/F	Vestibular schwannoma	Coma	1 mo	(+)	Cyst fenestration, duraplasty
Sharif et al 2016 <sup>9</sup>	8	70/F	Vestibular schwannoma	Cerebellar symptoms, headache	1 mo	(-)	Cyst fenestration
Watanabe et al., 2019 <sup>4</sup>	9	68/M	Accessory neurinoma	Cerebellar symptoms	1 mo	(+)	Conservative
Cui et al 2020 <sup>12</sup>	10	50/M	Hemifacial spasm	Cerebellar symptoms	12 d	(-)	Cyst drainage
	11	44/F	Hemifacial spasm	Cerebellar symptoms	18 d	(-)	Conservative
Present case	12	76/F	Foramen magnum meningioma	Coma	7 d	(+)	Cyst fenestration, duraplasty

Abbreviations: d, day; F, female; h, hour; M, male; mo, month.

postoperative changes in venous return, while Cui et al inferred parenchymal brain damage due to over-retraction to the cerebellum.<sup>11,12</sup> Thus, there is no single mechanism for cerebellar cyst formation but rather a combination of several factors, including intraoperative brain injury, dural and arachnoid damage, and abrupt changes in posterior cranial fossa pressure gradients.

As seen in our case, optimal pseudomeningocele avoidance is achieved by elimination of CSF leakage from the dura. Small dural defects heal almost spontaneously, whereas large dural defects, inadequate soft tissue coverage, scar tissue, previous irradiation, infection, nutritional deficiencies, steroids, and elevated CSF pressure may delay dural defect recovery.<sup>13</sup> As the CSF water hammer effect is also associated with tissue detachment, cyst formation, and cyst enlargement,<sup>9</sup> it is, therefore, necessary to completely prevent CSF leakage by using various sealants (e.g., fibrin glue) and the Valsalva maneuver during dural suture, as well as protective brain manipulation during the operation. Additionally, if a pseudomeningocele occurs, they often improve with conservative treatments, such as compression dressings, and rest to keep the head elevated but intractable cases may require needle aspiration or lumbar drainage.<sup>3</sup> However, lumbar drainage should be performed cautiously because Manley and Dillon<sup>10</sup> reported that cerebellar cysts might form after lumbar drainage, worsening the condition. Surgical treatment is indicated if the pseudomeningocele becomes large enough to cause neuropathy.<sup>3</sup> If additional cerebellar cysts form, close monitoring is mandatory since coma can occur, requiring prompt surgical release of the cyst to relieve brain stem pressure as seen in our case and the case of Chiang and Lin.<sup>3</sup>

## Conclusion

As pseudomeningocele due to CSF leakage from the dura after craniotomy was likely causative for cerebellar cyst formation in our case, we recommend watertight dural closure as essential for prevention. Even if some patients may be asymptomatic with conservative treatment, vigilance against pseudomeningocele that leads to cerebellar cyst formation, although rare, is required.

### Note

This case report complies with the Declaration of Helsinki.

### Authors' Contributions

S.H. drafted this case report. K.Y. made the design of this case report and revised the report. K.O., K.N., M.K., and H.A. treated this patient and checked this report. E.I. revised the

report and advised the manuscript. All authors reviewed the final version of the case report.

### Conflict of Interest

None declared

### Acknowledgment

The authors would like to thank Alexander Zaboronok for professional and language revision.

## References

- Macki M, Lo SF, Bydon M, Kaloostian P, Bydon A. Post-surgical thoracic pseudomeningocele causing spinal cord compression. *J Clin Neurosci* 2014;21(03):367–372
- Menger R, Connor DE Jr, Hefner M, Caldito G, Nanda A. Pseudomeningocele formation following Chiari decompression: 19-year retrospective review of predisposing and prognostic factors. *Surg Neurol Int* 2015;6:70
- Chiang JY, Lin HL. Life-threatening posterior fossa cyst induced by pseudomeningocele after operation for acoustic neuroma. *Surg Neurol Int* 2015;6(suppl 2):S101–S103
- Watanabe Y, Higuchi Y, Sunaoka H, Yakufujiang M, Ikegami S, Iwade Y. Postoperative cerebellar cyst with pseudomeningocele after tumor removal at the craniovertebral junction. *World Neurosurg* 2019;130:71–76
- Korinth MC, Weinzierl MR, Krings T, Gilsbach JM. Occurrence and therapy of space-occupying cystic lesions after brain tumor surgery. *Zentralbl Neurochir* 2001;62(03):87–92
- Pan HC, Sheehan J, Stroila M, Steiner M, Steiner L. Late cyst formation following gamma knife surgery of arteriovenous malformations. *J Neurosurg* 2005;102(suppl):124–127
- Yu J, Xiong W, Qu L, Huang H. Reoperation as a result of raised intracranial pressure associated with cyst formation in tumor cavity after intracranial tumor resection: a report of two cases. *Case Rep Med* 2010;2010:634839
- de Jong L, Engelborghs K, Vandevenne J, Weyns F. Migrating pseudomeningocele causing posterior fossa syndrome. *Br J Neurosurg* 2012;26(04):537–539
- Sharif R, Moscovici S, Wygoda M, Eliahou R, Spektor S. Iatrogenic postoperative cerebellar cyst. *J Clin Neurosci* 2016;34:219–221
- Manley GT, Dillon W. Acute posterior fossa syndrome following lumbar drainage for treatment of suboccipital pseudomeningocele. Report of three cases. *J Neurosurg* 2000;92(03):469–474
- Wait SD, Feiz-Erfan I, Hanel RA, Ponce FA, Killory BD, Spetzler RF. De novo postoperative simple cerebellar cyst. *Barrow Quarterly* 2006;22:15–16
- Cui Y, Yang ZX, Wang CM, Zhu ZP. Appearance of cerebellar cyst following microvascular decompression to treat hemifacial spasm: a report of two cases and literature review. *J Int Med Res* 2020;48(07):300060520932118
- Tran DDT, Dinh TPH, Nguyen QB, Mai DT, Truong VT. Spontaneous resolution of postoperative giant frontal pseudomeningocele. *Asian J Neurosurg* 2021;16(02):372–375