

# Arthroscopic Labral Repair in the Setting of Recurrent Posterior Shoulder Instability



George Sanchez, B.S., Nicholas I. Kennedy, M.D., Márcio B. Ferrari, M.D., Sandeep Mannava, M.D., Ph.D., Salvatore J. Frangiamore, M.D., M.S., and CAPT Matthew T. Provencher, M.D., M.C., U.S.N.R.

**Abstract:** Posterior shoulder instability, although relatively rare in the general population, is more commonly seen in athletes, especially those in contact sports. Although nonoperative treatment has been associated with satisfactory results in the setting of posterior shoulder instability, conservative management may ultimately fail and lead to recurrence particularly in young, male patients. Both arthroscopic and open repair techniques to address posterior instability have been described, with each showing positive patient-reported outcomes, low risk of recurrence, and considerably high return-to-sport rates. In particular, arthroscopic treatment includes the following: capsular plication and knotted and/or knotless suture anchor fixation. The purpose of this technique is to describe our preferred technique to treat recurrent posterior shoulder instability through arthroscopic labral repair using knotless suture anchor fixation.

Given that posterior shoulder instability accounts for only 10% to 12% of all instability cases, it may be overlooked in patients with nonspecific symptoms; however, posterior shoulder instability is prevalent among certain athlete populations, particularly in contact sport athletes.<sup>1-4</sup> Aside from its rarity and vague clinical presentation, posterior instability is also particularly challenging as a result of its inconsistent and, at times, complex etiology. This inconsistency across cases of posterior instability is due to the wide array of causes leading to posterior instability, including acute trauma,<sup>5</sup> repetitive microtrauma,<sup>6</sup> and chronic insidious onset.<sup>5,7</sup>

Although many of these patients may do well with conservative treatment and will not require surgery, patients with a traumatic etiology resulting in instability have been shown to have poor results.<sup>4,8</sup> With more and more favorable outcomes reported after arthroscopic repair in the recent past, this treatment option for recurrent posterior shoulder instability is increasingly popular versus open repair. The purpose of this article is to describe our preferred technique to treat recurrent posterior shoulder instability through arthroscopic labral repair using knotless suture anchor fixation.

## Surgical Technique

### Preoperative Setup

To ensure the correct patient, extremity, and procedure, the operative extremity is marked with a surgical pen before treatment. Before being taken to the operating room, an interscalene catheter is placed for both anesthesia and postoperative pain control. The patient is then brought to the operating room. Then, after induction of general anesthesia, the patient is positioned in the lateral decubitus position through use of the Shoulder Suspension System (S3) (Arthrex, Naples, FL) with 10 lb of balanced traction.

For the completion of this procedure, we prefer and suggest the lateral decubitus given its lesser risk of a potential cardiopulmonary complication and lesser burden of operating room setup versus the beach-chair position. Furthermore, the lateral decubitus position

From the Steadman Philippon Research Institute (G.S., N.I.K., M.B.F., M.T.P.) and the Steadman Clinic (S.M., S.J.F., M.T.P.), Vail, Colorado, U.S.A.

The authors report the following potential conflicts of interest or sources of funding: M.T.P. is a consultant for Arthrex and JRF Ortho; has patents issued (9226743, 20150164498, 20150150594, 20110040339); and receives publishing royalties from Arthrex and Slack. Full ICMJE author disclosure forms are available for this article online, as [supplementary material](#).

The investigation was performed at the Steadman Philippon Research Institute, Vail, Colorado, U.S.A.

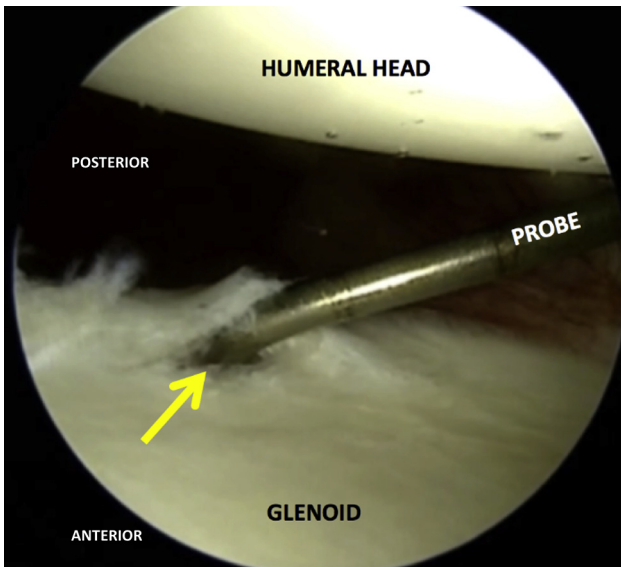
Received March 28, 2017; accepted June 28, 2017.

Address correspondence to CAPT Matthew T. Provencher, M.D., M.C., U.S.N.R., Steadman Philippon Research Institute, 181 West Meadow Drive, Ste 1000, Vail, Colorado 81657, U.S.A. E-mail: [mprovencher@thesteadmanclinic.com](mailto:mprovencher@thesteadmanclinic.com)

© 2017 by the Arthroscopy Association of North America. Published by Elsevier. This is an open access article under the CC BY-NC-ND license (<http://creativecommons.org/licenses/by-nc-nd/4.0/>).

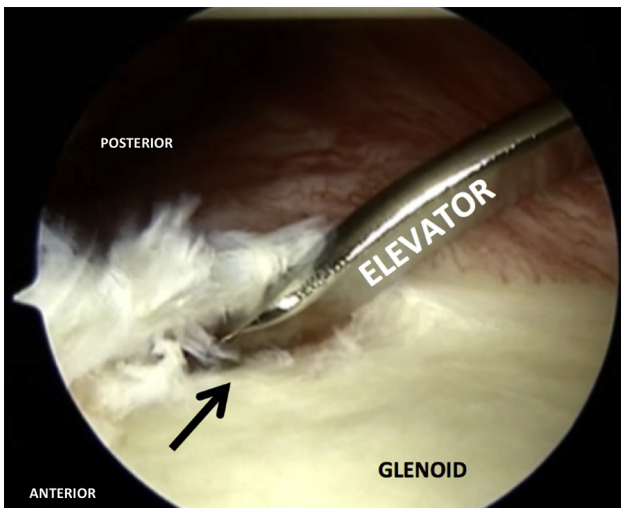
2212-6287/17518

<http://dx.doi.org/10.1016/j.eats.2017.06.055>

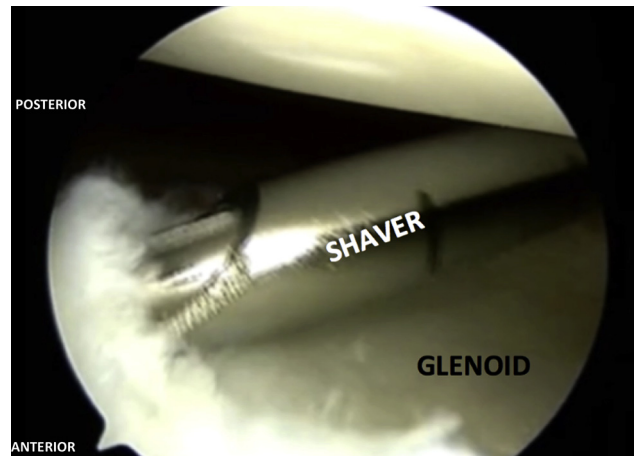


**Fig 1.** The area of the injury is arthroscopically visualized through the posterior portal using a 30° arthroscope and compared with the preoperative magnetic resonance image in this right shoulder. An arthroscopic probe is then used through the anterior midglenoid portal to evaluate the extension of the tear and quality of the labrum tissue (arrow).

allows for gentle distraction and full 360° access of the glenohumeral joint. Moreover, completion of this procedure in the lateral decubitus position leads to better “reduction” of the torn labrum onto the glenoid face during repair.



**Fig 2.** After the diagnosis of the labrum tear through the posterior portal, attention is turned to the preparation for the reattachment of the labrum in this right shoulder. A visible and palpable defect between the glenoid rim and labrum is present (black arrow). Usually, the labrum will have torn off the glenoid rim. A combination of arthroscopic rasps and elevators, both shallow and steep, is used to release the torn labrum from all adhesions. It is easier to prepare the posterior labrum from the front portal of the shoulder with an elevator, rasp, and a curved shaver.



**Fig 3.** Arthroscopic visualization is done through the posterior portal to visualize the arthroscopic shaver, which is inserted from the anterior midglenoid portal and used to remove all degenerated tissue in this right shoulder. This allows the suture to be placed in healthy tissue, ultimately decreasing the risk of construct failure and providing greater likelihood of a positive postoperative outcome.

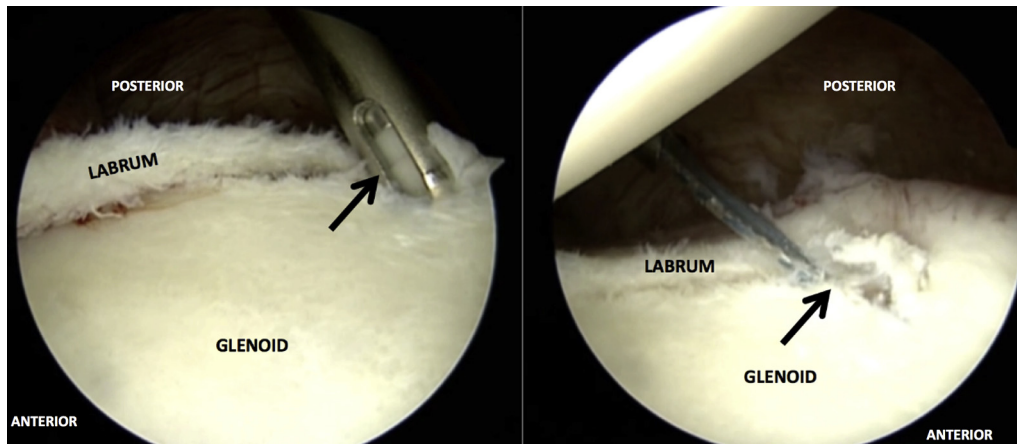
### Diagnostic Arthroscopy

A standard posterior portal is made approximately 2 cm distal to the posterior and lateral border of the acromion. Afterward, an anterior midglenoid portal is made in the rotator interval under arthroscopic visualization, and used as the working portal in our technique. During diagnostic arthroscopy, using the arthroscope through the posterior portal, debridement and synovectomy is performed to remove frayed and degenerated tissue from the joint space. In addition, chondroplasty of the glenoid and humeral head may be performed concurrently.

Initial evaluation of the glenohumeral joint is performed using a probe with confirmation of the posterior labral tear from the 6-o'clock to the 11-o'clock position (with a 3-o'clock anterior convention) (Fig 1). It is important to note that in a chronic instability, and occasionally in a posterior instability setting, the labrum may be adhered off the glenoid face, which leads to a loss of the gasket effect provided by the deepening of the glenoid face.

### Posterior Labral Repair—Labral and Glenoid Preparation

After diagnosing the area of the injury, attention is turned to preparation of the glenoid rim and torn labrum. The labrum is typically found slipped off the glenoid face and adhered below the crest of the glenoid. The adhered labrum is liberated using a combination of a shallow and steep elevator (Fig 2). The adhered scar tissue is liberated further with an arthroscopic shaver and a rasp. The shaver, rasp, and arthroscopic burr can be used to prepare a bleeding surface of the glenoid rim interface to facilitate healing from the bone to the



**Fig 4.** A Knotless SutureTak Anchor (Arthrex) used through the anterior midglenoid to properly fix the labrum onto the glenoid bone is shown in this right shoulder, using a 30° arthroscope through the posterior portal. The anchor (black arrow) is placed on the glenoid rim with anchor position verified through use of a percutaneous spinal needle. The amount of anchors depends on the extent of the labral tear.

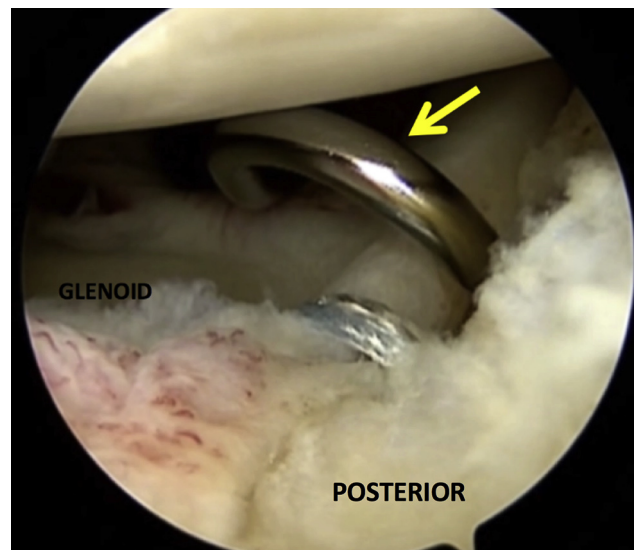
repaired labrum (Fig 3). Care must be taken to not resect excessive bone, as this can result in iatrogenic bone loss and recurrent instability. Loose flaps of degenerative labral tissue is debrided back to healthier labral tissue that can maintain suture integrity after repair using an arthroscopic shaver. A radiofrequency device is also occasionally used to remove the water content from the labral tissue and “shrink” the inflamed labral tissue back to healthier labral tissue that can better accept suture repair.

#### Posterior Labral Repair with Associated Capsular Plication—Suture Fixation of the Torn Posterior Labrum

After sufficient mobilization of the torn labrum and preparation of both the labrum and glenoid, suture repair is performed through an 8-mm Arthrex cannula (Arthrex) placed posteriorly. This suture repair consists of starting from the most inferior and distal aspect of the torn labrum and working more superior on the clock face. The reason for proceeding in this manner is that the more inferior aspect of the repair becomes difficult to access after suture repair is performed more superiorly.

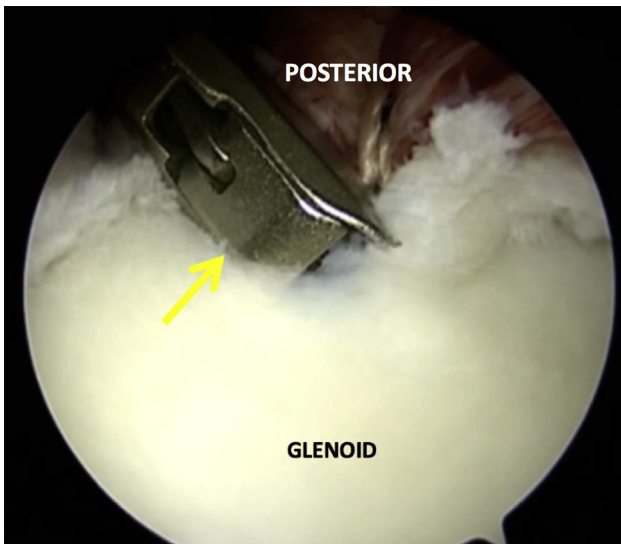
The 2.4-mm drill for 3-mm SutureTak (Arthrex) is used on the glenoid rim through a percutaneous drill guide. The guide is localized using a spinal needle to the 6-o’clock position. The drill guide is used to lever the humeral head anterior and out of the way of the drill track. Once drilled, it is important to ensure that the guide path and trajectory is maintained. After this, the anchor is placed through this guide path (Fig 4). Then a ReelPass SutureLasso (Arthrex) is used to grasp a several-millimeter (approximately 2-3 mm) portion of the capsule through the chondrolabral junction (Fig 5). For the Knotless SutureTak Anchor (Arthrex) shoulder labral repair anchor, the suture without a stripe is

retrieved and a knot is tied to the ReelPass suture. After this, the anchor suture is pulled through the labrum and capsule and retrieved through the cannula posteriorly. The suture is then placed through the striped suture loop and folded over to the portion that is not colored. The other striped suture end is then pulled until taut, thereby tensioning the repair. Afterward, an arthroscopic suture cutter is then used under arthroscopic visualization to trim the end of the suture after the labrum is repaired (Fig 6). These steps were



**Fig 5.** A ReelPass SutureLasso (Arthrex) is a hook instrument used to pass the suture through the capsule and labrum in this right shoulder, and used through the anterior midglenoid portal. Once the device (yellow arrow) is safely placed between the labrum and glenoid rim, a monofilament suture is released from the device and used to fix the torn labrum back onto the bone. Ultimately, a knotless labral repair construct is formed.





**Fig 6.** Once the labral repair is performed in this right shoulder, an arthroscopic suture cutter (yellow arrow) is used through the anterior midglenoid portal to remove excess suture under arthroscopic visualization.

repeated for 3 total Knotless SutureTak Anchor from approximately the 6-o'clock position to the 10-o'clock position.

In our case example, the patient's tissue quality between 10 and 11 o'clock was insufficient. Therefore, we felt that a labral tape repair would be more appropriate with a 2.9-mm PEEK (polyether ether ketone) Knotless Labral Tape Anchor (Arthrex). Once again, we drilled the anchor track through an arthroscopic drill guide. Then, while maintaining our trajectory, the 2.9-mm PEEK Knotless Labral Tape Anchor is placed with a mallet. After this, a ReelPass SutureLasso is used to grasp a portion of the joint capsule. The blue no. 1 monofilament is passed and exits through the chondrolabral junction. This suture is retrieved and then one

of the limbs of the labral tape is shuttled through the labrum and capsule. We then repaired the labrum with a Weston knot followed by 3 racking half hitches. Care is taken to make certain that the knot did not lie outside the glenohumeral joint on the periphery of the labrum. Afterward, an arthroscopic suture cutter is used under visualization to trim the end of the suture after completion of the repair.

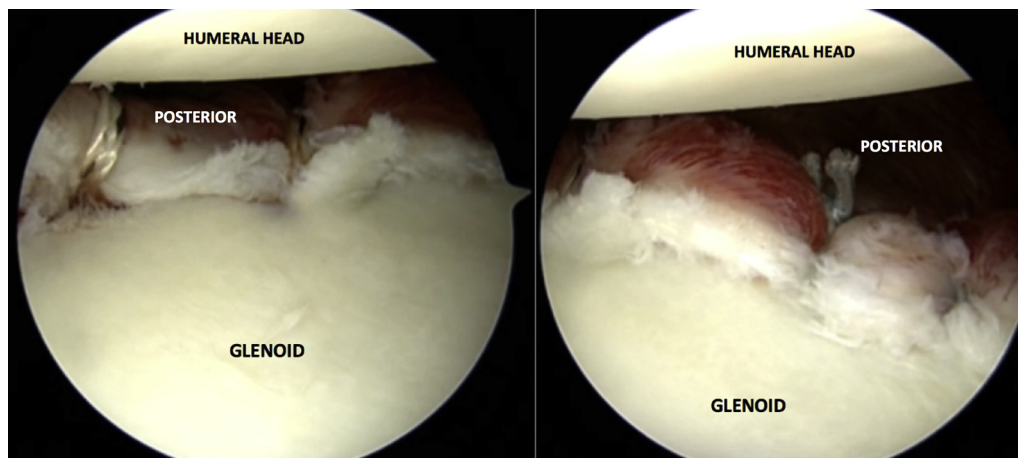
### Final Inspection and Closure

Final inspection of the repaired labrum with associated capsular plication is then performed. An arthroscopic probe is used to check the integrity of the repair, thereby ensuring restoration of the labrum to its anatomic position after arthroscopic repair (Fig 7).

The shoulder is then evacuated of arthroscopic fluid. The portal sites are closed with no. 3-0 Monocryl suture, Dermabond, and Steri-Strips. A sterile dressing is placed, and then the shoulder is placed into a padded abduction sling. The advantages and disadvantages associated with the described technique are listed in Table 1, and pearls and pitfalls are shown in Table 2.

### Postoperative Rehabilitation

The patient is initially placed in an immobilization sling for the first 6 postoperative weeks. Passive range-of-motion exercises may be initiated in the sagittal and frontal plane as well as shoulder external rotation to 40° in neutral. Once the patient has successfully progressed through passive range-of-motion exercises, active range of motion exercises may be started at week 6. The goals of these exercises include strengthening the scapula and regaining dynamic neuromuscular control. Nevertheless, it is important to restrict internal rotation past neutral until 6 weeks after surgery and internal rotation with abduction until 8 weeks after surgery. This restriction on internal rotation is placed to protect repaired tissues. At 8 weeks after surgery, there should



**Fig 7.** Arthroscopic visualization through the anterior portal of the completed labrum repair in this right shoulder is shown. The detachment of the labrum has been fully addressed with complete restoration of the native junction.

**Table 1.** Advantages and Disadvantages

Advantages	Disadvantages
Significantly stronger fixation than anchorless repair, which decreases the risk of failure	More technically challenging than open repair
Decreased risk of arthrofibrosis with arthroscopic technique compared with open procedure	
Knotless technique allows for decreased potential for joint abrasion	
Better pullout strength than knotted repairs	

be no restriction with initiation of strengthening exercises, including shoulder flexion in prone, horizontal abduction in prone, and dumbbell exercises with light resistance and high number of repetitions. At the patient’s discretion and particular progression, further strengthening exercises are integrated into the rehabilitation program, including medicine ball exercises, resistive tubing, and cable column. A return to sport depends on the patient’s functional demands and sport-specific goals with clearance typically given at 18 to 22 weeks after surgery.

**Discussion**

This Technical Note describes our preferred technique for addressing posterior instability. This injury can be managed conservatively with success. However, in high-demand patients, especially contact athletes, and patients with continued symptomatic instability after conservative treatment, we recommend our surgical technique, which can help restore stability to allow resolution of symptomology.

Although nonoperative management should be considered the first line of treatment in low-demand patients, unfavorable results after conservative management in younger, more active male patients have been shown.<sup>2-4,9</sup> Early reported outcomes after open and arthroscopic repair for treatment of posterior instability were discouraging, with reported failure rates of up to 70%.<sup>3</sup> However, more recently, modern arthroscopic techniques have developed into the “gold standard” of care for patients with pain or symptomatic instability.

Recent clinical studies with greater than 2 years of follow-up have reported high success rates after arthroscopic management of posterior instability with ranges of 88% to 97%.<sup>10-13</sup> Bradley et al. reported on 200 patients who underwent posterior labral repair with 94% satisfaction, 90% return to sport, and 7% persistent instability.<sup>10</sup> A systematic review by Leivadiotou and Ahrens of almost 400 shoulders reported a 92.5% return to sport and a 5.37% rate of recurrent instability.<sup>14</sup> A systematic review by DeLong et al. showed that patients treated arthroscopically have superior outcomes compared with patients who undergo open procedures with respect to stability, recurrence of instability, patient satisfaction, return to sport, and return to previous level of play.<sup>3</sup> In summary, arthroscopic posterior stabilization has shown excellent clinical outcomes with high patient satisfaction and low complication rates in patients with symptomatic posterior instability.<sup>9</sup>

There are a few different surgical fixation techniques described for treatment of posterior instability, including use of suture anchors, anchorless suture repair, and capsular plication. Numerous studies including those done by Provencher et al. and Radkowski et al. have shown that capsular plication has a much higher failure rate than repair with suture anchors.<sup>11,12</sup> Bradley et al. similarly showed that 7 of 8 repairs that underwent revision had a primary surgery involving plication and no suture anchors.<sup>15</sup> In a comparison between anchorless and anchor repair, Bradley et al. reported a significantly higher failure rate in anchorless suture repair, with a significantly higher return to sport for repair with use of anchors.<sup>10</sup> McIntyre et al. also revealed inefficacy of anchorless repair, with a 25% recurrence rate in 20 shoulders at a minimum 24 months’ follow-up for treatment of symptomatic posterior instability.<sup>16</sup>

In conclusion, we recommend surgical repair with knotless suture anchor fixation for recurrent posterior shoulder instability for patients with high functional demand and those with recurrent symptomatic instability unresponsive to conservative management. Future follow-up studies are needed to determine and validate the long-term efficacy of this procedure with regard to both stability of the joint and incurrence of osteoarthritis.

**Table 2.** Pearls and Pitfalls

Pearls	Pitfalls
Lateral decubitus position, unlike a beach-chair position, allows easy access of the posterior capsule	If the repair is not performed in a correct manner, or order, it can become quite difficult
Placement of the posterior portal slightly lateral will allow for a single, effective posterior portal	Incorrect placement of the posterior portal will result in poor visualization and inaccessibility of the joint
Suture repairs should be performed in the inferior-to-superior direction	If suture repair is performed more superiorly at first, then access to the inferior portion of the joint will be difficult
Restriction of internal rotation during the early postoperative period helps maintain repair integrity and avoid failure	

## References

1. Antoniou J, Duckworth DT, Harryman DT 2nd. Capsulolabral augmentation for the management of posteroinferior instability of the shoulder. *J Bone Joint Surg Am* 2000;82:1220-1230.
2. Arner JW, McClincy MP, Bradley JP. Arthroscopic stabilization of posterior shoulder instability is successful in American football players. *Arthroscopy* 2015;31:1466-1471.
3. DeLong JM, Jiang K, Bradley JP. Posterior instability of the shoulder: A systematic review and meta-analysis of clinical outcomes. *Am J Sports Med* 2015;43:1805-1817.
4. Provencher MT, LeClere LE, King S, et al. Posterior instability of the shoulder: Diagnosis and management. *Am J Sports Med* 2011;39:874-886.
5. Millett PJ, Clavert P, Hatch GF 3rd, Warner JJ. Recurrent posterior shoulder instability. *J Am Acad Orthop Surg* 2006;14:464-476.
6. Fronek J, Warren RF, Bowen M. Posterior subluxation of the glenohumeral joint. *J Bone Joint Surg Am* 1989;71:205-216.
7. Wanich T, Dines J, Dines D, Gambardella RA, Yocum LA. "Batter's shoulder": Can athletes return to play at the same level after operative treatment? *Clin Orthop Relat Res* 2012;470:1565-1570.
8. Burkhead WZ Jr, Rockwood CA Jr. Treatment of instability of the shoulder with an exercise program. *J Bone Joint Surg Am* 1992;74:890-896.
9. Antosh IJ, Tokish JM, Owens BD. Posterior shoulder instability. *Sports Health* 2016;8:520-526.
10. Bradley JP, McClincy MP, Arner JW, Tejwani SG. Arthroscopic capsulolabral reconstruction for posterior instability of the shoulder: A prospective study of 200 shoulders. *Am J Sports Med* 2013;41:2005-2014.
11. Provencher MT, Bell SJ, Menzel KA, Mologne TS. Arthroscopic treatment of posterior shoulder instability: Results in 33 patients. *Am J Sports Med* 2005;33:1463-1471.
12. Radkowski CA, Chhabra A, Baker CL 3rd, Tejwani SG, Bradley JP. Arthroscopic capsulolabral repair for posterior shoulder instability in throwing athletes compared with nonthrowing athletes. *Am J Sports Med* 2008;36:693-699.
13. Savoie FH 3rd, Holt MS, Field LD, Ramsey JR. Arthroscopic management of posterior instability: Evolution of technique and results. *Arthroscopy* 2008;24:389-396.
14. Leivadiotou D, Ahrens P. Arthroscopic treatment of posterior shoulder instability: A systematic review. *Arthroscopy* 2015;31:555-560.
15. Bradley JP, Baker CL 3rd, Kline AJ, Armfield DR, Chhabra A. Arthroscopic capsulolabral reconstruction for posterior instability of the shoulder: A prospective study of 100 shoulders. *Am J Sports Med* 2006;34:1061-1071.
16. McIntyre LF, Caspari RB, Savoie FH 3rd. The arthroscopic treatment of posterior shoulder instability: Two-year results of a multiple suture technique. *Arthroscopy* 1997;13:426-432.