

ORIGINAL PAPER

# Combining Ultrasound with a Pediatric Appendicitis Score to Distinguish Complicated from Uncomplicated Appendicitis in a Pediatric Population

Tran Kiem Hao<sup>1</sup>, Nguyen Tien Chung<sup>2</sup>, Huynh Quang Huy<sup>3\*</sup>, Nguyen Thi My Linh<sup>1</sup>, Nguyen Thanh Xuan<sup>4</sup>

<sup>1</sup>Pediatric Center, Hue Central Hospital, Vietnam.

<sup>2</sup>Department of Internal Medicine, University Of Traditional Medicine, Ha Noi, Vietnam

<sup>3</sup>Department of Radiology, Pham Ngoc Thach University of Medicine, Vietnam.

<sup>4</sup>Department of Abdominal Emergency and Pediatric Surgery, Hue Central Hospital, Vietnam.

\*Corresponding author: Huynh Quang Huy, A/ Prof,MD,PhD. Department of Radiology, Pham Ngoc Thach University of Medicine. 2 Duong Quang Trung street, District 10, Ho Chi Minh city, Vietnam. ORCID ID: <https://orcid.org/0000-0001-5177-1460>. Email: [huyhq@pnt.edu.vn](mailto:huyhq@pnt.edu.vn)

doi: 10.5455/aim.2020.28.114-118

ACTA INFORM MED. 2020 JUN 28(2): 114-118

Received: MAR 09, 2020

Accepted: JUN 12, 2020

© 2020 Tran Kiem Hao, Nguyen Tien Chung, Huynh Quang Huy, Nguyen Thi My Linh, Nguyen Thanh Xuan

This is an Open Access article distributed under the terms of the Creative Commons Attribution Non-Commercial License (<http://creativecommons.org/licenses/by-nc/4.0/>) which permits unrestricted non-commercial use, distribution, and reproduction in any medium, provided the original work is properly cited.

## ABSTRACT

Background: The accurate diagnosis of complicated appendicitis has been improved by using various diagnostic modalities. However, no preoperative diagnostic method could completely confirm the results. Therefore, preoperative diagnosis of complicated appendicitis to have the right management is still a huge challenge. Objectives: The aim of this study was to evaluate the diagnostic value of ultrasound combined with pediatric appendicitis score for differentiation between acute uncomplicated appendicitis and acute complicated appendicitis in a pediatric population. Methods: We prospectively evaluated 120 pediatric patients who underwent surgery for acute appendicitis from November 2017 to June 2019. Pediatric appendicitis score (PAS) was calculated and ultrasound (US) was performed before surgery. The histopathology of phlegmonous appendicitis corresponds to uncomplicated appendicitis (AUA), while gangrenous appendicitis and perforation are classified as complicated appendicitis (ACA). Results: Histopathologically, the results provided a diagnosis of acute appendicitis including 86 (71.7%) patients with AUA and 34 (28.3%) children with ACA. US findings showed a sensitivity of 23.5%, the specificity of 95.4%, PPV of 66.7%, NPV of 75.9%, and an accuracy of 75%. PAS of 8 was found to be the most appropriate cutoff point compatible with ACA; it resulted in a sensitivity of 76.5% and a specificity of 84.1%. Combining ultrasound with a pediatric appendicitis score resulted in a higher specificity to distinguish complicated from uncomplicated appendicitis when compared with ultrasound or PAS solely. Conclusions: the US is highly specific but nonsensitive for detecting complicated pediatric appendicitis. Combining ultrasound with pediatric appendicitis is a very good concept to distinguish complicated from uncomplicated appendicitis in a pediatric population.

**Keywords:** ultrasound, pediatric appendicitis score (PAS), complicated, appendicitis

## 1. INTRODUCTION

Acute appendicitis is the most common emergency in surgical abdominal disease in children, accounting for about 20%–30% of children hospitalized for acute abdominal pain (1). Diagnosis of appendicitis in children, especially young children, is often more difficult than in adults (2). Appendicitis in children under three years of age with clinical tableau often leads to missed diagnosis, is often diagnosed at the perforated stage. A total of 5% of children with acute appendicitis were not diagnosed at their first hospital admission (3). The rate of errors in the primary diagnosis of acute appendicitis

ranges from 28% to 57% in older children to nearly 100% in children less than two years old (1).

Only today, the accurate diagnosis of complicated appendicitis has been improved by applying a number of tests, such as leukocyte count and serum C-reactive protein level, abdominal ultrasound, and computerized tomography. However, no preoperative diagnostic method could completely confirm the results. Therefore, preoperative diagnosis of complicated appendicitis to have the right management is still a huge challenge (4).

To differentiate between uncomplicated and complicated appendicitis, the clinical and laboratory

findings can be combined with diagnostic imaging results. Common risk factors for the complications of appendicitis include the younger the child (5,6), the longer the duration of symptoms (5,7,8), and the severity of inflammatory markers (7-10). Although the factors for evaluating conventional diagnosis when used separately are likely to have a low differential diagnosis. Combining them increases the differential diagnostic value of appendicitis (10).

The aim of this study was to evaluate how a pediatric appendicitis score improves the diagnostic value of ultrasound for the differentiation between acute uncomplicated appendicitis and acute complicated appendicitis in a pediatric population.

## 2. METHODS

### Patients

We prospectively evaluated 120 consecutive patients who underwent surgery for acute appendicitis from November 2017 to June 2019 in this study.

Patients under 16 years of age with a clinical suspicion of acute appendicitis (based on medical history, physical examination and white blood cell count) and ultrasonography findings positive for acute appendicitis were included in the analysis. The distinguish between non-appendicitis and acute appendicitis was not the aim of this study. The final diagnosis of acute appendicitis (either complicated or uncomplicated) was based on surgery and histopathology reports.

Exclusion criteria were successful treatment with antibiotics, missing histopathologies or components of pediatric appendicitis score, concomitant chronic disease. In addition, patients with incidental appendectomy, and normal appendix after histologic examination were excluded from this study.

The written consent forms were obtained from all patients before the study. The steps of the operative procedure were explained to all patients' parents. This study was approved by the ethical review committee board of the hospital (IRB No.: 01112017/HCH).

### Study Design

After admission, all patients were well-examined. The definitive diagnosis was determined by the pediatrician after the history, clinical examination, the patient's body temperature, and the laboratory. The pediatric appendicitis score (PAS) was calculated for each patient according to the original PAS definition (11). The PAS is based on 8 signs: fever, anorexia, nausea/ emesis, migration of the pain to the right lower quadrant (RLQ), tenderness upon light palpation of RLQ, cough and/ or percussion and/ or heel tapping tenderness in the RLQ, leukocytosis, and polymorphonuclear neutrophilia. A 10-point scoring system was created using these variables.

Before a clinically-based ultrasound performance, all patients were classified into the following groups, helping to assess the need for surgical intervention.

- High possibility of acute appendicitis; requires emergency surgery;
- Monitor acute appendicitis at the hospital;

- Less likely to have acute appendicitis.

Ultrasound examination was performed as soon as the patient was clinically classified. Treatment decisions were made after obtaining the ultrasound results, combined with clinical features and laboratory findings.

### Ultrasound examination

All patients underwent ultrasound examination with Curved 3.5-5 MHZ transducers and Linear 6 MHZ transducers.

The criteria for the diagnosis of acute appendicitis were as follows (12): pain when pressing the transducer against the abdominal wall, appendix not collapsing, large appendix (larger than 6 mm in diameter), presence of an appendicoliths, fat infiltrate surrounding the appendix, and free fluid adjacent to the appendix.

In addition, all abdominal ultrasound was done at our hospital by licensed radiologists with at least 5 years of experience.

### Operative and histopathological analysis

Surgery was performed by a pediatric surgeon with over 10 years of experience. The following three groups of appendicitis were distinguished: phlegmonous appendicitis, gangrenous appendicitis, and perforated appendicitis. Phlegmonous appendicitis is determined by neutrophil infiltrates on the wall of the appendix without gangrene or perforation. Gangrenous appendicitis is characterized by ischemic regions that cause gangrene of the appendix, while perforation of the appendix is determined by the loss of continuity of the appendix (13). The histopathology of phlegmonous appendicitis corresponds to uncomplicated appendicitis (AUA), while gangrenous appendicitis and perforation are classified as complicated appendicitis (ACA), as stated in the document (13, 14).

### Statistical analysis

IBM SPSS version 20 for Windows was used to analyze the data. Continuous variables were presented as a median and interquartile range and compared by the Mann-Whitney U test. Categorical variables were expressed as numbers and percentages and compared using the Chi-square test.

To explore the diagnosis value of ultrasound for the acute complicated appendicitis, the sensitivity, specificity, positive predictive value (PPV), negative predictive value (NPV), and accuracy were calculated. For the evaluation of the predictive value of PAS, the receiver operating characteristic (ROC) curves were analyzed. It was considered significant in all statistical tests at the 5% level of significance if the *p*-value was less than 0.05.

## 3. RESULTS

A total of 120 patients who were evaluated with a PAS and received ultrasound due to suspected acute appendicitis, who then underwent appendectomy, met the inclusion criteria. Histopathologically, the results provided a diagnosis of acute appendicitis including 86 (71.7%) patients with AUA and 34 (28.3%) children with ACA. Out of 120 patients included in this study, 79 were males and 41 were females. There was a significant difference between the ACA and AUA groups regarding patients' age

( $p = 0.007$ ) and symptom duration ( $p < 0.001$ ). Patients' ages ranged from 4 to 15 years and their median age was 9.0 years. Table 1 summarizes the demographic data.

Regarding the components of pediatric appendicitis score, there was a significant difference between ACA and AUA groups of these signs: anorexia, fever ( $\geq 38.0^\circ\text{C}$ ), RLQ tenderness up light palpation. In overall, the PAS was higher in the ACA group than that in the AUA group ( $p < 0.001$ ) as shown in Table 1.

In this study, a PAS of 8 was found to be the most appropriate cutoff point compatible with ACA; it resulted in a sensitivity of 76.5% (95% CI = 58.8%–89.3%) and a specificity of 84.1% (95% CI = 74.4%–91.3%) (as shown in Figure 1). Further analysis of PAS in Table 2 demonstrated that PAS > 6 showed the highest sensitivity of 97.1% (95% CI = 84.7%–99.9%), whereas using a higher cutoff value (PAS > 9) showed the highest specificity of 96.3% (95% CI = 89.7%–99.2%).

Criterion	Sensitivity	95% CI	Specificity	95% CI
>5	100.0	89.7–100.0	4.9	1.3–12.0
>6	97.1	84.7–99.9	17.1	9.7–27.0
>7	91.2	76.3–98.1	63.4	52.0–73.8
>8 *	76.5	58.8–89.3	84.1	74.4–91.3
>9	38.2	22.2–56.4	96.3	89.7–99.2

Table 2. Criterion values and coordinates of the receiver operating characteristic (ROC) curve of PAS. \* Criterion corresponding with highest Youden index.

Diagnostic modalities	Sensitivity (95% CI)	Specificity (95% CI)
PAS > 8	76.5% (58.8–89.3)	84.1% (74.4–91.3)
Ultrasound	23.5% (10.8–41.2)	95.4% (88.5–98.7)
PAS-ultrasound combining*	17.6% (6.8–34.5)	98.8% (93.7–99.8)

Table 3. The diagnostic value of ultrasound intergrated with pediatric appendicitis score, and compared with PAS or ultrasound solely.. \*PAS>8 and ultrasound suspected of ACA

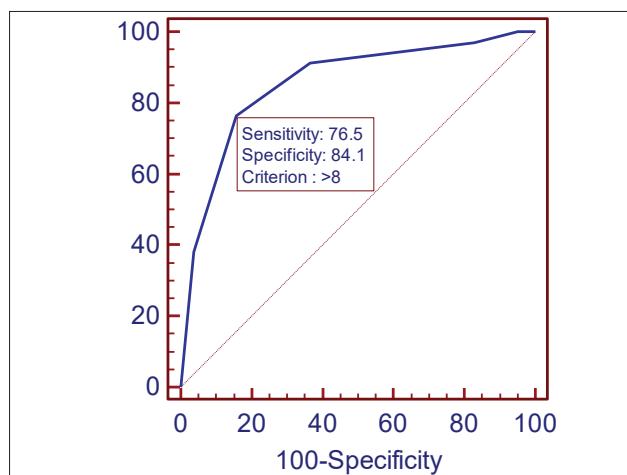


Figure 1. Receiver operating characteristic curve for the performance of a pediatric appendicitis score with area under curve (95% confidence interval) AUC = 0.856 (0.778 to 0.914). A PAS of 8 was found to be the the most appropriate cutoff point compatible with ACA where the Youden's index was maximum (Youden's index = 1).

The abdominal ultrasound examination of ACA gave true positive results in 8 cases (6.7%), true negative in

Variable	ACA (n = 34)	AUA (n = 86)	p-value
Age (median, interquartile range), (years)	8.0 (4.0)	10.0 (6.0)	0.007*
Sex (n, %)			
Male	23 (67.6%)	56 (65.1%)	0.792
Female	11 (32.4%)	30 (34.9%)	
Symptoms duration (median, interquartile range) (hours)	28.5 (28.3)	14.3 (11.6)	0.000*
Pediatric appendicitis score (median, interquartile range)	9.0 (1.0)	7.0 (1.0)	0.000*
PAS components (n,%)			
Nausea / emesis	27 (79.4%)	55 (64.0%)	0.101
Anorexia	34 (100.0%)	67 (77.9%)	0.001*
Migration of pain to RLQ	22 (64.7%)	43 (50.0%)	0.145
Fever ( $\geq 38.0^\circ\text{C}$ )	29 (85.3%)	57 (66.3%)	0.037*
RLQ tenderness up light palpation	33 (97.1%)	41 (47.7%)	0.000*
Cough and/ or percussion and/ or heel tapping tenderness in RLQ	31 (91.2%)	83 (96.5%)	0.221
Leukocytosis ( $>10,000/\text{mm}^3$ )	33 (97.1%)	82 (95.3%)	0.562
Left shift ( $>75\%$ neutrophilia)	33 (97.1%)	80 (93.0%)	0.359

Table 1. Distribution of age, sex, and pediatric appendicitis score. \*statistical significant

82 cases (68.3%), false negative (missed ACA) in 26 cases (21.7%), and false positive in 4 cases (3.3%). It showed a sensitivity of 23.5% (95% CI = 10.8%–41.2%), specificity of 95.4% (95% CI = 88.5%–98.7%), PPV of 66.7% (95% CI = 34.9%–90.1%), NPV of 75.9% (95% CI = 66.8%–83.6%), and an accuracy of 75%. Table 3 showed, combining ultrasound with a pediatric appendicitis score resulted in a higher specificity to distinguish complicated from uncomplicated appendicitis in a pediatric population when compared with ultrasound or PAS solely.

#### 4. DISCUSSION

Diagnosis of appendicitis in children, especially young children, is often more difficult than in adults. Because a child's clinical symptoms are very diverse, complex, and vary by age, the diagnosis of a digestive disorder is very common, leading easily to a misdiagnosis. When the inflamed appendix bursts, the large, incompletely developed connective lining will not be able to cover the broken appendix, causing localized peritonitis, which is worse than generalized peritonitis.

Differential diagnosis between AUA and ACA has been made in recent studies and indicates that antibiotic treatment for children with AUA is safe (15, sss16). Therefore, diagnostic imaging is a reliable method for differential diagnosis between AUA and ACA. Ultrasound helps children avoid radiation exposure, so it is currently the diagnostic imaging method of choice for evaluating patients with acute appendicitis and has even been shown to be helpful to improve accuracy and to confirm the diagnosis of advanced imaging methods, such as CT (12). We hope that combining ultrasound with a PAS can improve the differential diagnosis of uncomplicated and complicated appendicitis, including gangrenous appendicitis and perforated appendicitis.

There were 34/120 (28.3%) patients in our study who had surgical results consistent with complicated appendicitis (gangrenous and/or perforation appendicitis) at the time of surgery and 71.7% were diagnosed with uncomplicated appendicitis. The incidence of complicated

appendicitis reported in other studies is 22%–62% (17–19). Although many hospitals often rely on CT to diagnose appendicitis in children, which is more accurate to diagnose complicated appendicitis, at our hospital less than 10% of children with suspected appendicitis with CT examinations. Surely, suspected appendectomy is required, usually based on ultrasound to differentiate ACA from AUA (20–23).

In our study, ultrasound has been shown to be very specific. However, it was not highly sensitive to distinguish between complicated and uncomplicated appendicitis in children. Even in a center with well-trained ultrasound technicians, there is a low sensitivity when applying ultrasound to diagnose complications of the appendix. According to Jennifer's research, ultrasound has a sensitivity of 44.0%, a specificity of 93.1%, a positive predictive value of 74.8%, and a negative predictive value of 78.1% (24). According to Rawolle (25), abdominal ultrasound can distinguish between uncomplicated and complicated appendicitis in pediatric patients by using an increased appendix diameter, surrounding fat infiltration, the presence of fecal stones in the lumen appendix, and suspected appendix perforation.

Previously published studies report the diagnostic effectiveness of ultrasound when suspected appendicitis complications in children are limited by retrospective design and limited exclusion criteria. Our study included all patients with suspected appendicitis and was graded on an appendicitis scale for children. This may explain the ultrasound results with low sensitivity and high specificity in our study.

Other studies have demonstrated the use of a scoring system that not only benefits the diagnosis of appendicitis but also helps distinguish complicated appendicitis from uncomplicated appendicitis (25, 26). Atema et al. (27) studied the use of a new scoring system in 395 patients and correctly identified uncomplicated appendicitis of up to 95%. However, their system combines imaging methods (CT and US) with clinical variables, such as age, body temperature, symptom onset time, white blood cell count, and serum C-reactive protein level. In our study, a PAS of 8 was found to be the most appropriate cutoff point compatible with ACA where the Youden's index was maximum; it resulted in a sensitivity of 76.5% (95% CI = 58.8%–89.3%) and a specificity of 84.1% (95% CI = 74.4%–91.3%). This will improve the diagnosis of patients. Research by Fujii et al. also concludes that a PAS is related to inflammatory appendiceal complications in children with a ROC chart showing a cutoff value of 8 points and AUC of 0.87. PAS  $\geq$  8 to identify complicated appendicitis with a sensitivity of 73%, the specificity of 89%, the positive predictive value of 91%, and negative predictive value of 68% (28). Adibe and colleagues also concluded that PAS may be a prognostic tool for acute appendicitis in children in which PAS  $\geq$  9 can predict severe appendicitis (29).

To our knowledge, there are no published reports on combining ultrasound with a pediatric appendicitis score to distinguish complicated from uncomplicated appendicitis in a pediatric population. Our results showed that combining ultrasound with a pediatric appendi-

citis score could improve the specificity to distinguish complicated from uncomplicated appendicitis in a pediatric population when compared with ultrasound or PAS solely. Therefore, we recommend that PAS be developed as a diagnostic tool, which can also be used as a prognostic indicator. At the same time, combining PAS with ultrasound will help improve the accuracy of ultrasound when predicting the severity of the disease. This allows the surgeon to better predict the difficulty of surgery.

## 5. CONCLUSION

A high PAS and the US findings are significantly associated with ACA. The US is highly specific but nonsensitive for detecting complicated pediatric appendicitis. Combining ultrasound with pediatric appendicitis is a very good concept to distinguish complicated from uncomplicated appendicitis in a pediatric population.

### ABREVIATION

US: Ultrasound. PAS: Pediatric appendicitis score. AUA: Acute uncomplicated appendicitis. ACA: Acute complicated appendicitis. RLQ: right lower quadrant. PPV: positive predictive value. NPV: negative predictive value. ROC: receiver operating characteristic.

- **Author's contribution:** Each author gave substantial contribution in acquisition, analysis and data interpretation. Each author had a part in preparing article for drafting and revising it critically for important intellectual content. Each author gave final approval of the version to be published and agreed to be accountable for all aspects of the work in ensuring that questions related to the accuracy or integrity of any part of the work are appropriately investigated and resolved.
- **Funding:** This research received no external funding
- **Conflicts of Interest:** The authors declare no conflict of interest
- **Acknowledgements:** We would like to thank Dr Nguyen Huu Son for his valuable contributions to the study

## REFERENCES

- 1 Almaramhy HH. Acute appendicitis in young children less than 5 years: review article. *Ital J Pediatr.* 2017; 43(1): 15.
- 2 Lee SL, Ho HS. Acute appendicitis: is there a difference between children and adults? *Am Surg.* 2006; 72(5): 409–413.
- 3 Naiditch JA, Lantz TB, Daley S, Pierce MC, Reynolds M. The implications of missed opportunities to diagnose appendicitis in children. *Acad Emerg Med.* 2013; 20(6): 592–596.
- 4 Hamid KA, Mohamed MA, Salih A. Acute Appendicitis in Young Children: A Persistent Diagnostic Challenge for Clinicians. *Cureus.* 2018; 10(3): e2347.
- 5 Augustin T, Cagir B, Vandermeer TJ. Characteristics of perforated appendicitis: effect of delay is confounded by age and gender. *J Gastrointest Surg.* 2011; 15(7): 1223–1231.
- 6 Guller U, Rosella L, McCall J, Brugger LE, Candinas D. Negative appendectomy and perforation rates in patients undergoing laparoscopic surgery for suspected appendicitis. *Br J Surg.* 2011; 98(4): 589–595.
- 7 Broker ME, van Lieshout EM, van der Elst M, Stassen LP, Schepers T. Discriminating between simple and perforated appendicitis. *J Surg Res.* 2012; 176(1): 79–83.
- 8 Lin CJ, Chen JD, Tiu CM, Chou YH, Chiang JH, Lee CH, et al. Can ruptured appendicitis be detected preoperatively in the ED? *Am J Emerg Med.* 2005; 23(1): 60–66.

- 9 Andersson R, Hugander A, Thulin A, Nystrom PO, Olaison G. Indications for operation in suspected appendicitis and incidence of perforation. *BMJ*. 1994; 308(6921): 107-110.
- 10 Andersson RE. Meta-analysis of the clinical and laboratory diagnosis of appendicitis. *Br J Surg*. 2004; 91(1): 28-37.
- 11 Samuel M. Pediatric appendicitis score. *J Pediatr Surg*. 2002; 37(6): 877-881.
- 12 Kim MS, Kwon HJ, Kang KA, Do IG, Park HJ, Kim EY, et al. Diagnostic performance and useful findings of ultrasound re-evaluation for patients with equivocal CT features of acute appendicitis. *Br J Radiol*. 2018; 91(1082): 20170529.
- 13 Fallon SC, Kim ME, Hallmark CA, Carpenter JL, Eldin KW, Lopez ME, et al. Correlating surgical and pathological diagnoses in pediatric appendicitis. *J Pediatr Surg*. 2015; 50(4): 638-641.
- 14 Imaoka Y, Itamoto T, Takakura Y, Suzuki T, Ikeda S, Urushihara T. Validity of predictive factors of acute complicated appendicitis. *World J Emerg Surg*. 2016; 11(48).
- 15 Hartwich J, Luks FI, Watson-Smith D, Kurkchubasche AG, Muratore CS, Wills HE, et al. Nonoperative treatment of acute appendicitis in children: A feasibility study. *J Pediatr Surg*. 2016; 51(1): 111-116.
- 16 Svensson JF, Patkova B, Almstrom M, Naji H, Hall NJ, Eaton S, et al. Nonoperative treatment with antibiotics versus surgery for acute nonperforated appendicitis in children: a pilot randomized controlled trial. *Ann Surg*. 2015; 261(1): 67-71.
- 17 Ma KW, Chia NH, Yeung HW, Cheung MT. If not appendicitis, then what else can it be? A retrospective review of 1492 appendectomies. *Hong Kong Med J*. 2010; 16(1): 12-17.
- 18 Ponsky TA, Huang ZJ, Kittle K, Eichelberger MR, Gilbert JC, Brody F, et al. Hospital- and patient-level characteristics and the risk of appendiceal rupture and negative appendectomy in children. *JAMA*. 2004; 292(16): 1977-1982.
- 19 Williams RF, Blakely ML, Fischer PE, Streck CJ, Dassinger MS, Gupta H, et al. Diagnosing ruptured appendicitis preoperatively in pediatric patients. *J Am Coll Surg*. 2009; 208(5): 819-825.
- 20 Fallon SC, Orth RC, Guillerman RP, Munden MM, Zhang W, Elder SC, et al. Development and validation of an ultrasound scoring system for children with suspected acute appendicitis. *Pediatr Radiol*. 2015; 45(13): 1945-1952.
- 21 Kotagal M, Richards MK, Chapman T, Finch L, McCann B, Ormazabal A, et al. Improving ultrasound quality to reduce computed tomography use in pediatric appendicitis: the Safe and Sound campaign. *Am J Surg*. 2015; 209(5): 896-900.
- 22 Stephen AE, Segev DL, Ryan DP, Mullins ME, Kim SH, Schnitzer JJ, et al. The diagnosis of acute appendicitis in a pediatric population: to CT or not to CT. *J Pediatr Surg*. 2003; 38(3): 367-371.
- 23 Wagenaar AE, Tashiro J, Wang B, Curbelo M, Mendelson KL, Perez EA, et al. Protocol for suspected pediatric appendicitis limits computed tomography utilization. *J Surg Res*. 2015; 199(1): 153-158.
- 24 Carpenter JL, Orth RC, Zhang W, Lopez ME, Mangona KL, Guillerman RP. Diagnostic Performance of US for Differentiating Perforated from Nonperforated Pediatric Appendicitis: A Prospective Cohort Study. *Radiology*. 2017; 282(3): 835-841.
- 25 Rawolle T, Reismann M, Minderjahn MI, Bassir C, Hauptmann K, Rothe K, et al. Sonographic differentiation of complicated from uncomplicated appendicitis. *Br J Radiol*. 2019; 92(1099): 20190102.
- 26 Xu Y, Jeffrey RB, Chang ST, DiMaio MA, Olcott EW. Sonographic Differentiation of Complicated From Uncomplicated Appendicitis: Implications for Antibiotics-First Therapy. *J Ultrasound Med*. 2017; 36(2): 269-277.
- 27 Atema JJ, van Rossem CC, Leeuwenburgh MM, Stoker J, Boermeester MA. Scoring system to distinguish uncomplicated from complicated acute appendicitis. *Br J Surg*. 2015; 102(8): 979-990.
- 28 Fujii T, Tanaka A, Katami H, Shimono R. Usefulness of the Pediatric Appendicitis Score for Assessing the Severity of Acute Appendicitis in Children. *Pediatr Int*. 2019.
- 29 Adibe OO, Muensterer OJ, Georgeson KE, Harmon CM. Severity of appendicitis correlates with the pediatric appendicitis score. *Pediatr Surg Int*. 2011; 27(6): 655-658.