

Reverse longitudinal stent deformation during percutaneous intervention via the retrograde approach to a chronic total occlusion of the right coronary artery: a case report

Claudia Cosgrove ¹, Marciej Marciniak ², and James C. Spratt ^{1*}

¹Cardiology Department, St George's University Hospitals NHS Trust, Blackshaw Road, London SW17 0QT, UK; and ²Cardiology Department, East Surrey Hospital, Canada Ave, London RH1 5RH, UK

Received 8 June 2020; first decision 28 July 2020; accepted 18 December 2020

Background

Longitudinal stent deformation (LSD) is an uncommon but recognized mechanical complication of coronary stent implantation, usually occurring at the proximal stent edge due to compression by guide catheter or catheter extensions. Retrograde techniques for chronic total occlusion (CTO) percutaneous coronary intervention expose the distal stent edge to potential interaction with retrograde equipment under a tensioned system.

Case summary

We describe a case of distal stent edge LSD, occurring during a retrograde approach to a right coronary artery CTO via septal collateral channels. While removing the externalized wire, interaction with the retrograde micro-catheter caused compression of the distal end of the newly implanted stents.

Discussion

This unusual complication highlights the reduced longitudinal strength of newer generation stent platforms and the risks of interaction between retrograde equipment and stents on an externalized wire.

Keywords

Case report • Chronic total occlusion • Retrograde • Percutaneous coronary intervention • Stent deformation

Learning points

- Newer generation stent platforms have reduced longitudinal strength, increasing the risk of longitudinal stent deformation.
- In retrograde techniques for chronic total occlusion percutaneous intervention, care must be taken to avoid interaction between retrograde equipment and the distal edge of the newly deployed stents.
- Intravascular imaging is integral to understanding the mechanism of mechanical stent complications and ensuring a satisfactory final result.

Introduction

Newer generation drug eluting stent (DES) platforms have thin struts and fewer inter-cell connectors, compromising their longitudinal

strength¹ (Figure 1). Deformation or shortening of a stent along its longitudinal axis is a recognized mechanical complication following stent implantation, usually occurring at the proximal stent edge due to compression by guide catheter or guide extension systems. The

* Corresponding author. Tel: +44 (0) 2087253576, Email: james.spratt@nhs.net

Handling Editor: Dejan Milasinovic

Peer-reviewers: Pierre Deharo and Piotr Nikodem Rudziński

Compliance Editor: Reshma Amin

Supplementary Material Editor: Deepti Ranganathan

© The Author(s) 2021. Published by Oxford University Press on behalf of the European Society of Cardiology.

This is an Open Access article distributed under the terms of the Creative Commons Attribution Non-Commercial License (<http://creativecommons.org/licenses/by-nc/4.0/>), which permits non-commercial re-use, distribution, and reproduction in any medium, provided the original work is properly cited. For commercial re-use, please contact journals.permissions@oup.com

reported incidence of longitudinal stent deformation (LSD) is between 0.2% and 1.4% per patient on angiographic studies, and 1.6% per patient when detected on intravascular ultrasound (IVUS).²

Chronic total occlusions (CTOs) are defined as complete interruption of antegrade flow due to atherosclerotic vessel narrowing of a coronary artery for more than 3 months.³ Collateral channels form between a non-occluded vessel and the CTO vessel, beyond the occluded segment, and may be traversed with equipment to approach the occluded segment retrogradely. Retrograde techniques have increased the rates of success in percutaneous coronary intervention (PCI) for CTOs.^{4–6} After crossing the collateral circulation and occluded segment a long (>300 cm) wire is commonly externalized. This wire enters the retrograde guide catheter, crosses the collateral circulation and CTO segment, and exits via the antegrade guide catheter, providing a highly stable platform for stent delivery.

Here, we provide the first description of reverse LSD, which occurred during a retrograde intervention to a right coronary artery (RCA) CTO.

Timeline

January 2018	Presentation with exertional chest pain and dyspnoea
February 2018	Diagnostic coronary angiogram showing chronic total occlusion (CTO) of the right coronary artery (RCA), moderate disease in mid left anterior descending artery, and CTO of the left circumflex artery
May 2018	Medical management of coronary artery disease Transthoracic echocardiogram shows left ventricular (LV) ejection fraction 45%, mild–moderate aortic stenosis
November 2018	Cardiac magnetic resonance imaging demonstrates inducible ischaemia in RCA territory
December 2018	Persistent symptoms of dyspnoea, chest discomfort, fatigue despite medical therapy Multidisciplinary team meeting–percutaneous revascularization favoured over surgical
March 2019	Percutaneous intervention to RCA CTO
December 2019	Diagnosed with Hodgkin Lymphoma
January 2020	LV ejection fraction 52% on echocardiogram Commenced chemotherapy
July 2020	LV ejection fraction 30% on echocardiogram Cardiology outpatient review: patient remains free of angina or dyspnoea

Case presentation

A 67-year-old man presented with exertional chest discomfort and dyspnoea [New York Heart Association (NYHA) class II] refractory

to medical therapy including a beta-blocker, long acting nitrate, and ranolazine. The patient was obese (body mass index of 35 kg/m²), hypertensive, with type II diabetes, and a previous stroke, which had left him with no residual deficits. Physical examination and vital signs were unremarkable. Electrocardiogram showed sinus rhythm with no conduction delays.

Diagnostic angiography showed a CTO of the proximal RCA with septal collateral channels from the left anterior descending (LAD) to the posterior descending artery (PDA). There was moderate disease in the mid LAD and a CTO of the proximal left circumflex. Transthoracic echocardiogram demonstrated mild left ventricular (LV) systolic impairment (ejection fraction 45%) and mild-moderate aortic stenosis (mean gradient 15 mmHg, peak gradient 28 mmHg, aortic valve area 1.2 mm²). Cardiac magnetic resonance imaging showed inducible ischaemia in the basal-mid inferoseptal, inferior and inferolateral walls, with partial thickness (25–50%) subendocardial infarction in these segments but full viability. The patient was discussed at the multidisciplinary team meeting, and in the absence of significant LAD disease, and given the patient’s obesity and history of stroke, percutaneous treatment was favoured over surgical.

The procedure was undertaken via 7F biradial arterial access. Antegrade dissection (blunt dissection via the subintimal space to bypass the occlusive plaque) was performed in the RCA with a ‘knuckled’ polymer-jacketed wire and a Corsair microcatheter (Asahi Intecc, Aichi, Japan). For the retrograde approach, the first septal collateral channel was crossed with a Sion wire (Asahi Intecc) and a Caravel 150 cm microcatheter (Asahi Intecc). The antegrade and retrograde equipment were overlapped in the distal RCA and, following antegrade balloon inflation to create of a common subintimal tract to connect the proximal and distal true lumen, a 330 cm RG3 (Asahi Intecc) wire was externalized.

IVUS-guided stent implantation was performed, with overlapping 2.5 × 20 mm, 3.5 × 48 mm, and 4.5 × 12 mm everolimus-eluting Synergy stents (Boston Scientific, Marlborough, MA, USA) stents placed from proximal PDA to the proximal RCA. High pressure post-dilatation was performed with non-compliant balloons along the entire length of implanted stent (Figure 2A).

Prior to removing the externalization wire, the retrograde microcatheter was advanced into the distal stent to protect the collateral from exposure to the externalized wire. After removing the RG3

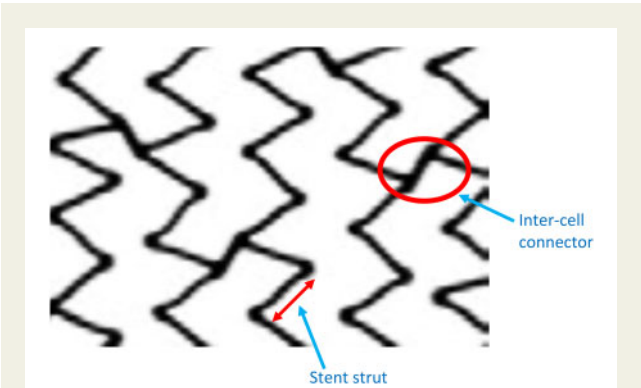


Figure 1 Diagram showing stent design with position of stent struts and inter-cell connectors.

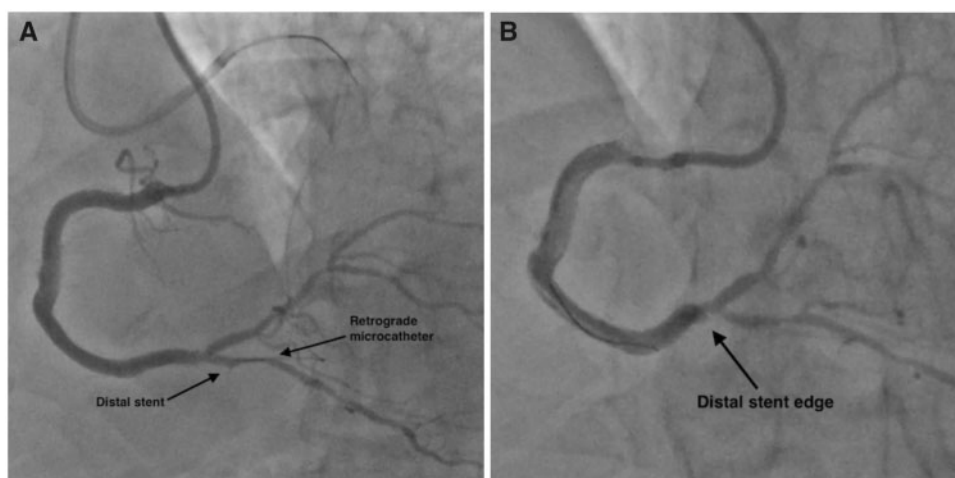


Figure 2 Angiogram following implantation of right coronary artery stents, with position of retrograde microcatheter illustrated in (A), and compression of distal stent edge after removal of externalisation wire in (B).

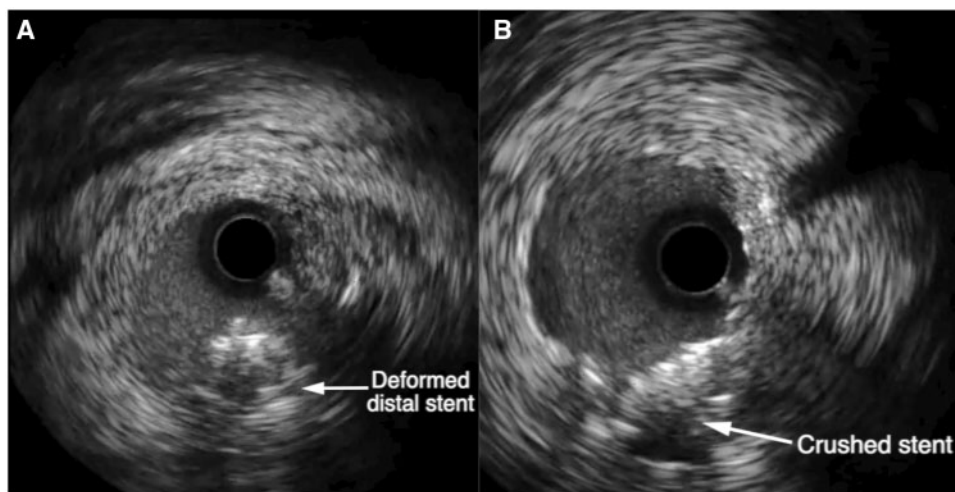


Figure 3 Intravascular ultrasound, showing deformed stent in (A), and after crushing of deformed stent and placement of new stent in (B).

wire and the retrograde microcatheter the previously placed stent in the PDA was no longer visible, with the distal stent edge now seen in the distal RCA (Figure 2B). IVUS was performed, showing multiple layers of stent at this location, consistent with LSD (Figure 3A).

The deformed segment of stent was expanded with a 3.0 mm non-compliant balloon, and a further 2.5 × 20 mm Synergy stent (Boston Scientific) was placed and post-dilated under IVUS guidance, which confirmed satisfactory expansion (Figures 3B and 4). The patient had an uneventful post-procedural course and was discharged on dual antiplatelet therapy with aspirin and clopidogrel for 12 months, followed by aspirin lifelong.

The patient's symptoms improved, and there was initially a small increment in LV function. Nine months after the procedure,

however, he was diagnosed with Stage IV Hodgkin lymphoma. During treatment with anthracycline-based chemotherapy, his LV function deteriorated, with his most recent echocardiogram showing an ejection fraction of 30%. The patient otherwise had a favourable response to chemotherapy and remained free of angina or breathlessness (NYHA class I), on no anti-anginal medications, at his most recent cardiology review in July 2020.

Discussion

Newer generation cobalt-chromium or platinum-chromium DES have thinner struts, which improves trackability (the ability to

traverse a curved or tortuous vessel path) and deliverability (the ability to deliver and position the stent across the target site), but at the expense of radial strength. Altering the distribution and reducing the number of fixed connectors between cells increases flexibility and conformability, but reduces longitudinal strength.⁷ LSD has been described via various mechanisms, including direct trauma from guide-catheters⁷ or snagging of the stent with guide-wires. Deformation has previously been reported following compression of the proximal stent edge, most frequently in ostial and left main lesions.² The resultant stent protrusion into the lumen and strut

malapposition can precipitate acute and late stent thrombosis^{8,9} and impair drug delivery, increasing the risk of restenosis.¹ To reduce the occurrence of proximal LSD, the proximal portion of the Synergy stent has five connectors, whilst the mid and distal portions (which are rarely subject to the same compressive force) have only two connectors. Thus, the distal end of the stent may be expected to be more susceptible to compressive forces than the proximal end.

In the case described, the retrograde microcatheter caused compression of the distal portion of stent at the time of removal of the externalization wire (Figures 5 and 6). The use of a proximal septal collateral channel meant entry of the retrograde microcatheter into the proximal PDA, creating a short landing zone and a marked angulation between the distal edge of the stent and the retrograde microcatheter. This increased the eccentric force applied to the distal stent edge by the retrograde microcatheter. Removal of the tensioned externalization wire must always be performed with care to avoid movement of equipment such as guide catheters or microcatheters. Ideally, the retrograde microcatheter should be placed well within the stent to avoid interaction with the distal stent struts.

Conclusions

LSD is an uncommon but recognized complication of PCI, usually occurring at the proximal stent edge. We describe here the first published case of reverse LSD, occurring due to interaction between the retrograde microcatheter and newly deployed stents in the CTO artery causing compression of the distal stent edge.

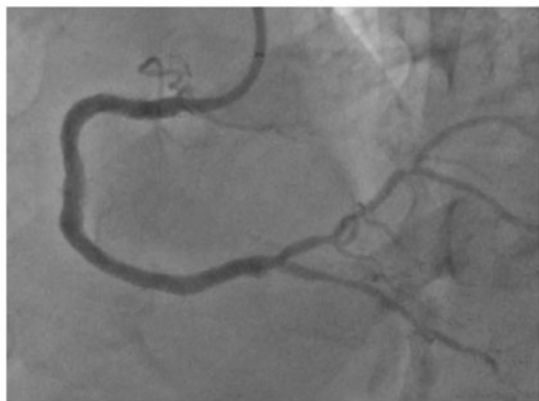

Figure 4 Angiogram showing final result after crushing of deformed stent and placement of new stent.

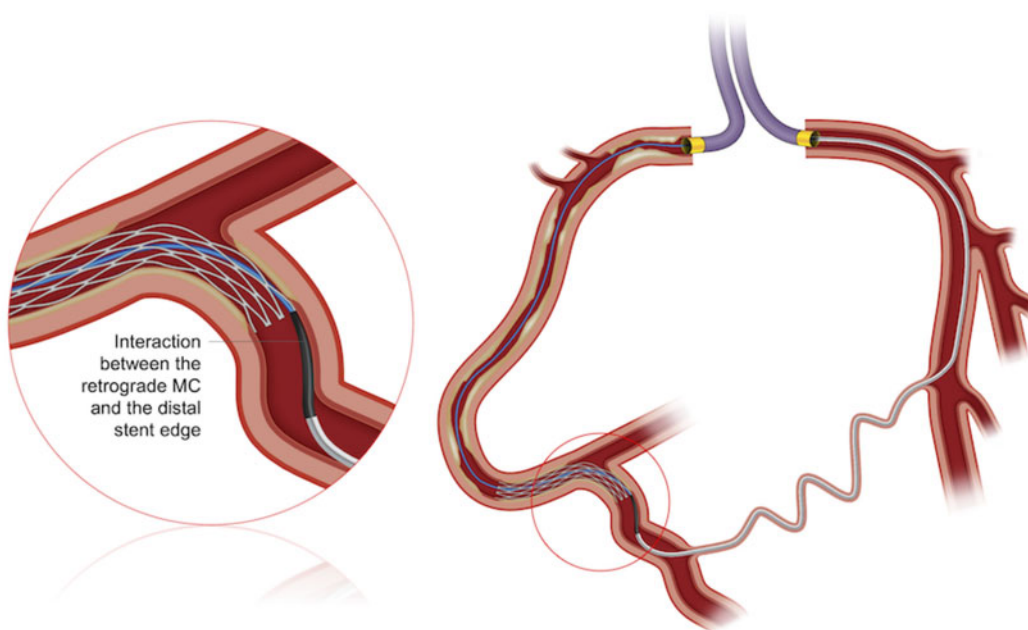


Figure 5 Graphic demonstrating interaction between retrograde microcatheter and distal stent edge.

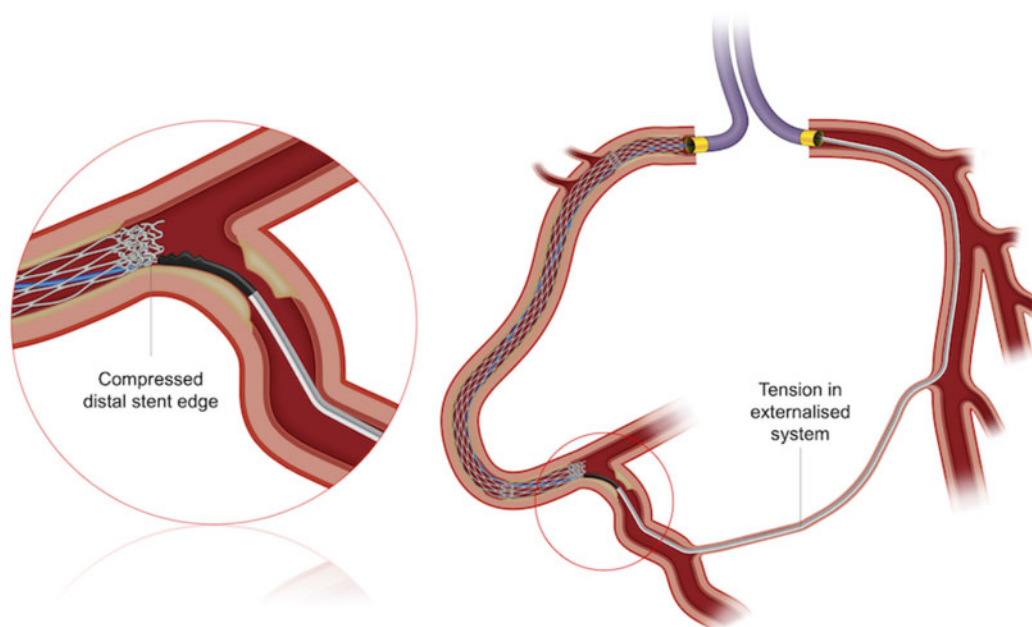


Figure 6 Graphic demonstrating compressed distal stent and tension in the externalized system.

Lead author biography



Claudia Cosgrove is an interventional cardiologist who trained in Australia before undertaking a fellowship in complex and CTO PCI with James Spratt at St George's Hospital, London.

Supplementary material

[Supplementary material](#) is available at *European Heart Journal - Case Reports* online.

Acknowledgements

Graphic design by Vascular Perspectives.

Slide sets: A fully edited slide set detailing this case and suitable for local presentation is available online as [Supplementary data](#).

Consent: The authors confirm that written consent for submission and publication of this case report including images and associated text has been obtained from the patient in line with COPE guidance.

Conflict of interest: none declared.

Funding: none declared.

References

1. Ormiston JA, Webber B, Webster MW. Stent longitudinal integrity bench insights into a clinical problem. *JACC Cardiovasc Interv* 2011;**4**:1310–1317.
2. Inaba S, Weisz G, Kobayashi N, Saito S, Dohi T, Dong L et al. Prevalence and anatomical features of acute longitudinal stent deformation: an intravascular ultrasound study. *Catheter Cardiovasc Interv* 2014;**84**:388–396.
3. Stone GW, Kandzari DE, Mehran R, Colombo A, Schwartz RS, Bailey S et al. Percutaneous recanalization of chronically occluded coronary arteries: a consensus document: part I. *Circulation* 2005;**112**:2364–2372.
4. Sapontis J, Salisbury AC, Yeh RW, Cohen DJ, Hirai T, Lombardi W et al. Early procedural and health status outcomes after chronic total occlusion angioplasty: a report from the OPEN-CTO Registry (Outcomes, Patient Health Status, and Efficiency in Chronic Total Occlusion Hybrid Procedures). *JACC Cardiovasc Interv* 2017;**10**:1523–1534.
5. Maeremans J, Walsh S, Knaapen P, Spratt JC, Avran A, Hanratty CG et al. The hybrid algorithm for treating chronic total occlusions in Europe: the RECHARGE Registry. *J Am Coll Cardiol* 2016;**68**:1958–1970.
6. Karpaliotis D, Karatasakis A, Alaswad K, Jaffer FA, Yeh RW, Wyman RM et al. Outcomes with the use of the retrograde approach for coronary chronic total occlusion interventions in a contemporary multicenter US registry. *Circ Cardiovasc Interv* 2016;**9**.
7. Hanratty CG, Walsh SJ. Longitudinal compression: a "new" complication with modern coronary stent platforms—time to think beyond deliverability? *EuroIntervention* 2011;**7**:872–877.
8. Vijayvergiya R, Sharma P, Gupta A, Goyal P, Panda P. Longitudinal stent deformation during coronary bifurcation stenting. *Cardiovasc Revasc Med* 2016;**17**:143–145.
9. Kobayashi N, Hata N, Okazaki H, Shimizu W. Longitudinal stent deformation as a cause of very late stent thrombosis: optical coherence tomography images. *Int J Cardiol* 2016;**202**:601–603.