



ORIGINAL ARTICLE

Usefulness of tumor traction with a snare and endoclips in gastric submucosal tumor resection: a propensity-score-matching analysis

Qiang Zhang *, Jian-Qun Cai and Zhen Wang

Guangdong Provincial Key Laboratory of Gastroenterology, Department of Gastroenterology, Nanfang Hospital, Southern Medical University, Guangzhou, Guangdong, P. R. China

*Corresponding author. Guangdong Provincial Key Laboratory of Gastroenterology, Department of Gastroenterology, Nanfang Hospital, Southern Medical University, No. 1838 North Guangzhou Avenue, Guangzhou, Guangdong 510515, P. R. China. Tel: +86-20-61641534; Fax: +86-20-87280770; Email: 4024313@qq.com

Abstract

Background: Endoscopic resection, including endoscopic submucosal dissection (ESD) and endoscopic full-thickness resection (EFR), was used to resect small gastric submucosal tumors (SMTs). Our team explored a method of tumor traction using a snare combined with endoclips to assist in the resection of SMTs. This study aims to explore the safety and effectiveness of the method.

Methods: This research performed a propensity-score-matching (PSM) analysis to compare ESD/EFR assisted by a snare combined with endoclips (ESD/EFR with snare traction) with conventional ESD/EFR for the resection of gastric SMTs.

Comparisons were made between the two groups, including operative time, *en bloc* resection rate, perioperative complications, and operation-related costs.

Results: A total of 253 patients with gastric SMTs resected between January 2012 and March 2019 were included in this study. PSM yielded 51 matched pairs. No significant differences were identified between the two groups in perioperative complications or the costs of disposable endoscopic surgical accessories. However, the ESD/EFR-with-snare-traction group had a shorter median operative time (39 vs 60 min, $P = 0.005$) and lower rate of *en bloc* resection (88.2% vs 100%, $P = 0.027$).

Conclusions: ESD/EFR with snare traction demonstrated a higher efficiency and *en bloc* resection rate for gastric SMTs, with no increases in perioperative complications and the costs of endoscopic surgical accessories. Therefore, the method seems an appropriate choice for the resection of gastric SMTs.

Key words: endoscopic submucosal dissection; endoscopic full-thickness resection; gastric submucosal tumor; snare; endoclip

Submitted: 14 October 2019; Revised: 30 December 2019; Accepted: 6 February 2020

© The Author(s) 2020. Published by Oxford University Press and Sixth Affiliated Hospital of Sun Yat-sen University

This is an Open Access article distributed under the terms of the Creative Commons Attribution Non-Commercial License (<http://creativecommons.org/licenses/by-nc/4.0/>), which permits non-commercial re-use, distribution, and reproduction in any medium, provided the original work is properly cited.

For commercial re-use, please contact journals.permissions@oup.com

Introduction

For relatively small gastric submucosal tumors (SMTs) with no high-risk endoscopic ultrasonography (EUS) features (including ulceration, irregular border, internal heterogeneity, and enlargement of regional lymph node), follow-up with gastroscopy or EUS is recommended [1]. However, there are certain clinical issues, such as poor follow-up compliance [2], psychological burden on the patients, and canceration risk [3, 4]. With the development of endoscopic technology, endoscopic resection for these tumors has gradually proven to be effective and safe [5–10].

Most gastric SMTs originate in the muscularis propria, which poses a considerable challenge for endoscopic resection; therefore, research into safe and effective resection methods is required. Currently, the use of endoscopic mucosal traction is widely accepted to facilitate the resection of gastrointestinal mucosal neoplasia [11, 12]. However, there are few alternative methods and studies on the traction of gastric SMTs. Our team explored a tumor-traction method to assist endoscopic submucosal dissection (ESD) and endoscopic full-thickness resection (EFR) using a snare with endoclips (ESD/EFR with snare traction). In this study, ESD/EFR with snare traction was compared with ESD/EFR to evaluate the effectiveness and safety of the former through a propensity-score-matching (PSM) analysis.

Materials and methods

Study subjects and study design

Patients with SMTs who underwent ESD or EFR at the Digestive Endoscopy Centre in Guangzhou Nanfang Hospital, China, between January 2012 and March 2019, were retrospectively included in this study. Exclusion criteria were as follows: (i) missing data on tumor size or operative time, (ii) tumor involving the cardiac orifice, and (iii) post-operative wound closed with an over-the-scope clip (OTSC). All the patients underwent preoperative EUS and were informed of the benefits and risks of the procedure. They provided written informed consent before the procedure. Data were collected in an anonymous manner. This retrospective study was approved by Nanfang Hospital's institutional review board.

According to whether the snare traction was used in ESD/EFR, the included patients were classified into the ESD/EFR-with-snare-traction group and the conventional ESD/EFR group. For gastric ESD, it has been reported that the size and location of lesions are factors that affect the operative time and difficulty [13–16]. Thus, this study conducted PSM, which included the following predictive factors: specimen size, lesion location (whether the location was in the greater gastric curvature), operative methods, methods of wound closure, surgical experience of the operator, and post-operative pathology. Using multivariate logistic regression, the disposal factor (whether to use snare traction) was the dependent variable; the above predictive factors were considered as the independent variables for calculating the propensity values. According to propensity value, the subjects in the ESD/EFR-with-snare-traction group and the conventional ESD/EFR group were matched at a 1:1 ratio. Furthermore, a Hosmer-Lemeshow test and a C-statistic test were applied to assess the fitting accuracy of the propensity-score model.

Definition of the collected data

The following data were collected for each patient: age, gender, location, tumor size, post-operative pathology, EUS assessment of tumor origin, experience of endoscopic operator, operative methods, intraoperative use of a snare for high-frequency electric tumor resection, intraoperative and post-operative complications (bleeding, perforation, and infection), operative time, results of tumor removal, post-operative wound closure, costs of disposable surgical accessories, total hospitalization costs, and post-operative length of stay. The complication of intraoperative perforation did not include the intentional perforation caused by EFR.

The operator was defined as unskilled if they had operated on <30 cases and as skilled if they had operated on ≥30 cases [17, 18]. Operative time referred to the duration between marking the tumor to the complete closure of the wound. Intraoperative high-frequency electric resection referred to the removal of SMTs directly using a snare (to reduce the risk of continued dissection); however, the potential difficulties in ensuring the integrity of tumor resection posed by this method were acknowledged. The results of tumor removal included *en bloc* resection, piecewise resection, and surgical failure. Post-operative wound closures included the use of endoclips, endoclips combined with purse-string sutures with nylon, and endoclips combined with reserved gastric-mucosa sutures. The use of endoclips combined with reserved gastric-mucosa sutures was reported in our previous study, in which the preserved gastric mucosa was seen to facilitate wound closure [19, 20]. Post-operative pathology included gastrointestinal stromal tumors (GISTs), leiomyomas, heterotopic pancreas, and neuroendocrine tumors. Disposable surgical accessories, the cost of which could directly influence an increase in medical costs for tumor-traction procedures, mainly included endoscopic knives (e.g. IT knife and hook knife), snares, endoclips, injection needles, and hemostatic forceps. Post-operative fever (>38°C) was recorded as an evaluation index for post-operative infection.

ESD/EFR with snare-traction procedure

This study used the following equipment: a GIFQ260J single-channel endoscope (Olympus Optical Co, Ltd, Tokyo, Japan), endoclips (HXROCC-D-26-195-C) (MICRO-TECH, China), (HX-610-090L) (Olympus, Tokyo, Japan), (M00522610) (Boston Scientific Corporation, USA), and a snare with an outer diameter of 1.8 mm (SD-221L-25) (Olympus, Japan). All the endoscopic operations were performed by three endoscopic surgeons who were experienced in ESD operation.

Conventional ESD and EFR are well-known procedures [21–23]. For ESD/EFR with snare traction, several techniques of performing traction using a snare with endoclips are used, including external traction and internal traction with mucosal preservation, and external traction and internal traction with non-mucosal preservation. The snare was delivered into the stomach by inverse insertion from the head end of the endoscope into the endoscopic working channel (Supplementary Figure 1).

For external traction with mucosal preservation (Figure 1 and Supplementary Video 1), a 1/2–3/4 circumferential incision of the gastric mucosa along the margin of the tumor was made followed by the fixation of the snare to the incised mucosa. Under mucosal traction, the submucosa was dissected until the tumor was fully exposed. Furthermore, the snare was fixed directly to the tumor exposing the muscularis propria side of the

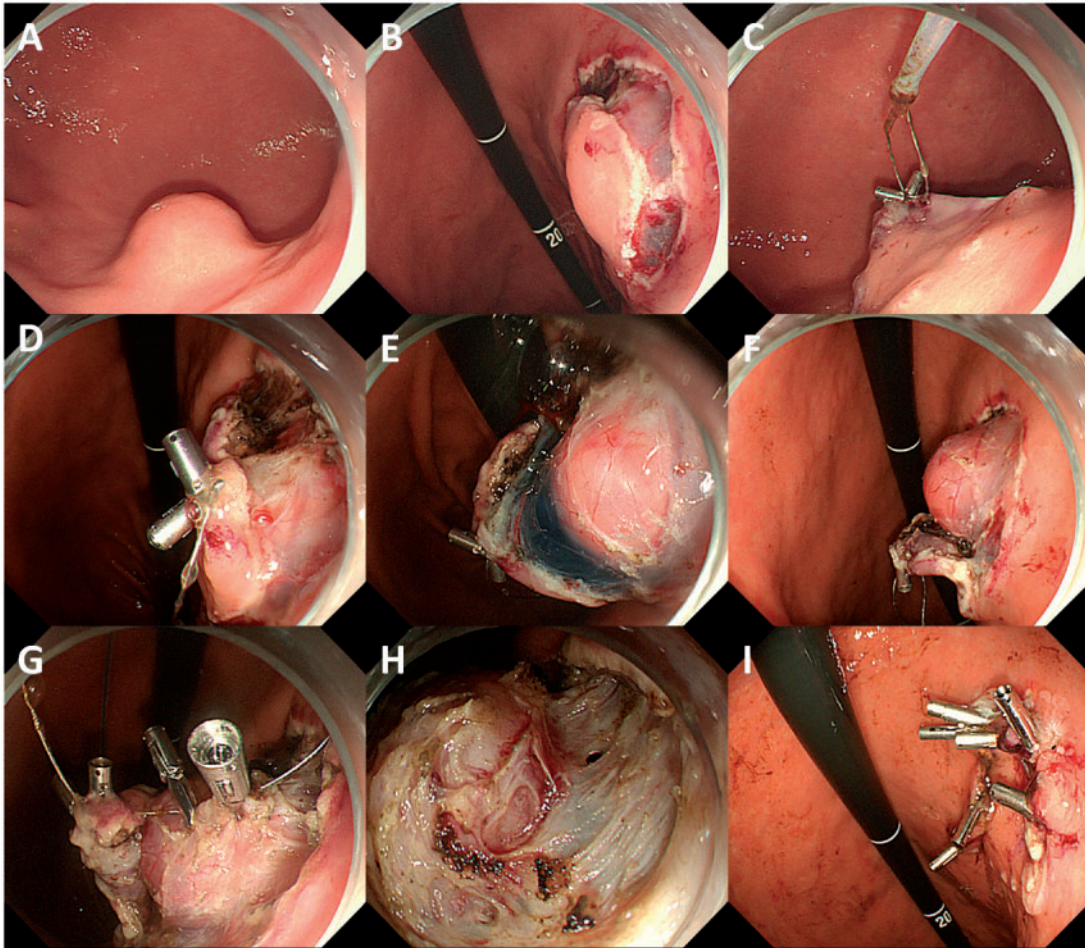


Figure 1. A submucosal tumor was resected by endoscopic submucosal dissection with the aid of external traction with mucosal preservation. (A) The tumor was located in the greater curvature of the lower part of the stomach. (B) A 1/2–3/4 circumferential gastric mucosa was incised along the margin of the tumor. (C) and (D) A snare was fixed to the incised mucosa. (E) and (F) The submucosa was dissected until the tumor was fully exposed under mucosal traction. (G) The snare was fixed directly to the tumor tissue. (H) The muscularis propria side of the tumor was exposed under traction. (I) The wound was closed with the reserved gastric mucosa combined with endoclips.

tumor. Following tumor removal, endoclips combined with the reserved gastric mucosa could be used for wound closure. External traction with non-mucosal preservation is shown in [Supplementary Video 2](#).

For internal traction with non-mucosal preservation ([Figure 2](#)), after the gastric mucosa was circumferentially incised along the edge of the tumor, the snare was fixed to the incised mucosa (fixed site No. 1) and also to the normal mucosa on the opposite side of the tumor (fixed site No. 2). Mutual traction between the two fixed sites was subsequently applied through the operation of the snare handle *in vitro* to achieve the effect of tumor traction. For internal and external traction with non-mucosal preservation for the same tumor ([Figure 3](#)), after making a circumferential gastric mucosal incision along the edge of the tumor, the snare was fixed to the incised gastric mucosa with endoclips (fixed site No. 1) and also to the normal mucosa on the opposite side of the tumor (fixed site No. 2) to achieve internal traction. Fixed site No. 2 was removed before the snare was pulled to achieve external traction.

The preferred methods were non-mucosal preservation and external traction. In cases in which tumors were at risk of EFR and when the availability of endoscopic instruments (such as

OTSC and purse-string sutures using a nylon rope combined with endoclips for large-sized wound closure) was limited, mucosal preservation was an alternative option. The technique of internal traction could be used to assist external traction and to adjust the direction of the traction. For some flat, deep tumors, the snare was fixed directly to the tumor tissue to achieve more effective traction, as illustrated in [Figure 1G](#) and [Supplementary Figure 2](#).

Statistical analysis

Continuous variables that were normally distributed were expressed as mean (standard deviation) values, whereas those that were not normally distributed were presented as median (range) values. Either a chi-squared test or Fisher's exact test was applied to the variables, the Mann-Whitney *U* test was used for continuous and unusually distributed variables, and the *t*-test was employed for continuous and normally distributed variables. The value of $P < 0.05$ (two-sided) was considered significant for all the tests. All analyses were performed using the SPSS statistical software package (version 25).

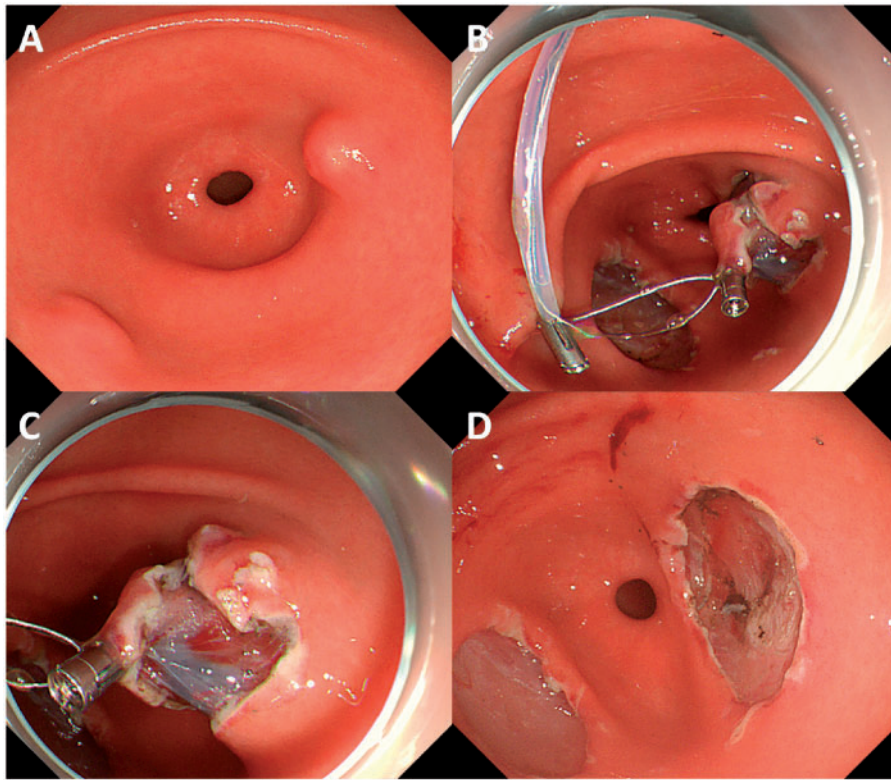


Figure 2. A submucosal tumor was resected by endoscopic submucosal dissection with the aid of internal traction with non-mucosal preservation. (A) The tumor was located in the posterior wall of the gastric antrum. (B) After the gastric mucosa was circumferentially incised, a snare was fixed to the incised mucosa (fixed site No. 1) and also to the normal mucosa on the opposite side of the tumor (fixed site No. 2). (C) Mutual traction between the two fixed sites was performed through the operation of the snare handle *in vitro* to fully expose the visual field of operation. (D) The wound.

Results

As revealed in Figure 4, a total of 264 gastric SMTs were resected with ESD or EFR during the study period. Ultimately, this study included 253 cases following the exclusion of 5 cases due to missing data, 4 cases due to lesions involving the cardiac orifice, and 2 cases in which OTSC was used for wound closure. A PSM analysis yielded 51 matched pairs. The propensity-score model was well calibrated (Hosmer-Lemeshow test, $P = 0.888$) and discriminated well between the two groups (C-statistic = 0.740).

Baseline characteristics before and after PSM

Before PSM, there were significant differences in the operator's experience and operative methods between the two groups (Table 1). After PSM, patient characteristics and surgical-related indicators were balanced between the two groups (Table 1).

Treatment outcomes before and after PSM

Before PSM, the ESD/EFR-with-snare-traction group had a shorter median operative time ($P = 0.015$), less use of snares for the high-frequency electric resection of tumors ($P = 0.001$), and lower rate of intraoperative perforations ($P = 0.030$). However, there was no significant difference between the two groups in the results of tumor removal, post-operative complications, post-operative length of hospital stay, the costs of disposable surgical accessories, or total hospitalization costs (Table 2).

After PSM, the ESD/EFR group revealed a shorter median operative time (39 vs 60 min, $P = 0.005$), less use of snares for high-

frequency electric tumor resection (0.0% vs 25.5%, $P < 0.001$), lower rate of *en bloc* resection (88.2% vs 100%, $P = 0.027$), and higher total hospitalization costs (3,476 vs 4,413 USD, $P = 0.017$). However, no significant differences were found in post-operative lengths of stay, post-operative complications, or the costs of disposable surgical accessories (Table 2).

Discussion

To our knowledge, this is the first study to compare conventional ESD/EFR with ESD/EFR with snare traction for gastric SMTs via a PSM analysis. ESD/EFR with snare traction could potentially significantly reduce the operation time and operative difficulty, leading to a higher *en bloc* resection rate. Although this method requires additional equipments (a snare and endoclips for tumor traction), there was no increase in the total cost of endoscopic accessories for the operation.

Some mucosal traction methods have been used to effectively assist ESD for gastrointestinal mucosal neoplasia, among which the line endoclip is the most widely used [24]. At present, there are very few reports on the resection of gastric SMTs with tumor traction. This study investigated tumor traction with a snare and endoclips to assist the resection of gastric SMTs. The method has the following operational features: (i) *in vitro*, real-time adjustment of the pulling force is possible by snare-handle adjustment; (ii) when the external traction fails to achieve the expected traction effect, internal traction can be achieved by adjusting the traction direction; (iii) when the pulling force is relatively large, the snare can be fixed into position with multiple endoclips, which increases the stability of the fixture to

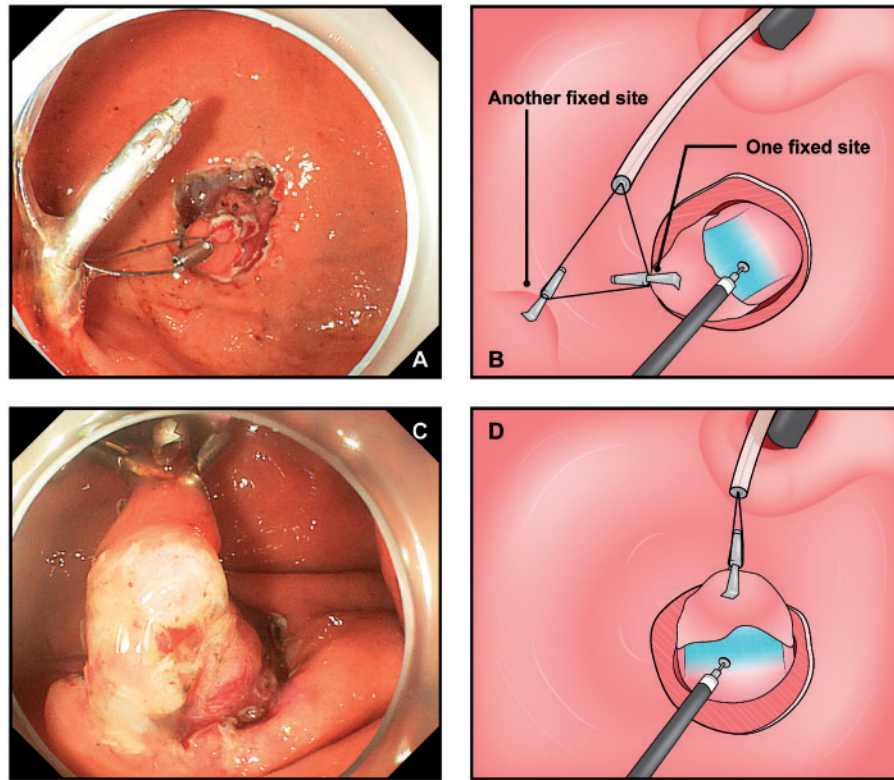


Figure 3. A submucosal tumor in the greater curvature of the gastric fundus was resected with the aid of internal and external traction with non-mucosal preservation. (A) and (B) A snare was fixed to the incised gastric mucosa with endoclips (fixed site No. 1) and also to the normal mucosa on the opposite side of the tumor (fixed site No. 2) to achieve internal traction. (C) and (D) The fixed site No. 2 is removed and external traction is achieved by pulling the snare.

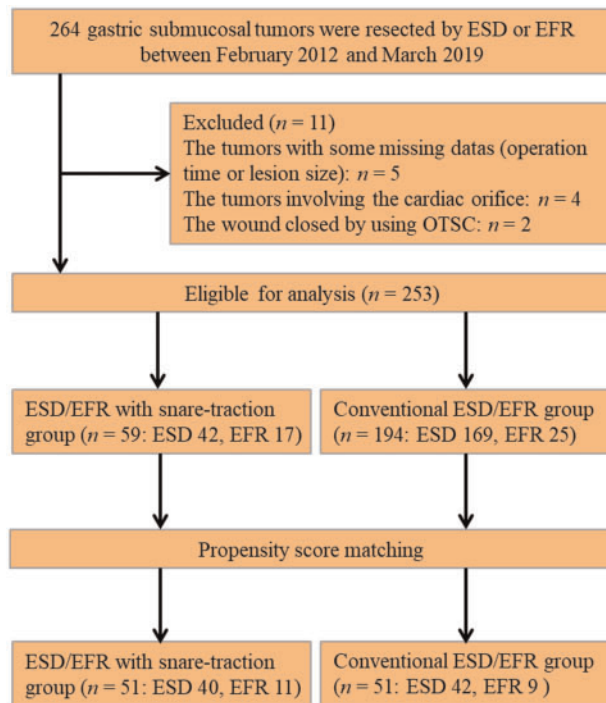


Figure 4. Flowchart of tumors enrolled in this study.

ESD, endoscopic submucosal dissection; EFR, endoscopic full-thickness resection; OTSC, over-the-scope clip.

prevent snare pull-off; and (iv) the fixed position of the snare on the incised mucosa or tumor tissue can be adjusted in real time to improve the traction effect. Lü *et al.* [25] reported that a snare was used to assist ESD with tumor traction for a SMT in the gastric fundus. However, their method (which was to hitch onto and then pull the mucosa over the tumor with a snare) was only presented in the form of a case report. In addition, two studies reported mucosal traction with a snare combined with endoclips to assist ESD for mucosal neoplasias and demonstrated an alternative way of achieving mucosal traction using this equipment [26, 27].

In total, this study included 253 gastric SMTs; 80% were GISTs, leiomyomas, and heterotopic pancreas. Over 80% of the tumors originated in the muscularis propria with a median size of 1.5 cm (ranging from 0.8 to 3.5 cm). In our practice, the tumor location did not influence the use of snare traction. A total of 76% of the tumors were located in the middle and upper parts of the stomach, and 50% were located in the greater curvature of the stomach; these locations are all difficult operating sites. ESD/EFR with snare traction had a shorter median operative time of 39.0 min (ranging from 9 to 120 min) compared with ESD/EFR. Two previous studies reported that line-endoclip traction to assist EFR for gastric SMTs significantly reduced the operative time [28, 29]. However, those studies only assessed the effect of line-endoclip traction in a relatively small sample size of EFR cases; one study reported the size of the resected tumor as 0.88 ± 0.33 cm and an operative time of 10.8 ± 2.8 min in the traction group [28], with the other stating a tumor size and operative time of 1.6 ± 0.4 cm and 71.9 ± 30.5 min, respectively [29]. The operative time varied considerably in these studies; this

Table 1. Baseline characteristics of included patients with gastric submucosal tumors before and after propensity-score matching (PSM)

Characteristic	Before PSM			After PSM		
	ESD/EFR with snare traction (n = 59)	Conventional ESD/EFR (n = 194)	P-value	ESD/EFR with snare traction (n = 51)	Conventional ESD/EFR (n = 51)	P-value
Age, years, median (range)	49 (20–72)	50 (18–76)	0.972	50 (22–72)	47 (11–74)	0.160
Male, n (%)	25 (42.4)	84 (43.3)	0.900	21 (41.2)	24 (47.1)	0.550
Location of lesions, n (%)			0.64			0.420
Upper	35 (59.3)	83 (42.8)		30 (58.8)	26 (51.0)	
Middle	11 (18.6)	41 (21.1)		9 (17.6)	7 (13.7)	
Lower	13 (22.0)	70 (36.1)		12 (23.5)	18 (35.3)	
Position of lesions, n (%)			0.065			1.000
Greater curvature	33 (55.9)	82 (42.3)		26 (51.0)	26 (51.0)	
Others	26 (44.1)	112 (57.7)		25 (49.0)	25 (49.0)	
Specimen size, cm, median (range)	1.5 (0.8–3.5)	1.65 (0.8–5.5)	0.860	1.5 (0.8–3.5)	1.8 (0.8–3.5)	0.515
Pathology, n (%)			0.065			0.203
Gastrointestinal stromal tumor	21 (35.6)	76 (39.2)		19 (37.2)	18 (35.3)	
Leiomyoma	12 (20.3)	39 (20.1)		11 (21.6)	5 (9.8)	
Ectopic pancreas	10 (16.9)	53 (27.3)		10 (19.6)	18 (35.3)	
Others	16 (27.1)	26 (13.4)		11 (21.6)	10 (19.6)	
Origin of tumors, n (%)			0.096			0.119
Submucosa	8 (13.6)	46 (23.7)		6 (11.8)	12 (23.5)	
Muscularis propria	51 (86.4)	148 (76.3)		45 (88.2)	39 (76.5)	
Procedure-related characteristics						
Operator's experience			<0.001			1.000
Skilled	56 (94.9)	136 (70.1)		48 (94.1)	48 (94.1)	
Unskilled	3 (5.1)	58 (29.9)		3 (5.9)	3 (5.9)	
Operative method, n (%)			0.004			0.618
ESD	42 (71.2)	169 (87.1)		40 (78.4)	42 (82.4)	
EFR	17 (28.8)	25 (12.9)		11 (21.6)	9 (17.6)	
Suture of wound, n (%)			0.110			0.102
Endoclip	25 (42.4)	68 (35.1)		21 (41.1)	24 (47.1)	
Endoclip combined with nylon rope	5 (8.5)	8 (4.1)		2 (3.9)	1 (2.0)	
Endoclip combined with retained mucosa	15 (25.4)	42 (21.6)		14 (27.5)	5 (9.8)	
No closure	14 (23.7)	76 (39.2)		14 (27.5)	21 (41.1)	

ESD, endoscopic submucosal dissection; EFR, endoscopic full-thickness resection.

Table 2. Treatment outcomes before and after propensity-score matching (PSM)

Outcome	Before PSM			After PSM		
	ESD/EFR with snare traction (n = 59)	Conventional ESD/EFR (n = 194)	P-value	ESD/EFR with snare traction (n = 51)	Conventional ESD/EFR (n = 51)	P-value
Operative time, min, median (range)	40 (9–120)	50 (6–220)	0.015	39 (9–120)	60 (8–220)	0.005
Use of snare, n (%) ^a	0 (0.0)	32 (16.5)	0.001	0 (0.0)	13 (25.5)	<0.001
Results of tumor removal, n (%)			0.124			0.027
En bloc resection	59 (100)	180 (92.8)		51 (100)	45 (88.2)	
Piecemeal resection	0 (0.0)	12 (6.2)		0 (0.0)	5 (9.8)	
Failed operation	0 (0.0)	2 (1.0)		0 (0.0)	1 (2.0)	
Intraoperative perforation, n (%)	4 (6.8)	36 (18.6)	0.030	4 (7.8)	8 (15.7)	0.219
Post-operative delayed perforation, n (%)	0 (0.0)	1 (0.5)	1.000	0 (0.0)	1 (2.0)	1.000
Post-operative delayed hemorrhage, n (%)	0 (0.0)	6 (3.1)	0.341	0 (0.0)	0 (0.0)	–
Post-operative fever (>38°C), n (%)	3 (5.1)	16 (8.2)	0.577	3 (5.9)	4 (7.8)	1.000
Total hospitalization stay, days, median (range)	9 (4–19)	9 (3–23)	0.355	9 (4–19)	8 (3–23)	0.101
Post-operative hospitalization stay, days, median (range)	5 (3–12)	5 (3–15)	0.250	5 (3–12)	5 (3–15)	0.090
Total hospitalization costs, USD, median (range)	4,424 (2,652–7,033)	4,035 (1,241–12,795)	0.054	4,413 (2,652–7,033)	3,476 (1,309–12,795)	0.017
Costs of disposable surgical accessories, USD, median (range)	1,482 (588–2,183)	1,223 (451–5,575)	0.088	1,400 (588–2,119)	1,426 (486–5,575)	0.396

^aA snare was directly used for intraoperative high-frequency electric resection of submucosal tumor, but not for tumor traction.
ESD, endoscopic submucosal dissection; EFR, endoscopic full-thickness resection.

may be associated with the tumor location/size and the operator's experience. In this study, 253 tumors resected by ESD or EFR were included. For these cases, a PSM analysis was performed to reduce the selection bias in the basic data of the two groups; therefore, this study was relatively accurate and stable in evaluating ESD/EFR with snare traction for these tumors.

At present, endoscopic resection for relatively small gastric SMTs has a high *en bloc* resection rate and high security [5–10]. In this research, tumor traction was found to improve the *en bloc* resection rate and reduce the difficulty of the operation; however, in the control group, high-frequency electric snare resection was performed during the operation in 25.5% of cases with a piecemeal resection rate of 9.8%. Furthermore, there were no significant differences in the intraoperative and postoperative complications (bleeding, perforation, and infection) between the two groups, which is consistent with previous reports [28, 29].

For each case of tumor traction with a snare combined with endoclips, the average cost of the endoclips was 104.1 USD (34.7 USD/1 endoclip×3 endoclips) and the cost of a snare was 84.0 USD. These costs were included in the total cost of disposable endoscopy accessories. Nevertheless, this research revealed that there was no increase in the total cost of endoscopic accessories for these cases despite the use of the additional equipment. This could be attributed to the reduction by tumor traction in both operative time and difficulty, thus reducing the costs of submucosal injection, wound closure, or hemostasis. These factors could compensate for the increased cost of the tumor-traction procedure. In the ESD/EFR-with-snare-traction group, the total median hospitalization cost increased. This increase was largely due to the additional costs of disposable endoscopy accessories, medical treatment, and preoperative evaluation. Hence, the increase in this part of the cost is multifaceted and may be influenced by other considerations apart from tumor traction.

This study has the following limitations. First, this was a retrospective analysis. In order to reduce its shortcomings, a PSM analysis was performed to reduce the selection bias of the basic data. Second, this study was single-centered; it reflected only the operational experience at our center and was not representative of a wider cross section. Therefore, future multicenter studies are required. Third, the study did not compare snare-endoclip and line-endoclip traction; therefore, the research was unable to make a definitive comparison of the advantages and disadvantages of the two methods.

In conclusion, ESD/EFR with snare traction is an appropriate choice for the resection of gastric SMTs. Further multicenter comparative studies and cost-effectiveness analyses are necessary for a more comprehensive assessment of snare-endoclip traction.

Supplementary Data

Supplementary data is available at *Gastroenterology Report* online.

Authors' contributions

Q.Z. designed the project, analysed and interpreted the data, and drafted the manuscript. Q.Z., J.Q.C., and Z.W. performed endoscopic operations. All authors read and approved the final manuscript.

Funding

No source of funding was provided for this study.

Acknowledgements

None.

Conflicts of interest

None declared.

References

1. Nishida T, Blay JY, Hirota S et al. The standard diagnosis, treatment, and follow-up of gastrointestinal stromal tumors based on guidelines. *Gastric Cancer* 2016;**19**:3–14.
2. Kushnir VM, Keswani RN, Hollander TG et al. Compliance with surveillance recommendations for foregut subepithelial tumors is poor: results of a prospective multicenter study. *Gastrointest Endosc* 2015;**81**:1378–84.
3. Fletcher CD, Berman JJ, Corless C et al. Diagnosis of gastrointestinal stromal tumors: a consensus approach. *Hum Pathol* 2002;**33**:459–10.
4. Miettinen M, Sobin LH, Lasota J. Gastrointestinal stromal tumors of the stomach: a clinicopathologic, immunohistochemical, and molecular genetic study of 1765 cases with long-term follow-up. *Am J Surg Pathol* 2005;**29**:52–68.
5. Cai MY, Martin Carreras-Presas F, Zhou PH. Endoscopic full-thickness resection for gastrointestinal submucosal tumors. *Dig Endosc* 2018;**30**:17–24.
6. Abe N, Takeuchi H, Ohki A et al. Comparison between endoscopic and laparoscopic removal of gastric submucosal tumor. *Dig Endosc* 2018;**30**:7–16.
7. Joo MK, Park JJ, Kim H et al. Endoscopic versus surgical resection of GI stromal tumors in the upper GI tract. *Gastrointest Endosc* 2016;**83**:318–26.
8. Zhang Y, Mao XL, Zhou XB et al. Long-term outcomes of endoscopic resection for small (≤ 4.0 cm) gastric gastrointestinal stromal tumors originating from the muscularis propria layer. *World J Gastroenterol* 2018;**24**:3030–7.
9. Ye LP, Zhang Y, Luo DH et al. Safety of endoscopic resection for upper gastrointestinal subepithelial tumors originating from the muscularis propria layer: an analysis of 733 tumors. *Am J Gastroenterol* 2016;**111**:788–96.
10. Park JJ. Long-term outcomes after endoscopic treatment of gastric gastrointestinal stromal tumor. *Clin Endosc* 2016;**49**:232–4.
11. Tsuji K, Yoshida N, Nakanishi H et al. Recent traction methods for endoscopic submucosal dissection. *World J Gastroenterol* 2016;**22**:5917–26.
12. Fukami N. What we want for ESD is a second hand! Traction method. *Gastrointest Endosc* 2013;**78**:274–6.
13. Chung IK, Lee JH, Lee SH et al. Therapeutic outcomes in 1000 cases of endoscopic submucosal dissection for early gastric neoplasms: Korean ESD Study Group multicenter study. *Gastrointest Endosc* 2009;**69**:1228–35.
14. Imagawa A, Okada H, Kawahara Y et al. Endoscopic submucosal dissection for early gastric cancer: results and degrees of technical difficulty as well as success. *Endoscopy* 2006;**38**:987–90.
15. Nagata S, Jin YF, Tomoeda M et al. Influential factors in procedure time of endoscopic submucosal dissection for gastric cancer with fibrotic change. *Dig Endosc* 2011;**23**:296–301.

16. Ono S, Kato M, Nakagawa M et al. Outcomes and predictive factors of 'not self-completion' in gastric endoscopic submucosal dissection for novice operators. *Surg Endosc* 2013;27:3577–83.
17. Yoshida M, Kakushima N, Mori K et al. Learning curve and clinical outcome of gastric endoscopic submucosal dissection performed by trainee operators. *Surg Endosc* 2017;31:3614–22.
18. Sun C, Zheng Z, Wang B. Learning curve for endoscopic submucosal dissection of gastric submucosal tumors: is it more difficult than it may seem?. *J Laparoendosc Adv Surg Tech A* 2014;24:623–7.
19. Zhang Q, Li Y, Lian ZY et al. A modified endoscopic method for resection of gastric submucosal tumor. *Surg Endosc* 2018;32:536–43.
20. Zhang Q, Li Y, Meng Y et al. Should the integrity of mucosa be considered in endoscopic resection of gastric submucosal tumors? *Gastroenterology* 2016;150:822–4.
21. Abe N, Takeuchi H, Ooki A et al. Recent developments in gastric endoscopic submucosal dissection: towards the era of endoscopic resection of layers deeper than the submucosa. *Dig Endosc* 2013;25:64–70.
22. Catalano F, Rodella L, Lombardo F et al. Endoscopic submucosal dissection in the treatment of gastric submucosal tumors: results from a retrospective cohort study. *Gastric Cancer* 2013;16:563–70.
23. Zhou PH, Yao LQ, Qin XY et al. Endoscopic full-thickness resection without laparoscopic assistance for gastric submucosal tumors originated from the muscularis propria. *Surg Endosc* 2011;25:2926–31.
24. Suzuki S, Gotoda T, Kobayashi Y et al. Usefulness of a traction method using dental floss and a hemoclip for gastric endoscopic submucosal dissection: a propensity score matching analysis (with videos). *Gastrointest Endosc* 2016;83:337–46.
25. Lü MH, Fu KI, Wang ZQ et al. Traction with snare during endoscopic submucosal dissection of a gastrointestinal stromal tumor in the gastric fundus. *Endoscopy* 2016;48:E183–5.
26. Baldaque-Silva F, Vilas-Boas F, Velosa M et al. Endoscopic submucosal dissection of gastric lesions using the 'yo-yo technique'. *Endoscopy* 2013;45:218–21.
27. Yoshida N, Doyama H, Ota R et al. The clip-and-snare method with a pre-looping technique during gastric endoscopic submucosal dissection. *Endoscopy* 2014;46:E611–2.
28. Shi Q, Li B, Qi ZP et al. Clinical values of dental floss traction assistance in endoscopic full-thickness resection for submucosal tumors originating from the muscularis propria layer in the gastric fundus. *J Laparoendosc Adv Surg Tech A* 2018;28:1261–5.
29. Li J, Meng Y, Ye S et al. Usefulness of the thread-traction method in endoscopic full-thickness resection for gastric submucosal tumor: a comparative study. *Surg Endosc* 2019;33:2880–5.