




Since January 2020 Elsevier has created a COVID-19 resource centre with free information in English and Mandarin on the novel coronavirus COVID-19. The COVID-19 resource centre is hosted on Elsevier Connect, the company's public news and information website.

Elsevier hereby grants permission to make all its COVID-19-related research that is available on the COVID-19 resource centre - including this research content - immediately available in PubMed Central and other publicly funded repositories, such as the WHO COVID database with rights for unrestricted research re-use and analyses in any form or by any means with acknowledgement of the original source. These permissions are granted for free by Elsevier for as long as the COVID-19 resource centre remains active.



Role of the otolaryngologist in nasopharyngeal swab training: A case report and review of the literature

Mark Liu^a, Prithwijit Roychowdhury^a, Christopher J. Ito^{b,*}

^a University of Massachusetts Medical School, 55 N Lake Ave, Worcester, MA, 01655, United States

^b Department of Otolaryngology Head and Neck Surgery, UMass Memorial Medical Center, 55 N Lake Ave, Worcester, MA, 01655, United States

ARTICLE INFO

Keywords:

COVID-19
Nasopharyngeal swab
Epistaxis
Education
Otolaryngology

ABSTRACT

Nasopharyngeal swabs are commonly done in the medical field for a multitude of reasons, and they recently have been an essential component of widespread testing to control the spread of COVID-19. Although rare, improper technique when performing nasopharyngeal swabs has the potential to lead to injury or misleading test results. We present a case of uncontrolled epistaxis requiring hospitalization following a routine nasopharyngeal swab in a healthy patient. Both the complexity and variability of the anatomy of the nasopharynx can contribute to poor swabbing technique. Otolaryngologists should be encouraged to educate and support other healthcare workers to improve the yield and reduce the risk of harm due to nasopharyngeal swabs. Increased comfort levels with performing nasopharyngeal swabs will also improve the sensitivity of screening tests for common respiratory viruses such as influenza, Epstein-Barr virus (EBV), or bacteria such as *Staphylococcus aureus*.

1. Introduction

The practice of nasopharyngeal swabbing has been thrust into the public spotlight by the COVID-19 pandemic, caused by the SARS-CoV-2 virus. With the pandemic's unprecedented upheavals of daily life, the need to mitigate both the pandemic's spread and impact has emerged as a priority across the world. Due to the known asymptomatic clinical presentation of certain individuals, effective and widespread diagnostic testing is generally viewed as a key determinant in public efforts to assess the prevalence of the virus as well as control its spread [1].

A broad array of sampling techniques has been implemented by healthcare facilities across the world, including but not limited to testing for the presence of SARS-CoV-2 in bronchoalveolar lavage fluids, sputum, nasopharyngeal swabs, oropharyngeal swabs, nasal swabs, and saliva [2,3]. With the inherent infectious risks of testing for SARS-CoV-2, the ideal test should combine the ability to detect the disease early in its progression and to minimize exposure of healthcare workers (HCWs) to patients without compromising sampling technique [4]. Widely seen as a cost-effective and sensitive test [5,6], the nasopharyngeal swab is currently among the recommended tests by the U.S. Centers for Disease Control and Prevention (CDC) [7]. If performed correctly, the swab is able to directly sample the posterior nasopharyngeal wall, which carries

a high load of SARS-CoV-2 virus, especially early in the progression of disease [8–11].

However, as more HCWs from a diverse background are recruited to perform nasopharyngeal swabs, the appropriateness of doing so without adequate training has been called into question [12–15]. Although for the vast majority of cases, the swab is a safe and effective tool to combat the pandemic, HCWs should be aware of the shortcomings of this test. The nasopharynx is an anatomically complex and variable region of the body in the general population that is not directly visible to HCWs without the proper equipment [11]. Poor familiarity with common structural variations such as nasal septum deviations, nasal polyposis, and turbinate hypertrophy may impede proper insertion of swabs and sampling of the posterior wall of the nasopharynx [11,16]. Despite its external appearance implying its superior position to the nostril, the nasopharynx is best reached posterior to the insertion of the swab [17].

Most obviously, poor familiarity with the anatomy can predispose to injury that can lead to hospitalization. In patients with preexisting rhinological disorders or structural differences including but not limited to vascular lesions, patent sphenoid sinus, and previous skull base surgery, there is a theoretical risk of epistaxis, structural injury, and CSF leakage that can be induced by poor swab technique [18]. HCWs unfamiliar with such variations as polyposis or deviated nasal septum may induce

* Corresponding author. 55 North Lake Avenue, Worcester, MA, 01655, United States.

E-mail addresses: mark.liu2@umassmed.edu (M. Liu), prithwijit.roychowdhury@umassmed.edu (P. Roychowdhury), Christopher.Ito@umassmemorial.org (C.J. Ito).

<https://doi.org/10.1016/j.xocr.2021.100316>

Received 4 April 2021; Accepted 11 May 2021

Available online 18 May 2021

2468-5488/© 2021 Elsevier Inc. This is an open access article under the CC BY-NC-ND license (<http://creativecommons.org/licenses/by-nc-nd/4.0/>).

mechanical trauma when attempting to forcibly insert the CDC-recommended length of the swab into patients' nasal cavities and encountering resistance [17]. Unfortunately, these possibilities have become reality in a few instances. A retrospective study performed at Treviso Hospital involving over 4000 patients found that one patient with a nasal septal deviation experienced uncontrollable bleeding after a swab, necessitating correction via surgical cauterization [19]. In another case report, a patient with a preexisting skull base defect developed a CSF leak following a routine swab that required surgical intervention [20].

Even in patients without these conditions, serious injuries resulting from nasopharyngeal swabs can occur. In the aforementioned Treviso Hospital study, there were 3 instances of epistaxis requiring nasal packing, 2 broken swabs that lodged into the nasal cavity, prompting intervention by otolaryngologists, and 1 case of a septal abscess following nasopharyngeal swabbing [19]. In a review of the literature regarding other major complications of nasopharyngeal swabs, there were at least 7 other instances in which the nasopharyngeal swab shaft broke within the nasal cavity of the patient, all of which required endoscopy for retrieval [21–25]. Three of these instances involved the shaft fragment inserting inferior to the inferior nasal turbinate, while two instances involved a fragment eventually being found in the gastric cavity [21–23,26]. In a study on 96 volunteers with both commercial swabs and 3D-printed swabs, the most common complications of commercial swab sampling included headache (5.2%), rhinorrhea (5.2%), and epistaxis (8.3%); however, one participant eventually had to be hospitalized for recurrent episodic bleeding after a commercial swab test [27].

Additionally, poor familiarity with the anatomy can preclude proper sampling and predispose to obtaining a false negative result for a patient infected with SARS-CoV-2. Studies documenting nasopharyngeal swabs' diagnostic values have found enormous variability in findings, even when performed on the same patients [2,3,8,28–30]. In Wyllie et al.'s study, when 9 asymptomatic HCWs tested positive for SARS-CoV-2 on salivary samples and had initial self-administered nasopharyngeal swabs as well, 7 of those initial nasopharyngeal swabs returned negative, a false negative rate of 77% [28]. Wyllie et al. also found higher variation in RNase P cycle threshold values in nasopharyngeal swabs compared to salivary samples matched to the same time points [28]. This suggests that the differences in viral load may be due to improper sampling rather than a reflection of the natural course of disease. Furthermore, past studies comparing nasopharyngeal washings and nasopharyngeal swabs for multiple respiratory viruses, including coronaviruses, respiratory syncytial virus, and influenza, showed greater sensitivities for nasopharyngeal washes, when compared to swabs [31–33]. As both methods sample the same anatomic region, the differences may be explained by a greater number of epithelial cells and virus particles obtained by the nasopharyngeal wash [33,34]. However, this may also reflect inadequate sampling technique of the nasopharyngeal swab as washings may circumvent anatomical variations that HCWs performing the swabs cannot. As Higgins et al. points out, if done incorrectly, the nasopharyngeal swab becomes effectively no more diagnostic than a simple nasal swab, despite its invasiveness and added risk to the sampled patient [17].

A lack of uniformity would almost certainly carry its own risks, including a high false negative rate and the risk of potential exposures to HCWs who would have otherwise taken the proper precautions when working with a COVID-19 positive patient. From an otolaryngological perspective, a probable explanation for many false negative tests is not that HCWs are inadequately trained but that there exists a high degree of variation in the normal anatomy of the nasal cavity and nasopharynx in the general population. For HCWs unfamiliar with such anatomic variations such as deviated nasal septum or nasal polyposis, the standard technique of nasopharyngeal swabs may not be adequate for proper sampling. In one case report, a patient with nasal polyposis had initially falsely tested negative with a nasopharyngeal swab but later re-tested

positive in the operating room during polyp resection as it was discovered that the polyps had largely precluded the nasopharynx from being physically accessed or sampled by the swabs [18].

We present a case of uncontrollable epistaxis as a complication of a nasopharyngeal swab in a patient. We also review various otolaryngological perspectives on improving the practice of performing nasopharyngeal swabs.

2. Case report

A 33-year-old male with a history of well-controlled hypertension presented to the emergency department with a 1-h history of uncontrolled epistaxis primarily from the right nostril. The bleeding had soaked through multiple towels despite pressure, and the patient experienced lightheadedness, tachycardia, and shortness of breath. He reported that he had experienced multiple episodes of epistaxis following a SARS-CoV-2 nasopharyngeal swab two weeks prior. Upon receiving the swab, the patient immediately experienced a significant bleed that he was initially able to control with direct pressure.

The patient was not on any anticoagulants. He had no history of tobacco smoke or recreational drug exposure, but he did endorse the use of vaping devices and alcohol.

On nasal endoscopy, the patient's right nasal cavity was found to have a lesion at the skull base covered by a blood clot with no signs of purulence, masses, or bleeding (Fig. 1). Upon closer inspection, the site was found to be on the septum at the level of the insertion of the middle turbinate (Fig. 2). As the site was unsuitable for cauterization, the patient elected for observation. Unfortunately, the patient had a recurrent severe nosebleed on the right side the following night that required packing with Surgicel applied directly to the site followed by placement of a Rhino Rocket nasal tampon.

The patient was discharged with instructions to follow up in 5 days for packing removal. He was evaluated 2 weeks after the packing removal and denied any episodes of epistaxis. He was lost to follow-up thereafter.

3. Discussion

Although rare, iatrogenic nasal cavity and nasopharyngeal injuries remain potential risks of nasopharyngeal swabs that HCWs and patients should be aware of. This case of major iatrogenic epistaxis in a patient with no prior significant surgical or medical history and no major anatomic variations in the nasal cavity reflects a rare but significant consequence of nasopharyngeal swabs. Due to the location, this lesion was unable to be cauterized in clinic and ultimately responded to repeat nasal packing.

As the nasopharyngeal swab remains a preferred testing method, it is crucial to ensure that the proper nasopharyngeal swabbing technique is

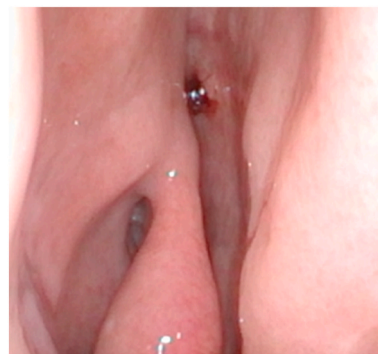


Fig. 1. Clot formation at site of injury just superior and posterior to the attachment of the middle turbinate on the right side of the nasal septum. The view pictured here is from the nasal vestibule.

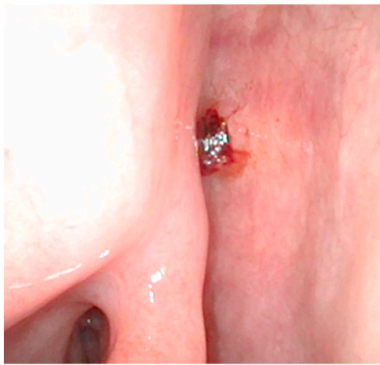


Fig. 2. Magnified view of clot formation from advanced position.

used by diversely trained HCWs asked to perform the swabs. There have been a number of instructional videos for this purpose [30,35–38]. Simulation programs involving nasopharyngeal swabs have reported a 45–51% increase in levels of self-perceived competence in ability to perform and a 77.5% correct first-attempt swab [13,15].

Although the simulation training exercises have been promising, it has been suggested for otolaryngologists to take on a more direct role in assisting with training other HCWs on nasopharyngeal swab techniques [11]. Kaufman et al. has even created an instructional video from an otolaryngological perspective [39]. With guidance from otolaryngologists, HCWs may better understand the complexity and variability of nasopharyngeal anatomy, which may not be as extensively covered by simulation training [40,41].

Programs that have encouraged collaboration between otolaryngologists and HCWs involved in sampling patients have reported higher comfort and compliance rates among patients and higher confidence levels in HCWs who performed the test [12]. The use of simulation training, along with assistance from otolaryngologists, appears a promising method to improve the technique and sensitivity of nasopharyngeal swabs throughout all of healthcare.

The widespread nature of nasopharyngeal swab training will not only assist with the current COVID-19 pandemic but also give a valuable boost to other areas of medicine that involve extensive use of nasopharyngeal swabs. Nasopharyngeal swabs remain a highly sensitive test for detecting Epstein-Barr virus DNA to screen for nasopharyngeal carcinoma [42]. Nasopharyngeal swabs can also be used to screen for the influenza virus and *Staphylococcus aureus* in the nares. Of note, prior to the COVID-19 pandemic, Warneke et al. had demonstrated that regimented training exercises had a significant improvement on participants' abilities to successfully harvest *Staphylococcus aureus* bacteria from nasal cavities [43]. Dhiman et al. demonstrated that proper education for patients in mid-turbinate nasal swabs for influenza could elevate patient self-test accuracies to those obtained by HCWs [44]. Therefore, evidence suggests that education in proper nasopharyngeal swab technique will be beneficial for training HCWs to screen for a variety of pathogens.

4. Conclusion

The nasopharyngeal swab, when done improperly, is not without the risk of major complications, including uncontrolled epistaxis or foreign body retention in the nasal cavity. The growing list of circulating instructional videos and manuals on how to perform nasopharyngeal swabs signifies an improved awareness of the impact that improper technique may have on obtaining valid test results and thus controlling the spread of COVID-19. Otolaryngologist involvement should be considered when educating other healthcare workers about the complexity and variability of nasopharyngeal anatomy in order to improve screening test sensitivity.

Financial disclosure

This research did not receive any specific grant from funding agencies in the public, commercial, or not-for-profit sectors.

Declaration of competing interest

The authors declare that they have no known competing financial interests or personal relationships that could have appeared to influence the work reported in this paper.

Acknowledgements

None.

References

- [1] World Health Organization. Diagnostic testing for SARS-CoV-2: interim guidance. 2020. Retrieved from, <https://apps.who.int/iris/handle/10665/334254>. [Accessed 20 February 2021].
- [2] Wang W, Xu Y, Gao R, Lu R, Han K, Wu G, et al. Detection of SARS-CoV-2 in different types of clinical specimens. *J Am Med Assoc* 2020;323(18):1843–4. <https://doi.org/10.1001/jama.2020.3786>.
- [3] Liu R, Han H, Liu F, Lv Z, Wu K, Liu Y, et al. Positive rate of RT-PCR detection of SARS-CoV-2 infection in 4880 cases from one hospital in Wuhan, China, from Jan to Feb 2020. *Clin Chim Acta* 2020;505:172–5. <https://doi.org/10.1016/j.cca.2020.03.009>.
- [4] Güçlü E, Koroglu M, Yürümez Y, Toptan H, Kose E, Güneysu F, et al. Comparison of saliva and oro-nasopharyngeal swab sample in the molecular diagnosis of COVID-19. *Rev Assoc Med Bras* 2020;66(8):1116–21. <https://doi.org/10.1590/1806-9282.66.8.1116>.
- [5] Patel R, Babady E, Theel ES, Storch GA, Pinsky BA, St George K, et al. Report from the American society for microbiology COVID-19 international summit, 23 March 2020: value of diagnostic testing for SARS-CoV-2/COVID-19. *mBio* 2020;11(2):e00722. <https://doi.org/10.1128/mBio.00722-20>.
- [6] Loeffelholz MJ, Tang YW. Laboratory diagnosis of emerging human coronavirus infections - the state of the art. *Emerg Microb Infect* 2020;9(1):747–56. <https://doi.org/10.1080/22221751.2020.1745095>.
- [7] Centers for Disease Control and Prevention. Interim guidelines for collecting, handling, and testing clinical specimens for COVID-19. 2020. <https://www.cdc.gov/coronavirus/2019-ncov/lab/guidelines-clinical-specimens.html>. [Accessed 3 September 2020].
- [8] Zou L, Ruan F, Huang M, Liang L, Huang H, Hong Z, et al. SARS-CoV-2 viral load in upper respiratory specimens of infected patients. *N Engl J Med* 2020;382(12):1177–9. <https://doi.org/10.1056/NEJMc2001737>.
- [9] Williams E, Bond K, Zhang B, Putland M, Williamson DA. Saliva as a noninvasive specimen for detection of SARS-CoV-2. *J Clin Microbiol* 2020;58(8):e00776. <https://doi.org/10.1128/JCM.00776-20>.
- [10] Iwasaki S, Fujisawa S, Nakakubo S, Kamada K, Yamashita Y, Fukumoto T, et al. Comparison of SARS-CoV-2 detection in nasopharyngeal swab and saliva. *J Infect* 2020;81(2):e145–7. <https://doi.org/10.1016/j.jinf.2020.05.071>.
- [11] De Virgilio A, Costantino A, Mercante G, Spriano G. How to increase the SARS-CoV-2 detection rate through the nasopharyngeal swab? *Oral Oncol* 2020;106:104802. <https://doi.org/10.1016/j.oraloncology.2020.104802>.
- [12] Tagliabue M, Pietrobbon G, Ugolini S, Chu F, Ansarin M. Nasopharyngeal swabs during SARS-CoV-2 pandemic: a role for the otolaryngologist. *Eur Arch Oto-Rhino-Laryngol* 2020;277(7):2155–7. <https://doi.org/10.1007/s00405-020-06027-2>.
- [13] Abud BT, Hajnas NM, Redleaf M, Kerolus JL, Lee V. Assessing the impact of a training initiative for nasopharyngeal and oropharyngeal swabbing for COVID-19 testing. *OTO Open* 2020;4(3):2473974X20953094. <https://doi.org/10.1177/2473974X20953094>.
- [14] De Virgilio A, Pellini R, Mercante G, Ferrelli F, Petrucci G, Spriano G. Who should perform the rhinopharyngeal swab in COVID-19 positive patients? *Head Neck* 2020;42(6):1250–1. <https://doi.org/10.1002/hed.26194>.
- [15] Mark ME, LoSavio P, Husain I, Papagiannopoulos P, Batra PS, Tajudeen BA. Effect of implementing simulation education on health care worker comfort with nasopharyngeal swabbing for COVID-19. *Otolaryngol Head Neck Surg* 2020;163(2):271–4. <https://doi.org/10.1177/0194599820933168>.
- [16] Mladina R, Cuić E, Subarić M, Vuković K. Nasal septal deformities in ear, nose, and throat patients: an international study. *Am J Otolaryngol* 2008;29(2):75–82. <https://doi.org/10.1016/j.amjoto.2007.02.002>.
- [17] Higgins TS, Wu AW, Ting JY. SARS-CoV-2 nasopharyngeal swab testing-false-negative results from a pervasive anatomical misconception. *JAMA Otolaryngol Head Neck Surg* 2020;146(11):993–4. <https://doi.org/10.1001/jamaoto.2020.2946>.
- [18] Bleier BS, Welch KC. Preprocedural COVID-19 screening: do rhinologic patients carry a unique risk burden for false-negative results? *Int Forum Allergy Rhinol* 2020;10(10):1186–8. <https://doi.org/10.1002/alr.22645>.
- [19] Fabbri C, Cestaro W, Menegaldo A, Spinato G, Frezza D, Vijendren A, et al. Is oro/nasopharyngeal swab for SARS-CoV-2 detection a safe procedure? Complications

- observed among a case series of 4876 consecutive swabs. *Am J Otolaryngol* 2021; 42(1):102758. <https://doi.org/10.1016/j.amjoto.2020.102758>.
- [20] Sullivan CB, Schwalje AT, Jensen M, Li L, Dlouhy BJ, Greenlee JD, et al. Cerebrospinal fluid leak after nasal swab testing for coronavirus disease 2019. *JAMA Otolaryngol Head Neck Surg* 2020;146(12):1179–81. <https://doi.org/10.1001/jamaoto.2020.3579>.
- [21] Medas R, Coelho R, Macedo G. An unusual collateral damage of COVID-19 pandemic. *Gastrointest Endosc* 2020;92(6):1261–2. <https://doi.org/10.1016/j.gie.2020.06.017>.
- [22] Mughal Z, Luff E, Okonkwo O, Hall CEJ. Test, test, test - a complication of testing for coronavirus disease 2019 with nasal swabs. *J Laryngol Otol* 2020;134(7): 646–9. <https://doi.org/10.1017/S0022215120001425>.
- [23] Azar A, Wessell DE, Janus JR, Simon LV. Fractured aluminum nasopharyngeal swab during drive-through testing for COVID-19: radiographic detection of a retained foreign body. *Skeletal Radiol* 2020;49:1873–7. <https://doi.org/10.1007/s00256-020-03582-x>.
- [24] Föh B, Borsche M, Balck A, Taube S, Rupp J, Klein C, et al. Complications of nasal and pharyngeal swabs - a relevant challenge of the COVID-19 pandemic? *Eur Respir J* 2020 Nov;2004004. <https://doi.org/10.1183/13993003.04004-2020>.
- [25] Suresh V. Anesthesia for extraction of a fractured COVID-19 nasopharyngeal swab. *Int J Pediatr Otorhinolaryngol*. Forthcoming 2021. <https://doi.org/10.1016/j.ijporl.2021.110611>. Available from.
- [26] De Luca L, Maltoni S. Is naso-pharyngeal swab always safe for SARS-CoV-2 testing? An unusual, accidental foreign body swallowing. *Clin J Gastroenterol* 2021;14(1): 44–7. <https://doi.org/10.1007/s12328-020-01236-y>.
- [27] Gupta K, Bellino PM, Charness ME. Adverse effects of nasopharyngeal swabs: three-dimensional printed versus commercial swabs. *Infect Control Hosp Epidemiol* 2020 Jun;1. <https://doi.org/10.1017/ice.2020.297>.
- [28] Wyllie AL, Fournier J, Casanovas-Massana A, Campbell M, Tokuyama M, Vijayakumar P, et al. Saliva or nasopharyngeal swab specimens for detection of SARS-CoV-2. *N Engl J Med* 2020;383:1283–6. <https://doi.org/10.1056/NEJMc2016359>.
- [29] Ai T, Yang Z, Hou H, Zhan C, Chen C, Lv W, et al. Correlation of chest CT and RT-PCR testing for coronavirus disease 2019 (COVID-19) in China: a report of 1014 cases. *Radiology* 2020;296(2):e32–40. <https://doi.org/10.1148/radiol.2020200642>.
- [30] Piras A, Rizzo D, Uzzau S, De Riu G, Rubino S, Bussu F. Inappropriate nasopharyngeal sampling for SARS-CoV-2 detection is a relevant cause of false-negative reports. *Otolaryngol Head Neck Surg* 2020;163(3):459–61. <https://doi.org/10.1177/019459820931793>.
- [31] Lieberman D, Lieberman D, Shimoni A, Keren-Naus A, Steinberg R, Shemer-Avni Y. Identification of respiratory viruses in adults: nasopharyngeal versus oropharyngeal sampling. *J Clin Microbiol* 2009;47(11):3439–43. <https://doi.org/10.1128/JCM.00886-09>.
- [32] Li L, Chen QY, Li YY, Wang YF, Yang ZF, Zhong NS. Comparison among nasopharyngeal swab, nasal wash, and oropharyngeal swab for respiratory virus detection in adults with acute pharyngitis. *BMC Infect Dis* 2013;13:281. <https://doi.org/10.1186/1471-2334-13-281>.
- [33] Masters HB, Weber KO, Groothuis JR, Wren CG, Lauer BA. Comparison of nasopharyngeal washings and swab specimens for diagnosis of respiratory syncytial virus by EIA, FAT, and cell culture. *Diagn Microbiol Infect Dis* 1987;8(2): 101–5. [https://doi.org/10.1016/0732-8893\(87\)90156-8](https://doi.org/10.1016/0732-8893(87)90156-8).
- [34] Hall CB, Douglas Jr RG. Clinically useful method for the isolation of respiratory syncytial virus. *J Infect Dis* 1975;131(1):1–5. <https://doi.org/10.1093/infdis/131.1.1>.
- [35] Piras A, Rizzo D, Longoni E, Turra N, Urru S, Saba PP, et al. Nasopharyngeal swab collection in the suspicion of COVID-19. *Am J Otolaryngol* 2020;41(5):102551. <https://doi.org/10.1016/j.amjoto.2020.102551>.
- [36] Petrucci G, De Virgilio A, Pichi B, Mazzola F, Zocchi J, Mercante G, et al. Covid-19: nasal and oropharyngeal swab. *Head Neck* 2020;42(6):1303–4. <https://doi.org/10.1002/hed.26212>.
- [37] Marty FM, Chen K, Verrill KA. How to obtain a nasopharyngeal swab specimen. *N Engl J Med* 2020;382(22):e76. <https://doi.org/10.1056/NEJMvcm2010260>.
- [38] Pondaven-Letourmy S, Alvin F, Boumghit Y, Simon F. How to perform a nasopharyngeal swab in adults and children in the covid-19 era. *Eur Ann Otorhinolaryngol Head Neck Dis* 2020;137(4):325–7. <https://doi.org/10.1016/j.anorl.2020.06.001>.
- [39] Kaufman AC, Brewster R, Rajasekaran K. How to perform a nasopharyngeal swab - an otolaryngology perspective. *Am J Med* 2020;133(11):1280–2. <https://doi.org/10.1016/j.amjmed.2020.05.004>.
- [40] Francesca BN, Barbara P, Emanuele F, Francesco SDC, Giovanni C, Fabio M, et al. Could a mannequin simplify rhinopharyngeal swab collection in COVID 19 patients? *Eur Arch Oto-Rhino-Laryngol* 2020;277:2947–8. <https://doi.org/10.1007/s00405-020-06113-5>.
- [41] Tagliabue M, Pietrobon G, Ugolini S, Chu F, Ansarin M. Reply to "could a mannequin simplify rhinopharyngeal swab collection in COVID 19 patients?". *Eur Arch Oto-Rhino-Laryngol* 2020;277:2949–50. <https://doi.org/10.1007/s00405-020-06186-2>.
- [42] Coghill AE, Wang CP, Verkuijlen S, Yu KJ, Hsu WL, Middeldorp JM, et al. Evaluation of nasal and nasopharyngeal swab collection for the detection of Epstein-Barr virus in nasopharyngeal carcinoma. *J Med Virol* 2018;90(1):191–5. <https://doi.org/10.1002/jmv.24918>.
- [43] Warnke P, Harnack T, Ottl P, Kundt G, Podbielski A. Nasal screening for *Staphylococcus Aureus*-daily routine with improvement potentials. *PLoS One* 2014; 9(2):e89667. <https://doi.org/10.1371/journal.pone.0089667>.
- [44] Dhiman N, Miller RM, Finley JL, Sztajnkrzyer MD, Nestler DM, Boggust AJ, et al. Effectiveness of patient-collected swabs for influenza testing. *Mayo Clin Proc* 2012; 87(6):548–54. <https://doi.org/10.1016/j.mayocp.2012.02.011>.