


The Efficacy of Intravenous Insulin Infusion in the Management of Hypertriglyceridemia-Induced Pancreatitis in a Rural Community Hospital

Journal of Investigative Medicine High Impact Case Reports
Volume 8: 1–4
© 2020 American Federation for Medical Research
DOI: 10.1177/2324709620940492
journals.sagepub.com/home/hic


Khalid Sawalha, MD¹, Anthony Kunnumpurath, MBBS¹, and Gilbert-Roy Kamoga, MD, FACP¹

Abstract

A 28-year-old female presented to the emergency room with epigastric pain, nausea, and vomiting; her lipase was elevated, and computed tomography of abdomen showed evidence of acute pancreatitis. Her past medical history was significant for poorly controlled insulin requiring type 2 diabetes mellitus and 2 previous admissions for hypertriglyceridemia-induced pancreatitis. Due to the severity of her pancreatitis presentation, she was admitted to the intensive care unit. She received aggressive intravenous fluid hydration and was started on an insulin drip. Apheresis was strongly considered given the degree of her hypertriglyceridemia (11 602 mg/dL), but there was no timely access to this treatment option. She, however, significantly improved with insulin therapy alone. Her triglyceride levels decreased rather quickly to 4783 mg/dL within 24 hours and by the fourth day of admission were comfortably <1000 mg/dL with insulin infusion along with clinical improvement. She was discharged on niacin and insulin therapy along with her home medications of statin and fenofibrate.

Keywords

hypertriglyceridemia, pancreatitis, insulin, cost-effective, rural community hospitals

Introduction

Hypertriglyceridemia-induced acute pancreatitis (HTG-AP) is a well-reported etiology of pancreatitis. 1% to 14% of pancreatitis are due to hypertriglyceridemia, with triglyceride levels usually >1000 mg/dL.¹ Current management of HTG-AP requires immediate supportive care and early detection of clinical deterioration that can be escalated appropriately to reduce development of organ failure and limit sequelae.² Our case is a young patient who developed acute pancreatitis secondary to very severe hypertriglyceridemia (>11 000 mg/dL) and was successfully treated with insulin therapy alone in a timely and effective manner similar to what would have been expected with therapeutic plasma exchange.

Case

A 28-year-old Caucasian female with a past medical history of poorly controlled insulin with type 2 diabetes mellitus, dyslipidemia, obesity, and recurrent pancreatitis presented with epigastric pain, nausea, and vomiting. She denied any

history of smoking, gallbladder stones, alcohol intake, or any new medication use. Family history was significant for her father having type 2 diabetes mellitus. Her home medications included atorvastatin calcium, *Bacillus coagulans*, calcium carbonate/simethicone, fenofibrate, insulin levemir 50 units qHs, insulin regular sliding scale, pancrelipase, lisinopril, omega-3 acid ethyl esters, omeprazole, and prenatal vitamins. On admission, vital signs were temperature of 98.1 °F, pulse rate of 105 beats/min, respiratory rate of 24 breaths/min, and a blood pressure of 142/95 mm Hg. Her laboratory findings revealed a white blood cell count = 12 200/μL with bandemia of 19%, hemoglobin A1c 10.7%, blood glucose level 331 mg/dL, triglyceride level 11 602 mg/dL (0–149 mg/dL), low-density lipoproteins level 254 mg/dL (0–99 mg/dL),

¹White River Health System, Batesville, AR, USA

Received April 25, 2020. Revised June 9, 2020. Accepted June 10, 2020.

Corresponding Author:

Khalid Sawalha, MD, Department of Internal Medicine, White River Health System, 1710 Harrison Street, Batesville, AR 72501, USA.
Email: Ksawalha@aol.com



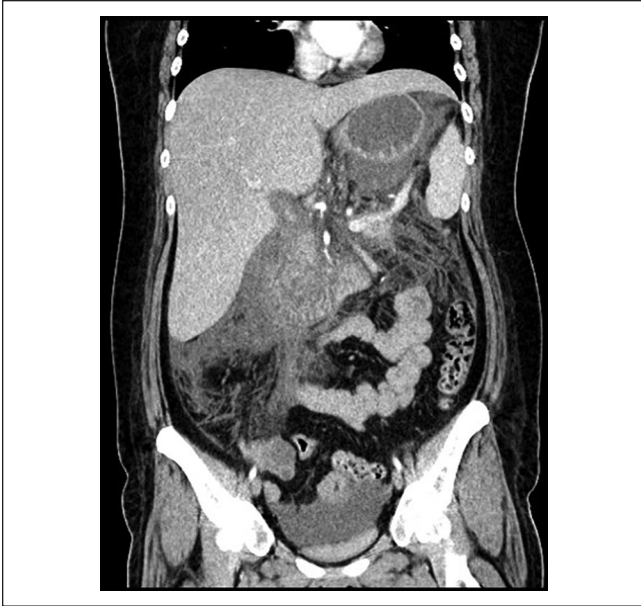

Figure 1. Computed tomography of the abdomen and pelvis coronal view showing extensive peripancreatic fluid collection.

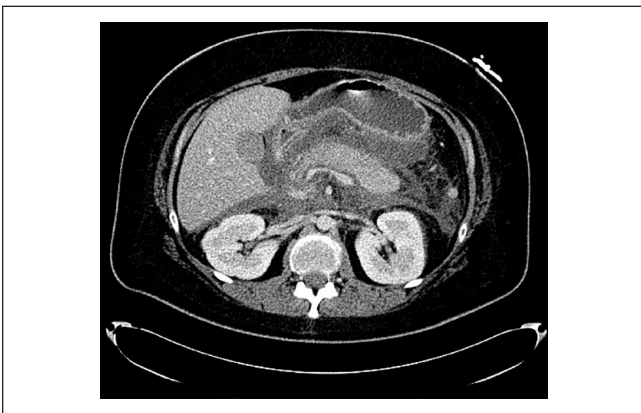

Figure 2. Computed tomography of the abdomen and pelvis axial view showing hypodense pancreas with peripancreatic fluid collection.

amylase 308 U/L (30-110 U/L), lipase 5517 U/L (23-300 U/L), calcium 6.1 mg/dL (8.4-10.2 mg/dL), lactate 3.0 mmol/L (0.7-2.0 mmol/L), bicarbonate 16 mmol/L (22-30 mmol/L), and anion gap 19 (10-14). A computed tomography of abdomen/pelvis showed findings consistent with pancreatitis with peripancreatic fluid but no evidence of pseudocysts or walled-off necrosis (Figures 1 and 2). Her clinical presentation was consistent with the diagnosis of severe HTG-AP.

She was started on an insulin drip at a rate of 0.1 U/kg/h. Within 24 hours, she had significant improvement, with triglyceride levels down to 4783 mg/dL with insulin therapy

alone. Her gallbladder ultrasound and HIDA scan were negative for stones or acute cholecystitis. The insulin drip was discontinued after 4 days when the triglyceride level was <1000 mg/dL. She was discharged on insulin and niacin along with her home medications statin, fenofibrate, and omega-3 acid ethyl esters after counseling about possible side effects. No genetic testing for hypertriglyceridemia was done while patient was admitted to the hospital. It was recommended at discharge for her to be initiated on an insulin pump not only for better glycemic control, but also for better triglyceride management.

Discussion

Hypertriglyceridemia is defined by a fasting serum triglyceride level of >150 mg/dL and is classified as very severe when the level is ≥ 2000 mg/dL. The risk of developing acute pancreatitis is approximately 10% to 20% with triglyceride levels >2000 mg/dL. The cause of lipotoxicity during acute pancreatitis is secondary to the breakdown of triglycerides into toxic free fatty acids by pancreatic lipases.¹ The severity of acute pancreatitis in patients with hypertriglyceridemia is dependent on both the inflammatory response caused by pancreatitis itself, and the injury caused by lipotoxicity from triglyceride hydrolysis.³

There are no current established guidelines for the treatment of very severe HTG-AP, although insulin, heparin, and plasmapheresis have all been used in the literature. Being in a rural hospital with no timely access to other treatment options, insulin drip was started as studies have showed, insulin is noninferior and as effective as plasmapheresis, which tends to be costly with limited access.⁴ Heparin is not used often due to the transient nature of the triglyceride levels, potential lipotoxicity from free fatty acids, and an increased risk of bleeding.¹ This leaves insulin infusions as a practical first line, easily accessible, and effective therapy especially in medically underserved or rural communities where access to therapeutic plasma exchange is remarkably limited.

Insulin is used usually to lower triglyceride levels, but the goal of insulin therapy in severe acute pancreatitis associated with severe hypertriglyceridemia is to reverse the stress-associated release of fatty acids from adipocytes, to promote intracellular triglyceride generation within adipocytes, and to promote fatty acid metabolism in insulin-sensitive cells, often in the setting of diabetes and peripheral insulin resistance.⁵ In our patient, this was achieved with initiation of insulin therapy in combination with a dextrose 5% infusion to avoid hypoglycemia. Insulin infusions are an affordable and clearly effective alternative to plasmapheresis in these cases.

The efficacy of therapeutic plasma exchange or apheresis in reducing the severity of HTG-AP or other endpoints like mortality has not been established. Although apheresis has shown to reduce triglyceride levels rapidly,⁶ apheresis has

not shown to ameliorate the overall mortality or morbidity of hyperlipidemic pancreatitis, as seen in retrospective case control studies.⁶ In a systematic review, definitive conclusions regarding the use of apheresis in HTG-AP could not be made.⁷ The American Society for Apheresis has identified apheresis use in hypertriglyceridemic pancreatitis as category 3, implying that the optimum role of apheresis therapy is not established and decision making on apheresis use should be individualized.² The American Society for Apheresis has given a grade 1c recommendation for apheresis use in HTG-AP, that is, it is a recommendation with low-quality or very-low-quality evidence.² Further randomized control studies would be needed to come to a definitive conclusion on the use of apheresis in HTG-AP.

Oral lipid lowering agents should be started when a patient is able to tolerate oral intake. As per Endocrine Society guidelines of 2012 on management of hypertriglyceridemia, fibrates should be strongly considered and often the first line for those with severe and very severe hypertriglyceridemia.⁴ Other oral agents that could be used for treatment of moderate-to-severe hypertriglyceridemia, in combination with fibrates are niacin, N-3 fatty acids, and statins; taking into account need for counseling about possible side effects.⁴ Aggressive lifestyle modifications along with regular triglyceride level monitoring should be done to prevent further episodes of acute pancreatitis.⁸ There are no current guidelines for the use of insulin pump infusion for diabetes mellitus type 2 in those with marked hypertriglyceridemia. The Endocrine Society guidelines 2012 on management of hypertriglyceridemia has identified poorly controlled blood sugars as one of the causes of secondary hypertriglyceridemia.⁴ This patient had poor glycemic control with a hemoglobin A1c of 10.7% with her current insulin regimen. Insulin pump therapy was therefore recommended on discharge for tighter control of blood sugars, thus treating the profound secondary hypertriglyceridemia and preventing future relapse of HTG-AP.

Conclusion

This case illustrates that intravenous insulin infusions are an excellent option in the management of severe HTG-AP. Our case highlighted the quick and effective response to insulin therapy despite a very severely elevated triglyceride level of 11 602 mg/dL on presentation with evidence of severe illness from the pancreatitis. There are recommendations regarding the management of hypertriglyceridemia by the Endocrine Society in 2012. For management of HTG-AP, there are numerous therapeutic options, but no clear guidelines so far.⁷ This case demonstrates, especially in a rural setting, that the use of intravenous insulin therapy is an effective, affordable, and accessible alternative to plasmapheresis. There have been cases of successful management of HTG-AP reported

even in those who are nondiabetic and do not have elevated blood glucose.^{9,10}

Intravenous insulin therapy is an effective, affordable, and accessible alternative to plasmapheresis in medically underserved or rural communities as clearly demonstrated in this case. Review of such cases may sway experts' in recommending insulin infusion therapy as first line for this HTG-AP, even with evidence of severe illness.

Acknowledgments

Charles McClain, MD, Radiology, White River Health Systems, Batesville, AR.

Declaration of Conflicting Interests

The author(s) declared no potential conflicts of interest with respect to the research, authorship, and/or publication of this article.

Funding

The author(s) received no financial support for the research, authorship, and/or publication of this article.

Ethics Approval

Our institution does not require ethical approval for reporting individual cases or case series.

Informed Consent

Verbal informed consent was obtained from the patient(s) for their anonymized information to be published in this article.

References

1. Navina S, Acharya C, DeLany JP, et al. Lipotoxicity causes multisystem organ failure and exacerbates acute pancreatitis in obesity. *Sci Transl Med*. 2011;3:107ra110.
2. Padmanabhan A, Connelly-Smith L, Aqui N, et al. Guidelines on the use of therapeutic apheresis in clinical practice—evidence-based approach from the Writing Committee of the American Society for Apheresis: the Eighth Special Issue. *J Clin Apher*. 2019;34.3:171-354.
3. Gayam V, Mandal AK, Gill A, et al. A rare case of acute pancreatitis due to very severe hypertriglyceridemia (>10 000 mg/dL) successfully resolved with insulin therapy alone: a case report and literature review. *J Investig Med High Impact Case Rep*. 2018;6:2324709618798399.
4. Berglund L, Brunzell JD, Goldberg AC, et al. Evaluation and treatment of hypertriglyceridemia: an Endocrine Society Clinical Practice Guideline. *J Clin Endocrinol Metab*. 2012;97:2969-2989.
5. Kitabchi AE, Umpierrez GE, Miles JM, Fisher JN. Hyperglycemic crises in adult patients with diabetes. *Diabetes Care*. 2009;32:1335-1343.
6. Chen JH, Yeh JH, Lai HW, Liao CS. Therapeutic plasma exchange in patients with hyperlipidemic pancreatitis. *World J Gastroenterol*. 2004;10:2272-2274. doi:10.3748/wjg.v10.i15.2272

7. Click B, Ketchum AM, Turner R, Whitcomb DC, Papachristou GI, Yadav D. The role of apheresis in hypertriglyceridemia-induced acute pancreatitis: a systematic review. *Pancreatology*. 2015;15:313-320.
8. Garg R, Rustagi T. Management of hypertriglyceridemia induced acute pancreatitis. *Biomed Res Int*. 2018;2018:4721357.
9. Mikhail N, Trivedi K, Page C, Wali S, Cope D. Treatment of severe hypertriglyceridemia in nondiabetic patients with insulin. *Am J Emerg Med*. 2005;23:415-417.
10. Jabbar MA, Zuhri-Yafi MI, Larrea J. Insulin therapy for a non-diabetic patient with severe hypertriglyceridemia. *J Am Coll Nutr*. 1998;17:458-461.