

Case report

Case report of Wolfe grafting for the management of bilateral cicatricial eyelid ectropion following severe burn injuries

Nina Jovanovic^{a,*}, Admir Dizdarevic^a, Nedžad Dizdarevic^b, Amir Haracic^b, Lamija Gafurovic^b^a Ophthalmology Department, Canton Hospital Zenica, 72000 Zenica, Bosnia and Herzegovina^b Department for Plastic and Reconstructive Surgery, Canton Hospital Zenica, 72000 Zenica, Bosnia and Herzegovina

ARTICLE INFO

Keywords:

Burn
Cicatricial ectropion
Full-thickness skin graft
Wolfe technique
Inguinal region

ABSTRACT

Introduction: Eye lid reconstruction followed by severe, extensive body and facial burns represents a surgical challenge due to difficulties to obtain proper, healthy skin graft, tissue ischemia and necrosis.

Presentation of case: We present a reconstructive lid surgery of cicatricial bilateral lower eyelid ectropion in a case of 31-year-old man who sustained thermal injuries, affecting more than 60% of total body surface area, causing severe, deep dermal burns. Reconstruction was made using the technique of skin cantus-to-cantus incision, contracture release, orbicularis liberation and lid elevation; and oversizing free full-thickness skin graft (FTSG) (Wolfe technique) from the left inguinal region, as the only healthy skin on the entire body surface. Residual lower left lid laxity was addressed by pentagonal wedge resection, not interrupting marginal arcade vessels, thus minimizing ischemia.

Discussion: Method of choice of the graft type has been much debated question; however, significantly less reoccurrence rate of ectropion was observed using FTSG. Time of grafting should be balanced to avoid excess granulation and, thus scarring caused by delayed grafting time, or poor graft adherence caused by premature grafting. An interruption of the marginal arcade vessels should not be performed due to already severe ischemic process and increased risk for lid necrosis.

Conclusion: Major issues when addressing cicatricial ectropion followed by severe burns are: right donor site selection, appropriate graft thickness with the least possible disturbance of the affected place vascularisation, followed by immediate grafting after debridement of scarring and unhealthy tissue, with generous preservation of the orbicularis muscle.

1. Introduction

Severe burns affect nearly every organ system, causing significant morbidity and are lethal if not treated properly. These patients are at the most risk and they require special consideration when treated [1]. Periocular area and lids are frequently affected with facial burns, ranging from 7.5 to 20% of all burn cases [2]. The affected skin area usually does not permit large skin grafting and is prone to necrosis and short graft survival. This makes cicatricial ectropion surgery following burn injuries difficult and sometimes unsuccessful. Proper timing for lid reconstruction and choice between split (STSG) and full-thickness skin grafting (FTSG) is debatable [3]. For example, a case report of the skin reconstruction following burns reports optimal waiting time of 5 days for graft placement following debridement allowing healthy granulation and bleeding observation [4]. Most severe burns affecting eyelids

are either full-thickness or deep. The former and latter ask for an early excision of damaged tissue and skin grafts, together with extensive wound treatment and contracture management which improves the outcomes of injured patients [1,5]. However, in some case early treatment is not possible due to patient late presentation, the need for other urgent, vital surgeries and treatment, or lack of healthy, proper skin for periocular area grafting. We present a case of bilateral cicatricial eyelid ectropion management following severe burn injuries in a patient who previously sustained severe, deep dermal thermal injuries, affecting more than 60% of Total Body Surface Area (TBSA). The work in this article has been reported in line with SCARE criteria [6].

2. Presentation of case

31-year-old Caucasian man was referred for treatment at our

* Corresponding author: Ophthalmology Department, Canton Hospital Zenica, Str. Crkvice 67, 72000 Zenica, Bosnia and Herzegovina.

E-mail addresses: nina-jovanovic@uiowa.edu (N. Jovanovic), ad25801@yahoo.com (A. Dizdarevic), drnedžad@yahoo.com (N. Dizdarevic), amir.haracic@yahoo.com (A. Haracic), lamija.gafurovic@gmail.com (L. Gafurovic).

<https://doi.org/10.1016/j.amsu.2018.07.013>

Received 16 March 2018; Received in revised form 13 May 2018; Accepted 14 July 2018

2049-0801/ © 2018 The Author(s). Published by Elsevier Ltd on behalf of IJS Publishing Group Ltd. This is an open access article under the CC BY-NC-ND license (<http://creativecommons.org/licenses/by-nc-nd/4.0/>).

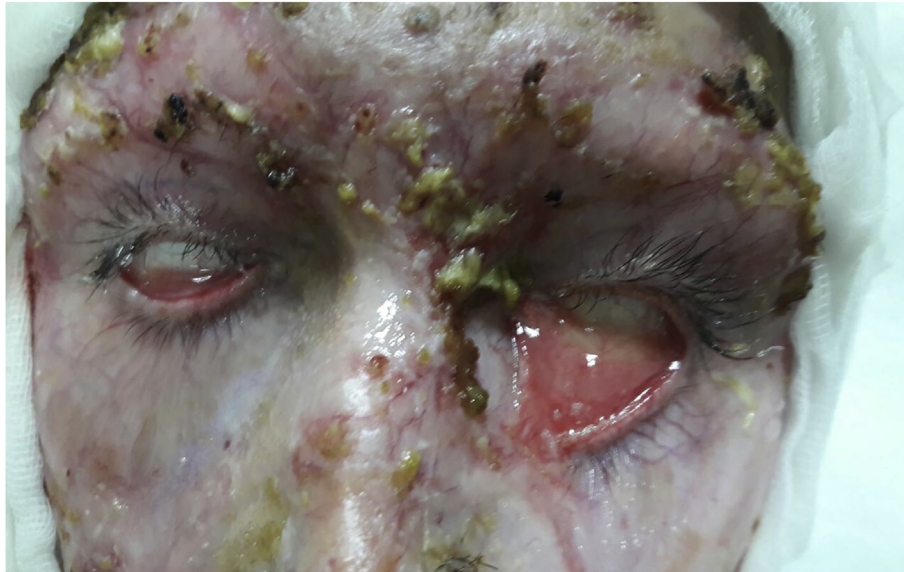

Fig. 1. Cicatricial ectropion in both lower eyelids, left eye more affected, before the surgery.

institution for surgical treatment of the cicatricial ectropion of both lower eyelids and exposure keratopathy due to severe deep dermal burns that affected minimally 60% of the TBSA (Fig. 1).

Eight months prior to this presentation, patient sustained thermal burn injuries. Mechanism of the injury was explained by patient as being doused with large amount of gasoline and set ablaze in closed space. Initial diagnosis stated that head, face, neck, breast, lower and upper bilateral extremities were affected with deep dermal and third-degree burns; urinary fistula; sepsis; paresis of the peronei nerve on the right side; both lids contractures; contractures and deformities of the both hands fingers. Primary treatment was obtained at the largest hospital in the country due the need for mechanic ventilation and intensive reanimation therapy. All burns were covered with bandages. Patient received decompressive fasciotomy and was transferred to subspecialized university clinic in other country (out-country treatment) for prolonged medical treatment that lasted seven months. There, he received 13 surgeries: several necrotomies and the Meek Micrografting technique procedures with two repeated keratinocytes cultures harvesting in their tissue bank. Due to prolonged respiratory treatment, a tracheostomy was performed. Patient had multiple times sepsis and bacterial cultures showed mixed gram positive and negative resistant organisms; therefore, often change of antibiotics' regime was applied. After multiple surgical treatments, lids, earlobe and fingers were still left with deformities. The patient was released from aforementioned institution in good general condition and recommendation for in-home-country surgical treatment of the lids.

Patient was referred to our hospital for the continuation of conservative treatment and lid surgeries. Here, we isolated following microbes during bacterial cultivations: *Coagulase negative staphylococcus*, *Proteus Mirabilis*, *Staphylococcus aureus*, *Pseudomonas Aeruginosa* and *Species*, and appropriate antibiotic treatment was given. Our examination found: multiple non-epithelized body areas (1–3 cm surface on average), damaged periocular and lid skin with scarring, cicatricial ectropion of both lower eyelids, complete loss of eye brown, upper lids with decreased motility, eyelashes somewhat preserved, eye ball fine, conjunctival hyperemia, right cornea with macula in the optic zone, left cornea with superficial 6 o'clock erosion. Best corrected visual acuity on the right eye was 7/200 and on the left eye 20/20, examined using standard Snellen eye chard from the distant of 6 m, with normal eye pressure. Plastic surgeons and ophthalmologists performed bilateral lower eyelids reconstructive surgery at the department of plastic and reconstructive surgery in the general endotracheal anesthesia. Surgical

protocol was as follows: patient's surgical site antiseptic skin preparation with aqueous iodine (10%), followed by right and subsequently left lower eyelid skin incision and excision of cicatricial tissue 5 mm below the cilia from canthus-to-canthus with orbicularis presentation. Scaring tissue was excised, and tissue above orbicularis was bluntly dissected, aiming to release contracture and elevate the lid. This produced left lower eyelid with excess tissue including both lamellas, accompanied with severe posterior lamella medially located focal damage; therefore, we made full thickness pentagonal wedge excision on the left lower eyelid of approximately 20% of the total lid surface. The defect was sutured using mattress suture technique. A wound bed in a size of 20 × 15mm right, and 25 × 20 mm on the left side remained in lower eyelids. Due to extensive skin damage and scaring tissue after auto-transplantation along the entire body surface, we used only available and suitable healthy skin for grafting method from the left inner upper thigh (inguinal region). The left inguinal surgical site region was pre-operatively prepared and cleaned with aqueous iodine (10%), and the full-thickness skin graft was taken (Wolfe technique), to replace the skin defect on the both lower eyelids. Graft was sutured using the 6.0 non-absorbable nylon suture and secured with tie-over tamponade on the both sides (Fig. 2). First inspection was made 72 hours after; tamponade was released, and the wound treated. Graft was 100% viable and of appropriate colour. Two days after, all dressing was taken off, graft exposed, and no additional dressing was applied on the both sides. On the third postoperative day, lid positions were satisfying, no corneal exposure was marked, good lid motility was obtained and preserved on the both sides, 6 months follow up grafts had good colour with no signs of necrosis, or discoloration, only showing mild medial ectropion on the left lower lid, but with no extensive corneal exposure (Fig. 3).

3. Discussion

Reconstruction of the cicatricial ectropion following face burns should have priority in planning and management of further treatment, although usually that is hard to obtain in case of large affected skin areas [7]. Incision and skin release without eschar excision is recommended by some authors [3], while others suggest that escharotomy is necessary for successful skin grafting and prevention of contracture [7,8]. If the orbicularis oculi been viable, it should be freed completely to avoid subsequent ectropion and scarring [4]. Same authors advise for Frost suture placement to allow for skin stretching and prevention of scarring. For lower eyelid management, a subciliary

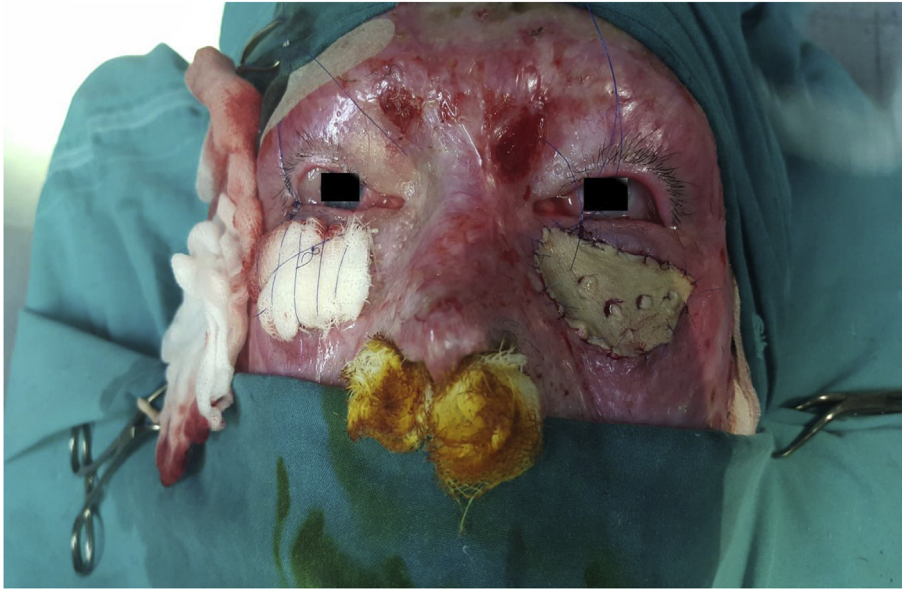


Fig. 2. Wolfe full-thickness skin graft on both eyelids during the surgery. Graft was sutured using the 6.0 non-absorbable nylon suture (left eye), and secured with tie-over tamponade (right eye).

incision from cantus to cantus, or extending, is preferable, followed by anterior lamella dissection, contracture release and scarring tissue excision. After affected tissue debridement, time of grafting reconstruction should be balanced to avoid excess granulation and, thus scarring caused by delayed grafting time, or poor graft adherence caused by premature grafting [4]. Defect can be reconstructed with full or split-thickness skin graft. Method of choice of the graft type has been much debated question; however, sufficient number of studies reported good results and significantly less reoccurrence rate of cicatricial ectropion with FTSG due to its presence of more dermis and subsequent less contraction. In case of incapability of obtaining FTSG [9], a STSG can be used [10]. Special care should be placed on the graft oversizing the defect, due to fact that FTSG contracts for at least a third [3]. These grafts are often used with satisfactory aesthetic results for the face surgery. Although, horizontal eyelid laxity may be seen in these patients, if not necessary, an interruption of the marginal arcade vessels should not be performed due to already severe ischemic process and increased risk for lid necrosis [3]. In the presented case, ipsilateral and contralateral upper skin was affected with burns and contractures; therefore, only distant, free FTSG (Wolfe technique) including epidermis and full layer of dermis was an option for the reconstruction.

Even though much advocated donor skin sites are from retro-auricular, supraclavicular, inner brachial area, and upper eyelid [10,11]; in our case only unaffected, healthy skin could have been harvested from the inguinal region.

4. Conclusion

An early treatment could not be obtained in our institution due to patient late presentation. However, with proper choice of surgical technique and the skin graft, the resulting outcome was satisfactory. Therefore, we conclude that major issues when addressing cicatricial ectropion followed by severe burns are: the right donor site selection, appropriate graft thickness with the least possible disturbance of the affected place vascularisation, followed by immediate grafting after debridement of scarring and unhealthy tissue, with generous preservation of the orbicularis muscle.

IRB approval

IRB approval was obtained from the institutional IRB and given the number 20/1-2-919-10 on 29.01.2018.

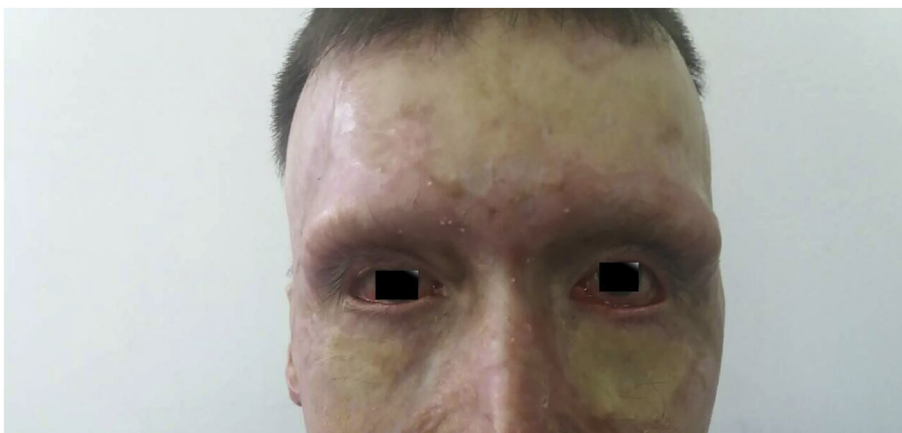


Fig. 3. Patient 6 months after the surgery; grafts had good colour with no signs of necrosis, or discoloration, only showing mild medial ectropion on the left lower lid, but with no extensive corneal exposure. (For interpretation of the references to colour in this figure legend, the reader is referred to the Web version of this article.)

Consent

Written informed consent was obtained from the patient for publication of this case report and accompanying images. A copy of the written consent is available for review by the Editor-in-Chief of this journal on request.

Conflicts of interest

The authors declare no conflict of interests.

Competing interests statement

The authors have no competing interests.

Appendix A. Supplementary data

Supplementary data to this article can be found online at <https://doi.org/10.1016/j.amsu.2018.07.013>.

References

- [1] Y. Wang, J. Beekman, J. Hew, S. Jackson, A.C. Issler-Fisher, R. Parungao, S.S. Lajevardi, Z. Li, P.K.M. Maitz, Burn injury: challenges and advances in burn wound healing, infection, pain and scarring, *Adv. Drug Deliv. Rev.* 123 (2018) 2–17 <https://doi.org/10.1016/j.addr.2017.09.018>.
- [2] L.P.M. Vana, C. Isaac, N. Alonso, Treatment of extrinsic ectropion on burned face with facial suspension technique, *Burns* 40 (8) (2014) 1713–1719 <https://doi.org/10.1016/j.burns.2014.02.016>.
- [3] R. Malhotra, I. Sheikh, B. Dheansa, The management of eyelid burns, *Surv. Ophthalmol.* 54 (3) (2009) 356–371 <https://doi.org/10.1016/j.survophthal.2009.02.009>.
- [4] J. Joethy, B.K. Tan, A multi-staged approach to the reconstruction of a burnt Asian face, *Indian J. Plast. Surg.* 44 (1) (2011) 142–146.
- [5] Kamolz LP. Burns, Learning from the past in order to be fit for the future, *Crit. Care* 14 (2010) 106 <https://doi.org/10.1186/cc8192>.
- [6] R.A. Agha, A.J. Fowler, A. Saeta, I. Barai, S. Rajmohan, D.P. Orgill, The SCARE Statement: consensus- based surgical case report guidelines, *Int. J. Surg.* 34 (2016) 180–186.
- [7] S. Sujata, K. Kanchana, Management of ocular and periocular burns, *Indian J. Burns* 22 (1) (2014) 22, <https://doi.org/10.4103/0971-653X.146997>.
- [8] H. Rode, R. Martinez, D. Potgieter, S. Adams, A.D. Rogers, Experience and outcomes of micrografting for major paediatric burns, *Burns* 43 (5) (2017) 1103–1110 <https://doi.org/10.1016/j.burns.2017.02.008>.
- [9] H. Liu, K. Wang, Q. Wang, S. Sun, Y. Ji, A modified surgical technique in the management of eyelid burns: a case series, *J. Med. Case Rep.* 5 (2011), <https://doi.org/10.1186/1752-1947-5-373> 373–373.
- [10] D.S. Rathore, S.S. Chickadasarahilli, S.R. Crossman, S.P. Mehta, S.H. Ahluwalia, Full thickness skin grafts in periocular reconstructions: long-term outcomes, *Ophthalmic Plast. Reconstr. Surg.* 30 (6) (2014) 517–520, <https://doi.org/10.1097/IOP.0000000000000237>.
- [11] J.C. Choi, K.A. Bauza, K.M. Yoon, K.R. Sobel, K.S. Freitag, Full-thickness skin graft as an independent or adjunctive technique for repair of cicatricial lower eyelid ectropion secondary to actinic skin changes, *Ophthalmic Plast. Reconstr. Surg.* 31 (6) (2015) 474–477, <https://doi.org/10.1097/IOP.0000000000000524>.