

## Oesophageal duplication cyst mimicking hydatid cyst in endemic areas

Melih Akin, Basak Erginel, Abdullah Yildiz, Cetin Ali Karadag, Nihat Sever, Ali Ihsan Dokucu

Department of Paediatric Surgery, Sisli Etfal Education and Research Hospital, Istanbul, Turkey

Kardiochirurgia i Torakochirurgia Polska 2015; 12 (3): 272-274



### Abstract

The cystic appearance of both oesophageal duplications and pulmonary hydatid cysts can cause a misdiagnosis very easily due to rarity of cystic oesophageal duplications beside the higher incidence of hydatid cyst, especially in endemic areas. Here we report a 7-year-old girl with an oesophageal duplication cyst on the left side misdiagnosed as a hydatid cyst. The aim of the study is to report rare oesophageal duplications in the differential diagnosis of intrathoracic cysts.

**Key words:** oesophageal duplication, hydatid cyst.

### Introduction

Duplications of the alimentary tract are well-known but rare congenital malformations that can occur anywhere in the gastrointestinal (GI) tract from the tongue to the anus [1]. While midgut duplications are the most common, foregut duplications such as oesophagus, stomach, and parts 1 and 2 of the duodenum account for approximately one-third of cases. The estimated incidence of oesophageal duplications is 1 in 8200. They are most commonly seen either in the thorax or abdomen or in both as congenital thoracoabdominal duplications. Cystic oesophageal duplication (CED), the most common presentation, is often found in the lower third part (60-95%) and on the right side [2, 3].

Hydatid cyst (HC) is still an important health problem throughout the world, particularly in Latin America, Africa, and Mediterranean areas. Turkey, located in the Mediterranean area, shares this problem, with an estimated incidence of 20/100 000. Haematogenous and lymphatic spread of the disease can involve unusual sites in the body. Most commonly reported effected organ is liver, but in children the lungs are the second most frequent site of involvement [4, 5].

In both CED and HC, the presentation depends on the site and the size of the cyst. Hydatid cysts presenting in the lungs are usually found incidentally. Hydatid cysts are far more common than other cystic intrathoracic lesions,

### Streszczenie

Torbielowaty wygląd zarówno zdwojeń przełyku, jak i bąblowcowych torbieli płucnych może łatwo prowadzić do błędnej diagnozy wynikającej z rzadkości zdwojeń przełyku i częstszego występowania torbieli bąblowca, szczególnie w rejonach endemicznych. W pracy przedstawiono przypadek 7-letniej dziewczynki z lewostronną torbielą zdwojenia przełyku błędnie zdiagnozowaną jako torbiel bąblowcowa. Celem doniesienia jest przedstawienie rzadkiego zdwojenia przełyku w rozpoznananiu różnicowym torbieli śródpiersia.

**Słowa kluczowe:** zdwojenie przełyku, torbiel bąblowca.

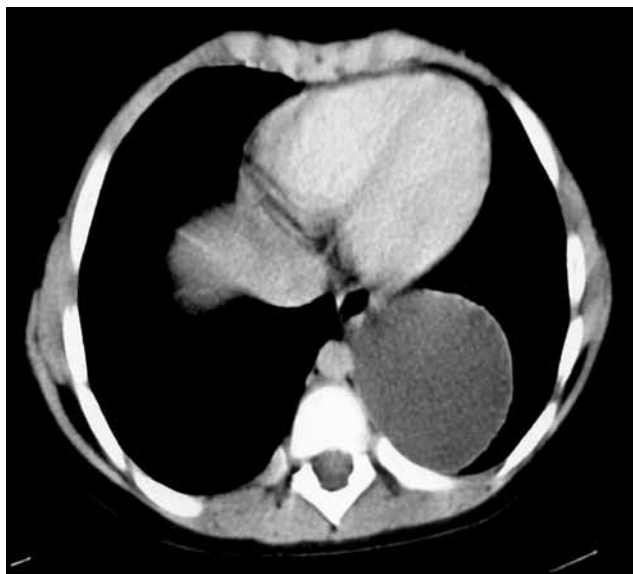
especially in endemic areas, so it is a challenge to differentiate CED from HC in these countries [6].

Here, we present a 7-year-old girl with intrathoracic cystic mass lesion, who had been treated for hydatid cyst for 9 months, but who turned out to have oesophageal cystic duplication.

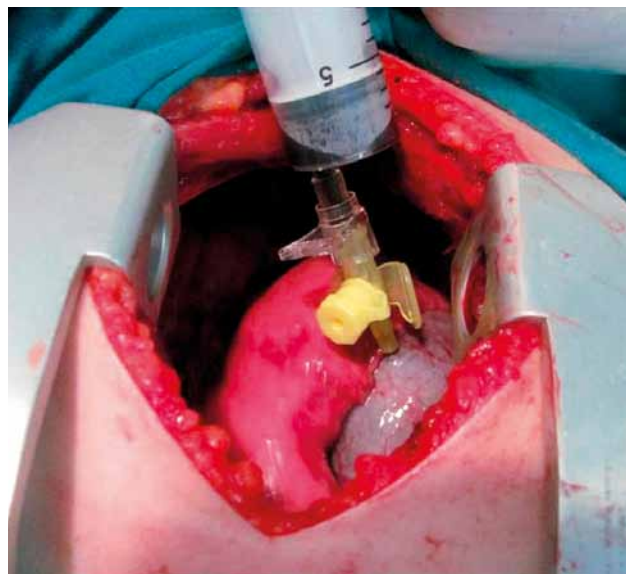
### Case report

A 7-year-old girl was referred to our clinic with coincidentally established cystic intrathoracic lesion during the investigation of aetiology of anaemia. The child was first admitted with loss of vision in another hospital ten months previously. The patient's complaints had been attributed to pseudotumour cerebri due to severe iron deficiency anaemia (haemoglobin: 3 g/dl). Chest radiography and computed tomography (CT) images resulted in a diagnosis of cystic intrathoracic lesion (Fig. 1). Indirect haemagglutination (IHA) test was negative. The cystic mass was accepted as a type 1 hydatid cyst according to World Health Organization (WHO) classification [6]. Albendazole treatment was started. After 9 months of medication, no regression was detected in CT images, so the patient was referred to our department. An indirect haemagglutination test result was again negative. During surgery, after left thoracotomy incision, a semi-mobile cystic lesion, which was almost seven centimetres in diameter, with smooth contour, was found

**Address for correspondence:** Basak Erginel, MD, Sisli Etfal Education and Research Hospital, Department of Paediatric Surgery, Adres Yildirim Oguz Goker Cad. 5. Gazeteciler Sitesi, C-1, no: 36, Akatlar-Beşiktaş, 34000 Istanbul, Turkey, phone: +90-532-6464787, e-mail: basakerginel@hotmail.com



**Fig. 1.** Computed tomography image of the cystic intrathoracic lesion



**Fig. 2.** Cystic lesion with brownish fluid in the cyst

above the diaphragm, below the lung, outside the pleura (Fig. 2). The entire fluid in the cyst was aspirated; it was brown and bloody (Fig. 2). The diagnosis of cystic oesophageal duplication was considered, and so an attachment point was searched for. It was below the hiatus, on the lower third left side of the oesophagus, and it also was excised completely through the hiatus. Neuronal attachment was not present. We ended the operation after insertion of a chest tube. Pathologic analysis of the specimen showed oesophageal mucosa with an underlying proper smooth muscle layer. Intraoperative diagnosis of cystic oesophageal duplication was supported with microscopic evaluation of the specimen.

## Discussion

Compressible organs facilitate the growth of the cyst, and this has been proposed as a reason for the apparent prevalence of lung involvement in children. Diagnosis is often incidental and can be made with serological tests and imaging [5, 7]. Laboratory investigations include the Casoni and Weinberg skin tests, indirect haemagglutination test, ELISA, and the presence of eosinophilia, but can be falsely negative because children may have a poor serological response to EG. Indirect haemagglutination test was negative but seronegativity does not exclude the diagnosis. Indirect haemagglutination has rather good sensitivity (60-100%) but poor specificity. False-positive reactions are related to the antigenic commonality among cestodes and conversely seronegativity cannot exclude hydatidosis. False-negative results are observed when cysts are calcified, even if fertile [4, 8]. In our patient IHA levels were negative twice.

Due to the relatively non-specific clinical signs, diagnosis can only be made confidently using appropriate imaging. Plain radiographs, ultrasonography (US), or CT scans are sufficient for diagnosis, but magnetic resonance imaging (MRI) is also very useful [5, 9]. Ultrasonography detects cystic

membranes, septa, and hydatid sand. Computed tomography demonstrates cyst wall calcification, infection, peritoneal seeding, bone involvement fluid density of intact cysts, and the characteristic internal structure of both uncomplicated and ruptured cysts [5, 9]. It is also able to demonstrate cysts not identified with plain radiographs [10].

The conventional treatment of hydatid cysts in all organs is surgical. In children, small hydatid cysts of the lungs respond favourably to medical treatment with oral administration of certain antihelminthic drugs such as albendazole in certain selected patients. The response to therapy differs according to age, cyst size, cyst structure (presence of daughter cysts inside the mother cysts and thickness of the pericystic capsule allowing penetration of the drugs), and localization of the cyst. In children, small cysts with thin pericystic capsule localised in the brain and lungs respond favourably [6, 11].

Oesophageal duplication is a rare entity. There are cystic or tubular types; the cystic form is more common. Respiratory symptoms are seen predominantly in cases before two years of age [2]. In our patient, who has vision loss, the asymptomatic duplication cyst was found incidentally. The lesion occupied the left hemithorax although the most common localisation reported in the literature is the lower and right oesophagus. Ninety percent of cases have not any relationship with neuronal elements. The presentation depends on the site and the size of the malformations, varying from dysphagia and respiratory distress to a lump and perforation or bleeding into the intestine, but cysts are mostly diagnosed incidentally. If a cystic mass is suspected in the chest, the best technique for evaluation is CT. A barium swallow study may be helpful to detect the relationship with the oesophagus. Magnetic resonance imaging can be used to detail the intimate nature of the cyst with the spinal canal. Low-level hydatid cysts can mimic oesophageal duplication cysts. Duplications should have all three typical

signs: first of all, they should be attached to at least one point of the alimentary tract; second and third are that they should have a well-developed smooth muscle coat, and the epithelial lining of duplication should represent some portions of alimentary tract, respectively [2, 10, 12].

In summary, the cystic appearance of both can cause a misdiagnosis very easily due to the rarity of cystic oesophageal duplications as well as the higher incidence of hydatid cyst, especially in endemic areas.

### Disclosure

Authors report no conflict of interest.

### References

1. Sharma KK, Ranka P, Meratiya S. Isolated cervical esophageal duplication: a rarity. *J Pediatr Surg* 2005; 40: 591-592.
2. Estefan Ventura D, Reibschheid S, Colleoni R, Schettini ST. Surgical images: soft tissue. Tubular duplication of the esophagus. *Can J Surg* 2008; 51: 205-206.
3. Snyder CL, Bickler SW, Gittes GK, Ramachandran V, Ashcraft KW. Esophageal duplication cyst with esophageal web and tracheoesophageal fistula. *J Pediatr Surg* 1996; 31: 968-969.
4. Biava MF, Dao A, Fortier B. Laboratory diagnosis of cystic hydatid disease. *World J Surg* 2001; 25: 10-14.
5. Andronikou S, Welman CJ, Kader E. Classic and unusual appearances of hydatid disease in children. *Pediatr Radiol* 2002; 32: 817-828.
6. Oral A, Yigiter M, Yildiz A, Yalcin O, Dikmen T, Eren S, Kantarci M, Salman AB. Diagnosis and management of hydatid liver disease in children: a report of 156 patients with hydatid disease. *J Pediatr Surg* 2012; 47: 528-534.
7. Celik M, Senol C, Keles M, Halezeroglu S, Urek S, Hacıbrahimoglu G, Ersev AA, Arman B. Surgical treatment of pulmonary hydatid disease in children: report of 122 cases. *J Pediatr Surg* 2000; 35: 1710-1713.
8. Coudert J, Ambroise-Thomas P, Kien Truong Thai, Pothier MA. 1st results concerning the serologic diagnosis of hydatid cyst by a new technic of immunofluorescence on slides. *Bull Soc Pathol Exot Filiales* 1967; 60: 555-563.
9. Turgut AT, Altin L, Topçu S, Kiliçoğlu B, Aliinok T, Kaptanoğlu E, Karademir A, Koşar U. Unusual imaging characteristics of complicated hydatid disease. *Eur J Radiol* 2007; 63: 84-93.
10. Carachi R, Azmy A. Foregut duplications. *Pediatr Surg Int* 2002; 18: 371-374.
11. Khuroo MS, Wani NA, Javid G, Khan BA, Yattoo GN, Shah AH, Jeelani SG. Percutaneous drainage compared with surgery for hepatic hydatid cysts. *N Engl J Med* 1997; 337: 881-887.
12. Rangasami R, Chandrasekharan A, Archana L, Santosh J. Case report: Antenatal MRI diagnosis of esophageal duplication cyst. *Indian J Radiol Imaging* 2009; 19: 75-77.