

# Novel Endoscopic Transnasal Technique for Anterolateral Thigh Flap Inset Post Nasopharyngeal Carcinoma Resection

Adrian S.H. Ooi, MRCS, MMed (Surg), FAMS (Plastic Surgery)\*†  
 Hargaven S. Gill, MBBS, MRCS\*  
 Kimberly L. Kiong, MMed (Otolaryn), MRCS, FAMS (ORL) †‡  
 Shuhui Xu, MBBS, MMed (Otolaryn), MRCS‡  
 Harold H.W. Heah, MMed (Otolaryn), MRCS, FAMS (ORL)†

**Summary:** Post-nasopharyngectomy reconstruction for recurrent nasopharyngeal carcinomas has been used for defect coverage and protection of vital structures. With the increasing use of endoscopic transnasal nasopharyngeal extirpation to offset complications faced with open techniques, there is a need for corresponding reconstructive support through a similar approach. We describe a novel endoscopic transnasal anterolateral thigh flap inset technique, combined with a transverse neck incision, in two patients who underwent transnasal nasopharyngectomy. We also include a video presentation of our operative technique. A vastus lateralis fascia free flap was used for one patient, and a vastus lateralis muscle free flap for the other. Both patients were aged 51 years. Mean nasopharyngeal defect size was 20 cm<sup>2</sup> (range 12–28 cm<sup>2</sup>). Average surgical stay was 13.5 days (11–16 days) and flap mucosalization was complete for both patients. No recipient site complications were observed in either patient, although donor site seroma formation was seen in one patient. Average time to speech recovery was 1.5 months (range 1–2 months) for both patients. Time to diet recovery was 2 months for one patient, whereas the other was on long-term percutaneous endoscopic gastrostomy feeding. There were no flap failures or peri-operative mortalities. Endoscopic transnasal anterolateral thigh flap inset to reconstruct the nasopharyngeal space is an effective technique that confers reduced morbidity and potentially better outcomes compared with open techniques. (*Plast Reconstr Surg Glob Open* 2021;9:e3665; doi: [10.1097/GOX.0000000000003665](https://doi.org/10.1097/GOX.0000000000003665); Published online 6 July 2021.)

**N**asopharyngeal resection is the standard of care for recurrent nasopharyngeal carcinomas, which is traditionally accomplished through open techniques.<sup>1</sup> However, open techniques in these irradiated surgical beds confer a higher risk of tissue scarring and postoperative maxillary osteoradionecrosis compared with endoscopic techniques. Subsequent nasopharyngeal reconstruction is often advised,<sup>2</sup> and the benefits of the anterolateral thigh (ALT) donor site are well known.<sup>3</sup> However, the challenge faced by the endoscopic reconstructionist is the ability to complete pedicular microvascular anastomosis while minimizing further incisions into irradiated tissues. Therefore,

we present a case report discussing our endoscopic transnasal ALT flap inset technique, with a single neck incision for microvascular anastomosis.

## METHODS

We describe our flap inset technique using the ALT flap through two patients who underwent endoscopic transnasal nasopharyngectomy.

### Surgical Technique

Reconstruction of the nasopharynx is deemed necessary for large anticipated postoperative defects with potential exposure of the internal carotid artery and/or existing skull base osteoradionecrosis from previous radiotherapy (RTx).

Through a transcervical incision, the internal carotid artery is traced through the parapharyngeal region to the level of the nasopharynx and protected using neuropatties. Subsequently, endoscopic nasopharyngectomy

From the \*Department of Plastic, Reconstructive and Aesthetic Surgery, Singapore General Hospital, Singapore; †SingHealth Duke-NUS Head and Neck Disease Centre, Singapore; and ‡SingHealth Otolaryngology, Singapore.

Received for publication March 8, 2021; accepted May 5, 2021.

Copyright © 2021 The Authors. Published by Wolters Kluwer Health, Inc. on behalf of The American Society of Plastic Surgeons. This is an open-access article distributed under the terms of the [Creative Commons Attribution-Non Commercial-No Derivatives License 4.0 \(CCBY-NC-ND\)](https://creativecommons.org/licenses/by-nc-nd/4.0/), where it is permissible to download and share the work provided it is properly cited. The work cannot be changed in any way or used commercially without permission from the journal.

DOI: [10.1097/GOX.0000000000003665](https://doi.org/10.1097/GOX.0000000000003665)

**Disclosure:** All the authors have no financial interests to declare in relation to the content of this article.

Related Digital Media are available in the full-text version of the article on [www.PRSGlobalOpen.com](http://www.PRSGlobalOpen.com).

commences with a posterior septectomy to allow access to the nasopharynx. Medial and posterior maxillectomies expose terminal branches of the internal maxillary artery. The medial pterygoid plate is then drilled down and nasopharyngectomy performed. The resultant defect size is endoscopically measured with a flexible ruler. (See Video [online], which displays endoscopic nasopharynx wound bed preparation, vastus lateralis free flap harvest, and chest tube guided flap inset technique.)

Simultaneously, a second surgical team proceeds to harvest the ALT free flap.<sup>4</sup> For smaller defect coverage, a vastus lateralis fascia (VLF) flap (Fig. 1) is harvested whereas a vastus lateralis muscle (VLM) is obtained for larger defects. For VLF harvest, dissection occurs through the Scarpa’s fascia until the supramuscular VLF is identified, after which the subscarpal fat is dissected off. The flap size is marked, and its distal border incised to locate the septum between the rectus femoris and VLM. The superior border of the flap is then incised to aid in perforator identification. Once a suitable perforator is found supplying the VLF, the flap is islanded and pedicle dissection of the descending branch of the lateral circumflex femoral artery (DBLCFA) is completed. If a VLM flap is required, a measured portion of the VLM is taken with the DBLCFA. (See Video [online], which displays endoscopic nasopharynx wound bed preparation, vastus lateralis free flap harvest, and chest tube guided flap inset technique.)

A 16F chest tube is introduced into the nares and grasped with a curved instrument passing through the previously created tunnel in the parapharyngeal space (Fig. 2) to form a conduit between the nasopharynx and neck recipient vessels (Fig. 3). The VLF flap is small enough to be introduced through the nares, whereas the larger VLM flap is placed into the nasopharynx via a velopharyngeal route (Fig. 4). The flap pedicle is subsequently introduced into the chest tube and guided into the neck for end-to-end arterial anastomosis between the DBLCFA and superior thyroid artery using 9/0 Ethilon sutures, and end-to-end venous anastomosis between the DBLCFA’s venae comitantes and internal jugular vein branches using 10/0 Ethilon sutures. (See Video [online], which displays endoscopic

**Table 1. Surgical Characteristics and Outcomes**

	Case 1	Case 2
Age* (gender)	51 (woman)	51 (man)
Indication of operation	Recurrent NPC	Base of skull osteomyelitis
TNM stage	T2N0M0	NA
Defect size (cm <sup>2</sup> )	12	28
Surgical stay (d)	11	16
Follow-up (mo)	15	6
Flap mucosalization	Complete	Complete
Donor site recovery	Seroma formation	Complete
Nasal crusting	Nil	Mild
Postoperative complications	Nil	Nil
Time to speech recovery (mo)†	2	1
Preoperative diet	DOC‡	PEG§
Postoperative diet	Blended	PEG
Time to diet recovery (mo)¶	2	Nil

\*Age defined in years.

†Speech recovery defined as 100% intelligible speech postoperatively.

‡Diet of choice.

§Percutaneous endoscopic gastrostomy.

¶Diet recovery defined as best attainable diet postoperatively.

nasopharynx wound bed preparation, vastus lateralis free flap harvest, and chest tube guided flap inset technique.)

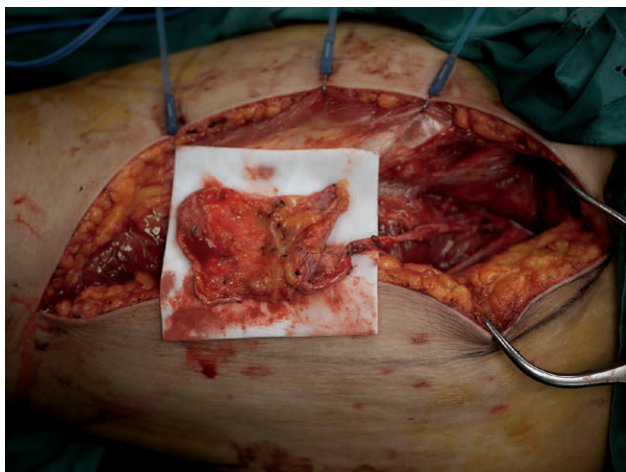
The flap is positioned and secured to the defect with fibrin glue and/or endoscopic staples. A nasogastric tube is then inserted under endoscopic visualization with a bismuth iodine paraffin paste pack placed in the nasal cavity for flap support.

**Postoperative Recovery**

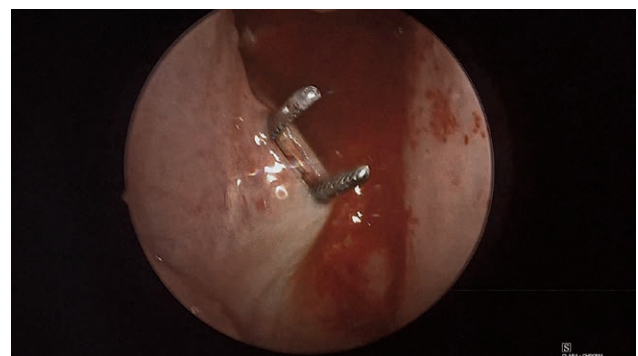Postoperatively, the flap is monitored daily through Doppler readings of the microvascular anastomosis in the right neck. The bismuth iodine paraffin paste pack is removed at the end of the first week, and nasoendoscopy is done to assess survival of the initially buried flap. The patient is then commenced on feeds with escalation of diet, and discharged home.

**RESULTS**

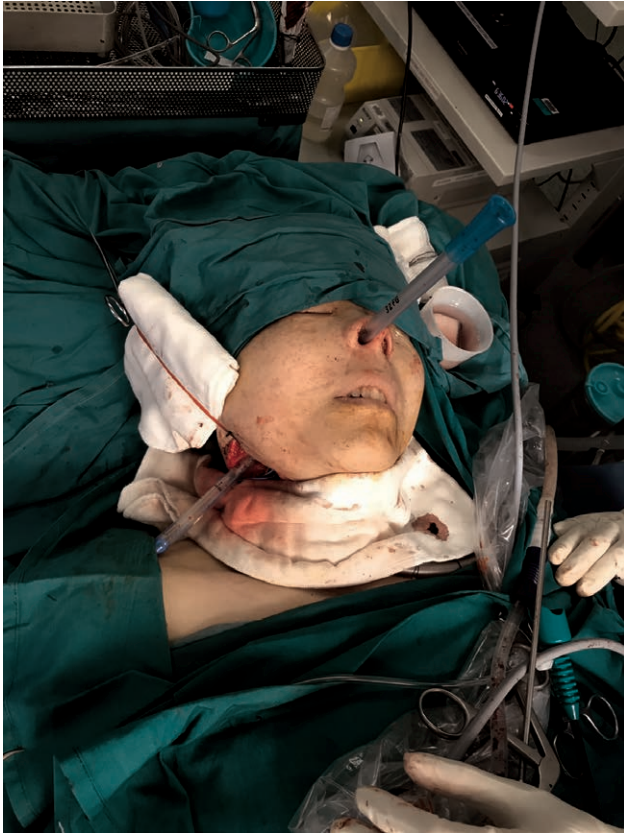A VLF flap was used for one patient and a VLM flap for the other. Both patients were aged 51 years, with a mean nasopharyngeal defect size of 20 cm<sup>2</sup> (range 12–28 cm<sup>2</sup>). Average surgical stay was 13.5 days (11–16 days), and flap



**Fig. 1.** Harvested VLF free flap.

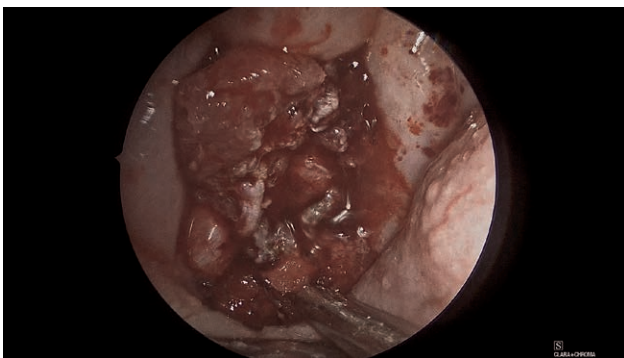

**Fig. 2.** Curved instrument inserted through the transcervical incision, up the parapharyngeal space and into the nasopharynx, preparing to grasp the chest tube inserted through the anterior nares for flap introduction into the posterior nasopharyngeal space with pedicle microanastomosis in the neck.



**Fig. 3.** Chest tube pulled from nasopharynx into neck via previously created tunnel in parapharyngeal space.

mucosalization was complete for both patients. No recipient site complications were observed, although donor site seroma formation was seen in 1 patient. Average time to speech recovery was 1.5 months (range 1–2 months) for both patients. Time to diet recovery was 2 months for one patient, whereas the other was on long-term percutaneous endoscopic gastrostomy feeding. Average postoperative follow-up duration was 10.5 months (range 6–15 months), and there was 100% flap survival with no perioperative mortalities.



**Fig. 4.** Intraoperative endoscopic placement of the VLM in the nasopharynx.

### Case 1

Case 1 is a 51-year-old Chinese woman diagnosed with rNPC, T2N0M0. She first presented with T1N1M0 NPC one year before, managed with RTx. She subsequently underwent endoscopic nasopharyngectomy and VLF flap reconstruction of the resultant 4 cm × 3 cm defect. Postoperatively, she sustained a minor donor site seroma, which was successfully evacuated. Subsequently, she underwent adjuvant RTx, and at 1-year follow-up, she was disease free with a healthy flap.

### Case 2

Case 2 is a 51-year-old Chinese man who first presented with T3N1M0 NPC 7 years before, which is managed with chemoradiation. He then sustained rNPC 3 and 4 years later, for which the condition was managed with endoscopic nasopharyngectomy and salvage RTx, respectively. Subsequently, he experienced severe trismus, resulting in the need for percutaneous endoscopic gastrostomy creation for feeding. He also sustained skull base osteomyelitis, which led to a left neck abscess, via a parapharyngeal space communication, requiring prolonged antibiotic therapy. For this, he underwent endoscopic nasopharyngectomy, burring of the skull base, and VLM flap reconstruction to obliterate the posterior nasopharynx. At the 6-month follow-up, he was disease-free with a healthy flap and sustained no further infections or recurrence.

## DISCUSSION

Endoscopic approaches for rNPC have gained popularity from being reserved for early stage tumor recurrences (rT1–rT2)<sup>5</sup> to comprising more advanced tumor recurrences (rT3–rT4) with good results when compared with open approaches.<sup>6</sup> However, these larger extirpative defects expose vital skull base structures such as the internal carotid artery which become difficult to reconstruct without free tissue coverage.

Free tissue options include the radial forearm free flap due to its thin and pliable nature<sup>7</sup> or muscle flaps whose bulk aid in dead space obliteration.<sup>3,8</sup> Of note, fascial flaps confer larger defect coverage than the radial forearm free flap while having similar benefits.<sup>9</sup> Thus, the ALT donor site offers an ideal choice for reconstruction, comprising both fascial and muscle components.

In our first case (Case 1), the area requiring flap coverage was relatively clean. Therefore, a VLF flap was chosen, entering the anterior nares with ease. In our second case (Case 2), the extent of resection, presence of osteoradionecrosis, and resultant defect size necessitated a larger well-vascularized VLM flap. Due to the associated risks of tissue ischemia and suture line dehiscence in irradiated wound beds,<sup>10</sup> fibrin glue and/or endoscopic staples were used with bismuth iodine paraffin paste packing to secure the flap.

The limitations of this study are its small sample size and retrospective nature of analysis.

## CONCLUSIONS

The endoscopic transnasal ALT flap inset technique described confers reduced morbidity and potentially better outcomes compared with open techniques. Further studies can be conducted with larger sample sizes, whilst comparing with newer transnasal flap inset techniques, to determine the ideal standard of care in nasopharyngeal reconstruction amidst an irradiated surgical bed.

**Adrian S.H. Ooi, MRCS, MMed (Surg), FAMS (Plastic Surgery)**  
 Department of Plastic, Reconstructive and Aesthetic Surgery  
 Singapore General Hospital  
 Outram Road, Singapore 169608  
 Singapore  
 E-mail: dradrianooi@gmail.com

## ACKNOWLEDGMENTS

*As no patient identifiable information was used, institutional ethics board approval was waived. Patient photographs were all taken with written consent, and any photographs reproduced for this publication were adequately de-identified.*

## REFERENCES

1. Vlantis AC, Yu BK, Kam MK, et al. Nasopharyngectomy: does the approach to the nasopharynx influence survival? *Otolaryngol Head Neck Surg.* 2008;139:40–46.
2. Thakkar P, Grossman A, Lin A, et al. Reconstructive flaps after salvage nasopharyngectomy. *Otolaryngol Open J.* 2016;2:24–7.
3. Joo YH, Cho KJ, Park JO, et al. Usefulness of the anterolateral thigh flap with vascularized fascia lata for reconstruction of orbital floor and nasal surface after total maxillectomy. *Laryngoscope.* 2013;123:2125–2130.
4. Wong CH, Wei FC. Anterolateral thigh flap. *Head Neck.* 2010;32:529–540.
5. Vlantis AC, Lee DL, Wong EW, et al. Endoscopic nasopharyngectomy in recurrent nasopharyngeal carcinoma: a case series, literature review, and pooled analysis. *Int Forum Allergy Rhinol.* 2017;7:425–432.
6. Wong EHC, Liew YT, Abu Bakar MZ, et al. A preliminary report on the role of endoscopic endonasal nasopharyngectomy in recurrent rT3 and rT4 nasopharyngeal carcinoma. *Eur Arch Otorhinolaryngol.* 2017;274:275–281.
7. Schwartz MS, Cohen JL, Meltzer T, et al. Use of the radial forearm microvascular free-flap graft for cranial base reconstruction. *J Neurosurg.* 1999;90:651–655.
8. Krane NA, Troob SH, Wax MK. Combined endoscopic and transcervical approach for free flap reconstruction of nasopharyngeal and clival defects: a case report. *Microsurgery.* 2019;39:259–262.
9. Veyrat M, Verillaud B, Herman P, et al. How I do it. The pedicled temporoparietal fascia flap for skull base reconstruction after endonasal endoscopic approaches. *Acta Neurochir (Wien).* 2016;158:2291–2294.
10. Tian B, Iyer NG, Tan HK, et al. Novel technique of creating a seal for the vacuum-assisted closure system application in complex head and neck wounds. *Head Neck.* 2016;38:E2523–E2526.