



# Ultrasonographic reliability and repeatability of simultaneous bilateral assessment of diaphragm muscle thickness during normal breathing

Nerea Molina-Hernández<sup>1</sup>, José López Chicharro<sup>2</sup>, Ricardo Becerro-de-Bengoa-Vallejo<sup>1^</sup>, Marta Elena Losa-Iglesias<sup>3^</sup>, David Rodríguez-Sanz<sup>1</sup>, Davinia Vicente-Campos<sup>4</sup>, Daniel Marugán-Rubio<sup>1,5</sup>, Samuel Eloy Gutiérrez-Torre<sup>1</sup>, César Calvo-Lobo<sup>1^</sup>

<sup>1</sup>Faculty of Nursing, Physiotherapy and Podiatry, Universidad Complutense de Madrid, Madrid, Spain; <sup>2</sup>Grupo FEBIO, Universidad Complutense de Madrid, Madrid, Spain; <sup>3</sup>Faculty of Health Sciences, Universidad Rey Juan Carlos, Madrid, Spain; <sup>4</sup>Faculty of Health Sciences, Universidad Francisco de Vitoria, Pozuelo de Alarcón, Madrid, Spain; <sup>5</sup>Centro Superior de Estudios Universitarios La Salle, Madrid, Spain

**Contributions:** (I) Conception and design: N Molina-Hernández, D Marugán-Rubio, SE Gutiérrez-Torre, ME Losa-Iglesias, D Vicente-Campos, JL Chicharro, R Becerro-de-Bengoa-Vallejo, D Rodríguez-Sanz, C Calvo-Lobo; (II) Administrative support: ME Losa-Iglesias, D Vicente-Campos; (III) Provision of study materials or patients: N Molina-Hernández, D Marugán-Rubio, SE Gutiérrez-Torre; (IV) Collection and assembly of data: N Molina-Hernández, JL Chicharro, R Becerro-de-Bengoa-Vallejo, D Rodríguez-Sanz, C Calvo-Lobo; (V) Data analysis and interpretation: N Molina-Hernández, JL Chicharro, R Becerro-de-Bengoa-Vallejo, D Rodríguez-Sanz, C Calvo-Lobo; (VI) Manuscript writing: All authors; (VII) Final approval of manuscript: All authors.

**Correspondence to:** David Rodríguez-Sanz, PT, DP, PhD. Faculty of Nursing, Physiotherapy and Podiatry, Universidad Complutense de Madrid, Plaza Ramón y Cajal, 3, Madrid 28040, Spain. Email: davidrodriguezsan@ucm.es.

**Background:** The diaphragm is considered the main muscle involved in breathing and also linked to trunk stabilization functions. Up to date, rehabilitative ultrasound imaging (RUSI) has been the most used technique to evaluate unilaterally the transcostal diaphragm thickness. Nevertheless, the inspiratory activity of both hemi-diaphragms is bilaterally performed at the same time, and its simultaneous evaluation with a thoracic orthosis could improve its assessment as well as its re-education with visual biofeedback of both hemi-diaphragms at the same time. The purpose was to evaluate the reliability and repeatability of simultaneous thickness measurements of both hemi-diaphragms bilaterally during normal breathing using a thoracic orthosis that allowed bilateral fixation of both right and left ultrasound probes.

**Methods:** The study was conducted in 46 healthy subjects, whose diaphragm thickness was measured bilaterally and simultaneously in the anterior axillary line during relaxed breathing with a designed thoracic orthosis and 2 ultrasound tools. Intra-examiner (same examiner), inter-examiner (2 examiners), intra-session (1 hour) and inter-session (1 week) reliability and repeatability between each pair of measurements of diaphragm muscle thickness were analyzed during normal breathing.

**Results:** Reliability and repeatability for intra-session evaluations using the thoracic orthosis were excellent to evaluate simultaneous thickness of both hemi-diaphragms by bilateral probes fixation (intraclass correlation coefficient =0.919–0.997; standard error of measurement =0.002–0.007 cm; minimum detectable change =0.006–0.020 cm), without systematic errors ( $P>0.05$ ) between each pair of measurements. Nevertheless, inter-session evaluations varied from good to excellent using the bilateral probes fixation (intraclass correlation coefficient =0.614–0.984; standard error of measurement =0.006–0.028 cm; minimum detectable change =0.017–0.079 cm), although some systematic errors were presented ( $P<0.05$ ).

<sup>^</sup> ORCID: Ricardo Becerro-de-Bengoa-Vallejo, 0000-0003-1568-7602; Marta Elena Losa-Iglesias, 0000-0001-7588-2069; Cesar Calvo-Lobo, 0000-0002-6569-1311.

**Conclusions:** Good to excellent reliability and repeatability was shown for simultaneous thickness measurements of both hemi-diaphragms bilaterally during normal breathing. Despite systematic errors were presented for some inter-examiner assessments, the use of the thoracic orthosis that allowed bilateral fixation of ultrasound probes could be recommended for simultaneous hemi-diaphragms breathing re-education by visual biofeedback.

**Keywords:** Biofeedback; psychology; diaphragm; repeatability; respiration; ultrasonography

Submitted Mar 15, 2023. Accepted for publication Aug 03, 2023. Published online Aug 17, 2023.

doi: 10.21037/qims-23-329

View this article at: <https://dx.doi.org/10.21037/qims-23-329>

## Introduction

The diaphragm was considered a key muscle placed in the trunk separating the thoracic cavity from the abdomen (1). From an anatomical point of view, its muscular region is shaped like a double dome divided into two parts by a central tendinous region. The medial region of this muscle is related to the lumbar vertebrae L2–L4 with their respective ligaments and its lateral region is related to the last six ribs (2). According to this location, it is the main muscle involved in the respiratory process, being responsible for up to 70% of pulmonary ventilation at rest (1). In addition, it is one of the muscles responsible for stabilizing the trunk together with the pelvic floor muscles and the abdominal wall (3), as well as their motor control, although the exact mechanisms by which the diaphragm stabilizes the trunk remain still unknown (4).

Therefore, assessment of both the morphology and function of the diaphragm may be crucial as it plays a key role and may be affected after certain surgical procedures or different neuromuscular (5) and/or respiratory conditions (6).

There are many techniques used in the evaluation and identification of the diaphragm such as computed tomography, radiography (7), electromyography (6), magnetic resonance imaging, fluoroscopy, plethysmography, and ultrasonography, among others (8).

Nevertheless, ultrasonography shows many advantages over the aforementioned techniques as it is a non-invasive imaging technique (9,10), not emitting ionizing radiation and allowing real-time imaging (10), which does not require patient transport for the test (11), offering the possibility of repeated images and spending relatively little time (2). Despite all its advantages, the main limitation of ultrasound is that this tool is an operator-dependent imaging technique which requires a certain degree of specialized training

and adequate experience of the examiner performing the assessment (6,11).

Among ultrasound techniques, the rehabilitative ultrasound imaging (RUSI) technique may be considered the approach used by physical therapists in the evaluation of the morphology and function of the different body structures. According to the term “Point of Care Ultrasound” (12), the motor control reeducation by RUSI may be considered a useful biofeedback method for patients with different conditions.

Indeed, ultrasound is a useful tool that allows physical therapists to quantitatively assess the movement and functionality of the diaphragm in both patients with musculoskeletal conditions and healthy subjects, as it may be used as a predictor of multiple alterations (3). Nevertheless, the function of the diaphragm evaluated by transdiaphragmatic pressures were weakly related to the thickening fraction of this muscle (13) and the application of diaphragmatic ultrasonography displayed controversies about its diagnostic value in critical care fields (14). Thus, the improvement of the diaphragm thickness evaluation may be the first aim to improve the ultrasound reliability and repeatability avoiding some systematic errors of measurement previously reported, and the use of ultrasonography as a visual biofeedback tool to reeducate the diaphragm contraction during normal breathing may be considered as a secondary purpose for future studies (4).

The diaphragm may be measured by ultrasound in different ways and modes, but there is a lack of consensus to which method is most advantageous, being B-mode considered as the preferred method to determine diaphragm thickness (15). Commonly, the thickness of the diaphragm is assessed in the apposition zone as the region of the trunk where the abdominal contents meet the lower part of the

rib cage (16,17). In this area, the diaphragm appears on the ultrasound image as a structure with 3 parts which may be distinguished: a central hypoechogenic area, that corresponds to the diaphragm muscle tissue, delimited by 2 hyperechogenic lines, that correspond to the perimuscular connective tissue as the most superficial edge and the diaphragmatic pleural membranes and the peritoneum as the deepest edge (18).

Recently, our research group evaluated the thickness of the diaphragm muscle in this region using a thoracic orthosis that allowed a unilateral fixation of an ultrasound probe improving the reliability and repeatability of the manual probe fixation with adequate concurrent validity during normal breathing (4). Unilateral RUSI visual biofeedback of each hemi-diaphragm separately in conjunction with inspiratory muscle training may improve lung function parameters (19). Nevertheless, the inspiratory activity of both hemi-diaphragms is bilaterally performed at the same time, and its simultaneous evaluation with a thoracic orthosis could improve its assessment as well as its re-education with visual biofeedback of both hemi-diaphragms at the same time (4,19). This fact may be especially important due to the human diaphragm contractile properties were well illustrated by single bilateral contraction while unilateral contraction stimulation was misleading to distortion secondary to abnormal changes of the diaphragm geometry (20). These considerations led us to investigate firstly the reliability and repeatability of the bilateral ultrasound measurements of both right and left hemi-diaphragms at the same time and secondly the use of the bilateral probes fixation thoracic orthosis in order to determine its effectiveness as a visual biofeedback tool in future studies (4,19). Therefore, the purpose of this study was to evaluate the reliability and repeatability of the simultaneous thickness measurements of both hemi-diaphragms bilaterally during normal breathing using a thoracic orthosis that allowed bilateral fixation of both right and left ultrasound probes. We present this article in accordance with the Guidelines for Reporting Reliability and Agreement Studies (GRRAS) reporting checklist (21) (available at <https://qims.amegroups.com/article/view/10.21037/qims-23-329/rc>).

## Methods

### *Study design*

This study was carried out from May 1, 2021, to November 30, 2022, according to the GRRAS (21). The study was

approved by the ethics committee of the Hospital Clínico San Carlos (Madrid, Spain) (No. 20.655-E\_BS). All participants included in the study received an information sheet and signed an informed consent, complying with the Declaration of Helsinki (as revised in 2013) (22) and Spanish Law 14/2007 on Biomedical Research. The research respected the Spanish Organic Law 3/2018, of December 5, on the Protection of Personal Data and Guarantee of Digital Rights.

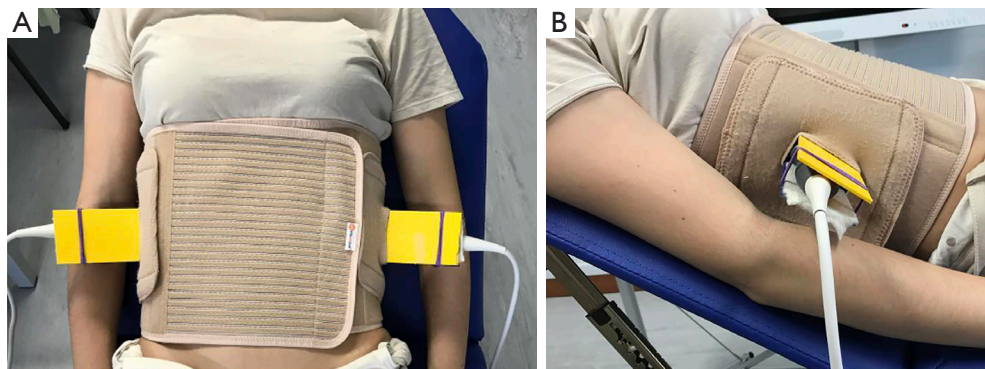
A patent registry was carried out as a utility model for the bilateral thoracic orthosis including both right and left holding devices for 2 ultrasound probes in the Spanish Patent and Trademark Office (number of application: U202200045; publication number: ES1288519; issue date: 30 March, 2022). These holding devices were used to fix both right and left ultrasound probes within the thoracic orthosis to measure diaphragm bilateral thickness at the same time during normal breathing (4). This research project was funded and supported by grant PID2020-117162RA-I00 funded by MCIN/AEI/10.13039/501100011033 from the Ministry of Science and Research as well as the State Agency for Investigation of the Spanish Government under the 2020 Call for Innovation, Development and Research (“I+D+i Projects”) within the framework of the State Programs for Knowledge Generation and Scientific and Technological Strengthening of the I+D+i System and I+D+i oriented to the Challenges of Society (grant No. PID2020-117162RA-I00).

### *Sample size calculation*

The sample size calculation was analyzed by the version 3.1.9.2 of the G\*Power<sup>®</sup> (University of Dusseldorf; Germany), using bivariate statistical correlation tests. According to a prior similar study assessing the reliability of ultrasound thickness measurements unilaterally (4), a coefficient of 0.4 was used to establish a moderate correlation between the measurements of 2 examiners obtained with the thoracic orthosis that used 2 ultrasound probes simultaneously to measure the thickness of the diaphragm bilaterally at transcostal level. Attending to bilateral tests,  $\alpha$  error of 0.05 and power of 0.80, a total sample size of 46 participants was obtained as the required sample size calculation.

### *Recruitment and sampling*

A total sample of 63 healthy participants was recruited for



**Figure 1** Thoracic orthosis for simultaneous bilateral diaphragm muscle thickness measurement during normal breathing using the RUSI technique. (A) Visualization of the designed thoracic orthosis that allowed the fixation of 2 ultrasound probes for the measurement of diaphragm muscle thickness in healthy participants during relaxed breathing activity using the RUSI technique. (B) Fixation of the ultrasound probe to the designed thoracic orthosis. RUSI, rehabilitative ultrasound imaging.

eligibility through consecutive sampling at the Faculty of Nursing, Physiotherapy and Podiatry of the Complutense University of Madrid (Spain). Nevertheless, 17 participants were excluded because they presented poor visualization of the diaphragm muscle interfaces in the ultrasound images, complicating diaphragm thickness measurements (4,19).

### *Study participants*

Inclusion criteria comprised healthy participants from 18 to 65 years without neuromuscular alterations in the year prior to the beginning of the study. Exclusion criteria comprised all those participants with low back pain, skin alterations, pregnancy, surgeries or pathologies of the lower limb, respiratory, neurological, neuromuscular, rheumatic or congenital lumbar alterations, a body mass index (BMI) above 31 kg/m<sup>2</sup> (4).

### *Protocol*

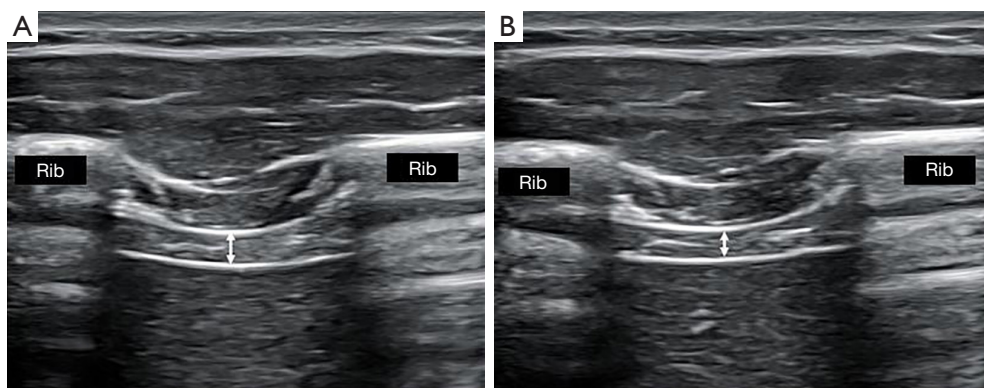
The thoracic orthosis was made of neoprene allowing complete thoracic mobility. In addition, this tool presented 2 cavities that allowed the introduction of the ultrasound gel, being able to visualize bilateral and simultaneously the last 2 intercostal spaces by two holding devices (4) that fixed 2 ultrasound probes perpendicularly at both right and left intercostal spaces in the mid-axillary line (*Figure 1*).

Two high-quality ultrasound tools (Ecube i7; Alpinion Medical System; Seoul, Korea) and 2 linear probes (Broadband Linear type L3\_12T, 38.4 mm field of view, 128 elements) were used for B-mode evaluation of the diaphragm.

A preset of frequency at 12 MHz, gain at 64 points, depth at 3 cm, dynamic range at 64 points and focus at 2-cm depth was used. Intra-examiner (same examiner), inter-examiner (2 examiners), intra-session (same day 1 hour apart) and inter-session (alternate days 1 week apart in the same time slot) reproducibility and reliability were analyzed by randomization of the order of examiners, who presented more than 4 years of experience with the RUSI technique for diaphragm evaluation (4). The images obtained were supervised by a physician with also more than 4 years of diaphragm ultrasound assessment as well as saved, coded, and analyzed with the ImageJ software (23). The mean of 3 repeated measurements were used for data analysis (23).

### *Descriptive data and outcome measurements*

The following socio-demographic descriptive data were considered: sex (dichotomous variable divided into male or female participants), age (quantitative variable measured in years), height [quantitative variable measured in meters (m)], weight [quantitative variable measured in kilograms (kg)], BMI [quantitative variable measured in kilograms/meters<sup>2</sup> (kg/m<sup>2</sup>)], International Physical activity Questionnaire (IPAQ) scores [quantitative variable measured in metabolic equivalents per minute per week (MET minutes/week)] whose reliability presented an intraclass correlation coefficient (ICC) of 0.93 [95% confidence interval (CI): 0.86–0.97] (24) and smoking habit (dichotomous variable divided into yes or no). Following the methodology of a prior similar study (4), physical activity score and smoking habits were not considered exclusion



**Figure 2** Diaphragmatic thickness visualized by RUSI technique in B-mode with the designed thoracic orthosis at the anterior axillary line in the last intercostal space. (A) Diaphragmatic thickness (white arrow) in maximum inspiration during a relaxed breathing pattern. (B) Diaphragmatic thickness (white arrow) in maximum expiration during a relaxed breathing pattern. RUSI, rehabilitative ultrasound imaging.

criteria and were considered baseline data to describe the study sample in order to promote the reproducibility of future studies with similar or different samples features,

Furthermore, the thickness of the diaphragm muscle was considered the main outcome measurement as a quantitative variable measured in centimeters (cm) and performed bilaterally and simultaneously (both left and right last intercostal spaces) in maximum inspiration ( $T^{\text{ins}}$ ), maximum expiration ( $T^{\text{exp}}$ ) and their difference ( $T^{\text{ins}} - T^{\text{exp}}$ ; maximum inspiration – maximum expiration) during relaxed breathing determined by the RUSI technique (Figure 2). These outcomes were previously measured with an orthotic device probe fixation at one hemi-diaphragm in an isolated manner showing excellent reliability with an ICC from 0.852 to 0.996, standard error of measurement (SEM) from 0.0002 to 0.054 cm, and minimum detectable change (MDC) from 0.002 to 0.072 cm (4).

### Data analysis

The Statistical Package of Social Sciences (SPSS), version 24.0 (IBM; Armonk, NY, USA), was used for data analysis. Firstly, the normality of the values of the descriptive data and outcome measurements was checked using the Kolmogorov-Smirnov statistical test. Secondly, data were described by mean and standard deviation (SD) completed by the upper and lower limits for the 95% CI. Finally, intra-examiner (same examiner), inter-examiner (2 examiners), intra-session (same day 1 hour apart) and inter-session (alternate days 1 week apart in the same time slot) reliability

and repeatability between each pair of measurements of diaphragm muscle thickness were analyzed at  $T^{\text{ins}}$ ,  $T^{\text{exp}}$  and  $T^{\text{ins}} - T^{\text{exp}}$  (4). Indeed, ICC were calculated and classified as poor (ICC <0.40), weak (ICC =0.40–0.59), good (ICC =0.60–0.74), excellent (ICC =0.75–1.00) (25). Furthermore, measurement errors were calculated and determined by standard errors of measurement (SEM) using the formula  $\text{SEM} = \text{SD} * \sqrt{1-\text{ICC}}$  (26) and MDC applying the formula  $\text{MDC} = \sqrt{2} * 1.96 * \text{SEM}$  for a 95% CI according to Bland & Altman (27). Lastly, statistically significant differences between each pair of measurements were analyzed by the Student's *t*-test and Wilcoxon test for paired samples according to parametric or non-parametric data, respectively, considering a P value <0.05 for a 95% CI (4).

## Results

### Descriptive data

From 46 healthy subjects who participated finally in this reliability and repeatability study, 21 participants were female (45.7%) and 25 participants were male (54.3%) presenting weight and height mean  $\pm$  SD (95% CI) of  $66.42 \pm 12.01$  (63.85–70.99) kg and  $1.72 \pm 0.08$  (1.69–1.74) m, respectively. In addition, their median and interquartile range were 24 and 3 years, respectively for age; 21.84 and  $3.7 \text{ kg/m}^2$ , respectively for BMI; and 3,113.5 and 2,765.38 MET minutes/week, respectively for the IPAQ questionnaire. Only 4.3% were smokers versus 95.7% who were non-smokers.

**Table 1** Intra-session and intra-examiner reliability and repeatability for the RUSI bilateral and simultaneous diaphragm thickness analysis using the designed orthosis during relaxed breathing

RUSI thickness	RUSI diaphragm thickness (cm), mean $\pm$ SD (95% CI)		ICC (95% CI)	SEM	MDC	P value
	Baseline	After 1 h				
Right diaphragm						
T <sup>ins</sup>	0.172 $\pm$ 0.050 (0.157–0.187)	0.172 $\pm$ 0.050 (0.157–0.187)	0.994 (0.989–0.997)	0.003	0.008	0.468 <sup>†</sup>
T <sup>exp</sup>	0.148 $\pm$ 0.045 (0.134–0.161)	0.149 $\pm$ 0.045 (0.136–0.162)	0.996 (0.992–0.998)	0.002	0.007	0.206 <sup>#</sup>
T <sup>ins</sup> – T <sup>exp</sup>	0.024 $\pm$ 0.035 (0.013–0.034)	0.023 $\pm$ 0.035 (0.012–0.033)	0.983 (0.969–0.991)	0.004	0.012	0.089 <sup>†</sup>
Left diaphragm						
T <sup>ins</sup>	0.187 $\pm$ 0.053 (0.171–0.203)	0.187 $\pm$ 0.051 (0.172–0.203)	0.997 (0.955–0.998)	0.002	0.006	0.377 <sup>†</sup>
T <sup>exp</sup>	0.160 $\pm$ 0.042 (0.148–0.173)	0.161 $\pm$ 0.039 (0.149–0.173)	0.992 (0.985–0.995)	0.003	0.009	0.579 <sup>†</sup>
T <sup>ins</sup> – T <sup>exp</sup>	0.026 $\pm$ 0.027 (0.018–0.034)	0.026 $\pm$ 0.027 (0.017–0.034)	0.984 (0.972–0.991)	0.002	0.007	0.653 <sup>#</sup>

<sup>#</sup>, Student's *t*-test for paired samples was used; <sup>†</sup>, Wilcoxon test for paired sample was used. RUSI, rehabilitative ultrasound imaging; SD, standard deviation; CI, confidence interval; ICC, intraclass correlation coefficient; SEM, standard error of measurement; MDC, minimum detectable change; T<sup>ins</sup>, maximum inspiration time; T<sup>exp</sup>, maximum expiration time.

#### ***Intra-session and intra-examiner reliability and repeatability***

The proposed procedure within the orthosis device that allowed bilateral fixation of both ultrasound probes presented an excellent intra-session and intra-examiner reliability and repeatability for RUSI diaphragm thickness according with the ICC =0.983–0.997, SEM =0.002–0.004 cm and MDC =0.006–0.012 cm without statistical differences (P>0.05) between each pair of measurements, as shown in *Table 1*.

#### ***Inter-session and intra-examiner reliability and repeatability***

The proposed protocol for the bilateral and simultaneous assessment of the diaphragm thickness showed excellent inter-session and intra-examiner reliability and repeatability for RUSI diaphragm thickness (ICC =0.919–0.990; SEM =0.004–0.007 cm; MDC =0.011–0.020 cm) and no statistically significant differences (P>0.05) were observed between each pair of measurements, as shown in *Table 2*.

#### ***Intra-session and inter-examiner reliability and repeatability***

The proposed bilateral and simultaneous evaluation of the diaphragm thickness within the orthosis showed a good to excellent intra-session and inter-examiner reliability

and repeatability (ICC =0.614–0.811; SEM =0.011–0.028 cm; MDC =0.032–0.079 cm) and no statistically significant differences (P>0.05) were observed in thickness difference between maximum inspiration and expiration (T<sup>ins</sup> – T<sup>exp</sup>) measurements of right diaphragm, as shown in *Table 3*. Nevertheless, significant differences (P<0.05) were observed between each pair of measurements for the rest of outcomes.

#### ***Inter-session and inter-examiner reliability and repeatability***

The measurement protocol for the bilateral and simultaneous diaphragm thickness by the thoracic orthosis that allowed fixation of the ultrasound probes presented an excellent inter-session and inter-examiner reliability and repeatability for RUSI diaphragm thickness with ICC =0.812–0.984, SEM =0.006–0.012 cm and MDC =0.017–0.035 cm, without statistically significant differences between each pair of thickness measurements of the right and left diaphragm at T<sup>ins</sup> (P>0.05), as shown in *Table 4*. Nevertheless, significant differences (P<0.05) were presented between each pair of measurements for the rest of outcomes.

## **Discussion**

Thus, our study findings suggested that simultaneous

**Table 2** Inter-session and intra-examiner reliability and repeatability for the RUSI bilateral and simultaneous diaphragm thickness analysis using the designed orthosis during relaxed breathing

RUSI thickness	RUSI diaphragm thickness (cm), mean ± SD (95% CI)		ICC (95% CI)	SEM	MDC	P value
	Baseline	After 1 week				
Right diaphragm						
T <sup>ins</sup>	0.172±0.050 (0.157–0.187)	0.173±0.050 (0.158–0.188)	0.990 (0.981–0.994)	0.005	0.013	0.437 <sup>#</sup>
T <sup>exp</sup>	0.148±0.045 (0.134–0.161)	0.149±0.043 (0.136–0.162)	0.990 (0.983–0.995)	0.004	0.012	0.381 <sup>†</sup>
T <sup>ins</sup> – T <sup>exp</sup>	0.024±0.035 (0.013–0.034)	0.024±0.035 (0.013–0.034)	0.985 (0.973–0.992)	0.004	0.011	0.946 <sup>#</sup>
Left diaphragm						
T <sup>ins</sup>	0.187±0.053 (0.171–0.203)	0.185±0.051 (0.170–0.201)	0.987 (0.976–0.993)	0.005	0.016	0.879 <sup>†</sup>
T <sup>exp</sup>	0.160±0.042 (0.148–0.173)	0.160±0.039 (0.148–0.171)	0.987 (0.977–0.993)	0.004	0.012	0.871 <sup>†</sup>
T <sup>ins</sup> – T <sup>exp</sup>	0.026±0.027 (0.018–0.034)	0.025±0.026 (0.017–0.033)	0.919 (0.854–0.955)	0.007	0.020	0.452 <sup>†</sup>

<sup>#</sup>, Student's *t*-test for paired samples was used; <sup>†</sup> Wilcoxon test for paired sample was used. RUSI, rehabilitative ultrasound imaging; SD, standard deviation; CI, confidence interval; ICC, intraclass correlation coefficient; SEM, standard error of measurement; MDC, minimum detectable change; T<sup>ins</sup>, maximum inspiration time; T<sup>exp</sup>, maximum expiration time.

**Table 3** Intra-session and inter-examiner reliability and repeatability for the RUSI bilateral and simultaneous diaphragm thickness analysis using the designed orthosis during relaxed breathing

RUSI thickness	RUSI diaphragm thickness (cm), mean ± SD (95% CI)		ICC (95% CI)	SEM	MDC	P value
	Examiner 1	Examiner 2				
Right diaphragm						
T <sup>ins</sup>	0.172±0.050 (0.157–0.187)	0.195±0.059 (0.177–0.212)	0.676 (0.400–0.823)	0.027	0.075	<0.001 <sup>*†</sup>
T <sup>exp</sup>	0.148±0.045 (0.134–0.161)	0.177±0.061 (0.159–0.195)	0.614 (0.260–0.793)	0.028	0.079	0.001 <sup>*#</sup>
T <sup>ins</sup> – T <sup>exp</sup>	0.024±0.035 (0.013–0.034)	0.017±0.034 (0.007–0.028)	0.811 (0.659–0.895)	0.013	0.038	0.117 <sup>†</sup>
Left diaphragm						
T <sup>ins</sup>	0.187±0.053 (0.171–0.203)	0.200±0.059 (0.183–0.218)	0.804 (0.644–0.892)	0.023	0.063	0.006 <sup>*†</sup>
T <sup>exp</sup>	0.160±0.042 (0.148–0.173)	0.182±0.057 (0.165–0.199)	0.678 (0.392–0.826)	0.024	0.069	<0.001 <sup>*†</sup>
T <sup>ins</sup> – T <sup>exp</sup>	0.026±0.027 (0.018–0.034)	0.018±0.030 (0.009–0.027)	0.800 (0.628–0.891)	0.011	0.032	0.022 <sup>*†</sup>

<sup>\*</sup>, P<0.05 was considered as statistically significant (95% CI); <sup>#</sup>, Student's *t*-test for paired samples was used; <sup>†</sup>, Wilcoxon test for paired sample was used. RUSI, rehabilitative ultrasound imaging; SD, standard deviation; CI, confidence interval; ICC, intraclass correlation coefficient; SEM, standard error of measurement; MDC, minimum detectable change; T<sup>ins</sup>, maximum inspiration time; T<sup>exp</sup>, maximum expiration time.

evaluation of both hemi-diaphragms with the thoracic orthosis presented good to excellent reliability and repeatability. In spite of systematic errors were presented for some inter-examiner evaluations, the use of this thoracic orthosis allowing bilateral fixation of 2 ultrasound probes to both right and left hemi-diaphragms at the same time could be recommended for normal breathing re-education as a visual biofeedback.

As mentioned above, the main disadvantage of ultrasound carried out by manual probe fixation was the variability of the imaging test based on the experience and knowledge of the technique by the examiner who performed the assessment (6,11). The unilateral fixation of the ultrasound probe improved reliability avoiding systematic errors of measurement to determine thickness of each hemi-diaphragm during normal breathing and

**Table 4** Inter-session and inter-examiner reliability and repeatability for the RUSI bilateral and simultaneous diaphragm thickness analysis using the designed orthosis during relaxed breathing

RUSI thickness	RUSI diaphragm thickness (cm), mean $\pm$ SD (95% CI)		ICC (95% CI)	SEM	MDC	P value
	Examiner 1	Examiner 2				
Right diaphragm						
T <sup>ins</sup>	0.173 $\pm$ 0.050 (0.158–0.188)	0.173 $\pm$ 0.042 (0.161–0.186)	0.950 (0.910–0.973)	0.010	0.027	0.178 <sup>†</sup>
T <sup>exp</sup>	0.149 $\pm$ 0.043 (0.136–0.162)	0.159 $\pm$ 0.041 (0.147–0.171)	0.927 (0.835–0.964)	0.010	0.029	<0.001* <sup>†</sup>
T <sup>ins</sup> – T <sup>exp</sup>	0.024 $\pm$ 0.035 (0.013–0.034)	0.014 $\pm$ 0.032 (0.004–0.023)	0.827 (0.666–0.908)	0.012	0.035	0.002* <sup>†</sup>
Left diaphragm						
T <sup>ins</sup>	0.185 $\pm$ 0.051 (0.170–0.201)	0.187 $\pm$ 0.049 (0.172–0.201)	0.984 (0.971–0.991)	0.006	0.017	0.096 <sup>†</sup>
T <sup>exp</sup>	0.160 $\pm$ 0.039 (0.148–0.171)	0.169 $\pm$ 0.037 (0.157–0.180)	0.955 (0.860–0.980)	0.007	0.021	<0.001* <sup>†</sup>
T <sup>ins</sup> – T <sup>exp</sup>	0.025 $\pm$ 0.026 (0.017–0.033)	0.017 $\pm$ 0.023 (0.011–0.024)	0.812 (0.642–0.899)	0.009	0.027	0.010* <sup>†</sup>

\*, P<0.05 was considered as statistically significant (95% CI); <sup>†</sup>, Wilcoxon test for paired sample was used. RUSI, rehabilitative ultrasound imaging; SD, standard deviation; CI, confidence interval; ICC, intraclass correlation coefficient; SEM, standard error of measurement; MDC, minimum detectable change; T<sup>ins</sup>, maximum inspiration time; T<sup>exp</sup>, maximum expiration time.

was applied to improve respiratory function by unilateral visual re-education of each hemi-diaphragm in athletes with lumbopelvic pain (4,19). Currently, our study findings support the use of the thoracic orthosis for the simultaneous and bilateral diaphragm thickness evaluation, recognizing some systematic errors during inter-examiner assessments, and overall it use for simultaneous re-education interventions of both hemi-diaphragms by visual biofeedback. Concretely, unilateral ultrasound evaluations of diaphragm thickness by a thoracic orthosis (ICC =0.852–0.996; SEM =0.0002–0.054 cm; MDC =0.002–0.072 cm) improved the reliability and repeatability of manual probe fixation (ICC =0.714–0.997; SEM =0.003–0.023 cm; MDC =0.008–0.064 cm) avoiding most systematic errors of measurement (4). Also, the bilateral and simultaneous assessment of the diaphragm thickness using a thoracic orthosis presented an adequate reliability and repeatability (ICC =0.614–0.997; SEM =0.002–0.028 cm; MDC =0.006–0.079 cm), although showing more systematic errors of measurement compared to the unilateral probe fixation measurements of each hemi-diaphragm separately by a thoracic orthosis (4).

Despite the described thoracic orthosis for the simultaneous and bilateral diaphragm thickness evaluation presented excellent reliability and repeatability for all intra- and inter-rater evaluations, systematic errors were only shown for inter-rater evaluations. Specifically, systematic errors (P<0.05) were presented for all intra-session and

inter-rater measurements at T<sup>ins</sup> and T<sup>exp</sup> of both hemi-diaphragms and T<sup>ins</sup> – T<sup>exp</sup> of left diaphragm, but not for the thickness difference of right diaphragm (P>0.05) between maximum inspiration and expiration (T<sup>ins</sup> – T<sup>exp</sup>). In addition, systematic errors (P<0.05) were also presented for all inter-session and inter-rater measurements at T<sup>exp</sup> and T<sup>ins</sup> – T<sup>exp</sup> of both hemi-diaphragms, except for thickness measurements of the right and left diaphragm (P>0.05) at maximum inspiration (T<sup>ins</sup>). These systematic errors may be due to the bilateral variability of the diaphragm position and rib cage (28,29), anatomical variations (2), and the lack of adaptability of the thoracic orthosis secondary to its material deformation during normal breathing and inter-raters criteria for bilateral probe fixation (4,19) to permit an adequate simultaneous thickness evaluation of both right and left hemi-diaphragms at the same time.

Indeed, reliability and repeatability for intra-session evaluations using the thoracic orthosis were excellent and similar to evaluate each hemi-diaphragm thickness separately by unilateral probe fixation (ICC =0.935–0.996; SEM =0.0002–0.012 cm; MDC =0.005–0.035 cm) (4) and simultaneous thickness of both hemi-diaphragms by bilateral probes fixation (ICC =0.919–0.997; SEM =0.002–0.007 cm; MDC =0.006–0.020 cm), without systematic errors (P>0.05) between each pair of measurements. Nevertheless, inter-session evaluations were excellent using unilateral probe fixation (ICC =0.852–0.982, SEM =0.001–0.054 cm, MDC =0.002–0.072 cm) (4), while



varied from good to excellent using the bilateral probes fixation (ICC =0.614–0.984; SEM =0.006–0.028 cm; MDC =0.017–0.079 cm) showing more systematic errors of measurement. Thus, the thoracic orthosis with the unilateral probe fixation may be more reliable avoiding systematic errors of measurement for diaphragm thickness assessments (4), while the thoracic orthosis with bilateral probes fixation could be more advisable for diaphragm visual biofeedback interventions allowing breathing reeducation for both hemi-diaphragms at the same time due to their visual biofeedback did not seem to be influenced by these measurement errors and may permit an adequate visualization of both right and left diaphragm layers during normal breathing (4,19).

Diaphragmatic breathing reeducation by RUSI visual biofeedback with the thoracic orthosis could facilitate bilateral probes fixation using 2 ultrasound machines permitting the visualization of both ultrasound screens at the same time, explaining thickening of both right and left hemi-diaphragms during inspiration as well as correcting paradoxical breathing patterns, for example in patients suffering from low back pain or improve lung function (19). Otherwise, it might be acknowledged that systematic errors occur, but that the validity and reliability of the manual approach could still be sufficient to guide therapy (4), although more than one clinician should be necessary to fix both probes and manage both ultrasound tools at the same time.

### *Future research lines*

The thoracic orthosis studied and investigated in this study, apart from being useful and reliable for measuring the thickness of the diaphragm muscle bilaterally and simultaneously in healthy subjects during the normal and relaxed respiratory cycle, may also be useful as a biofeedback tool to improve motor control of the diaphragm muscle. This intervention may be useful to improve respiratory function in patients suffering from low back pain (4,19), due to the role of the diaphragm as a stabilizer of the lumbar region, which presented smaller thickness and smaller excursion and a higher position in patients with this condition (27).

Furthermore, it would be interesting to perform a progression in the training and evaluation of the diaphragm in different postures, since all trunk stabilization training

seems to start with exercises in weightless positions and ends in more upright positions (29).

Lastly, the replication of this study in the next future in samples with similar or different physical activity levels and smoking habits could be useful due to these features could modify the diaphragm thickness and thus the reliability of ultrasound measurements (4).

### *Limitations*

One of the limitations of the present study may be the position of diaphragm assessment due to the thickness of the diaphragm varied depending on the evaluation position according to its location in the rib cage as well as the effect and pressure that viscera can exert on diaphragmatic movement and position (29). Another limitation was the exclusion of some participants secondary to poor visualization of the diaphragm muscle interfaces in the ultrasound images which complicated diaphragm bilateral and simultaneous thickness measurements. Anatomical variations of the diaphragm insertions may be common and differed between both right and left hemi-diaphragms (2). In spite of the authors of the manuscript declared financial interests in the context of a patent application, they acknowledged systematic errors of measurement for inter-rater assessments with the orthosis device for bilateral probe fixation. Finally, the moderate correlation for the sample size calculation was established based on a prior similar study assessing the reliability of ultrasound thickness measurements unilaterally within a thoracic orthosis (4), although a strong correlation could have been used in order to strengthen the accuracy of this study. Despite the ICC was classified as good from 0.60 to 0.74 to determine our study findings and conclusions according to prior recommendations (25), we acknowledge that other classifications could be more exigent suggesting a lower ICC range.

### *Conclusions*

Good to excellent reliability and repeatability was shown for simultaneous thickness measurements of both hemi-diaphragms bilaterally during normal breathing. Despite systematic errors were presented for some inter-examiner assessments, the use of the thoracic orthosis that allowed bilateral fixation of ultrasound probes could be

recommended for simultaneous hemi-diaphragms breathing re-education by visual biofeedback.

## Acknowledgments

*Funding:* This work was supported by the Ministry of Science and Research as well as the State Agency for Investigation of the Spanish Government under the 2020 Call for Innovation, Development, and Research (“I+D+i Projects”) within the framework of the State Programs for Knowledge Generation and Scientific and Technological Strengthening of the I+D+i System and I+D+i oriented to the Challenges of Society (grant No. PID2020-117162RA-I00, funded by MCIN/AEI/10.13039/501100011033).

## Footnote

*Reporting Checklist:* The authors have completed the GRRAS reporting checklist. Available at <https://qims.amegroups.com/article/view/10.21037/qims-23-329/rc>

*Conflicts of Interest:* All authors have completed the ICMJE uniform disclosure form (available at <https://qims.amegroups.com/article/view/10.21037/qims-23-329/coif>). JLC, RBdBV, DRS, and CCL report competing financial interests due to a patent registry was carried out as a utility model for the bilateral thoracic orthosis including both right and left holding devices for 2 ultrasound probes in the Spanish Patent and Trademark Office (number of application: U202200045; publication number: ES1288519; issue date: 30 March, 2022). The other authors have no conflicts of interest to declare.

*Ethical Statement:* The authors are accountable for all aspects of the work in ensuring that questions related to the accuracy or integrity of any part of the work are appropriately investigated and resolved. The study was approved by the ethics committee of the Hospital Clínico San Carlos (Madrid, Spain) (No. 20.655-E\_BS). The study was conducted in accordance with the Declaration of Helsinki (as revised in 2013). All participants included in the study received an information sheet and signed an informed consent.

*Open Access Statement:* This is an Open Access article distributed in accordance with the Creative Commons

Attribution-NonCommercial-NoDerivs 4.0 International License (CC BY-NC-ND 4.0), which permits the non-commercial replication and distribution of the article with the strict proviso that no changes or edits are made and the original work is properly cited (including links to both the formal publication through the relevant DOI and the license). See: <https://creativecommons.org/licenses/by-nc-nd/4.0/>.

## References

1. Kuo CY, Chuang HC, Zhou YL, Wu YP, Wang JC, Kuo CC, Jeng SC, Kao HW, Huang MY, Chiou JF, Liao AH. Application of Ultrasound Image Tracking Algorithm for Real-Time Diaphragmatic Excursion Measurement. *J Med Biol Eng* 2018;38:678-84.
2. Santana PV, Cardenas LZ, Albuquerque ALP, Carvalho CRR, Caruso P. Diaphragmatic ultrasound: a review of its methodological aspects and clinical uses. *J Bras Pneumol* 2020;46:e20200064.
3. Romero-Morales C, Bravo-Aguilar M, Ruiz-Ruiz B, Almazán-Polo J, López-López D, Blanco-Morales M, Téllez-González P, Calvo-Lobo C. Current advances and research in ultrasound imaging to the assessment and management of musculoskeletal disorders. *Dis Mon* 2021;67:101050.
4. Marugán-Rubio D, Chicharro JL, Becerro-de-Bengoa-Vallejo R, Losa-Iglesias ME, Rodríguez-Sanz D, Vicente-Campos D, Dávila-Sánchez GJ, Calvo-Lobo C. Concurrent Validity and Reliability of Manual Versus Specific Device Transcostal Measurements for Breathing Diaphragm Thickness by Ultrasonography in Lumbopelvic Pain Athletes. *Sensors (Basel)* 2021;21:4329.
5. Boussuges A, Finance J, Chaumet G, Brégeon F. Diaphragmatic motion recorded by M-mode ultrasonography: limits of normality. *ERJ Open Res* 2021;7:e00714-2020.
6. Sæverud HA, Falk RS, Dowrick A, Eriksen M, Aarrestad S, Skjongsberg OH. Measuring diaphragm movement and respiratory frequency using a novel ultrasound device in healthy volunteers. *J Ultrasound* 2021;24:15-22.
7. Scarlata S, Mancini D, Laudisio A, Benigni A, Antonelli Incalzi R. Reproducibility and Clinical Correlates of Supine Diaphragmatic Motion Measured by M-Mode Ultrasonography in Healthy Volunteers. *Respiration* 2018;96:259-66.

8. Khurana J, Gartner SC, Naik L, Tsui BCH. Ultrasound Identification of Diaphragm by Novices Using ABCDE Technique. *Reg Anesth Pain Med* 2018;43:161-5.
9. Wijntjes J, van Alfen N. Muscle ultrasound: Present state and future opportunities. *Muscle Nerve* 2021;63:455-66.
10. Cardenas LZ, Santana PV, Caruso P, Ribeiro de Carvalho CR, Pereira de Albuquerque AL. Diaphragmatic Ultrasound Correlates with Inspiratory Muscle Strength and Pulmonary Function in Healthy Subjects. *Ultrasound Med Biol* 2018;44:786-93.
11. Cappellini I, Picciafuochi F, Bartolucci M, Matteini S, Virgili G, Adembri C. Evaluation of diaphragm thickening by diaphragm ultrasonography: a reproducibility and a repeatability study. *J Ultrasound* 2021;24:411-6.
12. Whittaker JL, Ellis R, Hodges PW, OSullivan C, Hides J, Fernandez-Carnero S, Arias-Buria JL, Teyhen DS, Stokes MJ. Imaging with ultrasound in physical therapy: What is the PT's scope of practice? A competency-based educational model and training recommendations. *Br J Sports Med* 2019;53:1447-53.
13. Poulard T, Bachasson D, Fossé Q, Niérat MC, Hogrel JY, Demoule A, Gennisson JL, Dres M. Poor Correlation between Diaphragm Thickening Fraction and Transdiaphragmatic Pressure in Mechanically Ventilated Patients and Healthy Subjects. *Anesthesiology* 2022;136:162-75.
14. Le Neindre A, Philippart F, Luperto M, Wormser J, Morel-Sapene J, Aho SL, Mongodi S, Mojoli F, Bouhemad B. Diagnostic accuracy of diaphragm ultrasound to predict weaning outcome: A systematic review and meta-analysis. *Int J Nurs Stud* 2021;117:103890.
15. Skaarup SH, Løkke A, Laursen CB. The Area method: a new method for ultrasound assessment of diaphragmatic movement. *Crit Ultrasound J* 2018;10:15.
16. Spiesshoefer J, Herkenrath S, Henke C, Langenbruch L, Schneppe M, Randerath W, Young P, Brix T, Boentert M. Evaluation of Respiratory Muscle Strength and Diaphragm Ultrasound: Normative Values, Theoretical Considerations, and Practical Recommendations. *Respiration* 2020;99:369-81.
17. Scarlata S, Mancini D, Laudisio A, Raffaele AI. Reproducibility of diaphragmatic thickness measured by M-mode ultrasonography in healthy volunteers. *Respir Physiol Neurobiol* 2019;260:58-62.
18. Holtzhausen S, Unger M, Lupton-Smith A, Hanekom S. An investigation into the use of ultrasound as a surrogate measure of diaphragm function. *Heart Lung* 2018;47:418-24.
19. Marugán-Rubio D, Chicharro JL, Becerro-de-Bengoa-Vallejo R, Losa-Iglesias ME, Rodríguez-Sanz D, Vicente-Campos D, Molina-Hernández N, Calvo-Lobo C. Effectiveness of Ultrasonography Visual Biofeedback of the Diaphragm in Conjunction with Inspiratory Muscle Training on Muscle Thickness, Respiratory Pressures, Pain, Disability, Quality of Life and Pulmonary Function in Athletes with Non-Specific Low Back Pain: A Randomized Clinical Trial. *J Clin Med* 2022;11:4318.
20. Bellemare F, Bigland-Ritchie B, Woods JJ. Contractile properties of the human diaphragm in vivo. *J Appl Physiol* (1985) 1986;61:1153-61.
21. Kottner J, Audige L, Brorson S, Donner A, Gajewski BJ, Hróbjartsson A, Roberts C, Shoukri M, Streiner DL. Guidelines for Reporting Reliability and Agreement Studies (GRRAS) were proposed. *Int J Nurs Stud* 2011;48:661-71.
22. Holt GR. Declaration of Helsinki-the world's document of conscience and responsibility. *South Med J* 2014;107:407.
23. Schneider CA, Rasband WS, Eliceiri KW. NIH Image to ImageJ: 25 years of image analysis. *Nat Methods* 2012;9:671-5.
24. Gauthier AP, Lariviere M, Young N. Psychometric properties of the IPAQ: a validation study in a sample of northern Franco-Ontarians. *J Phys Act Health* 2009;6 Suppl 1:S54-60.
25. Lobo CC, Morales CR, Sanz DR, Corbalán IS, Marín AG, López DL. Ultrasonography Comparison of Peroneus Muscle Cross-sectional Area in Subjects With or Without Lateral Ankle Sprains. *J Manipulative Physiol Ther* 2016;39:635-44.
26. Chang PH, Chen YJ, Chang KV, Wu WT, Özçakar L. Ultrasound measurements of superficial and deep masticatory muscles in various postures: reliability and influencers. *Sci Rep* 2020;10:14357.
27. Calvo-Lobo C, Almazán-Polo J, Becerro-de-Bengoa-Vallejo R, Losa-Iglesias ME, Palomo-López P, Rodríguez-Sanz D, López-López D. Ultrasonography comparison of diaphragm thickness and excursion between athletes with and without lumbopelvic pain. *Phys Ther Sport* 2019;37:128-37.
28. Boussuges A, Rives S, Finance J, Chaumet G, Vallée N, Risso JJ, Brégeon F. Ultrasound Assessment of Diaphragm

Thickness and Thickening: Reference Values and Limits of Normality When in a Seated Position. *Front Med (Lausanne)* 2021;8:742703.  
29. Hellyer NJ, Andreas NM, Bernstetter AS, Cieslak

KR, Donahue GF, Steiner EA, Hollman JH, Boon AJ. Comparison of Diaphragm Thickness Measurements Among Postures Via Ultrasound Imaging. *PM R* 2017;9:21-5.

**Cite this article as:** Molina-Hernández N, Chicharro JL, Becerro-de-Bengoa-Vallejo R, Losa-Iglesias ME, Rodríguez-Sanz D, Vicente-Campos D, Marugán-Rubio D, Gutiérrez-Torre SE, Calvo-Lobo C. Ultrasonographic reliability and repeatability of simultaneous bilateral assessment of diaphragm muscle thickness during normal breathing. *Quant Imaging Med Surg* 2023;13(10):6656-6667. doi: 10.21037/qims-23-329