

Early Active Motion versus Immobilization after Tendon Transfer for Foot Drop Deformity

A Randomized Clinical Trial

Santosh Rath MS, Ton A. R. Schreuders PT, PhD,
Henk J. Stam MD, PhD, Steven E. R. Hovius PhD, MD,
Ruud W. Selles PhD

Received: 23 August 2009 / Accepted: 25 March 2010 / Published online: 17 April 2010
© The Author(s) 2010. This article is published with open access at Springerlink.com

Abstract

Background Immobilization after tendon transfers has been the conventional postoperative management. Several recent studies suggest early mobilization does not increase tendon pullout.

Questions/purposes To confirm those studies we determined whether when compared with immobilization early active mobilization after a tendon transfer for foot-drop correction would (1) have a similar low rate of tendon insertion pullout, (2) reduce rehabilitation time, and (3) result in similar functional outcomes (active

ankle dorsiflexion, plantar flexion, ROM, walking ability, Stanmore score, and resolution of functional problems.

Methods We randomized 24 patients with surgically corrected foot-drop deformities to postoperative treatment with early mobilization with active motion at 5 days ($n = 13$) or 4 weeks of immobilization with active motion at 29 days ($n = 11$). In both groups, the tibialis posterior tendon was transferred to the extensor hallucis longus and extensors digitorum communis for foot-drop correction. Rehabilitation time was defined as the time from surgery until discharge from rehabilitation with independent walking. The minimum followup was 16 months (mean, 19 months; range, 16–38 months) in both groups.

Results We observed no case of tendon pullout in either group. Rehabilitation time in the mobilized group was reduced by an average of 15 days. The various functional outcomes were similar in the two groups.

Conclusion In patients with Hansen's disease, an early active mobilization protocol for foot-drop correction has no added risk of tendon pullout and provides similar functional outcomes compared with immobilization. Early mobilization had the advantage of earlier restoration of independent walking.

Level of Evidence Level I, therapeutic study. See Guidelines for Authors for a complete description of levels of evidence.

Each author certifies that he or she has no commercial associations (eg, consultancies, stock ownership, equity interest, patent/licensing arrangements, etc) that might pose a conflict of interest in connection with the submitted article.

Each author certifies that his or her institution approved the human protocol for this investigation, that all investigations were conducted in conformity with ethical principles of research, and that informed consent for participation in the study was obtained.

The investigation was performed at the LEPRF Funded Leprosy Reconstructive Surgery Unit, HOINA, Muniguda, and Orissa, India.

S. Rath
LEPRF Funded Leprosy Reconstructive Surgery Unit, HOINA,
Muniguda, Orissa, India

S. Rath (✉)
Department of Orthopaedics, Hi-Tech Medical College &
Hospital Pandara, F 35/A BJB Nagar, Bhubaneswar 751 014,
Orissa, India
e-mail: handsurgery.rath@gmail.com

S. Rath, S. E. R. Hovius, R. W. Selles
Department of Plastic and Reconstructive Surgery, Erasmus MC
Rotterdam, Rotterdam, The Netherlands

S. Rath, T. A. R. Schreuders, H. J. Stam, R. W. Selles
Department of Rehabilitation Medicine, Erasmus MC
Rotterdam, Rotterdam, The Netherlands

Introduction

Although an ankle foot orthosis (AFO) may be the preferred option to treat foot-drop deformity in patients with peripheral nerve injuries or an intervertebral disc prolapse as this intervention is noninvasive and inexpensive, it has limited use for foot-drop in patients with Hansen's disease

as the majority of these patients in endemic countries are manual or agricultural workers accustomed to walking barefoot. In addition, for those using footwear, social and religious practices require them to remove these for entering places of worship and homes. Therefore, anterior transfer of the tibialis posterior tendon often is used for foot-drop correction as this allows walking without wearing an orthosis and removes part of the social stigma associated with deformities from Hansen's disease but often is rejected by the patients owing to the long rehabilitation time.

Immobilization is the conventional postoperative management after tendon transfers to the feet. The period of immobilization for foot-drop correction with a tibialis posterior tendon transfer is 4 weeks [10, 11, 13–15, 17, 18] and is followed by a rehabilitation period of another 4 to 6 weeks [11, 14].

Recent studies suggested there is no added risk of tendon insertion pullout with immediate postoperative active mobilization after tendon transfers to the hand for opposition [6] and claw-deformity correction [7, 9] in patients with Hansen's disease. In these studies, early mobilization after tendon transfers of the hand restored function earlier and reduced morbidity while similar functional outcomes were observed at followup. An earlier small prospective cohort study of early active mobilization after tibialis posterior transfer for foot-drop correction showed no incidence of tendon insertion pullout, reduced rehabilitation time, low complication rate, and earlier independent walking compared with results of an historical cohort of patients who received immobilization [8]. However, these cohorts were not controlled in a randomized clinical design and outcome assessment was limited by inadequate data for the historical cohort.

We therefore asked whether early active mobilization after tibialis posterior transfer for foot-drop compared with immobilization would (1) have a similarly low rate of tendon insertion pullout, (2) reduce rehabilitation time, and (3) result in similar functional outcomes in terms of active ankle dorsiflexion (ADF), plantar flexion (APF), active total ankle ROM, strength of dorsiflexion, walking performance, Stanmore score [19], and resolution of functional problems.

Patients and Methods

We designed a randomized control trial to assess early mobilization versus postoperative immobilization in patients with Hansen's disease having a tendon transfer for foot-drop correction. From July 2005 until June 2006 we performed a tendon transfer in 39 patients with Hansen's disease with irreversible common peroneal nerve paralysis

of greater than a year in duration. The diagnosis and treatment of the disease occurred at the field level by trained medical staff of the National Leprosy Eradication Programme. The neurologic deficit was documented by the physiotherapist using the manual muscle strength test (MMST) grading [2]. All patients had completed multidrug therapy for Hansen's disease and the muscle strength of the ankle dorsiflexors was MMST Grade 0. We excluded nine patients with clawed toes having additional surgery, active neuropathic plantar ulcers, absorption of toes, and Charcot's arthropathy of the feet and ankles (Fig. 1). Six patients were not able to return for repeat followups and therefore were excluded (Fig. 1). These exclusions left 24 patients for the RCT; these patients were randomized postoperatively into one of two groups: those receiving early mobilization (mobilized group) or those receiving 4 weeks of immobilization (immobilized group). Randomization was performed using unmarked sealed opaque envelopes that were mixed in a box. A person not involved in the trial assigned the patients to the groups by opening an envelope picked at random from the box after completion of surgery and wound closure to avoid any influence of group allocation on surgical procedures. Thirteen patients were allocated to the mobilized group and 11 to the immobilized group. The patients in both groups were similar in age, gender, side of involvement, and duration of paralysis (Table 1). For a power analysis, we used data for rehabilitation time from a previous prospective cohort study [8] of patients using early active mobilization (rehabilitation time, 44 ± 8 days) and an historical cohort of patients who received immobilization (rehabilitation time, 57 ± 8 days). We calculated that with a 10-day difference in rehabilitation time between groups and a group size of 10 patients we would have a power of 97%.

The tibialis anterior, extensor hallucis longus, extensor digitorum longus, and extensor digitorum brevis were Grade 0 in all 24 patients (Table 2). Five patients in each group had incomplete common peroneal paralysis of Grade III or greater in the peroneus longus and peroneus brevis muscles. The tibialis posterior, the flexor hallucis longus, and flexor digitorum longus were Grade V in all patients. Twenty-three of the 24 patients were available beyond 1 year for followup (Fig. 1). The minimum followups at final assessment were 16 months (mean, 19 months; range, 16–38 months) for the mobilized group and 16 months (mean, 19 months; range, 16–38 months) for the immobilized group (Table 1). One patient had no followup after discharge from rehabilitation therapy and could not be located owing to geographic relocation. Approval was obtained from the institutional review board and informed consent was signed by all patients.

A tibialis posterior tendon transfer for foot-drop correction was performed by the circumtibial route for all

Fig. 1 A CONSORT flow diagram illustrates the design of the RCT comparing early mobilization versus immobilization after tendon transfer for foot-drop.

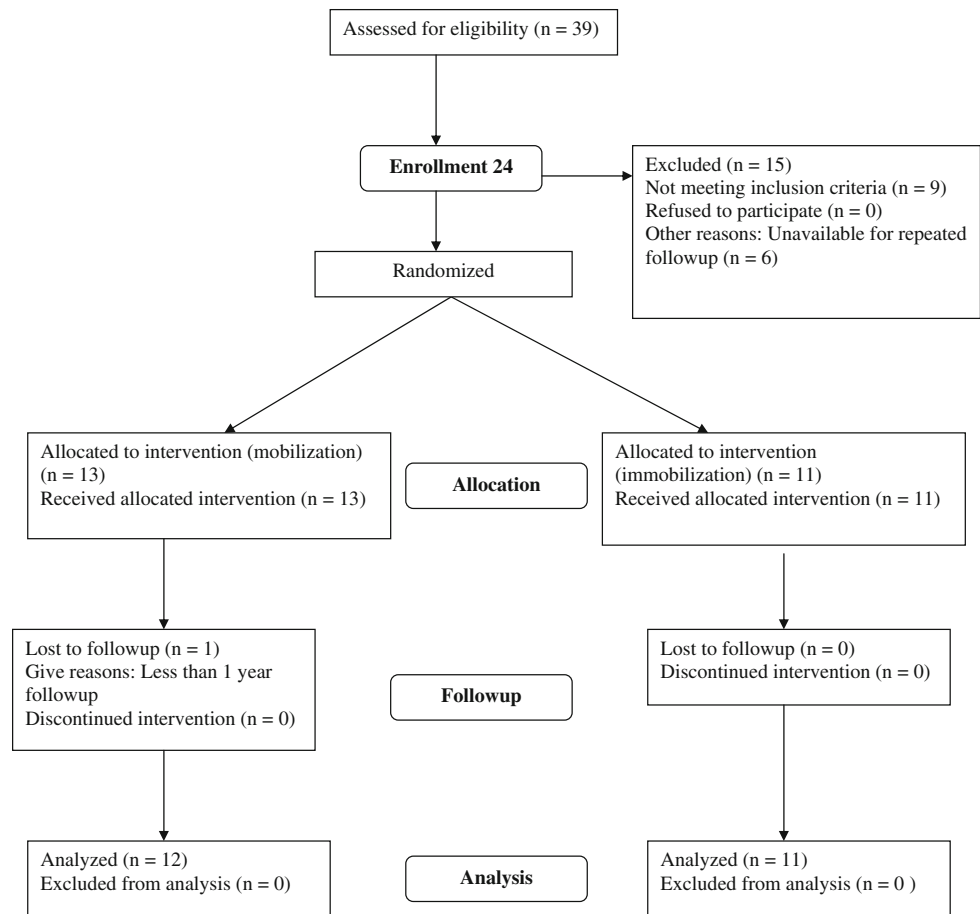


Table 1. Comparison of baseline data of patients in the two groups

Variables	Mobilized group	Immobilized group	p Value
Age (years)*	29 ± 12	32 ± 10	0.524
Gender (male:female)	12:1	10:1	
Duration of paralysis (months)*	41 ± 3	40 ± 3	0.959
Duration of followup (months)*	19 ± 6 (range 16–38)	19 ± 5 (range 16–38)	0.960

* Values are expressed as mean ± SD.

patients [14]. Patients were operated on under sedation using wide local infiltration of 1% lidocaine with 1:10000 adrenaline and without the use of a tourniquet. Percutaneous lengthening of the Achilles tendon always was performed before the tendon transfer because passive ankle dorsiflexion was less than 20° in all patients. The surgical technique is similar to that described by Srinivasan et al. [14]. The tibialis posterior tendon was detached from its insertion to the navicular bone, retrieved in the lower leg, and split to the musculotendinous junction into two slips. Each slip then was transferred to the foot separately along the circumtibial route passing anterior to the ankle and superficial to the extensor retinaculum. One slip was inserted into the tendons of the extensor digitorum longus

with maximum tension and the second slip was inserted into the extensor hallucis longus tendon in neutral tension. The transfer was inserted using a Pulvertaft's weave [5] and the points of entry and exit were sutured using 2-0 Ethibond® (Ethicon, Inc, Somerville, NJ). During suturing of the transferred tendon slips, the limb was put in a pre-fabricated splint that maintained the knee in 60° flexion and the ankle in 20° dorsiflexion to ensure standardization of tendon transfer tension.

After completion of surgery the ankles were immobilized in 20° dorsiflexion in both groups with a below-knee posterior splint for the mobilized group and a below-knee cast with a walking heel for the immobilized group. For the mobilized group the below-knee posterior splint was

Table 2. Preoperative Manual Muscle Strength Test results

Patient number	Group	TA	EHL	EDL	EDB	PL	PB	TP	GS	FHL	FDL
1	m	0	0	0	0	0	0	5	5	5	5
2	m	0	0	0	0	0	0	5	5	5	5
3	m	0	0	0	0	3	3	5	5	5	5
4	m	0	0	0	0	0	0	5	5	5	5
5	m	0	0	0	0	0	0	5	5	5	5
6	m	0	0	0	0	1	1	5	5	5	5
7	m	0	0	0	0	0	0	5	5	5	5
8	m	0	0	0	0	5	5	5	5	5	5
9	m	0	0	0	0	5	5	5	5	5	5
10	m	0	0	0	0	5	5	5	5	5	5
11	m	0	0	0	0	5	5	5	5	5	5
12	m	0	0	0	0	0	0	5	5	5	5
13	m	0	0	0	0	1	1	5	5	5	5
14	i	0	0	0	0	0	0	5	5	5	5
15	i	0	0	0	0	0	0	5	5	5	5
16	i	0	0	0	0	0	0	5	5	5	5
17	i	0	0	0	0	0	0	5	5	5	5
18	i	0	0	0	0	0	0	5	5	5	5
19	i	0	0	0	0	0	0	5	5	5	5
20	i	0	0	0	0	5	5	5	5	5	5
21	i	0	0	0	0	5	5	5	5	5	5
22	i	0	0	0	0	5	5	5	5	5	5
23	i	0	0	0	0	5	5	5	5	5	5
24	i	0	0	0	0	5	5	5	5	5	5

TA = tibialis anterior; EHL = extensor hallucis longus; EDL = extensor digitorum longus; EDB = extensor digitorum brevis; PL = peroneus longus; PB = peroneus brevis; TP = tibialis posterior; GS = gastrosoleus; FHL = flexor hallucis longus; FDL = flexor digitorum longus; i = immobilized group; m = mobilized group.

removed on postoperative Day 5 for therapy. For the immobilized group the cast was removed on the 29th postoperative day for therapy with the foot supported by a splint between therapy sessions.

Patients in both groups were allowed nonweightbearing crutch-walking from postoperative Day 2. Patients in the immobilized group were allowed partial weightbearing when pain subsided. Owing to logistic reasons, all patients were housed in an unsupervised residential area at the institution during the rehabilitation period. Rehabilitation was supervised by a therapist not involved in the selection of patients for the trial. Blinding of the therapist to group allocation was not possible as patients in the immobilized group required removal of the cast on the first day of therapy. A therapist (NP), not involved with care of the patients and therefore blinded to group assignment, discharged the patients and performed the followups beyond 1 year.

The rehabilitation protocol was similar in both groups except that active mobilization started on postoperative Day 5 for the mobilized group and at the beginning of

postoperative Week 5 for the immobilized group. As a result, the therapy protocol during postoperative Weeks 2 to 5 for the mobilized group corresponded to the protocol for postoperative Weeks 5 to 8 for the immobilized group. The therapy program consisted of 10 repetitions of active dorsiflexion exercises once a day during the first week of therapy (postoperative Week 2 for the mobilized group, postoperative Week 5 for the immobilized group), 25 repetitions of active dorsiflexion and plantar flexion exercises during the second week of therapy (postoperative Week 3 for the mobilized group, postoperative Week 6 for the immobilized group), partial weightbearing using parallel bars during the third week of therapy (postoperative Week 4 for the mobilized group, postoperative Week 7 for the immobilized group), and full weightbearing and gait training during the fourth week of therapy (postoperative Week 5 for the mobilized group, postoperative Week 8 for the immobilized group). The limb was supported after therapy in a posterior splint at 20° dorsiflexion for 3 weeks and thereafter only at night for 3 months. Patients in both groups were discharged from rehabilitation when they had

achieved MMST Grade IV of the transferred muscle and independent walking without any aids. Unrestricted activities of daily living were allowed 3 months after discharge from rehabilitation.

The main risk of early mobilization is tendon transfer rupture or insertion pullout. Therefore, we evaluated the presence of transfer pullout by monitoring active dorsiflexion, position of the foot at rest, and active ankle ROM on a daily basis for the first 2 weeks of therapy and then at the end of each week. A sudden or progressive reduction of dorsiflexion and ROM would indicate rupture or impending insertion pullout. The measurements were performed using a hand-held goniometer with the patient in a sitting position with the knee in 90° flexion.

Clinical review was recommended once a month for 3 months, then every 3 months for 1 year, and then once a year. At each visit the functional outcome measurements were (1) ADF angle, (2) APF angle, and (3) active ankle ROM between plantar flexion and dorsiflexion. Rehabilitation time was defined as the time from surgery until discharge from rehabilitation with independent walking. Additionally, at the last followup, the strength of active dorsiflexion was measured with the MMST (0-5) score [2], and the 6-minute walking test [3] was performed to determine functional walking performance (NP). The surgical outcomes were graded using the Stanmore system [19], which is a 100-point scale with seven scoring categories.

A patient-specific index of what the patients rate as the most important problem attributable to impairment from foot-drop was determined based on the study methodology of McCormick et al. for ulnar nerve paralysis [4]. These problems were difficulty with walking (76%), running (61%), climbing stairs (61%), scraping the toes during the swing phase of gait (61%), and riding a bicycle (30%). All patients were conscious of their awkward gait and cosmesis. Impact of the index intervention on these functional problems was scored by the patient as complete or partial resolution or no change at last followup.

Data obtained at discharge and last followup were compared for both groups using the nonparametric Mann-Whitney U test. We determined differences in tendon insertion pullout, rehabilitation time, and functional outcomes (active ankle dorsiflexion, plantar flexion, ROM, strength of dorsiflexion, walking ability, Stanmore score, and resolution of functional problems) between the mobilized and the immobilized groups. All data were analyzed with SPSS® 16.0.1 statistical software (SPSS Inc, Chicago, IL).

Results

We observed no insertion pullout of the transferred tendon in any of the patients in either group. Rehabilitation time

was 43 ± 5 days for the mobilized group and 59 ± 2 days for the immobilized group. Patients in the mobilized group were discharged from rehabilitation, on average, 15 days earlier ($p < 0.001$) than patients in the immobilized group.

We found no differences between the groups in ADF, APF, and total ankle ROM angles at discharge and at last followup (Table 3). The strength of dorsiflexion was similar in both groups at last followup. Dorsiflexion was MMST Grade V in 10 patients and Grade IV and Grade III in one patient each in the mobilized group. In the immobilized group there were 10 patients with MMST Grade V and one with Grade IV. The 6-minute walking distance was similar in both groups at last followup. At last followup 12 patients in the mobilized group had Stanmore scores between 96 and 98 (average score, 97), and one patient had a score of 69 (Table 4). All 12 patients in the immobilized group had scores ranging from 93 to 98 (average score, 97) (Table 4). The common functional problems of walking, climbing stairs, scraping the toes during the swing phase of gait, and riding a bicycle were resolved by tibialis posterior tendon transfer in both groups. All patients in both groups had improved gait and cosmesis.

Table 3. Comparison of outcomes at discharge and last followup

Test	Group	Mean	p Value (Mann Whitney U)
ADF D	m (n = 13)	18.5	0.69
	i (n = 11)	18.9	
ADF L	m (n = 12)	17.7	0.26
	i (n = 11)	20.8	
APF D	m (n = 13)	-7	0.95
	i (n = 11)	-7	
APF L	m (n = 12)	5.1	0.45
	i (n = 11)	2.1	
TAM D	m (n = 13)	12.0	0.91
	i (n = 11)	12.0	
TAM L	m (n = 12)	22.8	0.52
	i (n = 11)	22.9	
MMST grade	m (n = 12)		0.56
	i (n = 11)		
Six-minute walking	m (n = 11)		0.28
	i (n = 10)		

m = mobilization group; i = immobilization group; ADF D = active dorsiflexion angle at discharge; ADF L = active dorsiflexion at last followup; APF D = active plantar flexion at discharge (negative sign (-) when active ankle plantar flexion does not reach neutral or zero position and the angles are recorded in the dorsiflexion range); APF L = active plantar flexion at last followup; TAM D = total active motion at discharge; TAM L = total active motion at last followup; MMST = Manual Muscle Strength Test.

Table 4. Results of tibialis posterior tendon transfer using the Stanmore system [19]

Parameter	Score	Mobilized group (1–12)											Immobilized group (13–23)										
		1	2	3	4	5	6	7	8	9	10	11	12	13	14	15	16	17	18	19	20	21	22
Pain (15 points)		15	15	15	15	15	15	15	15	15	15	15	15	15	15	15	15	15	15	15	15	15	15
No pain at any time or not worse	15																						
Mild pain or slightly worse	10																						
Moderate pain or moderately worse	5																						
Severe pain or marked worse	0																						
Need for orthosis (15 points)		15	15	15	15	15	15	15	15	15	15	15	15	15	15	15	15	15	15	15	15	15	15
No	15																						
Occasional (once a week)	10																						
Frequently (twice a week)	5																						
Regularly (greater than twice a week)	0																						
Normal shoes (5 points)		3	3	3	3	3	3	3	3	3	3	3	3	3	3	3	3	3	3	3	3	3	3
Yes	5																						
Yes, but prefers certain types	3																						
No	0																						
Functional outcome (10 points)		10	10	10	10	10	3	10	10	10	10	10	10	10	10	10	10	10	10	10	10	10	10
Normal daily activity and normal recreation	10																						
Normal daily activity and limited recreation	6																						
Limited daily activity and recreation	3																						
Severe limitation on daily activity and recreation	0																						
Muscle power (modified MRC grading) (25 points)		25	25	25	25	20	10	25	25	25	25	25	25	25	25	25	25	25	20	10	25	25	25
Grade 4 + or 5	25																						
Grade 4	20																						
Grade 3	10																						
Grade 2 or less	0																						
Degree of active dorsiflexion (degrees) (25 points)		25	25	25	25	20	25	25	25	25	25	25	25	25	25	25	25	25	20	10	25	25	25
Greater than 6	25																						
0–5	20																						
–5 to –1	10																						
–10 to –6	5																						
less than –11	0																						
Foot posture (5 points)		5	5	3	5	5	3	5	5	5	5	5	5	3	5	5	5	5	5	5	5	5	5
Plantigrade, balanced, no deformity	5																						
Plantigrade, mild deformity	3																						
Obvious deformity or misalignment	0																						
Total	100	98	98	96	98	93	69	98	98	98	98	98	98	96	98	98	96	98	93	69	98	98	98

MRC = medical research council.

Discussion

Immobilization after tendon transfers typically has been used for postoperative treatment for varying periods of time. However, several recent studies suggest early mobilization does not increase tendon pullout. To confirm these studies, we therefore determined whether early active mobilization of tendon transfer for foot-drop would increase tendon insertion pullout, reduce rehabilitation

time, and have similar functional outcomes (active ankle dorsiflexion, plantar flexion, ROM, walking ability, Stanmore score, and resolution of functional problems) compared with immobilization.

There are numerous limitations to our study. First, the number of patients enrolled in the trial was relatively small. A power analysis indicated that a group of 10 patients would be sufficient to determine whether there was reduced rehabilitation time. We did not anticipate important

differences in functional outcome between both groups and although we found none, the group size would not be sufficient to detect small differences in functional outcome. Second, we did not assess direct or indirect cost reductions associated with earlier discharge of patients in the mobilized group. Our patients remained in the institution during their rehabilitation and this increased the cost of treatment compared with those receiving rehabilitation therapy on an outpatient basis. This added cost can be avoided as postoperative therapy can be initiated on an outpatient basis if facilities are available locally. Third, we did not measure whether patients returned to productive employment quicker with early mobilization. All patients in both groups reportedly returned to their previous activities 3 months after discharge from rehabilitation. As patients in the mobilized group were discharged an average 15 days earlier, we presumed return to work would be quicker in the mobilized group, although we did not objectively quantify this in the study. Fourth, we used no validated system of scoring change in functional problems and subjective satisfaction after tendon transfer. Improvement in running was not assessed properly as patients were advised to avoid running for fear of stretching the transfer.

We identified no patient with tendon insertion pullout during early active mobilization of the foot-drop tendon transfer. This finding is similar to that of a previous report regarding early active mobilization in the same patient group [8], and also in line with studies of early active mobilization of tendon transfer to the hand [6, 7, 9]. Our observation is also consistent with that made by Silfverskiold and May [12] on early active mobilization after tendon transfers to the hand using mesh-reinforced suture techniques. They also reported no insertion pullout. Similarly, Germann et al. [1], in a study of dynamic splint-assisted mobilization of extensor indicis transfer for thumb extension, reported no patient transfer insertion pullout. Together, these studies suggest the risk of tendon insertion pullout is negligible with early mobilization of these tendon transfers.

In this randomized controlled trial, patients in the early mobilization group had a 15-day shorter rehabilitation time compared with the immobilization group. This finding is similar to that in our study comparing a prospective cohort with historical data in which we found a 13-day reduction in rehabilitation time [8]. The reduction in rehabilitation time after early mobilization for foot-drop correction in the current study is less than the 22 days reduction achieved for early mobilization for claw-deformity correction of the hand [9]. However, patients who had tendon transfers for the hands were mobilized on the 2nd postoperative day [7, 9], whereas in the current study, patients were not mobilized before the 5th postoperative day. Additional studies are needed to investigate if mobilization for foot tendon

transfers can be started earlier than the 5th postoperative day to further reduce rehabilitation time.

The functional outcome of patients who had early mobilization after foot-drop tendon transfers was similar to the outcome for patients in the immobilization group in this study. Thus, although we had expected a small functional benefit with early mobilization because of less disuse atrophy, this was not observed. The finding of a similar functional outcome is in line with the findings of previous reports on foot-drop correction [8] and early mobilization of tendon transfers to the hand [1, 6, 7, 9, 12]. These studies showed that the benefits of early mobilization after tendon transfer are limited to reduced rehabilitation time but have no additional advantage over immobilization in terms of functional recovery. It is possible that the group size was too small to show subtle differences and this warrants additional studies with larger numbers of patients. The Stanmore scores for patients in this study [Table 4] were comparable to scores for patients having foot-drop correction by combined anterior transfer of the tibialis posterior and flexor hallucis longus [15] and by insertion of the tibialis tendon proximal to the ankle [16].

The faster discharge from rehabilitation may affect the cost of tendon transfer surgery for foot-drop correction. For example, Germann et al. [1] reported that hand function recovers faster in patients receiving extensor indicis proprius transfer for thumb extension after early dynamic motion than after immobilization, making early dynamic motion treatment for tendon transfer highly cost-effective. The total costs for tendon transfer surgery include the institutional charges for the operation (infrastructure, consumables), personnel costs for surgeons, therapists, and other staff, and work-loss compensation [1]. Future trials should determine a possible cost reduction with early mobilization of tendon transfer compared with the current practice of immobilization.

For future studies, several aspects of the surgical technique could be considered before further application of early mobilization to other foot tendon transfers. The prerequisite of a strong insertion may limit the choice of the tendon donor and the site of insertion. The transfer insertion site for tendon-to-tendon attachment should be of sizable dimension for a Pulvertaft weave [5]. Additional studies are needed to determine if tendon transfer insertion to bone can be a solution in situations in which the Pulvertaft weave is not possible owing to tendon size mismatch. Also, the technical feasibility of early mobilization after tibialis posterior tendon transfer to bone insertion to restore ankle dorsiflexion needs to be investigated. Tendon-to-bone insertion was not attempted in our trial owing to the concern for neuropathic tarsal disintegration in patients with Hansen's disease [14, 18].

We found early active mobilization of tendon transfer adds no risk of insertion pullout. Earlier restoration of independent walking with early mobilization compared with immobilization is a substantial advantage with the potential of a reduction of total costs and loss of work for patients. The large effects in reduction of rehabilitation time after early mobilization in this and in previous studies [1, 6, 7, 9, 12] on tendon transfers of the hand warrant additional clinical trials to expand application of early mobilization to other tendon transfers of the foot.

Acknowledgments We acknowledge the contribution of physiotherapists at the LEPRa Funded Reconstructive Surgery Unit, HOINA, Muniguda, in performing this research; Nagesh Patro (NP), Research Therapist for postoperative assessments; the LEPRa Society for funding treatment of patients included in this study; the director of HOINA for permission to perform the research; and the late Frederick Finseth, MD, FACS, for his contribution to the development of the concept of early mobilization after tendon transfers and guidance for this research.

Open Access This article is distributed under the terms of the Creative Commons Attribution Noncommercial License which permits any noncommercial use, distribution, and reproduction in any medium, provided the original author(s) and source are credited.

References

- Germann G, Wagner H, Blome-Eberwein S, Karle B, Wittemann M. Early dynamic motion versus postoperative immobilization in patients with extensor indicis proprius transfer to restore thumb extension: a prospective randomized study. *J Hand Surg Am.* 2001;26:1111–1115.
- Kendall FP, McCreary EK, Provance PG. *Muscles: Testing and Function.* Ed 4. Baltimore, MD: Williams & Wilkins; 1993.
- Kennedy DM, Stratford PW, Riddle DL, Hanna SE, Gollish JD. Assessing recovery and establishing prognosis following total knee arthroplasty. *Phys Ther.* 2008;88:22–32.
- McCormick CA, Rath S, Patra PN, Pereira J, Wilkinson M. A qualitative study of common functional problems experienced by people with complete ulnar nerve paralysis. *Lepr Rev.* 2008;79:154–161.
- Pulvertaft RG. Tendon grafts for flexor tendon injuries in the fingers and thumb: a study of technique and results. *J Bone Joint Surg Br.* 1956;38:175–194.
- Rath S. Immediate active mobilization versus immobilization for opposition tendon transfer in the hand. *J Hand Surg Am.* 2006;31:754–759.
- Rath S. Immediate postoperative active mobilization versus immobilization following tendon transfer for claw deformity correction in the hand. *J Hand Surg Am.* 2008;33:232–240.
- Rath S, Schreuders TA, Selles RW. Early postoperative active mobilisation versus immobilisation following tibialis posterior tendon transfer for foot-drop correction in patients with Hansen's disease. *J Plast Reconstr Aesthet Surg.* 2010;63:554–560.
- Rath S, Schreuders TA, Selles RW, Stam HJ, Hovius SE. A randomized clinical trial comparing immediate active motion with immobilization after tendon transfer for claw deformity. *J Hand Surg Am.* 2009;34:488–494.
- Richard BM. Interosseous transfer of tibialis posterior for common peroneal nerve palsy. *J Bone Joint Surg Br.* 1989;71:834–837.
- Schwarz R, Brandsma W. *Surgical Reconstruction and Rehabilitation in Leprosy and Other Neuropathies.* Kathmandu, Nepal: Ekta Books; 2004.
- Silfverskiold KL, May EJ. Early active mobilization after tendon transfers using mesh reinforced suture techniques. *J Hand Surg Br.* 1995;20:291–300.
- Soares D. Tibialis posterior transfer for the correction of foot drop in leprosy: long-term outcome. *J Bone Joint Surg Br.* 1996;78:61–62.
- Srinivasan H, Mukherjee SM, Subramaniam RA. Two-tailed transfer of tibialis posterior for correction of drop-foot in leprosy. *J Bone Joint Surg Br.* 1968;50:623–628.
- Vigasio A, Marcoccio I, Patelli A, Mattiuzzo V, Prestini G. New tendon transfer for correction of foot deformity in common peroneal nerve palsy. *Clin Orthop Relat Res.* 2008;466:1454–1466.
- Wagenaar FC, Louwerens JW. Posterior tibial tendon transfer: results of fixation to the dorsiflexors proximal to the ankle joint. *Foot Ankle Int.* 2007;28:1128–1142.
- Warren AG. The correction of foot drop in leprosy. *J Bone Joint Surg Br.* 1968;50:629–634.
- Warren AG, Nade S. *The Care of Neuropathic Limbs: A Practical Manual.* Carnforth, UK: Parthenon Publishing Group; 1999.
- Yeap JS, Singh D, Birch R. A method for evaluating the results of tendon transfers for foot drop. *Clin Orthop Relat Res.* 2001;383:208–213.