

Nuclear Protein in Testis Midline Carcinoma Presenting in an Infant as a Pericardial Mass with Staging by ^{18}F -Fluorodeoxyglucose-positron Emission Tomography/Computed Tomography

Crystal Perkins, Darko Pucar¹, Colleen H. McDonough², Hadyn T. Williams¹

Medical Student, Augusta University/University of Georgia Medical Partnership, Augusta, ¹Department of Radiology and Imaging, Nuclear Medicine Section, Medical College of Georgia, Augusta University, ²Department of Pediatrics, Hematology/Oncology Division, Medical College of Georgia, Augusta University, Georgia, USA

Abstract

Nuclear protein in testis (NUT) midline carcinoma (NMC) is a rare, aggressive, lethal, epithelioid, poorly differentiated cancer first described in Japan in 1991, unique in that it is defined genetically rather than by histological tissue of origin. It usually arises in the body midline and presents as a mass with metastasis. An infant presenting with pneumonia was found to have a pericardial mass, NMC resected, and subsequent staging positron emission tomography (PET) showing residual mediastinal tumor and midline abdominal metastases. Fewer than 100 cases of NMC have been reported in the literature, and PET appears to be the imaging modality of choice in complete staging and evaluation of treatment response.

Keywords: ^{18}F -fluorodeoxyglucose-positron emission tomography/computed tomography, nuclear protein in testis midline carcinoma, squamous cell

Introduction

Nuclear protein in testis (NUT) midline carcinoma (NMC), an orphan disease both in rarity and in lack of specific organ or tissue of origin, is far more aggressive than other squamous cell carcinoma antigen (SCCA), with median survival time of 6.7 months.^[1] Most tumors present at advanced stage with metastases, so primary resection is uncommon. After a confirmed diagnosis, ^{18}F -fluorodeoxyglucose (FDG)-positron emission tomography (PET)/computed tomography (CT) is the imaging modality of choice for staging and assessing

for metastatic disease, more sensitive and specific for typically lytic bony metastases, and useful in directing biopsy to obtain viable tissue separate from necrosis. A diagnosis of NMC comes with substantial clinical challenges.

Case Report

A 2-year-old female child with a 2-day history of persistent fever and cough was brought to the emergency department in respiratory distress and diagnosed with the left lingular pneumonia. Chest X-ray demonstrated cardiomegaly [Figure 1], and subsequent echocardiogram showed a large intrapericardial

Address for correspondence:

Dr. Hadyn T. Williams, Department of Radiology and Imaging, Nuclear Medicine Section, Medical College of Georgia, Augusta University, 1120 15th Street, BA-1411, Augusta, Georgia, USA. E-mail: hawilliams@augusta.edu

Access this article online

Quick Response Code:



Website:
www.wjnm.org

DOI:
10.4103/1450-1147.207284

For reprints contact: reprints@medknow.com

How to cite this article: Perkins C, Pucar D, McDonough CH, Williams HT. Nuclear protein in testis midline carcinoma presenting in an infant as a pericardial mass with staging by ^{18}F -fluorodeoxyglucose-positron emission tomography/computed tomography. World J Nucl Med 2017;16:247-50.

mass with small pericardial effusion. CT [Figure 2] and magnetic resonance imaging (MRI) [Figure 3] showed a 7.3 cm × 3.6 cm mass adjacent to the left ventricle with both soft tissue and fluid components exerting a mass effect on the left ventricular chamber. A median sternotomy was performed with 95% resection/cytoreduction of the mass. Fluorescence *in situ* hybridization revealed *t*(15;19) mutation and immunohistochemistry exhibited diffuse nuclear reactivity for NUT; histopathology showed high-grade malignancy composed of primitive-appearing round to ovoid-shaped cells, with irregular nuclei and scant pale eosinophilic cytoplasm arranged in a vague nested growth pattern with areas of myxoid change, focal-spindled morphology, and large areas of necrosis, consistent with NMC. Two weeks after subtotal surgical resection, FDG-PET/CT [Figures 4-7] revealed increased uptake in a 2.7 cm × 2.3 cm pericardial soft tissue density

abutting the superior aspect of the left ventricular base, maximum standardized uptake value (SUV) 2.5; midline abdominal mesenteric soft tissue tumor, SUV 4.5; no metastasis to solid organs, bone, or lung parenchyma.

Following subtotal resection of the primary pericardial tumor, the patient was started on systemic chemotherapy with paclitaxel, ifosfamide, cisplatin, and vorinostat while awaiting the US Food and Drug Administration approval for compassionate use of a small molecule bromodomain and extraterminal motif (BET) inhibitor. Nine weeks postoperative, an FDG-PET/CT [Figures 8 and 9] showed disease progression while on the BET inhibitor, and she received multiple other standard chemotherapy regimens, including cyclophosphamide, doxorubicin, vincristine, topotecan, irinotecan, and temozolomide. Despite initial stabilization of disease, she ultimately experienced disease progression and died approximately 11 months following diagnosis.

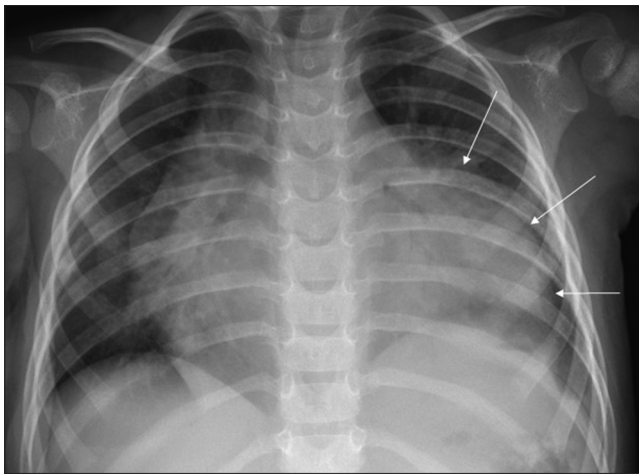


Figure 1: Frontal chest radiograph, large pericardial mass (arrows) occupying lingular region of the left lung

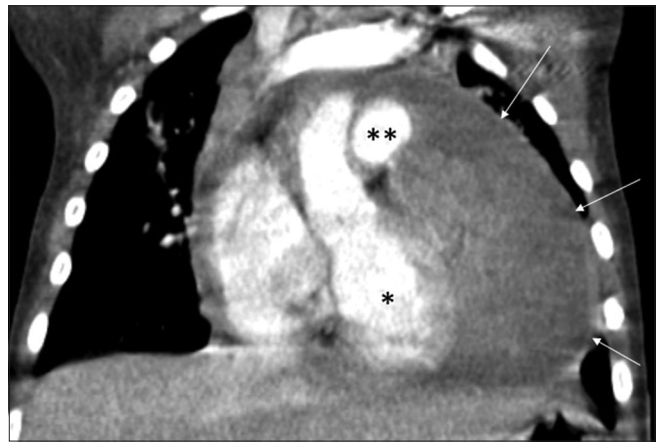


Figure 2: Coronal computed tomography, large pericardial mass (arrows), compressing the left ventricle (*) and pulmonary artery (**)

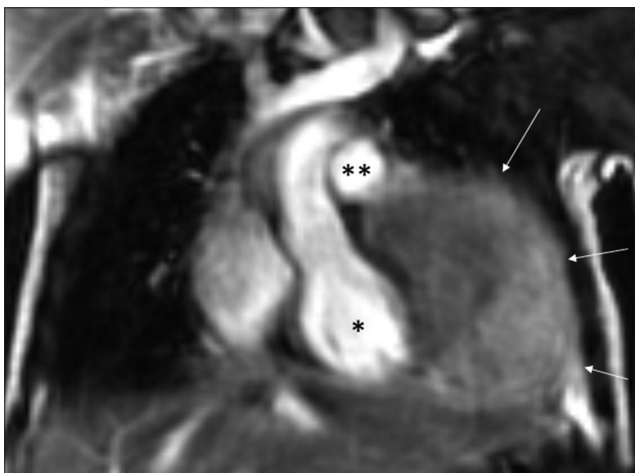


Figure 3: Coronal magnetic resonance imaging, 1.5 T, balanced steady-state gradient echo sequence, large pericardial mass (arrows), no invasion of left ventricle (*), no invasion of pulmonary artery (**), and no invasion of chest wall



Figure 4: Postoperative coronal ^{18}F -fluorodeoxyglucose-positron emission tomography/computed tomography, residual active pericardial tumor (arrow) at base of left ventricle (*), adjacent to pulmonary artery (**)

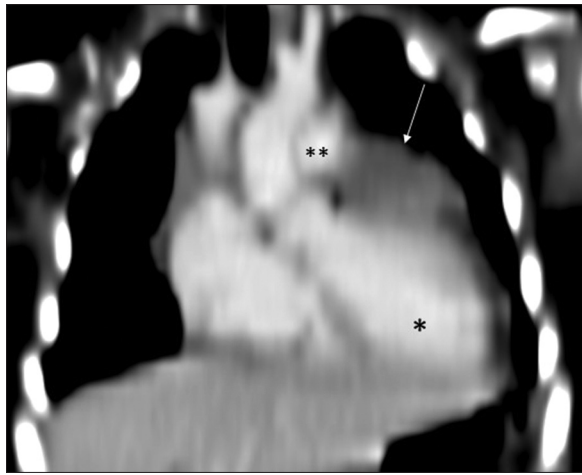


Figure 5: Postoperative coronal computed tomography residual pericardial mass (arrow) at base of left ventricle (*), adjacent to pulmonary artery (**)

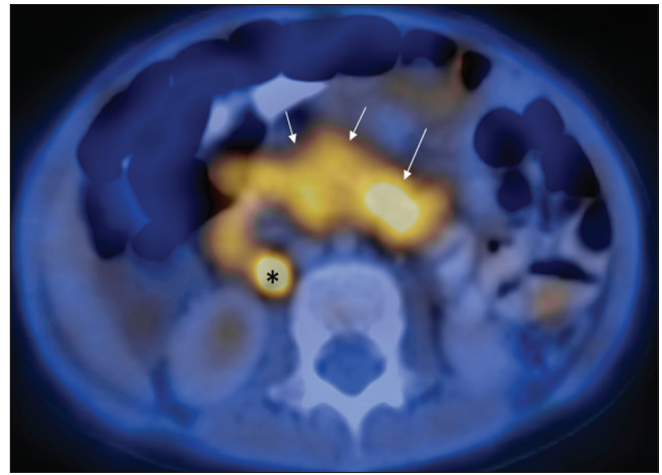


Figure 6: Postoperative transaxial ^{18}F -fluorodeoxyglucose-positron emission tomography/computed tomography, active mesenteric/retroperitoneal tumor (arrows), prominent right ureter (*)

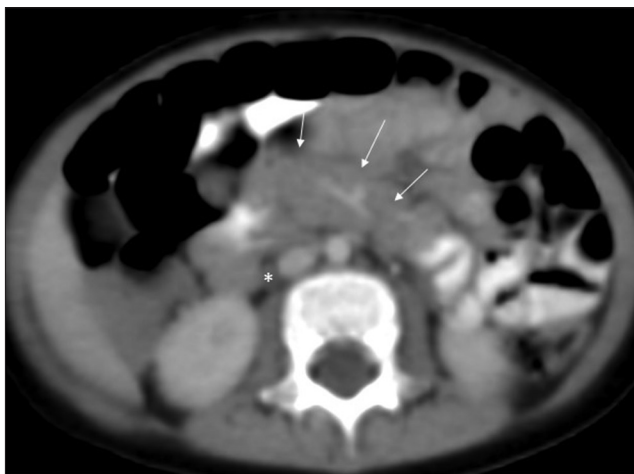


Figure 7: Postoperative transaxial computed tomography, mesenteric/retroperitoneal mass (arrows), prominent right ureter (*)

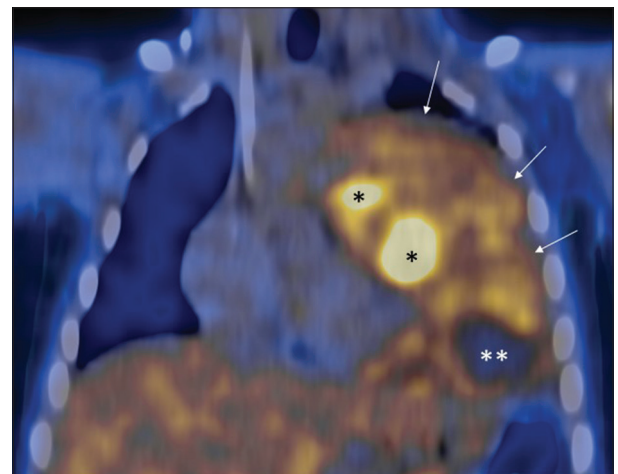


Figure 8: Follow-up coronal ^{18}F -fluorodeoxyglucose-positron emission tomography/computed tomography, progression during therapy, large pericardial tumor (arrows) more active medially (*), standardized uptake value 4.4, with necrosis (**)

Discussion

NMC is defined by chromosomal rearrangement of the NUT gene on chromosome 15 usually fused to bromodomain-containing protein 4 (BRD4) on chromosome 19. For unknown reason, it usually arises from the body midline, mostly in the head, neck, and chest but occasionally in the iliac region and bladder.

The true incidence of NMC is unknown as it is often confused with other SCCA arising in the aerodigestive tract. In young adults (median age 32.5 years), 11 of 98 lethal carcinomas were NMCs, median age 17.6 years, range from 0.1 to 78 years.^[2] Cases have been reported in all ages and both sexes.

The mechanism of action of the BRD-NUT protein is not well understood; however, the BRD4 is known to bind to acetylated histones and is thought to

preserve cellular memory by marking these regions for transcription. NUT is expressed in postmeiotic spermatids and has unknown function.^[3] The BRD-NUT protein may modify chromatin to block cell differentiation, allowing progenitor cells to continue proliferating.

CT with intravenous contrast is standard for initial staging, with NMC typically appearing as a hypoattenuating heterogeneously enhancing infiltrative mass with poorly defined margins and internal necrosis, with local invasion. Adjunctive MRI is performed if there is a concern for the chest wall, vascular, or cardiac invasion.^[4] The signal intensity on T2-weighted MRIs is that of a cellular neoplasm, but imaging characteristics are otherwise indistinguishable from other high-grade neoplasms such as lymphoma or

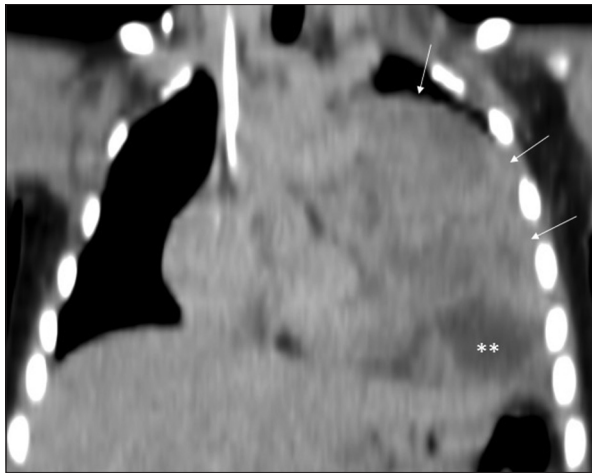


Figure 9: Follow-up coronal computed tomography, progression during therapy, large pericardial mass (arrows) with necrosis (**)

sarcoma.^[5] FDG-PET/CT is the preferred modality for guiding biopsy to viable tissue, staging and assessment of metastatic disease, evaluation of disease treatment response, and restaging with assessment of disease extent and severity over time.^[4]

NMC has a poor clinical response to aggressive chemotherapy and radiation, and to date, there has been only one known case of successful treatment of a 10-year-old boy with NMC of the iliac bone.^[6] Therapeutic targeting of BRD4-NUT fusion proteins by inhibitors targeting the bromodomain of BRD4 (BET inhibitors) leads to dissociation of BRD4-NUT from the MYC transcription promoter, leading to cellular apoptosis. Several phase 1 and one phase 2 clinical trials are underway evaluating BET inhibitors for the treatment of hematologic malignancies, lymphoma, metastatic castration-resistant prostate carcinoma, and advanced solid tumors, as well as NMC.^[7,8] An International NMC registry has been established.^[9]

NMC, a poorly differentiated highly aggressive malignancy with no specific histological tissue of origin, is likely underdiagnosed, rapidly lethal, mostly occurs in the midline above the diaphragm, and is in need of targeted therapy. We present a case of NMC in an infant, in the midline above and below the diaphragm as staged by FDG-PET/CT, responding poorly to chemotherapy.

Financial support and sponsorship

Nil.

Conflicts of interest

There are no conflicts of interest.

References

1. Bauer DE, Mitchell CM, Strait KM, Lathan CS, Stelow EB, Lüer SC, *et al.* Clinicopathologic features and long-term outcomes of NUT midline carcinoma. *Clin Cancer Res* 2012;18:5773-9.
2. French CA, Kutok JL, Faquin WC, Toretzky JA, Antonescu CR, Griffin CA, *et al.* Midline carcinoma of children and young adults with NUT rearrangement. *J Clin Oncol* 2004;22:4135-9.
3. French CA. NUT midline carcinoma. *Cancer Genet Cytogenet* 2010;203:16-20.
4. Bair RJ, Chick JF, Chauhan NR, French C, Madan R. Demystifying NUT midline carcinoma: Radiologic and pathologic correlations of an aggressive malignancy. *AJR Am J Roentgenol* 2014;203:W391-9.
5. Mills AF, Lanfranchi M, Wein RO, Mukand-Cerro I, Pilichowska M, Cowan J, *et al.* NUT midline carcinoma: A case report with a novel translocation and review of the literature. *Head Neck Pathol* 2014;8:182-6.
6. Mertens F, Wiebe T, Adlercreutz C, Mandahl N, French CA. Successful treatment of a child with t(15;19)-positive tumor. *Pediatr Blood Cancer* 2007;49:1015-7.
7. French C. NUT midline carcinoma. *Nat Rev Cancer* 2014;14:149-50.
8. Available from: <https://www.clinicaltrials.gov/ct2/results?term=BET+inhibitor>. [Last accessed on 2016 Jun 24].
9. Available from: <http://www.nmcregistry.org/>. [Last accessed 2016 Jun 24].