


Tension-free hiatal hernia repair with biological mesh

A real-world experience

Fahui Cheng, MD^a, Hongyan Liang, BA^b, Yu Zhang, MD^a, Hui Zeng, MD^a, Xiao Gao, MD^a, Lipeng Tan, BA^a, Hengzheng He, MD^{a,*} 

Abstract

Laparoscopic Nissen fundoplication and esophagoplasty are the standards for gastroesophageal reflux disease (GERD) and hiatal hernia (HH) repair. Biologically derived mesh is also associated with reduced recurrence. This study attempted to evaluate the effectiveness of a biological mesh in the 4K laparoscopic repair of HH. This retrospective study reviewed patients with a severe GERD complicated with HH from August 2019 to August 2020. All patients underwent the HH repair using a biological mesh under a 4K laparoscope accompanying Nissen fundoplication. Up to 16 months postoperatively, GERD-health-related quality-of-life (GERD-HRQL) scale, radiologic studies on HH recurrence, and symptoms were recorded. The mean surgical time and postoperative hospital stay were 70.9 ± 8.72 min, 4.8 ± 0.76 days, respectively. The postoperative symptom relief rate was 96.5%, and no recurrence exhibited during follow-up. Dysphagia occurred in 10 (9.43%) patients. There were no intraoperative vagus nerve injury or postoperative complications, mesh infection, and reoperation for mesh. The tension-free repair of HH with the biological mesh is an option for clinical use, with effectiveness and few short-term complications being reported.

Abbreviations: CT = computed tomography, GERD = gastroesophageal reflux disease, GERD-HRQL = GERD-health-related quality-of-life, GerdQ = gastroesophageal reflux disease questionnaire, HH = hiatal hernia, MRI = magnetic resonance imaging, PEH = paraesophageal hernia, VAS = visual analog scale.

Keywords: biological mesh, fundoplication, gastroesophageal reflux disease, hernia hiatal, laparoscopy

1. Introduction

As a common condition often associated with symptomatic gastroesophageal reflux disease (GERD),^[1] hiatal hernia (HH) refers to abdominal tissue structure other than the esophagus entering the thoracic cavity through the enlarged diaphragm hiatus. Global incidence of the GERD is approximately 10% to 50%, and 5% to 10% incidence happened in China with continuous increasing every year.^[2] According to the guidelines of the Society of American Gastrointestinal and Endoscopic Surgeons, laparoscopic Nissen fundoplication and esophagoplasty are standards for GERD and HH repair.^[3]

Laparoscopic treatment is the mainstay for repair in GERD and HH repair patients. Reports from Nationwide Inpatient Sample dataset showed that laparoscopic repair of paraesophageal HH is associated with significantly reduced length of stay, and a lower mortality in the uncomplicated group compared

with outcomes of the open approach.^[4] A retrospective study of laparoscopic HH repair in 221 patients found the GERD-health-related quality-of-life (GERD-HRQL) significantly decline from preoperative to 14.5 months follow-up.^[1]

Recent studies demonstrated that the use of mesh to enhance esophagoplasty can reduce recurrence rates compared to suturing repair at short-term follow-up.^[5] Several mesh materials are used for surgery, including synthetic and biological with differing shapes and fixation methods.^[6–8] Biological meshes have superior histocompatibility and decreased foreign body reactions and postoperative rejection. The incidence of postoperative esophageal stenosis, infection, esophageal erosion, and cutting and perforation in biological meshes is significantly lower than that in synthetic meshes.^[9] However, the persistence of recurrence rates and mesh-related complications such as mesh erosion or displacement, infection, and development of fibrotic stenosis in biological meshes are maintained.^[10] Controversies

FC and HL contributed equally to this work.

This study was supported by the Project No. of Wu Jieping Medical Foundation Clinical Research Special Supporting Fund (320.6750. 2020-16-1).

The authors have no conflicts of interest to disclose.

The datasets generated during and/or analyzed during the current study are available from the corresponding author on reasonable request.

The study was carried out in accordance with the Helsinki Declaration. This study was approved by the Ethics Committee of Brain Hospital of Hunan Province ((2020) LS [K] No. 13), and the informed consent was exempted.

^a Department of Mini-Invasivesurgery, Brain Hospital of Hunan Province (The Second People's Hospital of Hunan Province), Changsha, Hunan, China, ^b The First Hospital of Hunan University of Chinese Medicine, Changsha, Hunan, China.

* Correspondence: Hengzheng He, Department of Mini-invasivesurgery, Brain Hospital of Hunan Province, 427, third segment, Furong Zhong Road, Changsha, Hunan 410007, China (e-mail: Hhz19801227@126.com).

Copyright © 2022 the Author(s). Published by Wolters Kluwer Health, Inc. This is an open-access article distributed under the terms of the Creative Commons Attribution-Non Commercial License 4.0 (CCBY-NC), where it is permissible to download, share, remix, transform, and buildup the work provided it is properly cited. The work cannot be used commercially without permission from the journal.

How to cite this article: Cheng F, Liang H, Zhang Y, Zeng H, Gao X, Tan L, He H. Tension-free hiatal hernia repair with biological mesh: A real-world experience. *Medicine* 2022;101:45(e31782).

Received: 22 September 2022 / Received in final form: 21 October 2022 / Accepted: 24 October 2022

<http://dx.doi.org/10.1097/MD.00000000000031782>

exist in the treatment plan and mesh materials. There is a lack of real world study of biological meshes in laparoscopic repair of HH.

The purpose of this study is to evaluate the clinical effectiveness, recurrence, and postoperative complications associated with the use of small intestinal mucosal biological mesh for laparoscopic repair of HH.

2. Methods

2.1. Patients

The present retrospective study was conducted on patients undergoing 4K laparoscopic HH repair and Nissen folding in the Minimally Invasive Surgery Department of the Brain Hospital of Hunan Province from August 2019 to August 2020, which was approved by the Ethics Committee of Brain Hospital of Hunan Province (# (2020) LS [K] No.13), and the informed consent was exempted. The inclusion criteria were age > 18 years, GERD and HH diagnosed by clinical manifestations, computed tomography (CT) or magnetic resonance imaging (MRI), endoscopy, upper gastrointestinal angiography, esophageal acid measurement, and manometry, underwent 4K laparoscopic HH repair and Nissen folding. The surgical indications conformed to the international consensus on indications for anti-reflux surgery.^[11] Patients in whom surgery was contraindicated; those who had a previous hiatal surgery; and who converted to laparotomy or a combination with other procedures intraoperatively; those with a specific allergic constitution, including severe cardiac and liver insufficiency (cardiac function grade III and above); those with alanine transferase or aspartate aminotransferase >2.5-time the upper limit of normal values) were excluded.

2.2. Surgical technique

Non-crosslinked regenerative biological meshes (Biosis Healing Biological Technology Co. Ltd., China) composed of multi-layer acellular porcine small intestinal submucosal materials were used to perform a tension-free HH repair under a 4K laparoscope (Olympus VISERA 4K OTV-S400, Japan). This study adopted a 7-step surgical procedure.^[12] After radiography exhibited partial hernia of gastric fundus into esophageal hiatus (Fig. 1A and B), the patient was placed in a supine position with both lower limbs abducted and the head 30-degrees higher than the feet, with the operator standing between the patient's legs.

A pneumoperitoneum was established on the umbilicus, with the pneumoperitoneum pressure at 12-mm Hg. Two 1-cm and 3 0.5-cm holes were established in the upper abdomen, and a trocar of the corresponding size was inserted. The first 1-cm hole was located at the junction of the umbilicus and the middle and lower one-third of the xiphoid process, and a 30 endoscope was placed through it. The second 1-cm hole was located 2-cm below the costal margin of the midline of the left clavicle, which was the main operating hole, and the main surgical instruments (e.g., ultrasonic scalpel) were placed. The first 0.5-cm hole was located under the costal margin of the front line of the left axilla, and instruments used by assistants. The second 0.5-cm hole was located under the rib margin of the right clavicular midline and was the secondary surgical hole of the main knife, and grasped forceps or separated forceps were placed. The third 0.5-cm hole was located under the xiphoid process, and Babcock forceps were placed to grasp the fascia above the esophageal hiatus to open the liver and expose the hiatus position.

The HH contents were reduced, the omentum tissue and short gastric blood vessels between the fundus of the stomach and spleen were severed segment by ultrasonic scalpel, the gastrodaphragm and esophageal diaphragm ligament were severed free, the left diaphragm foot was exposed, the omentum tissue on the side of the small curvature of the stomach was severed, and

the right diaphragm foot and anterior peritoneum of esophagus were freed. The free esophageal length was increased to ≥ 5 -cm to create the posterior esophageal space.

The diaphragm feet on both sides were intermittently sutured with 2-0 propylene silk thread (Ethicon) to reduce the esophageal hiatus, trimmed with a trimmable concave biological mesh, and filled in front of the esophageal hiatus. The diaphragm feet on both sides were intermittently sutured and fixed with 3-0 propylene silk thread (Ethicon). The fundus of the stomach was pulled from the back of the esophagus to the front and sutured with the gastric wall on the left side of the esophagus (2-3 stitches were intermittently sutured with 2-0 silk thread, 2-cm wide; at least 2 stitches were sewn on the muscular esophageal layer) to form a 360° loose fold (Nissen fundus folding), which wrapped the whole circumference of the lower esophagus without tension (Fig. 1C–H).

2.3. Data collection

Baseline characteristics regarding the sex, age, height, weight, body mass index, medical history, and American Society of Anesthesiologists (ASA) score of the patients were collected. HH is divided into the following 4 types according to Barrett classification. Type I: Sliding type. Type II: Paraesophageal type. Type III: Mixed type. Type IV: Multi-organ type.^[13]

2.4. Outcome and follow-up

Perioperative indicators, including operating time, intraoperative estimated blood loss, hospitalization time, incidence of intraoperative vagus nerve injury, incidence of postoperative hemorrhage of surgical site, symptom relief rate, VAS score, dysphagia, esophageal stenosis, gastric fistula, esophageal fistula, and mesh infection; and reoperation were collected. Intraoperative vagus nerve injury referred to intraoperatively cut off and thermal injury by appliance. A Visual Analog Scale (VAS) was used to evaluate the degree of pain, and the subjective pain perception of patients was quantified by the VAS scale from 1 to 10. Dysphagia based on Saeed criteria.^[14] 0: No swallowing; 1: Swallows liquid difficultly, without pasty nor solids; 2: Swallows normal liquid, pasty difficultly, without swallowing solids; 3: Swallows liquid and pasty normally, with swallowing solids difficultly; 4: Swallows liquid and pasty normally, difficult to swallow solids; 5: Normal swallowing.

The follow-up was performed postoperatively through the outpatient department. The first follow-up was 1 month after surgery, with an interval of 3 months and up to 16 months. All postoperative follow-up symptoms were assessed by gastroesophageal reflux disease questionnaire (GerdQ).^[15,16] Symptomatic recurrence was defined as patient reports of symptoms of GERD. The follow-up also included parameters such as high-resolution esophageal manometry, 24-hours esophageal pH monitoring, CT, gastroscopy, and upper gastrointestinal angiography to determine radiographic recurrence.^[17] Radiographic recurrence was defined as evidence of HH.

2.5. Statistical analysis

Statistical analysis was conducted using SPSS 22.0. Variables with normal distribution were presented as mean \pm SD, and discordance with normal distribution were expressed as median (range).

3. Results

3.1. Patient demographics

106 patients, 62 (58.4%) men and 44 (41.5%) women underwent 4K laparoscopic HH repair with biologic mesh reinforcement.

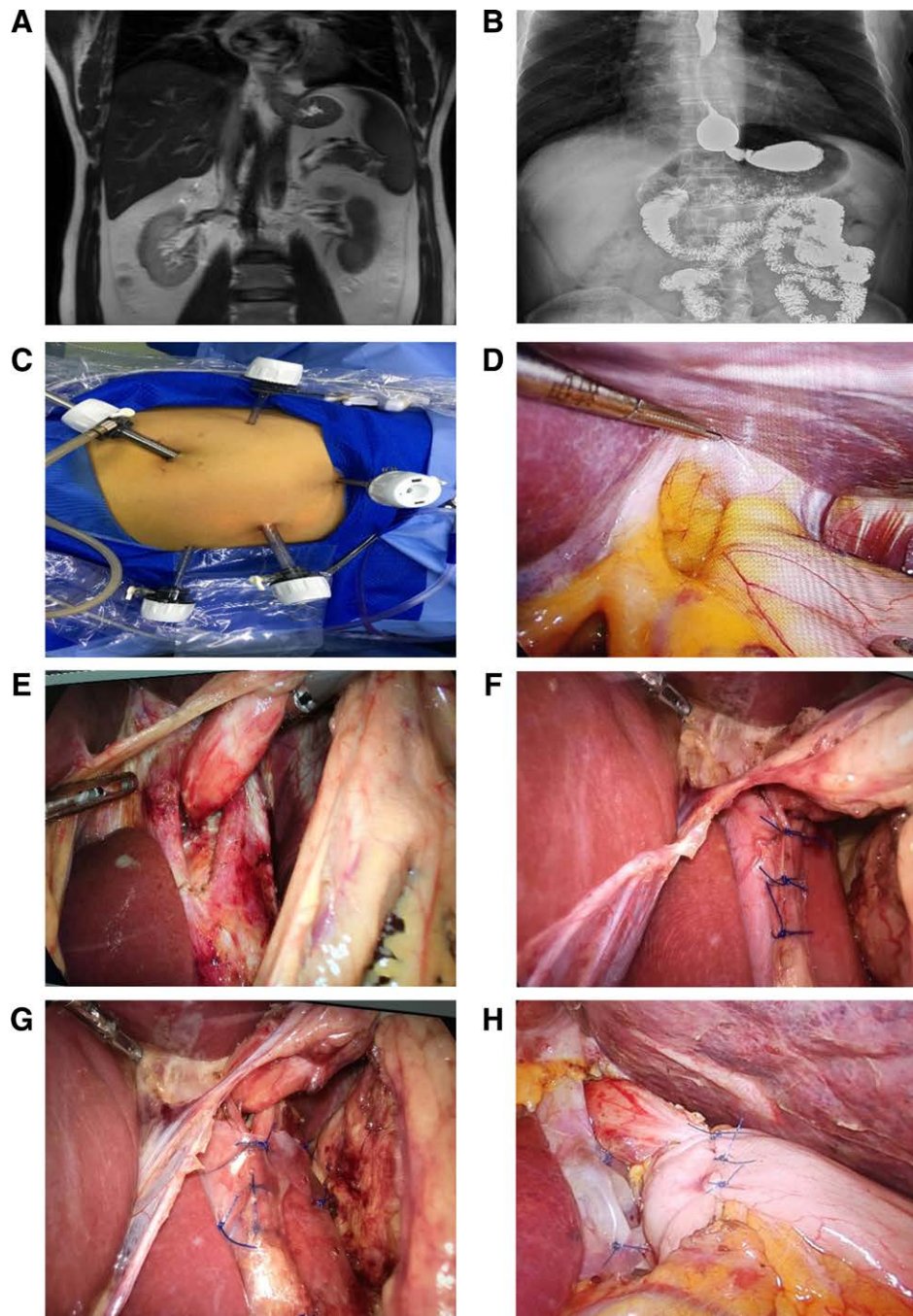


Figure 1. Surgery-related picture A: preoperative magnetic resonance imaging exhibits partial hernia of gastric fundus into esophageal hiatus; B: Barium meal of upper digestive tract indicates hiatal hernia; C: Trocar position layout; D: Restoration of hernia contents; E: Free esophagus and posterior space; F: Intermittent suture of diaphragm foot to reduce esophageal hiatus; G: Placement of biological mesh and fixation with silk thread; H: 360° Nissen fundoplication.

The ages of the patients were 52.4 (32–85) years, and the body mass index was 24.8 (18.4–35.1) kg/m². Demographic information and medical history of the patients, including hypertension, diabetes mellitus, hyperlipidemia, history of myocardial infarction, and smoking status, are presented (Table 1).

3.2. Operative data

HH was diagnosed intraoperatively in 104 (98.1%) patients, whereas 2 (1.8%) were diagnosed preoperatively. Type I to IV HH was included. The ASA physical status score was calculated that 77 (72.6%), 27 (25.4%), and 2 (1.88%) patients exhibited scores 1, 2, and 3, respectively. The surgical time for all

cases was 70.9 ± 8.72 min. The intraoperative blood loss was 30.0 ± 9.89 mL, and length of hospital stay was 4.8 ± 0.76 days. No intraoperative or perioperative complications, including vagus nerve injury, were observed (Table 2).

3.3. Postoperative data and follow-up

Postoperative symptom remission rate was 96.5%. The postoperative complications were minor. Ten of 106 (9.43%) patients exhibited dysphagia. The mean VAS score was 1.6 ± 0.71. No symptoms of postoperative complications including hemorrhage, gastric fistula, esophageal fistula, and esophageal stenosis, were observed. The length of clinical follow-up was 11 (1–16)

Table 1
Patient demographics.

Variable	Total (n = 106)
Age, yrs	52.4 (32–85)
Sex	
Male	62 (58.4%)
Female	44 (41.5%)
Body mass index, kg/m ²	24.8 (18.4–35.1)
Type of hiatal hernia	
I	65 (61.3%)
II	23 (21.6%)
III	15 (14.1%)
IV	3 (2.8%)
Hiatal hernia diagnosis	
Intraoperative	2 (1.8%)
Preoperative	104 (98.1%)
Hypertension	56 (52.8%)
Diabetes mellitus	38 (35.8%)
Hyperlipidemia	23 (21.6%)
Active smoker	55 (51.8%)
History of myocardial infarction	2 (1.8%)

Continuous data summarized as median (range). Categorical data are expressed as n (%).

Table 2
Perioperative data and complications.

Variable	Total (n = 106)
Surgical time, min	70.9 ± 8.72
Estimated blood loss, mL	30.0 ± 9.89
Length of hospital stay, days	4.8 ± 0.76
Postoperative symptom remission rate (%)	96.5%
Intraoperative complications/Injury of vagus nerve	0 (0%)
Postoperative complications	
Hemorrhage	0 (0%)
Gastric fistula	0 (0%)
Esophageal fistula	0 (0%)
Esophageal stenosis	0 (0%)
Dysphagia	10 (9.43%)
VAS score	1.6 ± 0.71
Reoperation	0 (0%)
Hernia recurrence	0 (0%)

Continuous data summarized as mean ± SD. Categorical data are expressed as n (%).

VAS = visual analog scale.

months. No patient exhibited mesh infection and required reoperation and no imaging in the asymptomatic patients displayed the recurrence (Table 2).

4. Discussion

This study evaluated the efficacy of the biological mesh in the 4K laparoscopic repair of HH in 106 patients with serious GERD. It had minimally deleterious effects on post-operative dysphagia (9.43%) and was associated with no short-term recurrence rate or complications, such as esophageal stricture, mesh infection, up to 16 months follow-up. Thus, confirming the utility and safety of a biological mesh.

Esophageal HH exhibited an occult onset. Patients exhibited either no clinical symptom or mild symptom, and the degree of symptoms was not proportional to the size of the hernial sac.^[18] The diagnosis was difficult in a small hernia, resulted in patients not lacking timely diagnosis and treatment.^[19] In China, understanding of HH has been deepened in Beijing, Shanghai and developed areas, however, the central and western regions remain unaware of this condition, delaying treatment and leading to serious consequences.^[20] According to the symptoms, duration, and medication, our center combined examination

methods such as gastroscopy, upper gastrointestinal radiography, CT, MRI, esophageal acid measurement, and manometry to make a clear diagnosis and formulate an individualized treatment plan. For patients with mild symptoms, small hernia, and no standard medical treatment, conservative medical treatment, oral proton pump inhibitors, should be administered for 2-3 months. Surgical treatment is adopted for patients with severe symptoms, large hernia, and poor long-term conservative medical treatment.

Additionally, suboptimal treatment effect and serious complications may occur due to differences in diagnosis and treatment opinions.^[21] Our results helped to establish the safety of HH repair. Laparoscopic treatment on giant HH is also safe and feasible in elective and emergency settings, even for patients over age of 80.^[22]

Patients in our center were treated with 4K laparoscopic transabdominal surgery, and 360 Nissen fundoplication was performed. This study excluded 5 patients who underwent 180° fundoplication due to short esophagus and 3 patients who underwent 270° fundoplication due to a narrow fundus. The patients were discharged from hospital 3 to 5 days postoperatively and were mobilized, could consume liquids at the first day postoperatively. Preoperative gastric tube insertion was not performed routinely, and enhanced recovery after surgery rapid rehabilitation measures were provided. The patients exhibited high comfort and few postoperative complications, with low postoperative recurrence rates. Ultra-clear image quality and local magnification function of the 4K laparoscope made the tissue structure clear and increased the tissue identification degree, enlarging the narrow space of the operation field to avoid damaging blood vessels, esophagus, stomach, and vagus nerve; allow better and safer delineation of the surgical anatomy; ensure decreased intraoperative bleeding, smooth operation process, decrease intraoperative and postoperative complications.

Both the curative effect and nerve protection must be considered. The operators should be familiar with the anatomical course of the vagus nerve and its relationship with the surrounding vascular system.^[23] The surgical procedure at our center strictly preserved the hepatic branch of vagus nerve and the trunk of vagus nerve. The incidence of postoperative complications such as abdominal distension, gastric emptying disorder, and bile stasis was low.

4.1. Simple repair

A randomized controlled pilot trial has shown no significant difference in postoperative esophagitis (p 0.737), gas bloating (p 0.782), and quality of life (p 0.992) between HH repair with or without fundoplication in the treatment of GERD, but laparoscopic HH repair combined with a fundoplication to avoid postoperative gastroesophageal reflux and resulting esophagitis.^[24] Several studies confirmed that a laparoscopic 270° Toupet or a laparoscopic 180° Dor fundoplication provided similar control of GORD at follow-up, with no difference in post-fundoplication symptoms, and majority of patients (88%) were satisfied with operation outcomes.^[25,26] A retrospective review of prospectively collected data reported that incidence of recurrent HH increased in direct correlation with the preoperative HH size (No HH: 0%, small HH (<3-cm): 10.1%, large HH (≥3-cm): 16.6%, paraesophageal hernia (PEH): 20%, p 0.032) after magnetic sphincter augmentation. According to a 5-year observation, patients who underwent laparoscopic repair of large (≥5-cm) type III HH, the 5-year recurrence-free probability was similar, but an earlier failure rate was noted in the non-mesh group at 12 months (p .299). For patients with esophageal hiatus <5-cm, simple repair could be attempted. However, given the increasing risks of long-term recurrence, we chose to place meshes and use tension-free repair. No consolidated standard

existed yet on whether the hernia sac must be removed and the size of the hernia sac to be removed. Haze suggested that there was no need to forcibly remove the hernial sac to avoid damaging the vagus nerve. Enough space was present for strengthening the diaphragm and placing a mesh.

4.2. Artificial synthetic mesh repair

Materials for artificial synthetic mesh repair include non-absorbable synthetic materials such as polypropylene, polyester, polytetrafluoroethylene, and polyvinylidene fluoride, absorbable synthetic materials such as polylactic acid and polycaprolactone, composite materials, animal-derived materials, and allogeneic materials. Since artificial synthetic hernia meshes have been applied in the clinical setting, significant progress has been made in approaches to treat hernia repair. However, with the extension of its application time, the problem of poor histocompatibility of nondegradable synthetic materials has become increasingly prominent, and increased cases of mesh infection after operation require reoperation to remove the mesh. The synthetic mesh, represented by the polypropylene mesh, directly comes into contact with internal organs and can not only cause serious abdominal adhesion but also long-term contact and friction between the mesh and gastric wall and esophagus when used to repair HH due to the rough surface of the mesh. Thus, it may easily damage the gastric wall and esophagus and erode the esophagus and gastric wall in severe cases, causing gastric and esophageal fistulas. Presently, the disadvantages of synthetic mesh such as permanent residue and scar after 3 months in clinical practice have become increasingly prominent. The pain, discomfort, and foreign body sensation caused by scar tissue sclerosis are difficulties that synthetic mesh cannot overcome. A systematic reviewed the application of a mesh in the HH repair during Nissen fundoplication for both GERD and HH, suggesting that the recurrence rate in the synthetic mesh group was 6.8% compared to 16.1% in the biological mesh group ($P < .05$), and the complication rate was 5.1% and 4.6% ($P .694$), respectively.^[10] Additionally, once infection and recurrence occur after the synthetic mesh is implanted into the human body, a secondary operation is required to extract the mesh, which not only increases pain but also the economic burden on the patient. Thus, in-depth research is required on collagen-based biomaterials when scientists are constantly exploring, improving, and developing composite materials.

4.3. Biological mesh repair

Biological mesh repair is based on biological materials and has been approved by FDA. The use of biological mesh can not only reduce the postoperative recurrence rate of HH but also effectively reduce the erosion and entrapment of esophagus by postoperative mesh and reduce the probability of esophageal stenosis caused by inflammation.^[9,27] Biological mesh is a novel biological material with unique clinical therapeutic effects. The biological mesh produced by Beijing Biosis Healing Biological Technology Co. Ltd. is a xenogeneic acellular matrix material prepared from the small intestinal submucosa of pigs. It can remove immunogenicity and has superior biocompatibility, mechanical strength, suitable porosity, and biodegradability. After being implanted into the human body, it can stimulate cells to grow into mesh pores. Then, a solid fibrous tissue wall is formed to achieve rapid repair and completely degraded after completing the replacement repair of native tissues, thus maintaining the supporting effect. All patients undergoing HH repair at our center were repaired with the biological mesh. The longest follow-up was 16 months with a superior effect observed and further long-term follow-up data are expected. The common complication after fundoplication is dysphagia, most of which are mild and can be relieved by conservative

treatment. Moderate and severe dysphagia must be expanded with the gastroscop, and the balloon expansion effect under gastroscop is obvious. Patients who fail balloon expansion must undergo surgical refolding again. The most common postoperative adverse reactions in our unit were slight obstruction after eating, which was observed in 10 cases, most of which occurred 2 weeks postoperatively, due to edema in the early operation area and not following the doctor's advice strictly. However, it could be relieved after fasting for 2 to 3 days. Endoscopic expansion completely relieved the obstruction in 1 case, and no severe scar stenosis was observed after 2 weeks. This might be related to the reduction of inflammation by biological mesh. Postoperative chronic pain was observed at the operated site, and no complications were observed. No secondary operation was performed to remove the mesh postoperatively. Therefore, the biological mesh exhibits superior histocompatibility and no postoperative recurrence, indicating sound surgical effect, is observed.

5. Conclusion

The use of the biological mesh in tension-free HH repair under the 4K laparoscope is safe and effective, and is associated with fewer adverse reactions and an obvious short-term effect.

Acknowledgments

The authors would like to thank the Beijing Biosis Healing Biological Technology Co., Ltd., for its support to this paper, Dr Yu Xueqiao and Dr Wu Wenyue for their guidance and help, and all participating authors for their contributions.

Author contributions

Conceptualization: Fahui Cheng.

Data curation: Hongyan Liang.

Formal analysis: Hui Zeng.

Funding acquisition: Hengzheng He.

Investigation: Xiao Gao.

Methodology: Fahui Cheng.

Project administration: Hengzheng He.

Resources: Fahui Cheng.

Software: Yu Zhang.

Supervision: Hengzheng He.

Validation: Fahui Cheng.

Visualization: Lipeng Tan.

Writing – original draft: Fahui Cheng.

Writing – review & editing: Fahui Cheng, Hengzheng He.

References

- [1] Chang CG, Thackeray L. Laparoscopic Hiatal Hernia repair in 221 patients: outcomes and experience. *JLS*. 2016;20:e2015.00104.
- [2] Eusebi LH, Ratnakumaran R, Yuan Y, et al. Global prevalence of, and risk factors for, gastro-oesophageal reflux symptoms: a meta-analysis. *Gut*. 2018;67:430–40.
- [3] Kohn GP, Price RR, DeMeester SR, et al. Guidelines for the management of hiatal hernia. *Surg Endosc*. 2013;27:4409–28.
- [4] Fullum TM, Oyetunji TA, Ortega G, et al. Open versus laparoscopic hiatal hernia repair. *JLS*. 2013;17:23–9.
- [5] Zhang C, Liu D, Li F, et al. Systematic review and meta-analysis of laparoscopic mesh versus suture repair of hiatus hernia: objective and subjective outcomes. *Surg Endosc*. 2017;31:4913–22.
- [6] Grossman RA, Brody FJ, Schoolfield CS, et al. Laparoscopic Hiatal Hernia repair with falciform ligament buttress. *J Gastrointest Surg*. 2018;22:1144–51.
- [7] Watkins JR, Truitt MS, Osman H, et al. Biologic Keyhole mesh in hiatal hernia repair. *JLS*. 2018;22:e2017.00086.
- [8] Kudsi O, Bou-Ayash N, Gokal F. Robotic transabdominal preperitoneal repair of complex inguinal hernias. *Int J Abdom Wall Hernia Surg*. 2021;4:1–6.

- [9] Spiro C, Quarmby N, Gananadha S. Mesh-related complications in paraoesophageal repair: a systematic review. *Surg Endosc*. 2020;34:4257–80.
- [10] Castelijns PSS, Ponten JEH, van de Poll MCG, et al. A collective review of biological versus synthetic mesh-reinforced cruroplasty during laparoscopic Nissen fundoplication. *J Minim Access Surg*. 2018;14:87–94.
- [11] Pauwels A, Boecxstaens V, Andrews CN, et al. How to select patients for antireflux surgery? The ICARUS guidelines (international consensus regarding preoperative examinations and clinical characteristics assessment to select adult patients for antireflux surgery). *Gut*. 2019;68:1928–41.
- [12] Tang F, Ma N, Li YR, et al. Preoperative progressive pneumoperitoneum enables defect closure and laparoscopic repair of large parastomal hernias. *Surg Laparosc Endosc Percutan Tech*. 2020;30:123–8.
- [13] Yu HX, Han CS, Xue JR, et al. Esophageal hiatal hernia: risk, diagnosis and management. *Expert Rev Gastroenterol Hepatol*. 2018;12:319–29.
- [14] Saeed ZA, Winchester CB, Ferro PS, et al. Prospective randomized comparison of polyvinyl bougies and through-the-scope balloons for dilation of peptic strictures of the esophagus. *Gastrointest Endosc*. 1995;41:189–95.
- [15] Dent J, Jones R, Vakil N, et al. A management strategy for GERD based on the Gastroesophageal reflux disease questionnaire (GerdQ). *Scand J Gastroenterol*. 2008;43:34–5.
- [16] Jones R, Junghard O, Dent J, et al. Development of the GerdQ, a tool for the diagnosis and management of gastro-oesophageal reflux disease in primary care. *Aliment Pharmacol Ther*. 2009;30:1030–8.
- [17] Zaninotto G, Portale G, Costantini M, et al. Objective follow-up after laparoscopic repair of large type III hiatal hernia. Assessment of safety and durability. *World J Surg*. 2007;31:2177–83.
- [18] Ushimaru Y, Nakajima K, Takahashi T, et al. Occult Hiatal Hernia in Achalasia patients: its incidence and treatment options. *Dig Surg*. 2019;36:418–25.
- [19] Schmidt E, Shaligram A, Reynoso JF, et al. Hiatal hernia repair with biologic mesh reinforcement reduces recurrence rate in small hiatal hernias. *Dis Esophagus*. 2014;27:13–7.
- [20] Zou D, He J, Ma X, et al. Epidemiology of symptom-defined gastroesophageal reflux disease and reflux esophagitis: the systematic investigation of gastrointestinal diseases in China (SILC). *Scand J Gastroenterol*. 2011;46:133–41.
- [21] Siegal SR, Dolan JP, Hunter JG. Modern diagnosis and treatment of hiatal hernias. *Langenbecks Arch Surg*. 2017;402:1145–51.
- [22] Khoma O, Mugino M, Falk GL. Is repairing giant hiatal hernia in patients over 80 worth the risk? *Surgeon*. 2020;18:197–201.
- [23] Imai TA, Soukiasian HJ. Management of complications in paraesophageal hernia repair. *Thorac Surg Clin*. 2019;29:351–8.
- [24] Müller-Stich BP, Achtstätter V, Diener MK, et al. Repair of paraesophageal hiatal hernias—is a fundoplication needed? A randomized controlled pilot trial. *J Am Coll Surg*. 2015;221:602–10.
- [25] Roks DJ, Koetje JH, Oor JE, et al. Randomized clinical trial of 270° posterior versus 180° anterior partial laparoscopic fundoplication for gastro-oesophageal reflux disease. *Br J Surg*. 2017;104:843–51.
- [26] Kiudelis M, Kubiliute E, Sakalys E, et al. The choice of optimal anti-reflux procedure after laparoscopic cardiomyotomy: two decades of clinical experience in one center. *Wideochir Inne Tech Maloinwazyjne*. 2017;12:238–44.
- [27] Antoniou SA, Pointner R, Grandrath FA. Hiatal hernia repair with the use of biologic meshes: a literature review. *Surg Laparosc Endosc Percutan Tech*. 2011;21:1–9.