

Contents lists available at [ScienceDirect](http://www.sciencedirect.com)

International Journal of Surgery Case Reports

journal homepage: www.casereports.com

Post coital penile ring entrapment: A report of a non-surgical extrication method



Agu Thaddeus Chika^{a,b,*}, Obiechina NJA^c

^a Imo State University, Owerri, Nigeria

^b First Choice Specialist Hospital, Nkpor, Nigeria

^c Nnamdi Azikiwe University, Nnewi, Nigeria

ARTICLE INFO

Article history:

Received 26 September 2015

Received in revised form

19 November 2015

Accepted 21 November 2015

Available online 30 November 2015

Keywords:

Post coital

Penile

Ring entrapment

ABSTRACT

This case report shows how a simple but painstaking method of milking and levering in a slippery field was used to remove a thick metallic ring entrapped at the root of the penis after sexual intercourse. A ring can be removed easily from an organ if the inter-phase is made slippery. However this must be weighed against the handling difficulties posed by a wet slippery surface. With perseverance and the use of unconventional instrument, the ring was successfully extricated as a day case and without a surgical incision.

© 2015 The Authors. Published by Elsevier Ltd. on behalf of IJS Publishing Group Ltd. This is an open access article under the CC BY-NC-ND license (<http://creativecommons.org/licenses/by-nc-nd/4.0/>).

1. Introduction

Penile ring entrapment is a rare urological emergency that can lead to different degrees of vascular and mechanical complications. The use of metal rings on the penis for erotic purposes has been described in men and adolescent boys [1]. There are some unconventional as well as surgical methods of extricating entrapped penile rings that have been reported in the literature. A useful algorithm that outlines management options based on the object type, object strength, object size and grade of penile strangulation is also available in the literature [1]. We believe that an entrapped ring should be removed by the fastest, safest, most efficient, and if possible, a non-surgical method so that recovery can be quick and uneventful. This method of extrication presented combines the merits of safety, efficiency, no morbidity and early discharge from hospital. The aim of this report is to create an awareness of penile ring entrapment in our sub-region and to review the common methods of extrication.

2. Case presentation

The patient is a 26 year old male who presented in a specialist orthopaedic & trauma centre on the 17th of September, 2015 with a painful engorged penis, 13 hours after sexual intercourse. He complained of weak and poorly sustained erections. During foreplay he

removed his thick completely circular ring from his finger, put it on the glans and slid it all the way to the root of his penis. He and his partner tried to remove the ring afterwards. In the agitation and manipulation, he noticed that the penis continued to engorge and pain ensued. He saw a doctor 10 hours later who tried to remove it without anaesthesia before referral to our centre.

On examination, he was anxious and distressed. The penile shaft was grossly oedematous, mildly tender, cold, sensate, engorged but not turgid. The glans was also oedematous, cyanosed, cold and sensate. The circumference of the penis at the widest point was 16 cm (measured with a strip of gauze thread intra-operatively and cross-checked with a measuring tape afterwards). A thick stainless steel ring, 6.5 cm in circumference (measured after extrication) was seen at the root of the penis (Fig. 1). He had a full urinary bladder which was mildly tender but there was no urgent need to micturate. The haemoglobin was 12.8 g/dl and urinalysis was normal. The plan was to remove the ring urgently.

Under general anaesthesia, the entire penile shaft was soaked with savlon to provide a fairly slippery field. The surgeon operated from the right hand side of the patient, steadied the ring with the left hand as he milked the oedematous skin and corpora from the shaft towards the root of the penis with the right hand. At the same time the assistant pulled any advanced tissue from beneath the ring towards the root of the penis. This maneuver was repeated severally and as the ring shifted distally, it was prevented from sliding back with the left hand. In addition, a blunt paediatric bone lever (Fig. 2) was a handy armamentarium [At1] used to lever the ring gradually and steadily until it got to the corona. The glans was squeezed and the ring slipped off. The procedure lasted twenty one minutes.

* Corresponding author at: Imo State University, Owerri, Nigeria.

E-mail addresses: tcagu@yahoo.com, tcaguieneth@yahoo.com (T.C. Agu).

He had some minor skin abrasions. A size 12 Foley urethral catheter was passed to evacuate the bladder and a clear urine was noted. The catheter was removed and there was no blood stain. The glans penis turned pink some minutes after the procedure (Fig. 3) and also became warm. The recovery from anaesthesia was uneventful and patient was discharged on the same day on antibiotics and analgesics. He was referred to an erectile dysfunction clinic.

3. Discussion

The practice of using metal rings to sustain penile erection is not common and the ring can get entrapped on the penis [1]. Many clinicians are not familiar with this emergency because of its rare occurrence. The management is challenging and often times, the surgeon considers many methods in an attempt to remove the ring from the inflamed penis. This case report intends to create an awareness of penile ring entrapment in our sub-region and review the common methods of extrication. Tying rubber bands and hair coils around penises by children as part of childhood pranks or to prevent enuresis is encountered occasionally and removal by cutting is easy [2]. The injury caused by this non-metallic ring is

not always recognizable and the clinician should keep this in mind when a boy presents with unexplained penile swelling, ulceration and leakage of urine [3,4]. In men and adolescent boys, penile ring entrapment results mainly from the use of metal rings for erotic purposes [1]. Early presentation and early extrication of the ring will reduce the chances of vascular or mechanical complications [5]. However, majority of patients do not seek medical advice early because of the embarrassment [6]. Our patient tried severally over a period of 10 hours to remove the ring before presenting to the doctor. Patients presenting with incarceration after 72 hours are more likely to sustain higher grade injuries like pressure necrosis, urethral fistula, penile gangrene and stricture [7].

There is no standard method of removing an entrapped penile ring and removal can be effected with non-medical tools. Some cases of penile ring entrapment can be difficult to treat and require resourcefulness and a multi-disciplinary approach [8,9]. However there is a useful algorithm outlining treatment options that are determined by the object type, strength and size, grade of injury and complications [1]. Penile ring entrapment is a urological emergency and should be treated by the easiest, fastest, yet safe method of extrication. This is to avoid the complications that may result from delay. The use of strings, cutters, aspiration decompression and surgical degloving have been explored by several authors depending on their experiences, preferences and results.

String method is simple and it can be maneuvered to extricate a thin metal ring in the early stages of penile entrapment. The string is passed through the interphase between the ring and penile skin. This may be difficult if there is gross oedema. The tightness of the string on the penile skin as the proximal part is unwound may cause penile skin lacerations and friction injury. For thick metal rings and ball bearing metal rings, string technique may not be the first line option especially when there is marked oedema [1].

The commonest reported device that causes penile entrapment is metal ring [7] and the commonest method of extrication is cutting despite the tediousness and risk of penile injury [1]. If a giant orthopaedic cutter can be insinuated beneath the ring to cut it, then it will be the fastest but may not be the safest method of removing a thick metal ring. On the other hand, a small cutter that can get beneath the ring easily without injuring the penis is unlikely to cut a thick metal. A hacksaw or gigli saw or angle grinder may also injure the penis from lack of adequate protection in the small operating field and from heat generation [9,10]. Sprinkling ice packed normal saline on the interphase will help to reduce the heat and prevent burns [10].




Fig. 1. Oedematous penile shaft and glans, thick circumferentially connected hard metal ring at root of penis, note the differential size, note also the wrinkles on the penile skin.

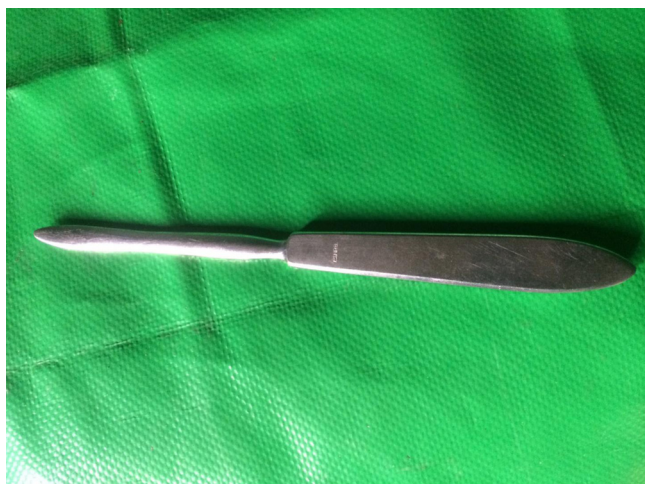

Fig. 2. A blunt ended paediatric bone lever used as an unconventional tool in levering the ring.

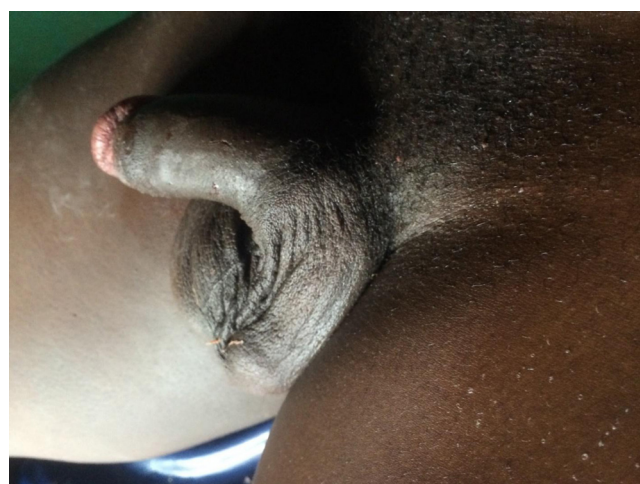


Fig. 3. The penis after extrication of the ring. Note the pink glans penis and minor skin abrasions.

Aspiration decompression is a surgical technique that is used to evacuate blood from the engorged corpora. This reduces the size of the penis so that the ring can be removed [11]. This method will not evacuate the inflammatory oedema within the penile skin and interstitial spaces and so may be combined with other maneuvers to effect the extrication.

Surgical degloving of the penile skin and Bucks fascia from the corpora is similar to raising flaps that are used in urethroplasties and hypospadias repairs. The flaps are reduced through the ring which in turn is easily slipped distally over the degloved shaft [12]. The oedematous glans cannot be degloved and this poses additional problem. This method requires special training and there are likely complications of wound breakdown, urethral injury and flap necrosis [12].

In our patient, we considered non-surgical method of milking and levering in a slippery field the fastest and safest method of extrication. The penile skin is lax and distensible. The patient's oedematous penis had wrinkles signifying that it can be squeezed (Fig. 1). General anaesthesia was used because by eliminating the visual and tactile stimuli, it was more likely to knock off the erectile inputs to the penis during the procedure. However, the surgeon should consider the risk of general anaesthesia in this emergency situation and take all the necessary precautions.

4. Conclusion

Penile ring entrapment is a surgical emergency. After quick clinical assessment, the next action is to extricate the ring by any safe, effective and possibly non-surgical method. This emergency can be handled by any readily available specialist surgeon who had participated in the treatment of similar ring entrapments as the principles of conservative treatment is the same. Comparatively, this extrication method is safe with little or no morbidity and should be a first line method for early penile ring entrapment and only when it fails should riskier or invasive methods be explored.

Conflict of interest

There is no conflict of interest amongst the authors.

Funding

The work is self-sponsored by the first author who conceptualized and designed and wrote the manuscript. The second author assisted in the surgery provided some literature review and made necessary correction which lead to the final manuscript.

Ethical approval

The ethical committee of First choice Specialist Hospital where the authors carried out the procedure approved the work. Ref no. FCSH 24/9/2015.

Consent

The patient gave an informed consent for this publication. He understood that part of his images will be published and also understood that due to the rarity of the case, that it is worthwhile publishing it for education and for health care delivery. The consent was unconditional.

Author contribution

The first author carried out the procedure, designed and wrote the manuscript. The second author assisted during the surgery, provided immediate care, provided some literature review and made necessary correction which lead to the final manuscript.

Guarantor

Agu Thaddeus Chika.

References

- [1] S. Iqbal, M.K. Joshi, M. Jaura, Strangulation of penis by a ball bearing device, *J. Sex. Med.* 7 (November (11)) (2010) 3793–3797.
- [2] F.S. Haddad, Penile strangulation by human hair: report of three cases and review of the literature, *Urol. Int.* 37 (6) (1982) 375–388.
- [3] A.G. Toguri, R.A. Light, M.M. Warren, Penile tourniquet syndrome caused by hair, *South Med. J.* 72 (May (5)) (1979) 627–628.
- [4] A.L. Bhat, A. Kumar, S.C. Mathur, K.C. Gangwal, Penile strangulation, *Br. J. Urol.* 68 (December (6)) (1991) 618–621.
- [5] O. Ivanovski, O. Stankov, M. Kuzmanoski, S. Saidi, S. Banev, V. Filipovski, L. Lekovski, Z. Popov, Penile strangulation: two case reports and review of the literature, *J. Sex. Med.* 4 (2007) 1775–1780.
- [6] T. Xu, M. Gu, H. Wang, Emergency management of penile strangulation: a case report and review of Chinese literature, *Emerg. Med. J.* 26 (2009) 73–74.
- [7] J. Silberstein, J. Grabowski, C. Lakin, I. Goldstein, Penile constriction devices: case report, review of the literature and recommendation for extrication, *J. Sex. Med.* 5 (July (7)) (2008) 1747–1757.
- [8] L. Dell'Atti, Penile strangulation: an unusual sexual practice that often present a urological emergency, *Arch. Ital. Urol. Androl.* 86 (March (1)) (2014) 43.
- [9] K.T. Sathesh, J.S. Hanna, N. De Zoysa, A. Saleemi, Genitalia strangulation: fireman to the rescue, *Ann. R. Coll. Surg. Engl.* 91 (May (4)) (2009) 15–16.
- [10] M.Y. Kyei, E.K. Asante, J.E. Mensah, G.O. Klufio, A. Paintsil, S. Gepi-Atee, B. Morton, K. Ampadu, B. Toboh, Penile strangulation by self-placement of metallic nut, *Ghana Med. J.* 49 (March (1)) (2015) 57–59.
- [11] S.J. Chang, I.N. Chiang, J.T. Hsieh, S.P. Liu, Extrication of penile constriction device with corpora aspiration, *J. Sex. Med.* 6 (March (3)) (2009) 890–891.
- [12] A.O. Olajide, A.K. Eziyi, F.O. Olajide, Novel surgical extraction of penile constricting metal ring: a case report, *Int. J. Case Rep. Images* 4 (9) (2013) 511–514.

Open Access

This article is published Open Access at sciendoirect.com. It is distributed under the [IJSCR Supplemental terms and conditions](#), which permits unrestricted non commercial use, distribution, and reproduction in any medium, provided the original authors and source are credited.