

Iliac Vein Injury Due to a Damaged Hot Shears™ Tip Cover During Robot Assisted Radical Prostatectomy

Enrique Ian Lorenzo, Wooju Jeong, Sangun Park, Won Tae Kim, Sung Joon Hong, and Koon Ho Rha

Urological Science Institute, Department of Urology, Yonsei University College of Medicine, Seoul, Korea.

Received: July 1, 2009

Revised: August 27, 2009

Accepted: August 27, 2009

Corresponding author: Dr. Koon Ho Rha,
Urological Science Institute, Department of
Urology, Yonsei University College of Medicine,
250 Seongsan-ro, Seodaemun-gu,
Seoul 120-752, Korea.

Tel: 82-2-2228-2318, Fax: 82-2-312-2538

E-mail: khrha@yuhs.ac

· The authors have no financial conflicts of interest.

We report a rare case of vascular injury secondary to a damaged Hot Shears™ tip cover. Two 1 mm holes in the tip cover resulted in perforations in the obturator and external iliac veins during pelvic node dissection. Bleeding was controlled with bipolar coagulation and a 5 mm metal clip in the obturator and iliac vein, respectively. The rest of the procedure was completed uneventfully. Frequent integrity assessment of this accessory is necessary. Its function is important in order to carry out safe dissection in proximity to delicate structures. When injuries arise from areas not directly involved in the dissection, immediate inspection of the instruments should be mandatory.

Key Words: Hot shears, instrument malfunction, robot assisted radical prostatectomy, Da Vinci prostatectomy

INTRODUCTION

This decade has witnessed the surge in popularity of robot assisted surgery. Due to benefits for both patients and surgeons, it has gained wide acceptance. As such, it has been considered as one of the surgical therapeutic options for prostate cancer patients.

Despite all the benefits, a robot is still a machine with mechanical parts and accessories. Questions have thus been raised on its stability and reliability, however, there have been reports of minimal error and failure rates.¹⁻³ This report aims to show that more attention should be given not only to the mechanical parts but also to its accessories as well. Extra caution should be exercised in the maintenance and care of the equipment to eliminate unnecessary complications during and after the operative procedure.

CASE REPORT

The patient was 63 years old with clinical T1c prostate cancer. Serum prostate specific antigen (PSA) was 7.59 ng/mL and biopsy showed gleason 7 (3 + 4) 40% involvement in 1 of 12 cores. MRI was negative for extracapsular extension, semi-

© Copyright:

Yonsei University College of Medicine 2011

This is an Open Access article distributed under the terms of the Creative Commons Attribution Non-Commercial License (<http://creativecommons.org/licenses/by-nc/3.0>) which permits unrestricted non-commercial use, distribution, and reproduction in any medium, provided the original work is properly cited.

nal vesicle involvement or enlarged pelvic lymph nodes. Bone scan was likewise negative. We performed pelvic lymph node dissection as an integral part of radical prostatectomy, especially for intermediate to high risk patients.

In the operating room, the patient was under general anesthesia in an exaggerated trendelenburg position. Two 12 mm, three 8 mm and one 5 mm ports were used. The four-arm da Vinci S Surgical System® (Intuitive Surgical, Inc., Sunnyvale, California, USA) was utilized. The right arm was loaded with Hot Shears™ (Intuitive Surgical, Inc., Sunnyvale, California, USA), left arm with PreCise™ bipolar forceps and the third arm with ProGrasp™ forceps. The surgery began with node dissection on the left which was unremarkable. On dissection of the contra lateral obturator lymph nodes, bleeding was noted from the obturator vein which was controlled by bipolar coagulation (Fig. 1). It was initially dispelled as a surgical error. On further dissection of the nodes from the obturator nerve with the Hot Shears™ a small perforation was noted on the right external iliac

vein despite a safe distance between the instrument and the vein (Fig. 2A). The vein was grasped with the bipolar forceps and a 5 mm metal clip was applied tangentially (Fig. 2B). Pressure was decreased to 5 mmHg, and no further bleeding was noted. The rest of the procedure was completed uneventfully. After the operation, inspection of the instruments revealed two 1mm holes on the Hot Shears™ tip cover which explains the perforation on the iliac and obturator veins (Fig. 3). Jackson-Pratt drain was placed on the pelvic cavity, as done routinely. Drainage was 27 cc on the first day and 30 cc on the 2nd day. Drain was pulled out on the third day, and the patient was discharged.

DISCUSSION

The Tip Cover plays an important role in the robotic instrument. It is a silicon boot applied on the Hot Shears™ which serves as an insulation for the metallic segment of the En-

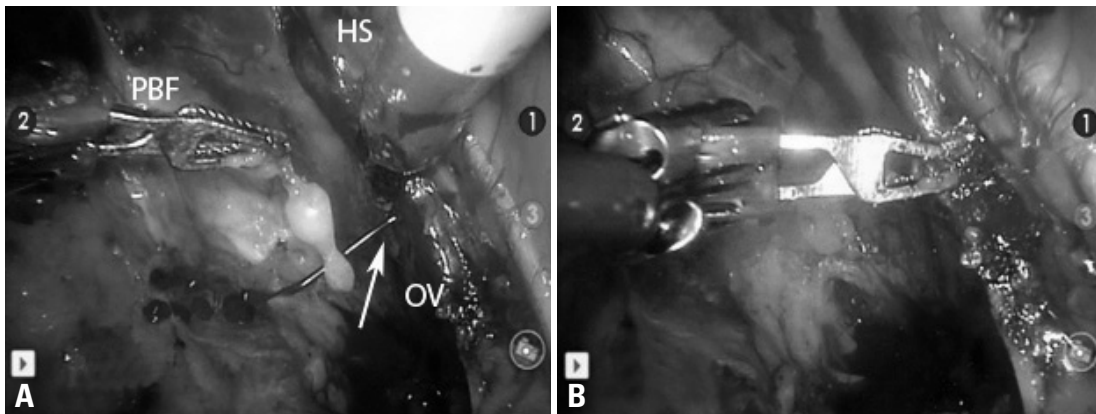


Fig. 1. (A) Obturator Vein Injury. Note the stream of blood from the obturator vein which noticed without apparent trauma to the vein (white arrow). (B) Controlled obturator vein bleeding. PreCise™ bipolar forceps was used to grasp the area of bleeding followed by bipolar coagulation. PBF, PreCise Bipolar Forceps; HS, Hot Shears; OV, obturator vein.

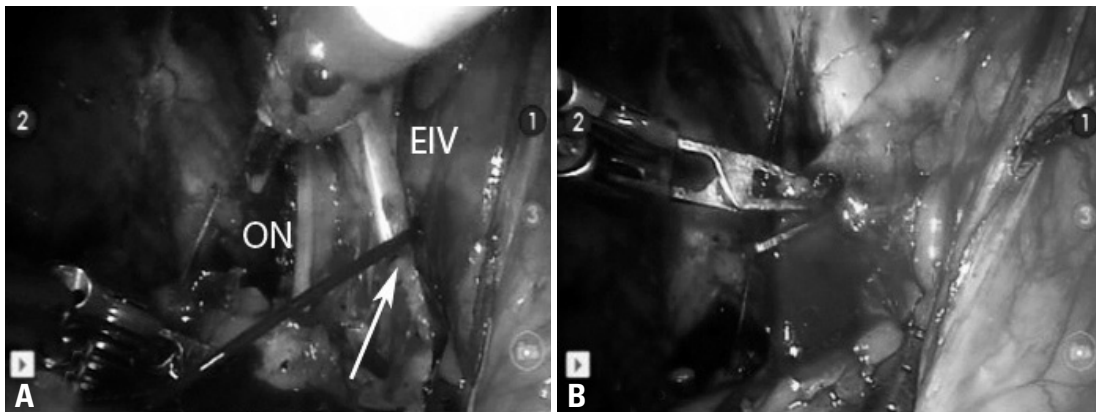


Fig. 2. (A) Injured External Iliac Vein. During dissection near the obturator nerve, a stream of blood was noted coming from the external iliac vein (white arrow). (B) Clipped External Iliac Vein. The iliac vein was grasped with the bipolar forceps close to the bleeding point, and a metal clip was applied tangentially. EIV, external iliac vein; ON, obturator nerve.




Fig. 3. Hot Shears with Tip Cover™. Inset: Perforations on Tip Cover accessory (black arrows).

doWrist™ and prevents broad dissipation of monopolar electric current. It allows safe dissection in proximity to delicate structures such as blood vessels, nerves and bowel. Among 900 robot assisted radical prostatectomy carried out from July 2005 to March 2009, more than 500 pelvic node dissections have been conducted in this institution. This incident is the first, and no similar report has been published. Review of the procedure's file video did not reveal any trauma to the Hot Shears™ area. We apply a new tip cover for every case as recommended by the product supplier. As the Hot Shears™ is a surgical scissors with monopolar coagulation capability, it is commonly used during dissection. It is, therefore, advocated then that the Tip Cover™ accessory should be inspected regularly in the course of surgery.

Hemostasis can be attained by a multitude of devices or techniques. Bipolar cautery, monopolar cautery, ultrasonic instrumentation, vessel sealing devices, ligasure, enseal, titanium clips, locking clips, and hemostatic agents are examples of these. We use monopolar and bipolar cautery, surgical, fibrin glue, titanium clips and locking clips. For the iliac vein injury, a titanium clip applied tangentially so as not to completely occlude the vessel proved to be simple and effective, averting conversion or intracorporeal suturing.

This is reminiscent of an issue encountered in pure laparoscopy- non-targeted tissue burns secondary to insulation failure or capacitive coupling. Many attempts to replace monopolar electro-surgery for laparoscopic dissection with lasers, bipolar electro-surgical instruments and ultrasonic energy probes have been made. However, these devices are slower, less versatile and more expensive than the former.

Active Electrode Monitoring system has been developed to minimize the risk of non-targeted tissue burns, and it provides safety by combining added electrical insulation, conductive shielding, and an electronic current monitoring system. Stray currents are absorbed by additional electrical insulation and conductive shielding.⁴ This technology may be adapted for robotic instrumentation to prevent unwanted tissue burns.

Many reports have cited the Da Vinci system to be very reliable. University of Chicago experience for robotic prostatectomy device failure resulted in case conversion; procedure abortion and surgeon handicap in 0, 0.5%, and 0.4% of procedures, respectively.¹ A multi-institution study conducted by Dr. Lavery and his associates² showed that critical robotic equipment malfunction is extremely rare in institutions that perform high volumes of robotic prostatectomies, with a nonrecoverable malfunction rate of only 0.4%.

Commonly, it is the robotic arms that encounter problems as reported by Koliakos, et al.¹ There is no report on problems encountered with accessories which are often disregarded but play crucial roles in the course of surgery. As shown in this case, two unnecessary vascular injuries would have been avoided if the tip cover was intact. Consequences could have been even more severe if bowel or large arteries were injured.

Despite the reliability of the da Vinci Surgical System®, there should always be a degree of precautionary care in its use. It is more so when injuries arise from areas not directly involved in the dissection, and immediate inspection of the instruments should be done. As preventive measure, the Tip Cover™ should always be in view during dissection. So doing, any sign of dissipating electric current can be identified. Furthermore, if an injury had occurred, it would immediately be recognized.

ACKNOWLEDGEMENTS

This study was supported by a grant of the Korea Healthcare technology R&D Project, Ministry for Health, Welfare & Family Affairs, Republic of Korea (A084120).

REFERENCES

1. Koliakos N, Denaeyer G, Willemsen P, Schatteman P, Mottrie A. Failure of a robotic arm during da Vinci prostatectomy: a case re-

- port. *J Robot Surg* 2008;2:95-6.
2. Lavery HJ, Thaly R, Albala D, Ahlering T, Sholha A, Lee D, et al. Robotic equipment malfunction during robotic prostatectomy: a multi-institutional study. *J Endourol* 2008;22:2165-8.
 3. Zorn KC, Gofrit ON, Orvieto MA, Mikhail AA, Galocy RM, Shalhar AL, et al. Da Vinci robot error and failure rates: single institution experience on a single three-arm robot unit of more than 700 consecutive robot-assisted laparoscopic radical prostatectomies. *J Endourol* 2007;21:1341-4.
 4. Vancaille TG. Active electrode monitoring. How to prevent unintentional thermal injury associated with monopolar electro-surgery at laparoscopy. *Surg Endosc* 1998;12:1009-12.