

CASE REPORT

Acute kidney injury secondary to chlorine dioxide use for COVID-19 prevention

Ernesto Medina-Avitia¹ | Pamela Tella-Vega² | Christian García-Estrada¹ 

¹Internal Medicine Department, General Hospital "Santiago Ramon y Cajal" ISSSTE Durango, Durango, Mexico

²Department of Clinical Epidemiology Research, National Institute of Geriatrics, Mexico City, Mexico

Correspondence

Christian García-Estrada, Internal Medicine Department, General Hospital "Santiago Ramon y Cajal" ISSSTE Durango, Predio Canoas, Durango, Mexico.
Email: christianalan.cg@gmail.com

Abstract

Chlorine dioxide has been historically used as a disinfecting agent for drinking water supplies and surfaces. Widespread use as an alternative option for prevention and treatment of COVID-19 has emerged due to a lack of specific treatment. We present the case of a 55-year-old male who developed acute kidney injury and disseminated intravascular coagulation after chlorine dioxide prophylactic ingestion, with regression after therapy with hemodialysis.

KEYWORDS

acute kidney injury, chlorine dioxide, COVID-19, hemodialysis

INTRODUCTION

Chlorine dioxide has been historically used as a disinfecting agent for drinking water supplies resulting in a dramatic impact on the incidence of cholera, dysentery, and typhoid fever dissemination thorough the 70s and 80s.^{1–3} It has also been used for bleaching textiles, antimicrobial applications, reducing loads of adsorbable organic halogenated compounds in industrial effluents.⁴ Since the emergence of severe acute respiratory syndrome coronavirus 2 (SARS-Cov-2) pandemic, chlorine dioxide has come into widespread use as a potential treatment or prevention option despite the absence of evidence regarding safety and efficacy. Here, we present a case of a patient presenting with acute kidney injury (AKI) due to chlorine dioxide ingestion.

CASE PRESENTATION

A 55-year-old male with a clinical history of hypertension and type 2 diabetes attended the emergency department after consumption of chlorine dioxide. The patient decided ingestion of a nonspecified dilution

as prevention for COVID-19 and after 5 days he developed nausea, vomiting, and altered mental state; no fever, dyspnea, or other symptoms were referred. Initial examination showed dehydration and inattention. No edema was found. Initial work-up reported glucose of 640 mg/dl serum creatinine of 4.6 mg/dl, blood urea of 236 mg/dl, hemoglobin of 12.3 g/dl, total leucocyte counts 4100/mm³, and platelet count 36,000/mm³, elevated prothrombin time (PT), INR (1.4), and D-dimer (15.43 mg/L), consistent with the diagnosis of disseminated intravascular coagulation (DIC). Peripheral smear was normal, methemoglobin levels were not available. Metabolic acidosis with secondary respiratory alkalosis was found. Hepatic function was remarkable. Chest X-ray and brain CT-scan were normal. No infectious etiologies were identified. The patient persisted with disorientation and progressed to anuria despite intravenous fluids and diuretic therapy after 48 h. He received one session of hemodialysis (HD) with decreased serum creatinine to 1 mg/dl and blood urea to 73 mg/dl, as well as notable improvement in alertness and uresis. Last platelet count was 100,000/mm³. No more HD sessions were offered, and he was discharged after 6 days of hospitalization (Figure 1).

FIGURE 1 Serum creatinine and blood urea over time

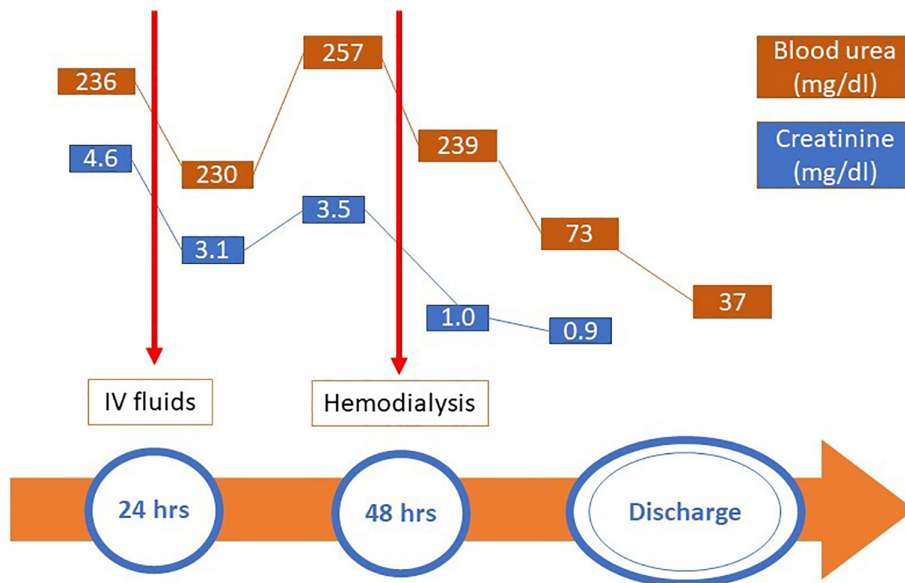


TABLE 1 Literature reported cases chlorine compound poisoning

References	Gender	Age (years)	Chlorine compound	Dose	Clinical findings	Notes
13	M	25	Sodium chlorite	10 g	Altered mental status	mHB 56%, acute tubulointerstitial nephritis on kidney biopsy. Complete recovery of renal function.
14	M	42	Sodium chloride	27 g	Abdominal pain, diarrhea and arterial hypotension	SC 3.2 mg/dl. Received 11 HD sessions. Developed DIC.
15	M	20	Chlorine dioxide	250 ml	Anuria	SC was 7.2 mg/dl. Renal biopsy showed features of ATN.
16	M	65	Sodium chlorite	NA	Nausea, vomiting, diarrhea, mild confusion and anuria	SC 1.6 mg/dl, K 5.5 mmol/L, mHB 6.7%. Developed hemolysis; received CVVH.
17	M	45	Sodium chlorite	100 ml	Cyanotic, lowered consciousness, vomiting and incontinence	Hemolytic anemia, DIC, bronchopneumonia and sepsis, mHB 40%. Received 16 HD sessions.

Abbreviations: ATN, acute tubular necrosis; CVVH, continuous venovenous hemofiltration; DIC, disseminated intravascular coagulopathy; HD, hemodialysis; mHB, methemoglobin; NA, not available; SC: serum creatinine.

DISCUSSION

Chlorine dioxide is a very attractive alternative as a disinfectant: its properties are equivalent to or even exceed those of chlorine.⁴ Chlorine dioxide does not produce the taste and odor problems that result from chloride treatment due to its lack of reaction with phenol,⁵ which makes its ingestion more tolerable when used as a water disinfectant. During SARS-Cov-2 pandemic, the absence of a specific and effective treatment has motivated the widespread use of

many off-label alternative therapies, despite the lack of evidence of its toxicity and efficacy. Recently, the FDA issued a warning letter against selling chlorine dioxide products to treat or prevent COVID-19 in adults and children.⁶ In Mexico, the Federal Commissions for the Protection against Sanitary Risks (COFEPRIS) also stated its posture against the use of chlorine dioxide.⁷

There is scarce information regarding the toxicity of chlorine dioxide, but some important side effects have been reported. Animal and in vitro models have shown

decreased red blood cell counts, half-life of erythrocytes, hemoglobin (HB) concentrations, and packed cell volume at 30 and 60 days of exposure to drinking water, at concentrations ranging from 1 to as high as 1000 mg/L.^{8–9} Previous authors have reported the ability of chlorite (ClO₂⁻) to oxidize HB to methemoglobin (mHB),¹⁰ which in turn depletes glutathione concentration (an antioxidant mechanism), increasing the levels of hydrogen peroxide (HP). This oxidative stress is the main mechanism causing lipid peroxidation, intravascular hemolysis, and cell injury.^{11–13} In addition, it was observed that chlorite (ClO₂⁻) and chlorate (ClO₃⁻) inhibit DNA synthesis in several organs.⁴ These effects tended to be reversed by 90 days. Other potentially side effects include gastrointestinal symptoms (gastric mucosa represents the first barrier defense mechanism) such as nausea, vomiting, and abdominal pain. Intravascular hemolysis¹³ and acute myocardial damage have also been reported.¹⁴

Regarding kidney injury, only case reports of chloride-compounds toxicity have been published. Lin and Lim reported the case of a 25-year-old male who developed AKI after sodium chlorite poisoning with features of acute tubulointerstitial nephritis on kidney biopsy, and complete recovery of renal function.¹⁵ Raghino et al. reported acute sodium chlorate poisoning in a 45-year-old male with AKI due to methemoglobinemia.¹⁶ Bathina et al. found features of acute tubular necrosis on renal biopsy of a 20-year-old man who presented with anuria following consumption of 250 ml of stable chlorine dioxide.¹⁷ The most recent case is a 55-year-old man who attempted suicide by ingesting <100 ml of 28% sodium chlorite; the patient developed hemolytic anemia and DIC, which were treated with red blood cell transfusion and intermittent hemodialysis, leading to recovering of his condition.¹⁸ Table 1 resumes reported cases of AKI related to chloride compounds. As in previous reports, our patient developed CID associated with chlorine dioxide consumption, no hemorrhagic complications were observed, and the normalization of levels of platelets, fibrinogen, and PT was achieved after hemodialysis session.

The exact cause of AKI secondary to chlorine compounds poisoning is unknown, but some mechanisms are remarkable: the “oxidative stress” causes excessive production of reactive oxygen species (ROS), which finally lead to cell injury in the form of ATN. Methemoglobinuria, direct proximal tubular toxicity, and vasoconstriction are others possible mechanisms related to AKI.

CONCLUSION

The absence of specific therapy in the COVID-19 pandemic has induced the widespread use of alternative

therapies for prevention and treatment of this infection. The main risk of this practice is the lack of evidence regarding safety and efficacy of these “natural” compounds and the absence of controlled and standard administration. Thus, emerging side effects are expected and physicians must be aware of these complications. This case illustrates AKI and DIC after chloride dioxide intoxication.

CONFLICT OF INTEREST

All authors declare no competing interests or external funding.

ETHICAL STATEMENT

This article does not contain any studies with human participants or animals performed by any of the authors. Ethical approval was obtained from the ethics committee. Written consent was obtained from the patient.

ORCID

Christian García-Estrada  <https://orcid.org/0000-0002-0668-0567>

REFERENCES

1. Smith RP, Willhite CC. Chlorine dioxide and hemodialysis. *Regul Toxicol Pharmacol.* 1990;11:42–62.
2. Couri D, Abdel-Rahman MS, Bull RJ. Toxicological effects of chlorine dioxide, chlorite and chlorate. *Environ Health Perspect.* 1982;46:13–7.
3. Enger M. Treatment of water with chlorine dioxide to improve the taste. *Gass Wasser Fach.* 1960;14:330–6.
4. Heffernan WP, Guion C, Bull RJ. Oxidative damage to the erythrocyte induced by sodium chlorite, in vivo. *J Environ Pathol Toxicol.* 1979;2:1487–99.
5. Moore G, Calabrese EJ. The effects of chlorine dioxide and sodium chlorite on erythrocytes of a/J and C57L/J mice. *J Environ Pathol Toxicol.* 1980;4:513–24.
6. Coronavirus (COVID-19) Update: FDA Warns Seller Marketing Dangerous Chlorine Dioxide Products that Claim to Treat or Prevent COVID-19 [Internet]. US Food and Drug Administration: April 8, 2020. [cited 2021 Feb 1]. <https://www.fda.gov/news-events/press-announcements/coronavirus-covid-19-update-fda-warns-seller-marketing-dangerous-chlorine-dioxide-products-claim>
7. La COFEPRIS informa sobre el riesgo que representa el uso de la sustancia denominada dióxido de cloro o solución mineral milagrosa (SMM). Comisión Federal para la Protección contra Riesgos Sanitarios: July 23, 2020. [cited 2021 Feb 1]. <https://www.gob.mx/cofepris/es/articulos/comunicado-a-la-poblacion-248797?idiom=es>
8. Abdel-Rahman MS, Couri D, Bull RJ. Toxicity of chlorine dioxide in drinking water. *J Environ Pathol Toxicol Oncol.* 1985;6:105–13.

9. Musil J, Kontek Z, Chalupa J, Schmidt P. Toxicological aspects of chlorine dioxide application for the treatment of water containing phenol. *Chem Technol Praze*. 1964;8:327–45.
10. Jandl JH, Engle LK, Allen DW. Oxidative hemolysis and precipitation of hemoglobin. I. Heinz body anemias as an acceleration of red cell aging. *J Clin Invest*. 1960;39:1818–36.
11. Cohen G, Hochstein P. Generation of hydrogen peroxide in erythrocytes by hemolytic agents. *Biochemistry*. 1964;3:895–900.
12. Kiese M. *Methemoglobinemia: a comprehensive treatise*. Cleveland: CRC Press; 1974.
13. Kishan H. Chlorine dioxide-induced acute hemolysis. *J Med Toxicol*. 2009;5:177.
14. Zhao M, Wang Y. One case of myocardial damage due to chlorine dioxide poisoning. *Zhonghua Lao Dong Wei Sheng Zhi Ye Bing Za Zhi (Chinese)*. 2005;23(6):470.
15. Lin JL, Lim PS. Acute sodium chlorite poisoning associated with renal failure. *Ren Fail*. 1993;15:645–8.
16. Ranghino A, Costantini L, Deprado A, Filiberti O, Fontaneto C, Ottone S, et al. A case of acute sodium chlorate self-poisoning successfully treated without conventional therapy. *Nephrol Dial Transplant*. 2006;21:2971–4.
17. Bathina G, Yadla M, Burri S, Enganti R, Prasad Ch R, Deshpande P, et al. An unusual case of reversible acute kidney injury due to chlorine dioxide poisoning. *Ren Fail*. 2013;35:1176–8.
18. Romanovsky A, Djogovic D, Chin D. A case of sodium chlorite toxicity managed with concurrent renal replacement therapy and red cell exchange. *J Med Toxicol*. 2013;9:67–70.

How to cite this article: Medina-Avitia E, Tella-Vega P, García-Estrada C. Acute kidney injury secondary to chlorine dioxide use for COVID-19 prevention. *Hemodialysis International*. 2021;25: E40–E43. <https://doi.org/10.1111/hdi.12941>