

Skin Rejuvenation with Cultured Melanocyte and Fibroblasts in a Medical Tourism Patient

Atefeh Shahbazi ¹, Seyed Jalal Zargar ^{1*}, Samin Sedaghat ¹

1. Department of Cell & Molecular Biology,
School of Biology, College of Science,
University of Tehran, Tehran, Iran

ABSTRACT

Medical tourism is speedily turning into a global and lucrative industry. Development of medical tourism market by using novel cell therapy procedures in Iran, is a profitable way that would lead to prevention of the work force migration from Iran. We aimed at examining effect of autologous fibroblast injection in an Iraqi patient who suffered from chronic wounds. A 24-year-old male from Iraq with different kinds of dermal deformities in his face, received third passage of autologous cultured fibroblast via three injections after 4-5 weeks. Percentage of cell viability before each transplantation was assessed. Before and after transplantation, the photographs were checked. After transplantation, the patient satisfaction was investigated. Obtained results showed that cell viability in the first transplantation was $97.8 \pm 3.5\%$ while in the second and third injections it was $92.8 \pm 12.2\%$ and $93.3 \pm 10.1\%$, respectively. After the first transplantation, patient satisfaction was 30%, after the second transplantation it was 50% and at the end, it was 70%. No serious adverse reactions were observed during the study. Autologous fibroblast transplantation is a promising approach with long-lasting corrective ability and negligible side reactions. It should be noted that our equipment and laboratories at the same level as those available in developed countries. Iran has a high potential for competing with other countries in attracting medical tourists for regenerative medicine.

KEYWORDS

Medical Tourism; Cell Therapy; Fibroblast

Please cite this paper as:

Shahbazi A, Zargar SJ, Sedaghat S. Skin Rejuvenation with Cultured Melanocyte and Fibroblasts in a Medical Tourism Patient. *World J Plast Surg.* 2022;11(3):116-121.

doi: 10.52547/wjps.11.3.116

*Corresponding Author:

Dr. Seyed Jalal Zargar, Ph.D.

Department of Cell & Molecular Biology,
School of Biology, College of Science,
University of Tehran,
Tehran, Iran

Tel.: + 98 21 61113646

Email: zargar@ut.ac.ir

Received: 11 Dec 2021

Accepted: 29 Jun 2022

INTRODUCTION

Medical tourism is defined as any type of travelling with the purpose of preserving and improvement physical or psychological health. Health tourism is a novel effective, and competitive industry, which includes medical tourism ^{1,2}, recovery tourism and preventive tourism low cost, modern treatments which are not available in the home lands (e.g. stem cell therapy), tourism and vacations, privacy and confidence, permissive and unenforced laws of the destination country, are reasons that medical tourists initiate worldwide journeys ^{3,4}. The unique combination of having natural resources, strategic location in south west Asia, tourism attractions, low cost and high quality of medical equipment, modern



and advanced medical procedures especially in the field of cell therapy, professional medical staffs and capable medical professionals attracts patients to Iran for purposes treatments ^{2, 5}. Besides, our country has similar trends to other countries that stand out in their region like the United States in North America, Sweden in Europe and India in Asia in terms of tourist medical therapy. These countries developed modern clinics in cell therapy and applied it against various diseases and cosmetic ⁶⁻⁸.

Stem cell therapies suggest beneficial solutions for treatment of a wide range of diseases that cannot be efficaciously treated by conventional therapies. Stem cells therapeutic effects were investigated for treatment of defective tissues (e.g. wounds) and it was found that their beneficial effects are mediated via two critical mechanisms, replacement with cell dysfunction and releasing bioactive factors which rehabilitate viability and function of scars and extensive and deep burn wounds ⁹. One of these treatments is skin regeneration by using fibroblast transplantation in wounds. This treatment is really helpful for people who suffer from such conditions. Increased number of fibroblasts in the vicinity of scar, provided by fibroblast transplantation procedure, accelerates and improves tissue regeneration¹⁰⁻¹⁴. This study intends to identify and analyze the determinants of medical tourism in cell therapy and fibroblast transplantation in an Iraqi soldier, who suffered from skin injury and deformities resulted in war. To this end, first, the Iraqi patient agreed and signed the provided written informed consent. Next, location of scars and injuries was checked and recorded by photography and findings were

compared with those obtained after transplantation of fibroblast cells ¹⁵.

Fibroblast cells contribute to skin regeneration through multiple functions like inducing growth and differentiation of keratinocyte, elaborating extra cellular matrixes (ECM) molecules, participation in basement membrane formation and stimulation of angiogenesis that are important for normal skin homeostasis, wound contraction and participating in long-term protein repair processes that help to sustain the corrective effect. These functions depend on the release of various cytokines and growth factors by fibroblast cells ¹⁶. In this area, people with various kinds of skin deformities such as different types of skin disorders, refer to Helal Iran Pharmaceutical and Medical Complex) Tehran, Iran (Clinic ^{17, 18}.

CASE PRESENTATION

A 24-year-old male from Iraq, was injured in a recent war in 2015 and most parts of his face were injured in the war by different sorts of weapons. The patient had serious trauma in his body, especially different kinds of dermal deformities and injuries in the face (Figure1). He reported he was seeking for improvement of facial rhytids or removed facial scars and he was referred to the dermatology and facial plastic surgery clinics in clinical and pharmaceutical complex of Helal Iran. The patient had no history of autoimmune disease, chronic skin disorders, disseminated cancer, or organ transplantation (which excluded a participant from the study). The patient presented with prominent glabellar lines, perioral rhytids, nasolabial folds, and depressed

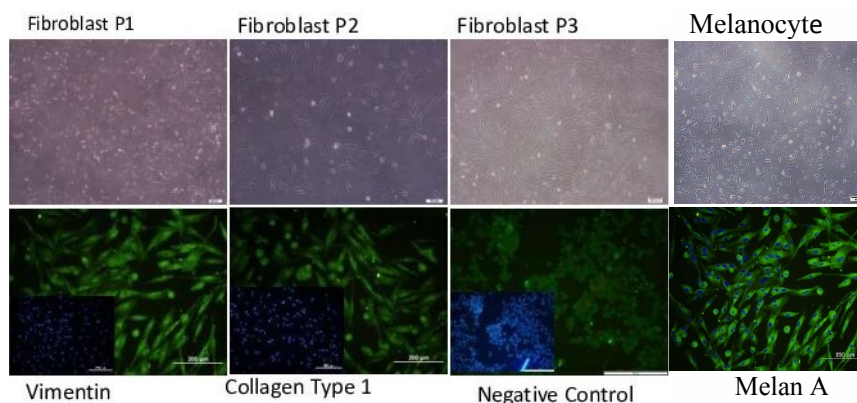


Figure 1: The fibroblasts showed a spindle-shaped morphology in culture. Immunostaining of cultured fibroblasts showed high-level expression of Vimentin and Collagen Type I Melanocyte showed high level expression of Melan A. We assessed karyotypes of passage-3 fibroblasts And cultured melanocyte for genomic stability.

facial scars. A study site was chosen, and its surface was measured and recorded with respect to a nearby facial anatomical landmark (e.g., lateral canthus or oral commissure). Patient excluded that had a history of laser treatment, immune-suppressive therapy, retinoid derivatives, botulinum toxin or temporary fillers during the past 6 months; history of organ transplantation or blood transfusion; any known cancer; known chronic disease; genetic fibroblast or collagen production disorder; permanent or semi-permanent fillers; allergy to animal collagen or its products; sensitivity to local anesthesia; hepatitis B, hepatitis C or HIV.

Ethics considerations

Ethical approval to report this case was obtained from The Institutional Review Board and Ethics Committee of Helal Iran Pharmaceutical and Medical Complex, Tehran, Iran (IR.SBMU.REC.1400.030). This patient provided written informed consent at Helal Iran Pharmaceutical and Medical Complex, Tehran, Iran.

Determination of population doubling time (PDT) of Human Melanocytes in Culture

We assessed the population doubling time (PDT) in each protocol by seeding melanocytes and fibroblast from passage tree, 10^4 cells per well in 12-well culture plates. PDT was calculated according to the following formula:

$$\text{PDT} = \text{culture time (CT)} / \text{PDN}$$

Where $\text{PDN} = \log N / N_0 \times 3.31$, N = Cell count at the end of the calculation period and N_0 = Cell count at the culture initiation

Cell preparation and injection technique

Mixed cells containing fibroblast cells and cultured melanocyte cells were isolated from left retroauricular site and cultured in Helal Iran Clean Room as previously described. briefly the full thickness skin pieces were taken from left retroauricular site was treated with 1.2 U/ml Dispase II solution (Gibco, 17105-041) for 15–18 hours at 4 °C and then, 0.1% collagenase type I (Sigma, C0130) for 4 hours at 37 °C in Hanks' balanced salt solution (HBSS, Gibco, 14185) to facilitate removal dermis layer from skin specimen and releasing cells from this layer. The isolated cells cultured and After

4-5 weeks, passage-3 cultured cells of $95 \pm 17 \times 10^6$ and $104 \pm 15 \times 10^6$ in wrinkle and acne scar groups, respectively were collected and divided in three equal parts of $65\text{--}152 \times 10^6$ cells as previously described. The first fresh part of the cells was injected and each ml of injection solution contained $5\text{--}15 \times 10^6$ cells. Then, 0.1 ml of the injection solution was injected by a dermatologist through a 30-gauge needle into the superficial and middle dermis layers of each centimeter of wrinkle sites or cm^2 of acne scar sites. The other two parts of the cells were frozen for the later injection as previously described.

Immunofluorescence staining

Cultured fibroblasts and cultured melanocyte cells were fixed using 4% freshly buffered paraformaldehyde, then rinsed with PBS and incubated with 10% goat serum, the cells incubated with primary antibody mouse anti-vimentin diluted 1:100 (Millipore; MAB1687) and anti-collagen type 1 diluted in 1:50 (Abcam; ab90395) in PBS. The cells were rinsed with PBS and bound antibodies were detected using fluorescein isothiocyanate (FITC), conjugated mouse IgM (Sigma; F9259), and conjugated anti-mouse IgG (Sigma; F9006) for 60 minutes at room temperature. Nuclei were counter-stained with 5 $\mu\text{g}/\text{ml}$ 4',6-diamidino-2-phenylindole (DAPI). Finally, the cells were observed and analyzed by confocal laser scanning fluorescence microscopy (Nikon, Tokyo, Japan).

Karyotyping

When cells reached a confluence of 70%, Colcemid® (10 $\mu\text{g}/\text{ml}$) was added to each flask at a final dilution of 25 $\mu\text{l}/\text{ml}$ and then incubated at 37 °C for 45 minutes. Changes in cell morphology were monitored using an inverted microscope until the fibroblasts were detached. For the hypotonic treatment, 13 ml of 0.056% KCl with distilled water, was carefully added, and incubated at 37 °C for 11 minutes and then, slides were fixed with methanol: acetic acid (3:1) solution. In order to obtain G-bands, the slides were kept at 60 °C overnight. The staining procedure was carried out using Giemsa (1:10). Next, 15 metaphases were analyzed. Before printing out each karyotype and counting each chromosome by writing a number on each sister chromatid pair, the slides were observed under a light microscope at 10x and 100x magnifications.

RESULTS

After 4-5 weeks, fibroblasts and melanocytes of third passage were collected. Cells showed a spindle-shaped morphology in culture. Cell viability in the first transplantation was 97.8 ± 3.5 % while in the second and third injections, was 92.8 ± 12.2 % and 93.3 ± 10.1 %, respectively. Immunostaining of cultured fibroblasts showed high-level expression of vimentin and collagen type 1 and cultured melanocytes showed expression of melan A (Figure 1). We assessed karyotypes of fibroblasts and melanocytes in third passages for genomic stability. Our observation showed normal 45XY karyotypes in this patient, with no evidence of abnormality (Figure 2). Before and after transplantation, the photographs were checked. It was found that after the first transplantation, the patient satisfaction was 30%, after the second transplantation it was 50%, and at the end, it was 70% (Figure 3).

DISCUSSION

We found that cost and quality had the greatest impact on attracting the medical tourists around the world. Marketing and public sector policy-making had positive but relatively small effects on attracting medical tourists to Iran. Private hospitals have to maintain their equipment and technology at similar or higher levels compared to those available in developed countries.

This investigation indicates that Iran has potential opportunities for competing in the medical tourism market. Health tourism is increasingly growing in the developing countries like Iran because of globalization tendency and economic unenforced regulation in health services. In our study, we used one of the more advanced cell therapy procedures, autologous fibroblast injection, for treatment of face scars¹⁹⁻²¹. Our results demonstrated improvement of regeneration of dermal tissue was associated

Cultured Melanocyte and Fibroblast karyotype



Figure 2: Our observation showed normal 45XY karyotypes in this patient, with no evidence of abnormality.

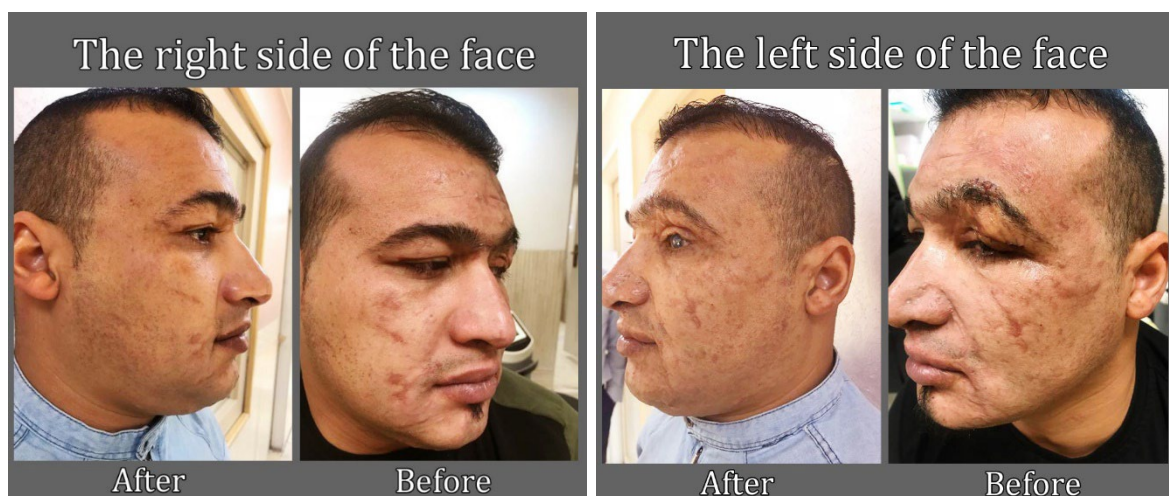

Figure 3: Photographs taken before and after the injection (Left and right sides). Pictures demonstrated improvement of regeneration of dermal tissue and autologous fibroblast and melanocyte injections produce safe and efficient improvements of dermal defects.

with higher number of fibroblasts and melanocytes present in the vicinity of chronic wounds and autologous cells injection produce safe and efficient improvements of dermal defects²²⁻²⁴. In fact, younger and freshly prepared fibroblasts compared to older and cultured ones, have shorter replication time, they are more responsive to growth factors and possess faster migration. Undoubtedly satisfaction of the present patient from our modern procedure and unique qualities of health services, physicians and laboratories in the Helal Iran Hospital, could lead to attraction of more medical tourists to Iran. Cellular therapy treatment is costly and if it is provided at lower costs, it will attract medical tourists. Finally, development of health tourism^{25, 26} for modern procedures like cell therapy, can result in retention of money and work forces in Iran and attract medical tourists.

CONCLUSION

Medical tourism has captured the interest of the social media on health tourism are being published and produced with increasing frequency, according to medical tourism is increasingly growing in the developing countries. Undoubtedly satisfaction of the patient from our modern procedure and unique qualities of health services, physicians and laboratories, could lead to attraction of more medical tourists to Iran. The more important idea is development of health tourism for modern procedures like cell therapy, can result in retention of money and work forces in Iran and attract medical tourists.

ACKNOWLEDGEMENTS

We express our appreciations to all members of the Dermatology Department at Helal Iran Pharmaceutical and Medical Complex for their helpful consultations during this work. We would like to particularly thank the patient and his family for participating in this study.

FUNDING

This study was funded by a grant from Helal Iran Pharmaceutical and Medical Complex, Tehran, Iran. (The Grant Number is 171-00099) and the ethical Code is: (IR.SBMU.REC.1400.030).

COMPETING INTERESTS

The authors declare that they have no competing interests.

REFERENCES

1. Beland D, Zarzeczny A. Medical tourism and national health care systems: an institutionalist research agenda. *Global Health* 2018;**14**(1):68.
2. Horowitz MD, Rosensweig JA. Medical tourism--health care in the global economy. *Physician Exec* 2007;**33**(6):24-6, 8-30.
3. Gunter KC, Caplan AL, Mason C, Salzman R, Janssen WE, Nichols K, et al. Cell therapy medical tourism: time for action. *Cytotherapy* 2010;**12**(8):965-8.
4. Jabbari A, Delgoshaei B, Mardani R, Tabibi SJ. Medical tourism in Iran: Issues and challenges. *J Educ Health Promot* 2012;**1**:39.
5. Mousavi SM, Haghi M, Gharasi Manshadi M. Health Tourism in Iran: A Path towards Sustainable Development. *Iran J Public Health* 2016;**45**(2):274-5.
6. Aramesh K. A Brief History of Biomedical Research Ethics in Iran: Conflict of Paradigms. *Dev World Bioeth* 2015;**15**(2):107-12.
7. Lyons S, Salgaonkar S, Flaherty GT. International stem cell tourism: a critical literature review and evidence-based recommendations. *Int Health* 2022;**14**(2):132-41.
8. Connolly R, O'Brien T, Flaherty G. Stem cell tourism--a web-based analysis of clinical services available to international travellers. *Travel Med Infect Dis* 2014;**12**(6 Pt B):695-701.
9. Leggat P. Medical tourism. *Aust Fam Physician* 2015;**44**(1-2):16-21.
10. Zhao Y, Wang J, Yan X, Li D, Xu J. Preliminary survival studies on autologous cultured skin fibroblasts transplantation by injection. *Cell Transplant* 2008;**17**(7):775-83.
11. Wong T, McGrath JA, Navsaria H. The role of fibroblasts in tissue engineering and regeneration. *Br J Dermatol* 2007;**156**(6):1149-55.
12. Bajouri A, Orouji Z, Taghiabadi E, Nazari A, Shahbazi A, Fallah N, et al. Long-Term Follow-up of Autologous Fibroblast Transplantation for Facial Contour Deformities, A Non-Randomized Phase IIa Clinical Trial. *Cell J* 2020;**22**(1):75-84.
13. Ichim TE, O'Heeron P, Kesari S. Fibroblasts as a practical alternative to mesenchymal stem cells. *J Transl Med* 2018;**16**(1):212.
14. Oram Y, Turgut G. Autologous Dermal Filler Derived from Cultured Dermal Fibroblasts and Plasma Gel (Fibrogel): One-year Follow-up of a Case. *J Cutan Aesthet Surg* 2019;**12**(4):237-9.
15. Van Geel NA, Ongenaes K, Vander Haeghen YM,

- Naeyaert JM. Autologous transplantation techniques for vitiligo: how to evaluate treatment outcome. *Eur J Dermatol* 2004;**14**(1):46-51.
16. Levenstein ME, Ludwig TE, Xu RH, Llanas RA, VanDenHeuvel-Kramer K, Manning D, et al. Basic fibroblast growth factor support of human embryonic stem cell self-renewal. *Stem Cells* 2006;**24**(3):568-74.
17. Takahashi K, Okita K, Nakagawa M, Yamanaka S. Induction of pluripotent stem cells from fibroblast cultures. *Nat Protoc* 2007;**2**(12):3081-9.
18. Sobotkova V. Islamic Republic of Iran - a surprisingly progressive centre of medical tourism. *Cas Lek Cesk* 2022;**161**(3-4):159-62.
19. Zhang X, Deng Z, Wang H, Yang Z, Guo W, Li Y, et al. Expansion and delivery of human fibroblasts on micronized acellular dermal matrix for skin regeneration. *Biomaterials* 2009;**30**(14):2666-74.
20. Li Y, Jiang QL, Van der Merwe L, Lou DH, Lin C. Preclinical efficacy of stem cell therapy for skin flap: a systematic review and meta-analysis. *Stem Cell Res Ther* 2021;**12**(1):28.
21. Lamme EN, Van Leeuwen RT, Brandsma K, Van Marle J, Middelkoop E. Higher numbers of autologous fibroblasts in an artificial dermal substitute improve tissue regeneration and modulate scar tissue formation. *J Pathol* 2000;**190**(5):595-603.
22. Lamme EN, de Vries HJ, van Veen H, Gabbiani G, Westerhof W, Middelkoop E. Extracellular matrix characterization during healing of full-thickness wounds treated with a collagen/elastin dermal substitute shows improved skin regeneration in pigs. *J Histochem Cytochem* 1996;**44**(11):1311-22.
23. Orouji Z, Bajouri A, Ghasemi M, Mohammadi P, Fallah N, Shahbazi A, et al. A single-arm open-label clinical trial of autologous epidermal cell transplantation for stable vitiligo: A 30-month follow-up. *J Dermatol Sci* 2018;**89**(1):52-9.
24. Shahbazi A, Safa M, Alikarami F, Kargozar S, Asadi MH, Joghataei MT, et al. Rapid Induction of Neural Differentiation in Human Umbilical Cord Matrix Mesenchymal Stem Cells by cAMP-elevating Agents. *Int J Mol Cell Med* 2016;**5**(3):167-77.
25. Andersson-Sjoland A, Thiman L, Nihlberg K, Hallgren O, Rolandsson S, Skog I, et al. Fibroblast phenotypes and their activity are changed in the wound healing process after lung transplantation. *J Heart Lung Transplant* 2011;**30**(8):945-54.
26. Xiao SC, Ben DF, Yang J, Tang HT, Wang GQ, Yang Y, et al. Transplantation of Composite Skin Containing Keratinocytes Cultured on a Fibroblast-conditioned Acellular Dermal Matrix. *Ann Burns Fire Disasters* 2005;**18**(4):194-6.