



# Cervical Flexor–Extensor Muscle Disparity in Monomelic Amyotrophy (Hirayama Disease): Evidence from a Comprehensive Morphometric Evaluation of Subaxial Paraspinal Musculature

Sumit Thakar<sup>1</sup> Niranjana Rajagopal<sup>1</sup> Prashanth Alle<sup>1</sup> Saritha Aryan<sup>1</sup> Alangar Hegde<sup>1</sup>

<sup>1</sup>Department of Neurological Sciences, Sri Sathya Sai Institute of Higher Medical Sciences, Bangalore, Karnataka, India

AJNS 2022;17:68–73.

Address for correspondence Sumit Thakar, MCh, Department of Neurological Sciences, Sri Sathya Sai Institute of Higher Medical Sciences, Bangalore, 560066, Karnataka, India (e-mail: sumit.thakar@gmail.com).

## Abstract

**Background** Monomelic amyotrophy (Hirayama disease) has been established to have accompanied biomechanical abnormalities such as flexion hypermobility and sagittal imbalance. Paraspinal muscles, the major contributor to cervical biomechanics, have, however, not been comprehensively evaluated in the disease. The objective of this study was to compare the morphology of the subaxial cervical paraspinal musculature in patients with and without Hirayama disease.

**Materials and Methods** A retrospective case-control study of 64 patients with Hirayama disease and 64 age- and sex-matched controls was performed. Cross-sectional areas (CSAs) of the superficial and deep flexors and extensors from C3 to C7 were measured on T2-weighted magnetic resonance imaging sequences. Student's *t*-test was used to compare differences between the paraspinal muscle CSAs in the study and control groups.

**Results** Compared with controls, patients with Hirayama disease were found to have larger flexors and smaller extensors at all levels. The overall subaxial muscle area values for superficial flexors and deep flexors were significantly larger ( $p < 0.0001$ ) in patients, while the corresponding superficial extensor and deep extensor area values were significantly smaller than in controls ( $p = 0.01$  and  $< 0.0001$ , respectively). The patient group demonstrated stronger subaxial deep flexor–deep extensor, superficial flexor–superficial extensor, and total flexor–total extensor ratios ( $p < 0.0001$ ).

**Conclusion** Patients with Hirayama disease have morphometric alterations at all levels of their subaxial cervical paraspinal musculature. These patients have abnormally large flexors and small extensors compared with controls. This flexor–extensor muscle disparity could be utilized as a potentially modifiable factor in the management of the disease.

## Keywords

- ▶ Hirayama disease
- ▶ paraspinal muscles
- ▶ morphometric
- ▶ flexor–extensor disparity

published online  
June 10, 2022

DOI <https://doi.org/10.1055/s-0042-1749111>.  
ISSN 2248-9614.

© 2022. Asian Congress of Neurological Surgeons. All rights reserved.

This is an open access article published by Thieme under the terms of the Creative Commons Attribution-NonDerivative-NonCommercial-License, permitting copying and reproduction so long as the original work is given appropriate credit. Contents may not be used for commercial purposes, or adapted, remixed, transformed or built upon. (<https://creativecommons.org/licenses/by-nc-nd/4.0/>)

Thieme Medical and Scientific Publishers Pvt. Ltd., A-12, 2nd Floor, Sector 2, Noida-201301 UP, India

## Key Message

Though the clinical manifestations of Hirayama disease are limited to the lower cervical segments, this study demonstrates morphometric alterations at all levels of the subaxial cervical paraspinal musculature. The flexor–extensor muscle disparity in these patients could be utilized as a potentially modifiable factor in the conservative management protocol of the disease.

## Introduction

Monomelic amyotrophy, commonly known as Hirayama disease (HD) or juvenile muscular atrophy of the distal upper extremities, is an unusual disorder characterized by self-limiting weakness and atrophy of the hands and forearm muscles in young male subjects.<sup>1–3</sup> Flexion-induced myelopathy is one of the widely accepted pathogenetic mechanisms,<sup>1,4,5</sup> though the exact pathogenesis of the disease remains controversial. The clinical manifestations of HD are limited to the lower cervical segments. However, recent studies have demonstrated biomechanical connotations of the disorder that relate to the entire cervical spine. Given this background and the fact that paraspinal musculature is the major biomechanical stabilizer of the cervical spine,<sup>6</sup> we postulated that patients with HD would have morphological alterations in their paraspinal muscles (PSMs). This has been previously demonstrated, though only at select lower cervical levels.<sup>7</sup> The objective of the present study was to explore if morphometric changes in HD extend to other levels of the subaxial cervical spine as well. We felt that a comprehensive evaluation of the entire subaxial cervical musculature was especially required for a condition where long-term-collar wear is a primary management protocol despite its potentially deleterious effects on PSMs and hence, on cervical biomechanics.

## Subjects and Methods

### Patient Population

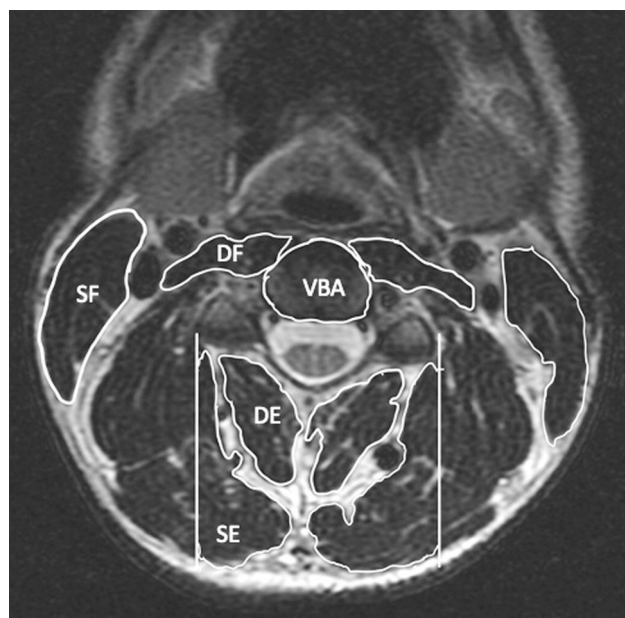
This was a single-center case–control study spanning an 8-year-period from January 2012 to January 2020. In view of the retrospective and anonymized nature of the data, the study qualified for an ethics committee waiver as per the local Institutional Review Board policy. The study group consisted of 64 consecutive patients diagnosed to have HD at our institution based on the criteria proposed by Hirayama et al<sup>8,9</sup>: weakness and wasting in the C7–T1 myotomes in one or both upper limbs, insidious onset of symptoms in the early third decade, rapid progression of symptoms from 1 to 3 years, irregular coarse tremors in the fingers of the affected hand(s), brief aggravation of symptoms on exposure to the cold, electromyographic evidence of chronic denervation in the affected muscles, and an absence of objective sensory loss. None of these patients were previously managed with collar wear for any cervical pathology, nor did they have history of prior trauma or cervical surgery.

### Control Group

Using an individual, “one-to-one” matching technique,<sup>10</sup> 64 age- and sex-matched non-HD subjects were selected as controls for comparison of their PSM morphometry with that of the study group. The controls had undergone cervical spine imaging as part of a routine neurological evaluation, and none of them had history of neck-pain, radicular pain, cervical trauma, or previous neck surgery.

### Radiographic Evaluation

The same imaging protocol was used for both, the study and control groups. Deidentified magnetic resonance (MR) images were obtained from the hospital radiographic system (Synapse, Fujifilm Medical Systems USA, Inc., Lexington, Massachusetts, United States). All images were acquired on a HDi 1.5 Tesla magnet (GE Signa, Milwaukee, Wisconsin, United States) using a standard neurovascular (NV) coil. Measurement parameters were slices, 26; slice thickness, 3.7 mm; field of view, 180 × 188 mm; repetition time (TR), 4,360 milliseconds; time to echo (TE), 98.2 milliseconds; matrix size, 1.60/256; number of excitations, 1.5; flip angle, 90 degrees. The cross-sectional areas (CSAs) of the PSMs were measured by a standardized technique using axial T2-weighted images.<sup>11,12</sup> The selected cuts were parallel to the disc spaces at the upper endplates from C3 to C7 vertebral levels. A region of interest (ROI) was created for each muscle bilaterally using the Synapse software. The lateral border of the facets was used as the lateral limit for the ROI for the superficial extensors (SEs). The CSAs of the following muscles were measured: sternocleidomastoid (superficial flexor, SF), longus colli and longus capitis (deep flexors, DFs), multifidus and semispinalis cervicis (deep extensors, DEs), and the semispinalis capitis, splenius capitis, and upper trapezius (SE) (– Fig. 1). Two independent operators (PA



**Fig. 1** T2-weighted axial magnetic resonance imaging section demonstrating the measurement of the cross-sectional area of the paraspinal muscles, with regions of interest drawn for the superficial and deep muscle groups. DE, deep extensor; DF, deep flexor; SE, superficial extensor; SF, superficial flexor; VBA, vertebral body area.

and NR) performed all the measurements, and the mean values of their measurements were used for analysis. Both the operators were blinded to the group allocation into cases and controls. To control for bias in the muscle areas due to varying body mass index, muscle CSA/vertebral body area (VBA) ratios were used rather than absolute muscle CSA values.<sup>12</sup> The mean CSA/VBA ratio at individual levels and for the entire subaxial spine were calculated for each muscle group.

### Statistical Methodology

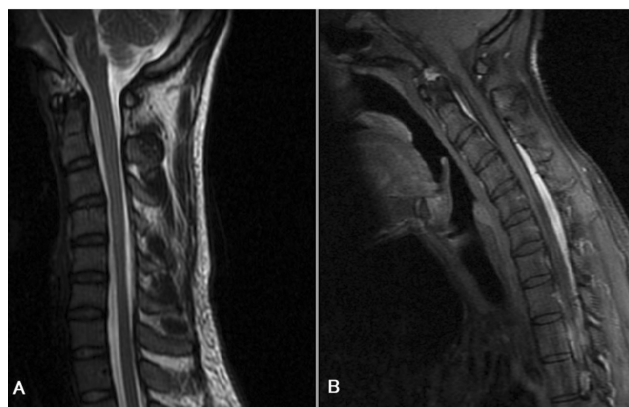
Using the clinically meaningful difference in CSA values from a previous study on cervical PSMs,<sup>12</sup> a sample size of 64 in each group was determined to be adequate to obtain a power of 0.9 for the study. Data was entered in an Excel spreadsheet (Microsoft Inc.) and analyzed using SPSS version 20. Means and standard deviations were computed for all the CSA/VBA ratios. Student's *t*-test was used to compare differences between the ratios in the study and control groups. Inter-observer variability was measured using the intraclass correlation coefficient and standardized ratings of agreement.

### Results

**Demographics and clinicoradiological presentation of the study group:** All the patients were male subjects with a mean age of  $20.49 \pm 2.87$  years. Their mean duration of symptoms was  $24.36 \pm 8.32$  months (range: 14–48 months). Forty-eight (75%) patients presented with bilateral, asymmetric weakness, or wasting of the hand and/or forearm muscles, while the remaining 16 (25%) presented with unilateral symptoms and signs. All patients demonstrated lower cervical cord atrophy on neutral MRI and forward migration of the cord with a prominent enhancing epidural venous plexus on flexion sequences (►Fig. 2).

### CSA/VBA Ratios at Individual Levels

The mean CSA/VBA ratios at individual levels from C3 to C7 for the respective muscle groups are listed in ►Table 1. Patients with HD uniformly demonstrated larger mean SF and DF CSA/VBA ratios than the controls at all levels, with the differ-



**Fig. 2** Sagittal magnetic resonance imaging: (A) T2-weighted sequence demonstrating lower cervical cord atrophy; (B) Gadolinium-enhanced flexion sequence demonstrating the characteristic enhancing venous plexus.

**Table 1** Paraspinal muscle CSAs at different cervical levels compared between cases and controls

Level	Muscle group	Mean CSA/VBA ratio		p-Value
		Cases (n = 64)	Controls (n = 64)	
C3	SF	1.14 ± 0.16	0.99 ± 0.15	< 0.0001
	DF	0.56 ± 0.08	0.45 ± 0.08	< 0.0001
	SE	0.47 ± 0.23	0.50 ± 0.21	0.44
	DE	1.14 ± 0.20	1.26 ± 0.02	< 0.0001
C4	SF	1.32 ± 0.34	1.25 ± 0.45	0.32
	DF	0.55 ± 0.10	0.47 ± 0.13	0.0002
	SE	0.63 ± 0.07	0.65 ± 0.50	0.75
	DE	1.09 ± 0.07	1.30 ± 0.07	< 0.0001
C5	SF	1.42 ± 0.01	1.33 ± 0.20	0.0005
	DF	0.45 ± 0.22	0.44 ± 0.03	0.71
	SE	0.76 ± 0.01	0.82 ± 0.19	0.01
	DE	0.97 ± 0.15	1.19 ± 0.28	< 0.0001
C6	SF	1.33 ± 0.22	1.30 ± 0.18	0.40
	DF	0.39 ± 0.19	0.34 ± 0.02	0.03
	SE	0.75 ± 0.14	0.82 ± 0.23	0.03
	DE	0.77 ± 0.05	0.92 ± 0.17	< 0.0001
C7	SF	1.28 ± 0.30	1.16 ± 0.19	0.007
	DF	0.61 ± 0.46	0.54 ± 0.29	0.30
	SE	0.62 ± 0.26	0.86 ± 0.01	< 0.0001
	DE	0.98 ± 0.11	1.06 ± 0.01	< 0.0001

Abbreviations: CSA, cross-sectional area; DE, deep extensors; DF, deep flexors; SE, superficial extensors; SF, superficial flexors; VBA, vertebral body area.

ences being significant at most levels. The extensor muscle CSA/VBA ratios, on the other hand, were smaller in HD patients than in the controls. The difference in the CSA/VBA values for the DEs in the two groups was significant at all levels.

**Overall subaxial spine CSA/VBA ratios:** Patients with HD demonstrated significantly larger mean SF and DF CSA/VBA ratios for the entire subaxial spine (►Fig. 3), while their mean SE and DF ratios were significantly smaller than those of the control subjects. The overall SF/SE, DF/DE, and total flexor/total extensor ratios were correspondingly larger in the HD patients than in the controls (►Fig. 4).

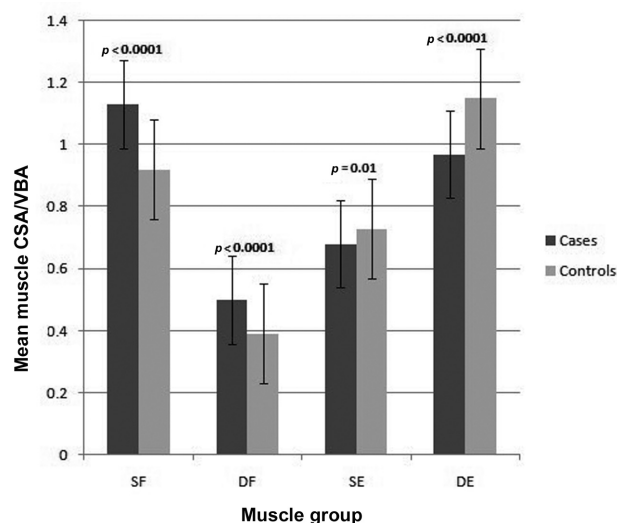
### Interobserver Variability

The agreement between the two observers for the measurement of the PSM areas ranged from substantial to almost perfect (weighted kappa coefficients: 0.78 for DF, 0.82 for SF, 0.76 for DE, and 0.85 for SE).

### Discussion

#### Biomechanical Abnormalities in HD

The repeated flexion-induced microtrauma in the lower cervical cord in HD patients has been commonly attributed



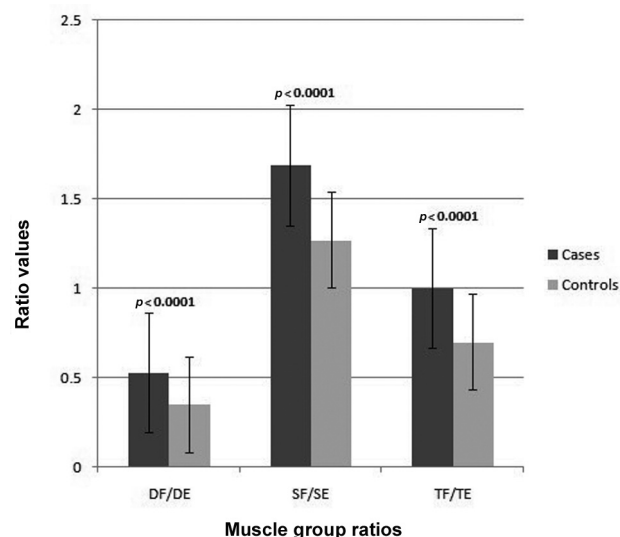
**Fig. 3** Error-bar chart demonstrating the comparison of the various paraspinal muscle cross-sectional area/vertebral body area ratios between cases and controls. DE, deep extensor; DF, deep flexor; SE, superficial extensor; SF, superficial flexor.

to factors like an inherently tight dura,<sup>13</sup> growth disparity between the spinal column and the cord,<sup>14</sup> flexion-induced venous stagnation,<sup>15</sup> and anterior osteophytes.<sup>13</sup> The role of spinal biomechanics in the pathogenesis of HD has been under-explored. Some studies have described an exaggerated range of vertebral flexion in these patients.<sup>16,17</sup> This flexional hypermobility is postulated to enhance the anterior displacement of the dural sac and aggravate cord injury and atrophy.<sup>18</sup> HD patients have also been noted to have loss of cervical lordosis and impaired sagittal balance parameters that improve after anterior cervical fixation procedures.<sup>19</sup> Instability itself has also been postulated to contribute to the disease process on the basis of accompanying findings like abnormal cervical curvatures and the presence of osteophytes<sup>20</sup> in these patients. The demonstration of altered cervical PSM morphology in our study reflects yet another biomechanical perspective to the disorder.

### Paraspinal Muscle Changes in HD

MRI-based measurement of CSAs of muscles is a robust proxy measure of muscle strength.<sup>21</sup> It has been found to be a reliable indicator of muscle atrophy and weakness, with excellent intra- and interobserver agreement.<sup>22–24</sup> With respect to HD, Li et al<sup>7</sup> had analyzed CSAs of cervical PSMs at two levels and had concluded that HD patients have smaller muscle areas compared with controls, and that there is an imbalance between the SF and SE CSAs. These findings were taken to reflect an underlying biomechanical instability. The findings of the study were, however, not generalizable to the entire subaxial spine as the measurements were restricted to limited levels in the lower cervical spine where PSM changes could have occurred as a direct consequence of anterior horn cell dysfunction.

The comprehensive PSM area measurements in our study demonstrate that the paraspinal morphometric alterations in HD extend to all levels of the subaxial cervical spine.



**Fig. 4** Error-bar chart demonstrating the comparison of various flexor–extensor cross-sectional area ratios between cases and controls. DE, deep extensor; DF, deep flexor; SE, superficial extensor; SF, superficial flexor; TE, total extensor; TF, total flexor.

Li et al's<sup>7</sup> conclusion of all cervical PSMs being uniformly smaller in HD patients is not borne out by our data. We found that while the subaxial extensor muscles in HD patients are indeed smaller, their flexor PSMs are uniformly larger than those of controls. This was found to be true for both the superficial and deep muscle groups. Interestingly, the flexor–extensor muscle disparity was noted to occur at all subaxial levels in a condition that primarily affects the C7–T1 myotomes, indicating that the biomechanical derangements in HD are pan-cervical.

### Muscle Group Co-contraction and Disparity

While the superficial cervical muscles are understood to assist predominantly in voluntary neck movements, the deep muscles control segmental motion and maintain cervical alignment. However, all motions of the cervical spine occur as a result of a delicate interplay of the flexors and extensors of the superficial and deep muscle groups. This co-contraction of different muscle groups stiffens the spine and contributes to its static and dynamic stability.<sup>25–28</sup> Impaired co-contraction of the flexors and extensor muscles under different movement conditions has been linked to the occurrence of various neck disorders<sup>29,30</sup> including HD.<sup>7</sup>

The possibility of a flexor–extensor disparity in HD was previously considered on the basis of a large SF/SE CSA ratio that was taken to imply a more pronounced hypotrophy in the extensors than the flexors.<sup>7</sup> Though other studies in HD have not directly alluded to this disparity, some did report loss of cervical lordosis<sup>31,32</sup>—a finding that intrinsically suggests the existence of weak extensors.<sup>33</sup> Our study confirms the existence of a flexor–extensor PSM disparity across all subaxial levels in HD. The larger flexor–extensor ratios in our study are not due to varying degrees of a generalized hypotrophy as reported previously,<sup>7</sup> but due to larger flexors and smaller extensors than those of the normal population.

### Implications of This Study

This study has potential implications in modifying the conservative treatment protocol for HD, currently restricted to long-term immobilization with a cervical collar. Patient compliance with this modality is poor in view of the prescribed requirement of continuous collar-wear for a minimum of 2 years.<sup>34–36</sup> This approach also carries the risk of causing disuse PSM atrophy in spines that are biomechanically unsound to begin with.

Our data has established a generalized subaxial cervical flexor–extensor disparity in HD patients. With the current analysis, it is difficult to comment on whether the larger flexors and smaller extensors in HD patients have a cause or effect relationship with the disease and its proposed pathogenetic mechanisms. Either way, it would be worth exploring whether the pronounced flexor–extensor disparity in these patients is modifiable by approaches such as extensor muscle strengthening, muscle co-contraction retraining, and postural re-education.<sup>37</sup> Such targeted physiotherapy protocols could unfold a more physiological method of managing HD and potentially help in arresting the clinical course of the disease.

### Limitations

This study is limited by the inherent disadvantages of a retrospective study, and prospective trials will help in further elucidating the interactions between PSMs and the clinical course of HD. Though MRI-based muscle CSA measurement is an appropriate marker of muscle strength, direct electromyographic evaluation of the PSMs could possibly strengthen the inferences of our study. Intraobserver agreement data for CSA measurement was not available in our study. To further strengthen the findings of the current study, it may be useful to analyze changes in muscle areas and a possible reduction of the flexor–extensor PSM disparity following conservative or surgical management of HD.

### Conclusion

Our study indicates that patients with HD have morphometric alterations at all levels of their subaxial cervical paraspinal musculature. These patients have abnormally large flexors and small extensors compared with controls. This flexor–extensor muscle disparity could be utilized as a potentially modifiable factor in the management of the disease.

#### Note

This paper was awarded the third place at the Young Neurosurgeons' session in the ACNS Autumn web seminar in November 2021.

#### Funding

None.

#### Conflict of Interest

None declared.

### References

- Hirayama K, Tokumaru Y. Cervical dural sac and spinal cord in juvenile muscular atrophy of distal upper extremity. *Neurology* 2000;54(10):1922–1926
- Tashiro K, Kikuchi S, Itoyama Y, et al. Nationwide survey of juvenile muscular atrophy of distal upper extremity (Hirayama disease) in Japan. *Amyotroph Lateral Scler* 2006;7(01):38–45
- Watanabe K, Hasegawa K, Hirano T, Endo N, Yamazaki A, Homma T. Anterior spinal decompression and fusion for cervical flexion myelopathy in young patients. *J Neurosurg Spine* 2005;3(02):86–91
- Huang YL, Chen CJ. Hirayama disease. *Neuroimaging Clin N Am* 2011;21(04):939–950, ix–x
- Lai V, Wong YC, Poon WL, Yuen MK, Fu YP, Wong OW. Forward shifting of posterior dural sac during flexion cervical magnetic resonance imaging in Hirayama disease: an initial study on normal subjects compared to patients with Hirayama disease. *Eur J Radiol* 2011;80(03):724–728
- Panjabi MM, Cholewicki J, Nibu K, Grauer J, Babat LB, Dvorak J. Critical load of the human cervical spine: an in vitro experimental study. *Clin Biomech (Bristol, Avon)* 1998;13(01):11–17
- Li Z, Zhang W, Wu W, Wei C, Chen X, Lin J. Is there cervical spine muscle weakness in patients with Hirayama disease? A morphological study about cross-sectional areas of muscles on MRI. *Eur Spine J* 2020;29(05):1022–1028
- Hirayama K. [Juvenile muscular atrophy of unilateral upper extremity (Hirayama disease)—half-century progress and establishment since its discovery]. *Brain Nerve* 2008;60(01):17–29
- Hirayama K, Tomonaga M, Kitano K, Yamada T, Kojima S, Arai K. Focal cervical poliopathy causing juvenile muscular atrophy of distal upper extremity: a pathological study. *J Neurol Neurosurg Psychiatry* 1987;50(03):285–290
- Kleinbaum DG, Sullivan KM, Barker ND. Matching—Seems Easy, But not that Easy. *A Pocket Guide to Epidemiology*. 2007:257–275
- Elliott J, Jull G, Noteboom JT, Darnell R, Galloway G, Gibbon WW. Fatty infiltration in the cervical extensor muscles in persistent whiplash-associated disorders: a magnetic resonance imaging analysis. *Spine* 2006;31(22):E847–E855
- Thakar S, Mohan D, Furtado SV, et al. Paraspinal muscle morphometry in cervical spondylotic myelopathy and its implications in clinicoradiological outcomes following central corpectomy: clinical article. *J Neurosurg Spine* 2014;21(02):223–230
- Kikuchi S, Tashiro K, Kitagawa M, Iwasaki Y, Abe H. [A mechanism of juvenile muscular atrophy localized in the hand and forearm (Hirayama's disease)—flexion myelopathy with tight dural canal in flexion]. *Rinsho Shinkeigaku* 1987;27(04):412–419
- Khadilkar S, Patel B, Bhutada A, Chaudhari C. Do longer necks predispose to Hirayama disease? A comparison with mimics and controls. *J Neurol Sci* 2015;359(1-2):213–216
- Ciceri EF, Chiapparini L, Erbetta A, et al. Angiographically proven cervical venous engorgement: a possible concurrent cause in the pathophysiology of Hirayama's myelopathy. *Neurol Sci* 2010;31(06):845–848
- Ding Y, Rong D, Wang X, Li C. [To evaluate the cervical spine curvature and growth rate for studying the pathogenesis of Hirayama disease in adolescents]. *Zhonghua Nei Ke Za Zhi* 2015;54(08):721–724
- Xu X, Han H, Gao H, et al. The increased range of cervical flexed motion detected by radiographs in Hirayama disease. *Eur J Radiol* 2011;78(01):82–86
- Liu X, Sun Y. The correlation analysis of the cervical spine alignment flexion ROM of adjacent segments with the spinal cord atrophy in Hirayama disease. *Zhongguo Jizhu Jisui Zazhi* 2013;23:514–519
- Song J, Cui ZY, Chen ZH, Jiang JY. Analysis of the effect of surgical treatment for the patients with Hirayama disease from the

- perspective of cervical spine sagittal alignment. *World Neurosurg* 2020;133:e342–e347
- 20 Goel A, Dhar A, Shah A. Multilevel spinal stabilization as a treatment for Hirayama disease: report of an experience with five cases. *World Neurosurg* 2017;99:186–191
  - 21 Blazeovich AJ, Coleman DR, Horne S, Cannavan D. Anatomical predictors of maximum isometric and concentric knee extensor moment. *Eur J Appl Physiol* 2009;105(06):869–878
  - 22 Okada E, Matsumoto M, Ichihara D, et al. Cross-sectional area of posterior extensor muscles of the cervical spine in asymptomatic subjects: a 10-year longitudinal magnetic resonance imaging study. *Eur Spine J* 2011;20(09):1567–1573
  - 23 Elliott JM, Jull GA, Noteboom JT, Durbridge GL, Gibbon WW. Magnetic resonance imaging study of cross-sectional area of the cervical extensor musculature in an asymptomatic cohort. *Clin Anat* 2007;20(01):35–40
  - 24 Takeuchi K, Yokoyama T, Aburakawa S, et al. Axial symptoms after cervical laminoplasty with C3 laminectomy compared with conventional C3–C7 laminoplasty: a modified laminoplasty preserving the semispinalis cervicis inserted into axis. *Spine* 2005;30(22):2544–2549
  - 25 Cheng CH, Lin KH, Wang JL. Co-contraction of cervical muscles during sagittal and coronal neck motions at different movement speeds. *Eur J Appl Physiol* 2008;103(06):647–654
  - 26 Cheng CH, Cheng HY, Chen CP, et al. Altered Co-contraction of cervical muscles in young adults with chronic neck pain during voluntary neck motions. *J Phys Ther Sci* 2014;26(04):587–590
  - 27 Lee PJ, Rogers EL, Granata KP. Active trunk stiffness increases with co-contraction. *J Electromyogr Kinesiol* 2006;16(01):51–57
  - 28 Gardner-Morse MG, Stokes IA. Trunk stiffness increases with steady-state effort. *J Biomech* 2001;34(04):457–463
  - 29 Crisco JJ, Panjabi MM, Yamamoto I, Oxland TR. Euler stability of the human ligamentous lumbar spine. Part II: Experiment. *Clin Biomech (Bristol, Avon)* 1992;7(01):27–32
  - 30 Lindstrøm R, Schomacher J, Farina D, Rechter L, Falla D. Association between neck muscle coactivation, pain, and strength in women with neck pain. *Man Ther* 2011;16(01):80–86
  - 31 Lehman VT, Luetmer PH, Sorenson EJ, et al. Cervical spine MR imaging findings of patients with Hirayama disease in North America: a multisite study. *AJNR Am J Neuroradiol* 2013;34(02):451–456
  - 32 Gupta K, Sood S, Modi J, Gupta R. Imaging in Hirayama disease. *J Neurosci Rural Pract* 2016;7(01):164–167
  - 33 Alpayci M, Şenköy E, Delen V, et al. Decreased neck muscle strength in patients with the loss of cervical lordosis. *Clin Biomech (Bristol, Avon)* 2016;33:98–102
  - 34 Agundez M, Rouco I, Barcena J, Mateos B, Barredo J, Zarranz JJ. Hirayama disease: Is surgery an option? *Neurologia* 2015;30(08):502–509
  - 35 Tokumaru Y, Hirayama K. [Cervical collar therapy for juvenile muscular atrophy of distal upper extremity (Hirayama disease): results from 38 cases]. *Rinsho Shinkeigaku* 2001;41(4–5):173–178 (Japanese)
  - 36 Fu Y, Qin W, Sun QL, Fan DS. [Investigation of the compliance of cervical collar therapy in 73 patients with Hirayama disease]. *Zhonghua Yi Xue Za Zhi* 2016;96(43):3485–3488
  - 37 Sarma AD, Devi M. Physical therapy for Hirayama disease: is the evidence bending towards or away from flexion? *Indian J Appl Res* 2019;9:40–41