

Childhood recurrent pneumonia caused by endobronchial sutures

A case report

Yiheng Zan, MD^a, Hanmin Liu, MD^{b,c}, Lin Zhong, MD^b, Li Qiu, MD^b, Qingfen Tao, MD^b, Lina Chen, MD^{b,c,*}

Abstract

Background: Recurrent pneumonia is defined as more than two episodes of pneumonia in one year or three or more episodes anytime in life. Common clinical scenarios leading to recurrent pneumonia include anatomical abnormalities of respiratory tract, immunodeficiency, congenital heart diseases, primary ciliary dyskinesia, etc.

Case report: A school-aged girl suffered from 1-2 episodes of pneumonia each year after trachea connection and lung repair operation resulted from an accident of car crash. Bronchoscopy revealed the sutures twisted with granulation in the left main bronchus and the patient's symptoms relieved after removal of the sutures. Here we report for the first time that surgical suture was the cause of recurrent pneumonia.

Conclusions: This case indicates that children with late and recurrent onset of pneumonia should undergo detailed evaluation including bronchoscopy.

Abbreviations: CT = computed tomography.

Keywords: bronchoscopy, children, recurrent pneumonia, surgical suture

1. Introduction

Recurrent pneumonia is defined as more than 2 episodes of pneumonia in 1 year or 3 or more episodes anytime in life.^[1] The morbidity is around 7% to 9% in such patients. It is reported that the common underlying diseases of childhood recurrent

pneumonia are congenital or acquired anatomical abnormalities of respiratory system, immune disorders, congenital heart diseases, primary ciliary dyskinesia, and so on.^[1-5] Endobronchial sutures are rarely considered as a fundamental cause of recurrent pneumonia in children. Here, we described a school-aged girl who suffered from recurrent pneumonia and endobronchial suture was found to be the underlying cause. In children with recurrent pneumonia, early referral for bronchoscopy should be considered for accurate differential diagnosis.

Editor: Girish Chandra Bhatt.

YZ and HL collected data, wrote and revised the manuscript. LZ, LQ, QT helped in the diagnosis and treatment of the patient. collected data. LC designed the study, collected data, wrote and revised the manuscript.

YZ and HL contributed equally to this study.

Funding: This work was supported by grant from the National Natural Science Foundation (No. 81200461) of China.

Ethical approval to report this case was not required.

Written informed consent was obtained from the parents for publication in this case report. A copy of the written consent is available for review by the Editor of this journal.

There are no additional data.

The authors declare that they have no competing interests.

^a West China Medical School of Sichuan University, ^b Department of Pediatric Pulmonology, West China Second University Hospital, Sichuan University, ^c Key Laboratory of Birth Defects and Related Diseases of Women and Children (Sichuan University), Ministry of Education, Chengdu, Sichuan, China.

* Correspondence to Lina Chen, Department of Pediatric Pulmonology, West China Second University Hospital, Sichuan University, Chengdu, Sichuan 610041, China (e-mail: chenln66@163.com).

Copyright © 2017 the Author(s). Published by Wolters Kluwer Health, Inc. This is an open access article distributed under the terms of the Creative Commons Attribution-Non Commercial License 4.0 (CCBY-NC), where it is permissible to download, share, remix, transform, and build up the work provided it is properly cited. The work cannot be used commercially without permission from the journal.

Medicine (2017) 96:4(e5992)

Received: 17 June 2016 / Received in final form: 7 December 2016 / Accepted: 4 January 2017

<http://dx.doi.org/10.1097/MD.0000000000005992>

2. Case presentation

A 12-year-old girl was admitted to West China Women and Children's Hospital of Sichuan University with the complaints of recurrent fever and cough for more than 1 month. Her highest body temperature was 39.0°C. The episodes of fever were not accompanied by chills, rigor, or rash. Her cough was occasional and dry at first, and then became more frequent and productive. The patient also had occasional dizziness without chest pain, dyspnea, or hemoptysis. She was treated in a local hospital with Amoxicillin and clavulanate potassium for 7 days, and cefoperazone sodium and tazobactam and penicillin for 2 days. But her symptoms did not improve. Then, she was referred to our hospital. It is noteworthy that the girl had encountered a car crash leading to fracture of her left ribs and mandible and rupture of the trachea 7 years ago. She received an operation to repair the broken trachea and lung. After that, she had pneumonia almost every year.

At the time of admission, the patient was afebrile, the respiratory rate was 20 breaths per minute, and oxygen saturation was 98% in ambient air. The breath sounds were harsh and neither rales nor wheezing were heard. Other physical examinations were unremarkable.

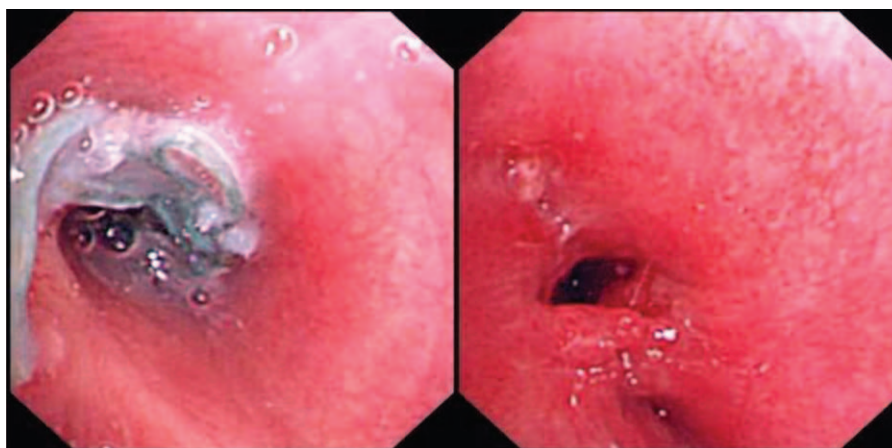


Figure 1. Bronchoscopy revealed surgical sutures in the left main bronchus, the sutures were then taken out by forceps, and the mucosa of the left main bronchus was edematous accompanied by granulation formation and the diameter of the bronchus was reduced.

The white-cell count was $10.3 \times 10^9/\text{mL}$, with 70.4% neutrophils; the hemoglobin and the platelet count were 108 g/L and $384 \times 10^9/\text{mL}$, respectively. The biochemical tests were normal.

The serum test for *Mycoplasma pneumoniae* antibody was positive with the titer of 1: 1280. Other pathogens including common respiratory viruses were not found.

Chest computerized tomography revealed stenosis or occlusion in the proximal end of left main bronchus, along with pleural effusion, consolidation, and partial atelectasis in the lower lobe of the left lung.

After admission, the girl received bronchoscopy and surgical sutures were found in the left main bronchus. The sutures were then taken out by forceps (Fig. 1). The mucosa of the left main bronchus was edematous accompanied by granulation formation, and the diameter of the bronchus was reduced. Much purulent secretions were suctioned out and the culture of bronchoalveolar lavage fluid revealed *Pseudomonas aeruginosa*. She received Piperacillin/tazobactam with much improvement of her symptoms and was discharged later.

3. Discussion

Recurrent pneumonia is defined as more than 2 episodes of pneumonia in 1 year or 3 or more episodes in a lifetime, with radiographically documented clearing episodes.^[1] Careful collection of present illness, past medical history, and selection of the appropriate accessory examination could yield the basic idea of diagnosis in children with recurrent pneumonia. Computed tomographic (CT) scan and bronchoscopy were necessary for differential diagnosis. Congenital or acquired anatomical abnormalities of respiratory system, aspiration syndrome, immunodeficiency, congenital heart diseases, primary ciliary dyskinesia are severe underlying causes of childhood recurrent pneumonia, which were usually diagnosed and treated in the first months of life.^[3–5] A case-control study revealed that wheezing, chronic rhinosinusitis with postnasal drip, atopy/allergy, and asthma were the most important predisposing factors of recurrent community-acquired pneumonia in children.^[6]

In this report, we describe a school-aged girl with recurrent pneumonia; her age of onset is very uncommon. To the best of our knowledge, this is the first case reported in a child that suture was the underlying cause of recurrent pneumonia. The patient

underwent trachea connection and lung repair operation after an accident of car crash. From then on, she suffered from 1 to 2 episodes of pneumonia every year. This time, her symptoms lasted for more than 1 month and anti-infection treatment was not effective. Bronchoscopy revealed surgical sutures twisted with granulation in the left main bronchus. After the removal of sutures, the patient had no episode of fever and her symptoms also relieved.

Surgical sutures causing recurrent pneumonia are rarely reported in both children and adults. It was reported that endobronchial sutures resulted in chronic cough in 6 adults.^[7] Symptoms lasted for 2 to 6 years because endobronchial suture was not considered in earlier diagnostic evaluations. Persistent cough and the presence of intermittent hemoptysis in these patients combined with the history of thoracic surgery led to bronchoscopy for further diagnosis. After lavage and suction, the endobronchial sutures were finally found. Sutures migrated from the stump of bronchus and located in peribronchial or endobronchial sites. And, granulation tissue formed around the sites by inflammation response. Different types of sutures induce different inflammation responses. It is easier for bacteria to adhere over silk and polyglycolic acid sutures, and suture braiding also boost bacterial adherence over monofilaments. Both granulation tissue and inflammation response contributed to such symptoms as cough, hemoptysis, and so on. Those 6 cases remind us that endobronchial suture should be considered in patients with a history of thoracic surgery and persistent cough that is unresponsive to medical therapy.

Diagnosis of endobronchial suture could be achieved by bronchoscopy, and biopsy forceps are usually used to remove suture. Repeated bronchoscopy is necessary to document resolution of granulation tissue and to assure that no underlying pathology is obscured by the inflammatory response. In summary, this case indicates that children with late and recurrent onset of pneumonia should be evaluated by bronchoscopy as early as possible to find out underlying causes, which can reduce misdiagnosis and recurrence.

Acknowledgment

The authors are grateful to the staff of West China Hospital of Sichuan University for their work in supporting treatment of the child in this case.

References

- [1] Hoving MF, Brand PL. Causes of recurrent pneumonia in children in a general hospital. *J Paediatr Child Health* 2013;49:E208–12.
- [2] Owayed AF, Campbell DM, Wang EE. Underlying causes of recurrent pneumonia in children. *Arch Pediatr Adolesc Med* 2000;154:190–4.
- [3] Lodha R, Puranik M, Natchu UC, et al. Recurrent pneumonia in children: clinical profile and underlying causes. *Acta Paediatr (Oslo, Norway: 1992)* 2002;91:1170–3.
- [4] Ciftci E, Gunes M, Koksai Y, et al. Underlying causes of recurrent pneumonia in Turkish children in a university hospital. *J Trop Pediatr* 2003;49:212–5.
- [5] Cabezuelo Huerta G, Vidal Mico S, Abeledo Gomez A, et al. Underlying causes of recurrent pneumonia. *Anal Pediatr (Barcelona, Spain: 2003)* 2005;63:409–12.
- [6] Patria F, Longhi B, Tagliabue C, et al. Clinical profile of recurrent community-acquired pneumonia in children. *BMC Pulm Med* 2013;13:60.
- [7] Shure D. Endobronchial suture. A foreign body causing chronic cough. *Chest* 1991;100:1193–6.