

Surgical Outcomes of Pneumatic Compression Using Carbon Dioxide Gas in Thoracoscopic Diaphragmatic Plication

Hyo Yeong Ahn, M.D., Yeong Dae Kim, M.D., Hoseok I, M.D., Jeong Su Cho, M.D.,
Jonggeun Lee, M.D., Joohyung Son, M.D.

Department of Thoracic and Cardiovascular Surgery, Pusan National University Hospital, Medical Research Institution

Background: Surgical correction needs to be considered when diaphragm eventration leads to impaired ventilation and respiratory muscle fatigue. Plication to sufficiently tense the diaphragm by VATS is not as easy to achieve as plication by open surgery. We used pneumatic compression with carbon dioxide (CO₂) gas in thoracoscopic diaphragmatic plication and evaluated feasibility and efficacy. **Methods:** Eleven patients underwent thoracoscopic diaphragmatic plication between January 2008 and December 2013 in Pusan National University Hospital. Medical records were retrospectively reviewed, and compared between the group using CO₂ gas and group without using CO₂ gas, for operative time, plication technique, duration of hospital stay, postoperative chest tube drainage, pulmonary spirometry, dyspnea score pre- and postoperation, and postoperative recurrence. **Results:** The improvement of forced expiratory volume at 1 second in the group using CO₂ gas and the group not using CO₂ gas was 22.46±11.27 and 21.08±5.39 (p=0.84). The improvement of forced vital capacity 3 months after surgery was 16.74±10.18 (with CO₂) and 15.6±0.89 (without CO₂) (p=0.03). During follow-up (17±17 months), there was no dehiscence in plication site and relapse. No complications or hospital mortalities occurred. **Conclusion:** Thoracoscopic plication under single lung ventilation using CO₂ insufflation could be an effective, safe option to flatten the diaphragm.

Key words: 1. Diaphragm
2. Thoracoscopy
3. Video-assisted thoracic surgery
4. Methods

Introduction

Diaphragm eventration or paralysis leads to impaired ventilation and decreases perfusion to basal lung parenchyma, which causes ventilation/perfusion mismatch and respiratory muscle fatigue. Surgical correction needs to be considered when patients experience dyspnea. However, plication to sufficiently tense the diaphragm is not as easy with VATS as with open surgery. Therefore, we used pneumatic com-

pression with carbon dioxide (CO₂) gas in thoracoscopic diaphragmatic plication and evaluated its feasibility and efficacy.

Methods

Eighteen patients had symptomatic diaphragmatic eventration and paralysis at Pusan National University Hospital. Of these, 11 patients underwent thoracoscopic diaphragmatic plication between January 2008

Received: December 22, 2015, Revised: March 29, 2016, Accepted: March 29, 2016, Published online: December 5, 2016

Corresponding author: Yeong Dae Kim, Department of Thoracic and Cardiovascular Surgery, Pusan National University Hospital, Medical Research Institute, Pusan National University School of Medicine, 179 Gudeok-ro, Seo-gu, Busan 49241, Korea (Tel) 82-51-240-7267 (Fax) 82-51-243-9389 (E-mail) domini@pnu.edu

© The Korean Society for Thoracic and Cardiovascular Surgery. 2016. All right reserved.

© This is an open access article distributed under the terms of the Creative Commons Attribution Non-Commercial License (<http://creativecommons.org/licenses/by-nc/4.0>) which permits unrestricted non-commercial use, distribution, and reproduction in any medium, provided the original work is properly cited.

and December 2013. Patients on mechanical ventilation, or with upper motor neuron diseases, malignancy, bilateral involvement, or significant comorbid diseases were excluded. The operation was electively conducted when the patient had related symptoms, such as dyspnea, chest pain, and discomfort. To evaluate the feasibility of pneumatic compression by CO₂ gas in thoracoscopic diaphragmatic plication, we compared the operative time, plication technique (suture or endostapler), duration of hospital stay, postoperative chest tube drainage, pulmonary spirometry, dyspnea score pre- and postoperation (based on the American Thoracic Society score criteria), and postoperative recurrence. We compared pneumatic compression by CO₂ gas with cases that did not use CO₂ gas. There was no definite indication for gas use (or disuse) from patients' baseline characteristics; gas

use depended on the surgeons' preference.

1) Surgical technique

(1) Thoracoscopic diaphragmatic plication using CO₂ gas: We placed the air-locking trocar (10 mm) in the fifth intercostal space (ICS) in the midaxillary line. CO₂ was insufflated at 6–8 mm Hg through the trocar under thoracoscopic guidance. In instances where the bulging diaphragm was displaced caudally, a second trocar was inserted in the lowermost part as an entrance for the endostapler. The other air-locking trocar (5 mm) was needed to grasp the diaphragm in the sixth to seventh ICS in the posterior axillary line (Fig. 1). We manipulated the bulging diaphragm so that it was adequately flattened. The endostapler or suture (using 6–8 parallel U stitches) was used to plicate in a posterolateral to anteromedial direction, which prevents phrenic nerve injury (Fig. 2). Under thoracoscopic guidance, the flattened diaphragm and lung expansion were identified and a Jackson-Pratt drain was placed.

2) Statistical analysis

Data were analyzed using SPSS Statistics software ver. 16.0 (SPSS Inc., Chicago, IL, USA) and statistical significance was assumed for a p-value <0.05. An unpaired Student t-test and chi-square test were used for univariate statistical analysis.

Results

Of 18 patients who underwent diaphragmatic plication, 11 patients underwent thoracoscopic diaphragmatic plication and seven patients underwent open surgery. Of 11 patients with thoracoscopic diaphragmatic plication, six patients received CO₂ and the

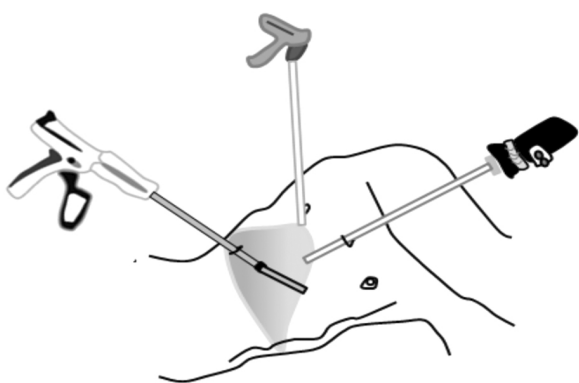


Fig. 1. Intraoperative incision. The thoracoscope was placed in the fifth ICS in the midaxillary line and the endostapler was inserted in the lowermost part, such as the ninth ICS in the PAL after CO₂ insufflation. The grasper was inserted through the sixth and seventh ICS in PAL. ICS, intercostal space; PAL, posterior axillary line.

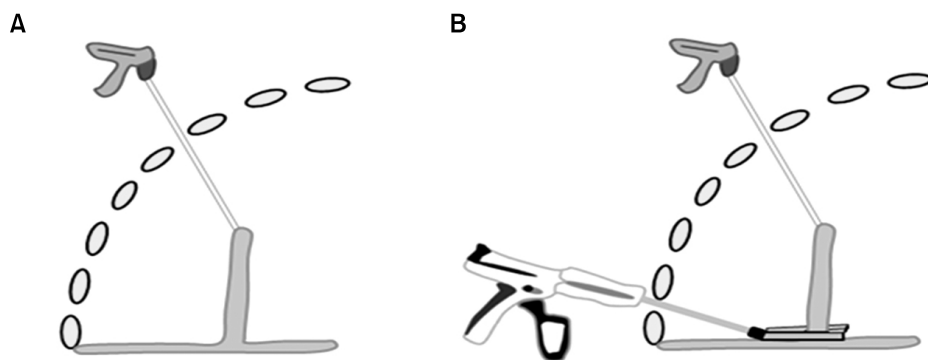


Fig. 2. Schematic illustration of thoracoscopic plication under CO₂ insufflation. (A) The extended diaphragm could be pulled upward and kept drawn tight under CO₂ insufflation. (B) Plication using a stapler could be performed easily as level as the folded diaphragm. In this view, the trocar for an entrance of endostapler is better to be inserted in the lowest part to resect the folded diaphragm. CO₂, carbon dioxide.

Table 1. Patient characteristics and perioperative findings after thoracoscopic diaphragmatic plication

Characteristic	Group using CO ₂	Group without using CO ₂	p-value
Age (yr)	58.62±13.81	58±18.00	0.95
Gender (female:male)	6:2	2:1	
Affected side (right:left)	3:5	0:3	
Operative time (min)	60±20.18	153.3±25.17	0.00 ^{a)}
Plication technique (suture:staple)	2:6	2:1	
Chest tube drainage (day)	3.25±4.86	5.33±4.16	0.53
Hospital stay (day)	5.5±6.12	8.67±4.73	0.4
Postoperative pain score ^{b)}	4.25±1.49	2.67±1.16	0.13

CO₂, carbon dioxide.^{a)}Statistically significant difference. ^{b)}Measured by visual analogue scale on the first postoperative day.**Table 2.** Comparison of pulmonary spirometry and symptoms depending on use of CO₂ insufflation

Variable	Group using CO ₂	Group not using CO ₂	p-value
Preoperative FEV ₁	2.03±0.34	1.68±2.89	0.99
Postoperative FEV ₁	1.98±0.56	1.68±5.2	0.89
Improvements of FEV ₁ (%)	22.46±11.27	21.08±5.39	0.84
Preoperative FVC	2.07±0.67	1.90±0.18	0.69
Postoperative FVC	2.39±0.68	2.19±0.22	0.65
Improvement of FVC (%)	16.74±10.18	15.6±0.89	0.03 ^{a)}
Preoperative dyspnea score ^{b)}	1.25±0.71	1.66±0.58	0.39
Postoperative dyspnea score ^{b)}	0.13±0.35	0.33±0.57	0.48
Improvement of dyspnea score ^{b)}	1.1±0.64	1.33±5.78	0.64

CO₂, carbon dioxide; FEV₁, forced expiratory volume at 1 second; FVC, forced vital capacity.^{a)}Statistically significant difference. ^{b)}Measured by American Thoracic Society score.

other patients did not received CO₂. In the group using CO₂ gas, the mean age was 58.62±13.81 years, there were 6 female patients, and 3 cases were affected on the right-side. Parallel U stitches were used in 2 patients and the endostapler was used in 6 patients. In the group that did not use CO₂ gas, the mean age was 58±18 years, there were 2 female patients, and all cases were affected on the left-side. The mean duration of drainage was 3.25±4.86 days (range, 0 to 15 days), the mean hospital stay was 5.5±6.12 days (range, 1 to 20 days), and the mean pain score on the first postoperative day was 4.25±1.49 (range, 2 to 6) in the group using CO₂ gas. In the group not using CO₂ gas, the mean duration of drainage was 5.33±4.16 days (range, 2 to 10 days), the mean hospital stay was 8.67±4.73 days (range, 5 to 14 days), and the mean pain score on the first postoperative day was 2.67±1.16 (range, 2 to 4) (Table 1).

The mean preoperative dyspnea score was 1.25±0.71 (with CO₂ gas) and 0.13±0.35 (without CO₂ gas), and

the mean postoperative dyspnea score 3 mo after surgery was 1.66±0.58 (with CO₂ gas) and 0.33±0.57 (without CO₂ gas). The mean pre- and postoperative forced expiratory volume at 1 second and the forced vital capacity (FVC) are shown in Table 2.

We analyzed follow-up images and postoperative pulmonary functions between the group using the endostapler and the group using sutures; these were not significantly different between the two groups (Table 3). The mean follow-up duration after diaphragmatic plication was 17±17 months (range, 1 to 45 months). During follow-up, there was no dehiscence in the plication site and relapse. No complications and no hospital mortalities occurred.

Discussion

Plication of the diaphragm could be considered as a treatment option in symptomatic unilateral diaphragmatic eventration to improve respiratory im-

Table 3. Comparison of pulmonary spirometry and symptoms depending on the plication technique

Variable	Plication by interrupted suture	Plication by endostapler	p-value
Preoperative FEV ₁	1.61±0.48	1.71±0.57	0.83
Postoperative FEV ₁	1.68±0.64	2.08±0.56	0.42
Improvement of FEV ₁ (%)	16.82±10.73	24.33±11.74	0.46
Preoperative FVC	1.90±0.63	2.12±0.73	0.72
Postoperative FVC	2.10±0.81	2.49±0.69	0.53
Improvement of FVC (%)	9.21±6.24	19.26±10.34	0.25
Preoperative dyspnea score ^{a)}	1.00±0.00	1.33±0.82	0.05 ^{b)}
Postoperative dyspnea score ^{a)}	0.00±0.00	0.17±0.41	0.60
Improvements of dyspnea score ^{a)}	1.0±0.00	1.17±0.75	0.78

FEV₁, forced expiratory volume at 1 second; FVC, forced vital capacity.

^{a)}Measured by American Thoracic Society score. ^{b)}Statistically significant difference.

pairment. However, patients with upper motor neuron diseases, bilateral involvement, and on mechanical ventilation were excluded in this study because the effect of plication was not unpredictable. VATS has recently been popular in cases with diaphragmatic diseases [1-5], although this technique has difficulties in the limited surgical field exposure and decisions regarding how much flatten the diaphragm.

In this study, we performed thoracoscopic plication under single lung ventilation using CO₂ insufflation to achieve exposure and to flatten the diaphragm. Risks include hypercapnia, hemodynamic instability, and acidosis [6], but insufflation pressure <10 mm Hg can prevent such risks. An improved surgical field exposure allowed for shorter operative times in this study. The flaccid diaphragm could be pulled upward and kept tightly drawn under CO₂ insufflation to decide how much to plicate the diaphragm. The plication using an endostapler or sutures was performed easily at the level of the lowest border of the folded diaphragm, which could prevent injury of abdominal organs (Fig. 2). Life threatening, adverse events could be prevented only if the folded diaphragm was plicated under thoracoscopic guidance. It is not difficult to overcome the learning curve for thoracoscopic plication (with or without CO₂ gas), and surgical techniques such as the placement of ports, the pressure of CO₂ insufflation, and the direction of the endostapler are similar.

Although our data shows significant differences in only a single factor (improvements of FVC), it does not mean there are no benefits from CO₂ insufflation in improvements of symptoms and pulmonary spirometry. Patients who received diaphragm plication, regardless

of CO₂ gas use, showed symptomatic improvements and improved pulmonary spirometry in the short-term outcomes. Long-term outcomes need to be evaluated in the future. Our study confirms the necessity of diaphragmatic plication in symptomatic patients with unilateral diaphragm paralysis.

Using sutures to plicate is time-consuming and hard to manipulate; however, sutures can be more delicate and have less risk of relapse (even if one of the sutures might be released). While it is easier to perform plication using an endostapler, the diaphragm could be ruptured if the staple line might be torn. In our study, the endostapler was usually chosen (interrupted sutures were used in just 3 cases). There were no data comparing outcomes between endostapler and suture use [1,2,7], but the follow-up images and postoperative pulmonary functions were not significantly different (Table 3). Postoperative complications and recurrences were not found during follow-up.

In conclusion, thoracoscopic plication under single lung ventilation using CO₂ insufflation could be an effective and safe option to flatten the diaphragm. Future studies are needed with large series of patients who undergo thoracoscopic plication under CO₂ insufflation, and comparison of outcomes of different plication techniques (stapler vs. sutures).

Conflict of interest

No potential conflicts of interest relevant to this article are reported.

Acknowledgments

This study was granted by 2014 Pusan National University Hospital, Medical Research Institution.

References

1. Abraham MK, Menon SS, S BP. *Thoracoscopic repair of eventration of diaphragm*. Indian Pediatr 2003;40:1088-9.
2. Dunning J. *Thoracoscopic diaphragm plication*. Interact Cardiovasc Thorac Surg 2015;20:689-90.
3. Hwang Z, Shin JS, Cho YH, Sun K, Lee IS. *A simple technique for the thoracoscopic plication of the diaphragm*. Chest 2003;124:376-8.
4. Kozlov Y, Novozhilov V. *Thoracoscopic plication of the diaphragm in infants in the first 3 months of life*. J Laparoendosc Adv Surg Tech A 2015;25:342-7.
5. Visouli AN, Mpakas A, Zarogoulidis P, et al. *Video assisted thoracoscopic plication of the left hemidiaphragm in symptomatic eventration in adulthood*. J Thorac Dis 2012;4 Suppl 1:6-16.
6. Homma T, Yamamoto Y, Doki Y, et al. *Complete thoracoscopic diaphragm plication using carbon dioxide insufflation: report of a case*. Surg Today 2015;45:915-8.
7. Moon SW, Wang YP, Kim YW, Shim SB, Jin W. *Thoracoscopic plication of diaphragmatic eventration using endostaplers*. Ann Thorac Surg 2000;70:299-300.