

# Reverse shoulder arthroplasty vs. hemiarthroplasty for the treatment of osteoporotic proximal humeral fractures in elderly patients: A systematic review and meta-analysis update

PENG-FEI HAN<sup>1\*</sup>, SU YANG<sup>2\*</sup>, YUE-PENG WANG<sup>2</sup>, XUE-DONG HOU<sup>2</sup>, YUAN LI<sup>1</sup> and XI-YONG LI<sup>2</sup>

<sup>1</sup>Department of Orthopedics, Heping Hospital Affiliated to Changzhi Medical College; <sup>2</sup>Graduate School, Graduate Student Department of Changzhi Medical College, Changzhi, Shanxi 046000, P.R. China

Received March 30, 2022; Accepted August 1, 2022

DOI: 10.3892/etm.2022.11574

**Abstract.** The present meta-analysis was conducted to compare the safety and effectiveness of reverse shoulder arthroplasty (RSA) and hemiarthroplasty (HA) in the treatment of osteoporotic proximal humeral fractures in elderly patients. The Embase, Pubmed Central, Cumulative Index to Nursing and Allied Health Literature, ProQuest Dissertations and Theses, Cochrane Library and Chinese Biomedical databases were searched between January 2009 and January 2022 to identify relevant studies. According to the search strategy, a total of 210 associated studies were retrieved and 16 were finally included. Review Manager 5.4 software was used for the data analysis. This study indicated that patients in the RSA group had significantly improved treatment outcomes compared with patients in the HA group, as assessed by Constant-Murley Shoulder Outcome Score (95% CI, 1.69-3.76;  $P < 0.001$ ), American Shoulder and Elbow Surgeons score (95% CI, 11.81-24.88;  $P < 0.001$ ) and shoulder range of motion (ROM; 95% CI, 3.41-9.07;  $P < 0.001$ ). However, the HA group was superior to the RSA group in terms of the Oxford Shoulder score (95% CI, 2.89-11.11;  $P < 0.001$ ). There was no significant statistical difference between the two groups in terms of the Disabilities of the Arm, Shoulder and Hand score and complications. Overall, for the treatment of osteoporotic proximal humeral fractures in the elderly, the RSA group had improved

postoperative ROM and functional scores compared with the HA group, without significant difference in the incidence of complications. However, HA remains a safe and reliable treatment option.

## Introduction

Proximal humeral fractures are the third most common fractures after proximal femur and distal radial fractures, accounting for 4-5% of all fractures (1), especially in the elderly population. With an increase in the incidence of osteoporosis in the aging society, the incidence of proximal humeral fractures is increasing year by year and the degree of fracture is often more serious, mostly occurring as a three-part or four-part fracture based on the Neer fracture classification system (2,3). At present, humeral locking plates and intramedullary nails have achieved good clinical efficacy, but there are more complications, such as increased operation times and intraoperative blood loss, as well as humeral head necrosis and screw perforation, when compared with shoulder arthroplasty (4). With the improvement of surgical techniques and implant materials, hemiarthroplasty (HA) and reverse shoulder arthroplasty (RSA) have gradually gained attention and made some progress in clinical practice (5). Conventional HA can solve the problems of internal fixation failure and humeral head necrosis of complex proximal humerus fractures. However, HA has certain requirements for the union of tubercle fractures and the integrity of the scapular glenoid (6). HA cannot deal with complicated rotator cuff injuries and glenoid cavity fractures (6), while RSA has higher requirements on the deltoid muscle function. There is still a lot of debate over which type of shoulder arthroplasty is more suitable for elderly comminuted proximal humerus fractures (7). Therefore, the present study aimed to systematically compare the differences between them by means of a meta-analysis to provide theoretical guidance for clinical practice.

## Materials and methods

*General information.* The present study included domestic and overseas clinical controlled studies that were published between January 2009 and January 2022. The patients were

---

*Correspondence to:* Mr. Xi-Yong Li, Graduate School, Graduate Student Department of Changzhi Medical College, 110 South Yan'an Road, Changzhi, Shanxi 046000, P.R. China  
E-mail: lxy160505@163.com

\*Contributed equally

*Abbreviations:* RSA, reverse shoulder arthroplasty; HA, hemiarthroplasty; ASES, American Shoulder and Elbow Surgeons; ROM, range of motion; DASH, Disabilities of the Arm, Shoulder and Hand; NOS, Newcastle-Ottawa scale; OR, odds ratio

*Key words:* reverse shoulder arthroplasty, hemiarthroplasty, proximal humeral fracture, meta-analysis

diagnosed with complex proximal humerus fractures (Neer three-part and four-part fractures) based on the patient's medical history (8), and physical and imaging examinations. All patients required shoulder arthroplasty. Non-case controlled studies, case reports, literature reviews, letters, duplicate reports, studies that included cases with a mean age of <60 years or those that did not provide sufficient relevant data were excluded. Intervention measures were HA replacement and RSA. Outcome indicators were Constant-Murley Shoulder Outcome Score, Disabilities of Arm, Shoulder and Hand (DASH) score, American Shoulder and Elbow Surgeons (ASES) score, Oxford Shoulder score, shoulder range of motion (ROM) and complications (9). The Preferred Reporting Items for Systematic Reviews and Meta-Analyses checklist was followed to perform the present meta-analysis (10).

*Search strategy.* The Embase (<https://www.embase.com>), Pubmed Central (<https://pubmed.ncbi.nlm.nih.gov/>), ProQuest Dissertations and Theses (<http://pqdtopen.proquest.com/>), Cochrane Library (<https://www.cochranelibrary.com/>) and Chinese Biomedical databases ([www.sinomed.ac.cn](http://www.sinomed.ac.cn)) were searched. The directories of periodical and references were manually retrieved and the gray literature (such as chapters in unpublished academic papers, monographs, non-publicly published documents, government documents, dissertations, conference documents, scientific and technological reports, technical archives) was retrieved. Meanwhile, no language constraints were applied to extend the search to all relevant content, and the papers were thereafter translated if necessary. The key words were 'hemiarthroplasty', 'HA', 'reverse shoulder arthroplasty', 'RSA' and 'proximal humeral fractures', and the search strategy was (reverse shoulder arthroplasty OR RSA) AND (hemiarthroplasty OR HA) AND (proximal humeral fractures).

*Quality assessment of the literature.* The included studies were independently analyzed by two physicians, and if disagreements occurred, they were resolved through discussion or handed over to a third senior physician to jointly determine the quality of the literature in strict accordance with the Cochrane risk of bias assessment criteria (11): i) Whether the experimental design adopts the random principle; ii) whether participants, performers and measurers use the double-blind principle; iii) whether the experimental data are complete and credible; iv) whether the allocation concealment method is adopted; v) whether the experiment adopts a selective data reporting method; and vi) other bias factors. According to the Newcastle-Ottawa scale (NOS) (12), the quality of the literature that met the inclusion criteria was evaluated.

*Statistical analysis.* Meta-analysis of the extracted data was performed using Review manager 5.4 software provided by the Cochrane Collaboration (<https://training.cochrane.org/online-learning/core-software/revman>). Dichotomous variables are expressed as the odds ratio and 95% CI. Continuous variables are expressed as the mean difference or standard mean difference and 95% CI. Heterogeneity among studies was tested by  $I^2$  statistics, with an  $I^2$  value of >50% indicating significant inconsistency. The reasons for the heterogeneity were analyzed and a random-effect model was

used at this time, otherwise, a fixed-effect model was used. Sensitivity analyses were performed by removing certain studies and reanalyzing the data, and funnel plots were made to assess publication bias.  $P < 0.05$  was considered to indicate a statistically significant difference.

## Results

*Essential features of the included studies.* A total of 210 related publications were retrieved according to the aforementioned search strategy. By reading the title and abstract, 181 publications that were not controlled studies, or were repeated publications and irrelevant to the research purpose were excluded, and so 29 suitable publications passed initial screening. Following full text reading and screening in accordance with the inclusion and exclusion criteria, 16 studies were finally included. Baseline patient information, such as age and course of disease were compared among the included studies, which was comparable ( $P > 0.05$ ). The literature screening process and results are shown in Fig. 1 and the basic characteristics of the included literature studies are shown in Table I.

*Quality assessment of the literature.* The present study included 1 randomized controlled trial, 5 prospective studies and 10 retrospective studies. To the best of our knowledge, the meta-analysis of retrospective, randomized controlled and prospective studies together will inevitably lead to certain biases in the results (13). However, when the literature was searched according to the search strategy, the number of randomized controlled studies and sample size was relatively small. Therefore, retrospective and prospective studies were included in the meta-analysis to increase the sample size. Consequently, NOS score was considered the most suitable for evaluating all the studies and the score was divided into low, medium and high quality grades, namely <5, 5-7 and 8-9 points (12). Among the literature, 3 papers scored nine points, 3 scored eight points, 4 scored seven points and 6 scored six points. Although the number of included studies was limited and there was a certain bias, the overall quality was moderate (Fig. 1 and Table I) (14-29).

## Outcomes

*Constant-Murley Shoulder Outcome Score.* In the present study, the Constant-Murley Shoulder Outcome Score was chosen as one of the outcomes of treatment. The Constant-Murley Shoulder Outcome Score is one of the most important scores for evaluating shoulder joint function (30); it mainly includes pain, daily activities, strength and shoulder joint ROM (31). A total of 6 studies reported the postoperative Constant-Murley Shoulder Outcome Score for RSA and HA in the treatment of elderly osteoporotic proximal humerus fractures, with scores divided into four subgroups according to pain, activity, strength and ROM. Due to the large heterogeneity ( $I^2 > 50\%$ ) between the results and subgroups of each study, a random-effects model was used for the meta-analysis. The results showed that during the treatment of elderly osteoporotic proximal humeral fractures with joint replacement, the postoperative Constant-Murley Shoulder Outcome Score in the RSA group was improved compared with that in the HA group (95% CI, 1.69-3.76;  $P < 0.001$ ) and the difference was

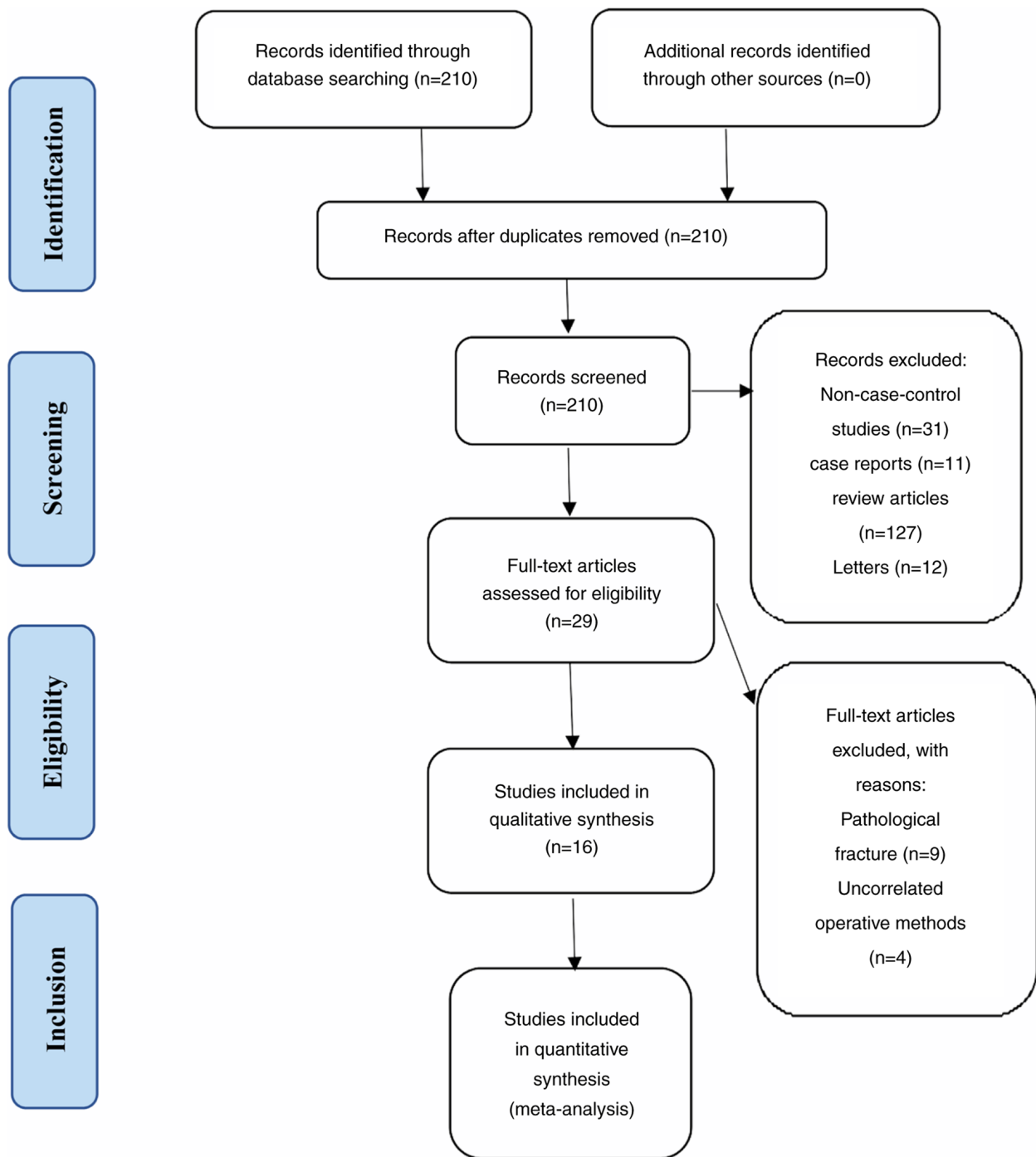


Figure 1. Flow diagram of the literature search.

statistically significant. In terms of activity, the RSA group score was significantly improved compared with that of the HA group (95% CI, 2.25-4.70;  $P<0.001$ ) and similarly, the RSA group outperformed the HA group for ROM (95% CI, 5.50-8.51;  $P<0.001$ ). However, in the two subgroups of pain (95% CI, -0.17-4.58;  $P=0.07$ ) and strength (95% CI, -1.10-2.32;  $P=0.48$ ), the scores of the RSA and HA group were comparable (Fig. 2).

**DASH score.** A total of 5 studies provided detailed information on the DASH score. The random-effect model was also used for the meta-analysis due to the large heterogeneity among the results ( $I^2=70\%$ ). After the meta-analysis, no significance

was observed (95% CI, -7.34-2.02;  $P=0.27$ ) for DASH score (Fig. 3).

**ASES score.** A total of 5 studies paid close attention to the ASES score for the treatment of elderly osteoporotic proximal humerus fractures. As there was little heterogeneity among the results of the studies ( $I^2<50\%$ ), a fixed-effects model was used for the meta-analysis. The mean ASES score of the RSA group was higher than that in the HA group, and the difference was statistically significant (95% CI, 11.81-24.88;  $P<0.001$ ; Fig. 4).

**Oxford Shoulder score.** A total of 3 publications compared the postoperative Oxford Shoulder score between the RSA and HA groups. Due to the large heterogeneity ( $I^2>50\%$ )

Table I. General characteristics of the included studies.

First author/s	Type of study	Country (city)	Publication year	RSA/HA	Cases, n	Mean age, years	Sex (M/F)	Outcome	NOS score	(Refs.)
Baudi <i>et al</i>	Retrospective	Italy (Modena)	2014	RSA HA	25	77.3	-/-	A,B,C,E	7	(14)
Bonneville <i>et al</i>	Retrospective	France (Toulouse)	2016	RSA HA	28	71.4	-/-	B,E,F	7	(15)
Boyer <i>et al</i>	Prospective	France (Besançon)	2017	RSA HA	41	78.0±5.0	4/37	B,F	7	(16)
Boyle <i>et al</i>	Retrospective	New Zealand (Auckland)	2012	RSA HA	57	67.0±10.1	18/39	D	6	(17)
Critchley <i>et al</i>	Retrospective	Australia (Adelaide)	2020	RSA HA	65	79.6	4/51	F	6	(18)
Cuff and Pupello	Prospective	America (Florida)	2013	RSA HA	69	71.9	69/244	C,EF	8	(19)
Alentorn-Geli <i>et al</i>	Prospective	Spain (Barcelona)	2014	RSA HA	55	74.4	-	A	7	(20)
Sebastiá-Forcada <i>et al</i>	Prospective	Spain (Alicante)	2014	RSA HA	23	78.6	4/16	B,E,F	9	(21)
Gallinet <i>et al</i>	Retrospective	France (Besançon)	2009	RSA HA	20	82.6	4/8	B,E	6	(22)
Garrigues <i>et al</i>	Retrospective	America (North Carolina)	2012	RSA HA	12	74.7	4/27	C,E	8	(23)
Cvetanovich <i>et al</i>	Retrospective	America (Chicago)	2016	RSA HA	31	73.3	5/25	F	6	(24)
Jonsson <i>et al</i>	Random	Sweden (Gothenburg)	2021	RSA HA	30	74.0	4/15	F	9	(25)
van der Merwe <i>et al</i>	Prospective	New Zealand (Auckland)	2017	RSA HA	19	74.0	3/18	D	6	(26)
Schairer <i>et al</i>	Retrospective	America (New York)	2015	RSA HA	21	80.5	-/-	F	6	(27)
Solomon <i>et al</i>	Retrospective	America (Cleveland)	2016	RSA HA	11	69.3	-/-	F	8	(28)
Young <i>et al</i>	Retrospective	New Zealand (Auckland)	2010	RSA HA	12	77.0	3/13	D,E	9	(29)
					125	77.2	0/10			
					404	75.5	2/8			

HA, hemiarthroplasty; RSA, reverse shoulder arthroplasty; M, male; F, female; NOS, Newcastle-Ottawa Scale; A, Constant-Murley Shoulder Outcome Score; B, Disabilities of the Arm, Shoulder and Hand score; C, American Shoulder and Elbow Surgeons score; D, Oxford Shoulder score; E, Shoulder range of motion; F, complications.

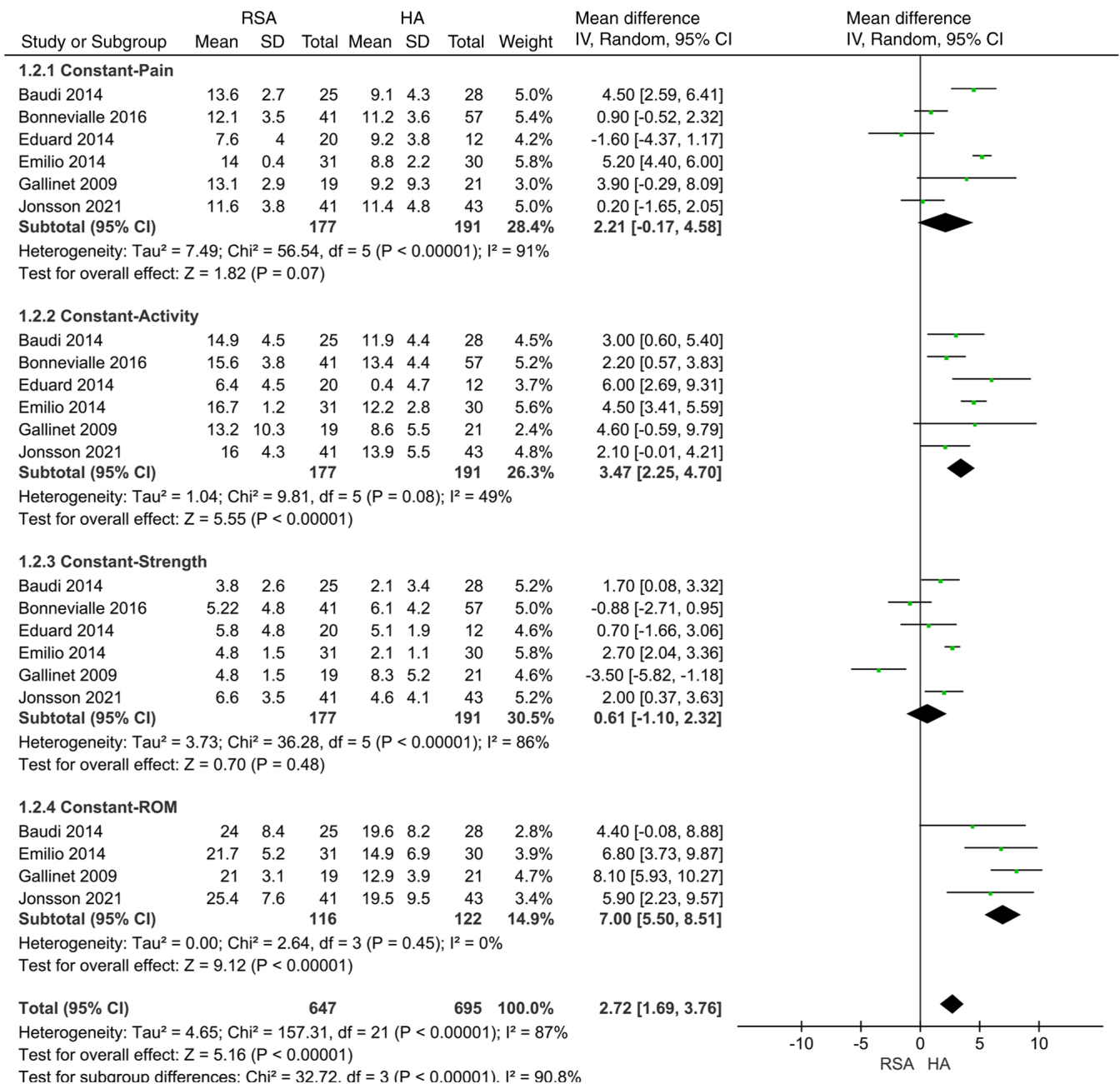


Figure 2. Meta-analysis of Constant-Murley Shoulder Outcome Score between RSA and HA in the treatment of elderly osteoporotic proximal humerus fractures. RSA, reverse shoulder arthroplasty; HA, hemiarthroplasty.

among the results of each study, the random-effects model was used for the meta-analysis. The results showed that the mean Oxford Shoulder score of the RSA group was higher when treating elderly osteoporotic proximal humerus fractures, and the difference was statistically significant (95% CI, 2.89-11.11;  $P < 0.001$ ; Fig. 5).

**Shoulder ROM.** A total of 9 studies compared the post-operative shoulder ROM of RSA and HA in the treatment of elderly osteoporotic proximal humerus fractures, with the scores divided into four subgroups according to anterior elevation, abduction, external rotation and internal rotation. Due to the large heterogeneity ( $I^2 > 50\%$ ) among the results, the random-effect model was used for the meta-analysis. The results showed that during the treatment of elderly osteoporotic proximal humerus fractures with shoulder arthroplasty,

the shoulder ROM in the RSA group was improved compared with that in the HA group (95% CI, 3.41-9.07;  $P < 0.001$ ) with statistically significant differences, especially with regard to the anterior elevation (95% CI, 18.27-39.38;  $P < 0.001$ ) and abduction (95% CI, 24.24-41.26;  $P < 0.001$ ). The meta-analysis for the other two subgroups involving external (95% CI, -5.33-1.12;  $P = 0.20$ ) and internal (95% CI, -1.86-1.06;  $P = 0.59$ ) rotations did not find a significant difference between both methods (Fig. 6).

**Complications.** There are several possible post-operative complications in the treatment of elderly osteoporotic proximal humerus fractures with shoulder arthroplasty. The 8 included studies compared the post-operative complications of RSA and HA and divided them into 13 complication subgroups, including arthrofibrosis,

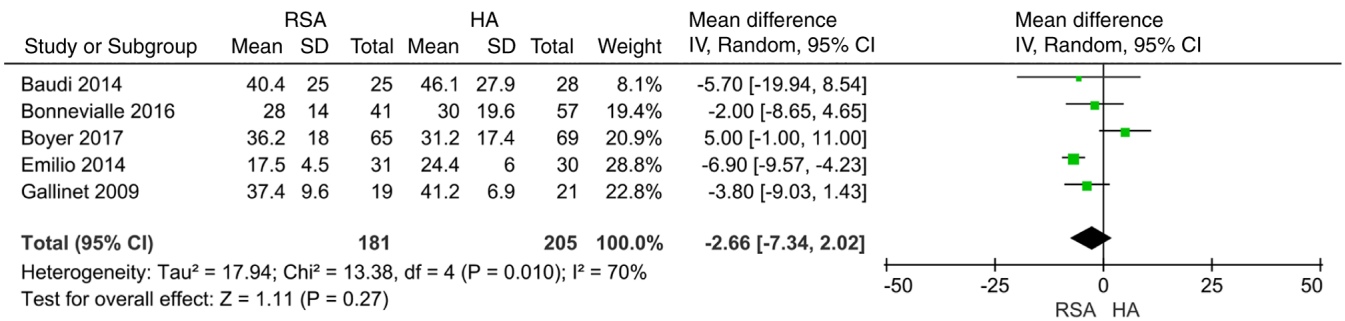


Figure 3. Meta-analysis of Disabilities of the Arm, Shoulder and Hand score between RSA and HA in the treatment of elderly osteoporotic proximal humerus fractures. RSA, reverse shoulder arthroplasty; HA, hemiarthroplasty.

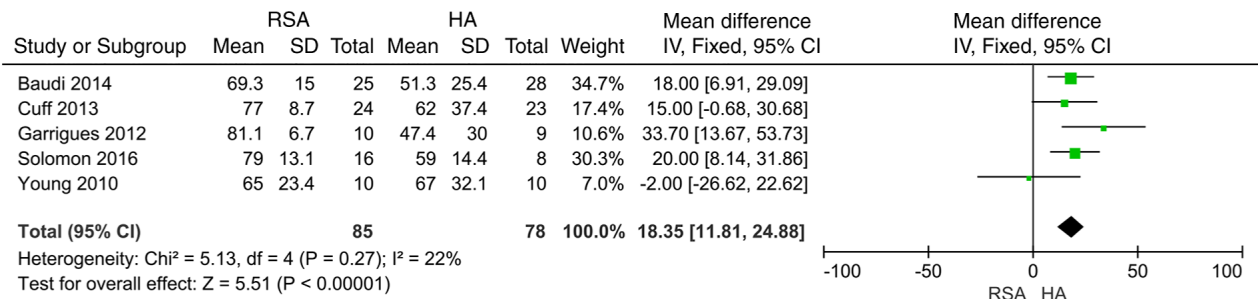


Figure 4. Meta-analysis of American Shoulder and Elbow Surgeons score between RSA and HA in the treatment of elderly osteoporotic proximal humerus fractures. RSA, reverse shoulder arthroplasty; HA, hemiarthroplasty.

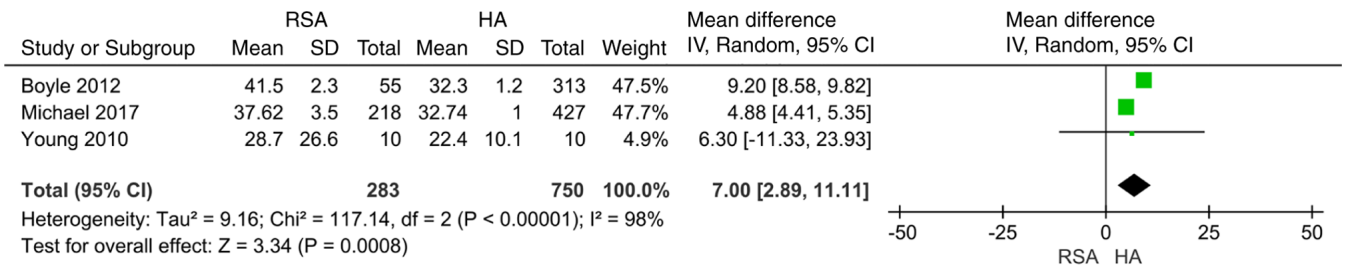


Figure 5. Meta-analysis of Oxford Shoulder score between RSA and HA in the treatment of elderly osteoporotic proximal humerus fractures. RSA, reverse shoulder arthroplasty; HA, hemiarthroplasty.

greater tuberosity osteolysis, malunion greater tuberosity, diaphyseal fracture of humerus, infection, heterotopic bone, loosening, secondary cuff rupture, deep venous thrombosis, instability/dislocation, complex regional pain syndrome, malposition and pulmonary embolism. Due to the large heterogeneity (I<sup>2</sup>>50%) among the results of each study, the random-effect model was used for the meta-analysis. The results showed that in the deep venous thrombosis subgroup, the HA group had a lower incidence rate than the RSA group (95% CI, 1.21-5.68; P=0.01). No significant differences were observed in the other subgroups or in terms of complications overall (95% CI, 0.59-1.20; P=0.35; Fig. 7).

**Publication bias and sensitivity analysis.** The Review Manager 5.4 statistical software provided by the Cochrane Collaboration was used to analyze the publication bias of the Constant-Murley Shoulder Outcome Score, DASH score, ASES score, Oxford Shoulder score, shoulder ROM and

complications after the shoulder arthroplasty. The results showed that the funnel plots were basically symmetrical, indicating that there was no obvious publication bias (Fig. 8). The analysis showed that there was high heterogeneity in the Constant-Murley Shoulder Outcome Score subgroups (pain, strength and ROM), DASH score, Oxford shoulder score and shoulder ROM subgroups (anterior elevation and internal rotation). The heterogeneity was reduced to 0% after the study by Bonneville *et al* (15) was excluded from the meta-results of Constant-Murley Shoulder Outcome Score-ROM. Due to strict compliance with the search and inclusion criteria, the inclusion of certain results in the literature is limited, and it would be difficult to complete the meta-analysis if certain studies were excluded. After further analyzing the heterogeneous sources using the one-by-one elimination method, the results of the meta-analysis showed no directional changes, indicating that the stability of the research results was good (Figs. 9 and 10).

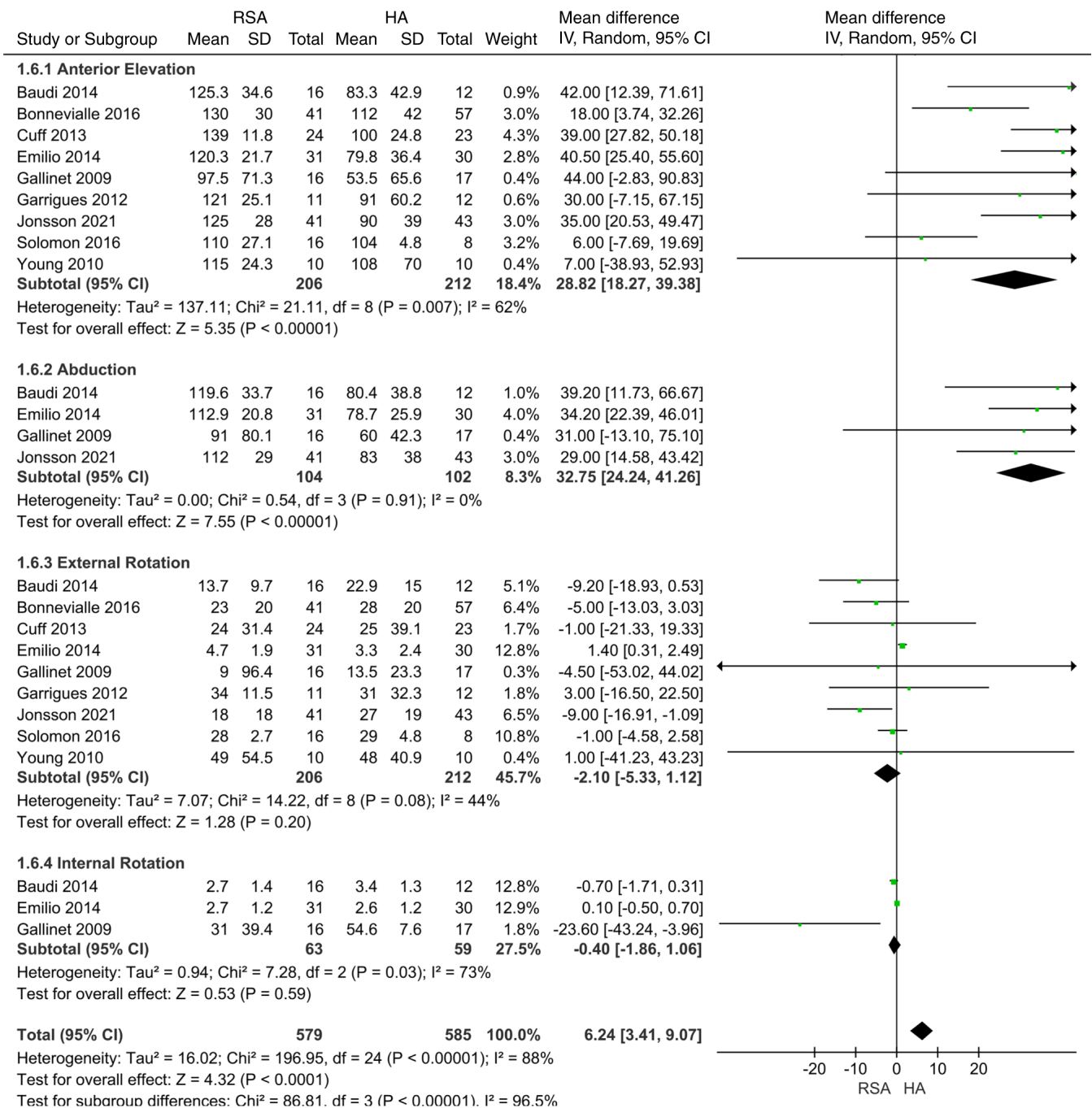


Figure 6. Meta-analysis of shoulder range of motion between RSA and HA in the treatment of elderly osteoporotic proximal humerus fractures. RSA, reverse shoulder arthroplasty; HA, hemiarthroplasty; ROM, range of motion.

## Discussion

Proximal humerus fractures are one of the common long bone fractures, accounting for more than one-fourth of shoulder fractures (32). The purpose of treatment for proximal humerus fractures is to relieve pain, restore the ROM of the shoulder joint and improve the quality of life of the patient. Most of the proximal humerus fractures in adolescents are undisplaced and simple fractures, which can be treated conservatively. However, proximal humeral fractures in the elderly are mostly comminuted fractures due to long-term bone loss (33).

Surgical options for proximal humerus fractures include open reduction and internal fixation, HA and RSA. A number

of studies have shown that shoulder arthroplasty has fewer complications and improved postoperative functional scores than the open reduction and internal fixation of proximal humerus fractures (34,35); however, there is still some controversy about the superiority of HA and RSA. Although HA can effectively solve the problem of humeral fracture pain, the matching degree of the prosthesis is relatively high and there are certain requirements for the integrity of the soft tissue around the shoulder joint (36). For example, the incompleteness of the greater tuberosity of the humerus is one of the reasons for the operation failure. Active anti-osteoporosis treatment and functional exercise are still required after the surgery. The RSA avoids a high degree of dependence on the rotator cuff

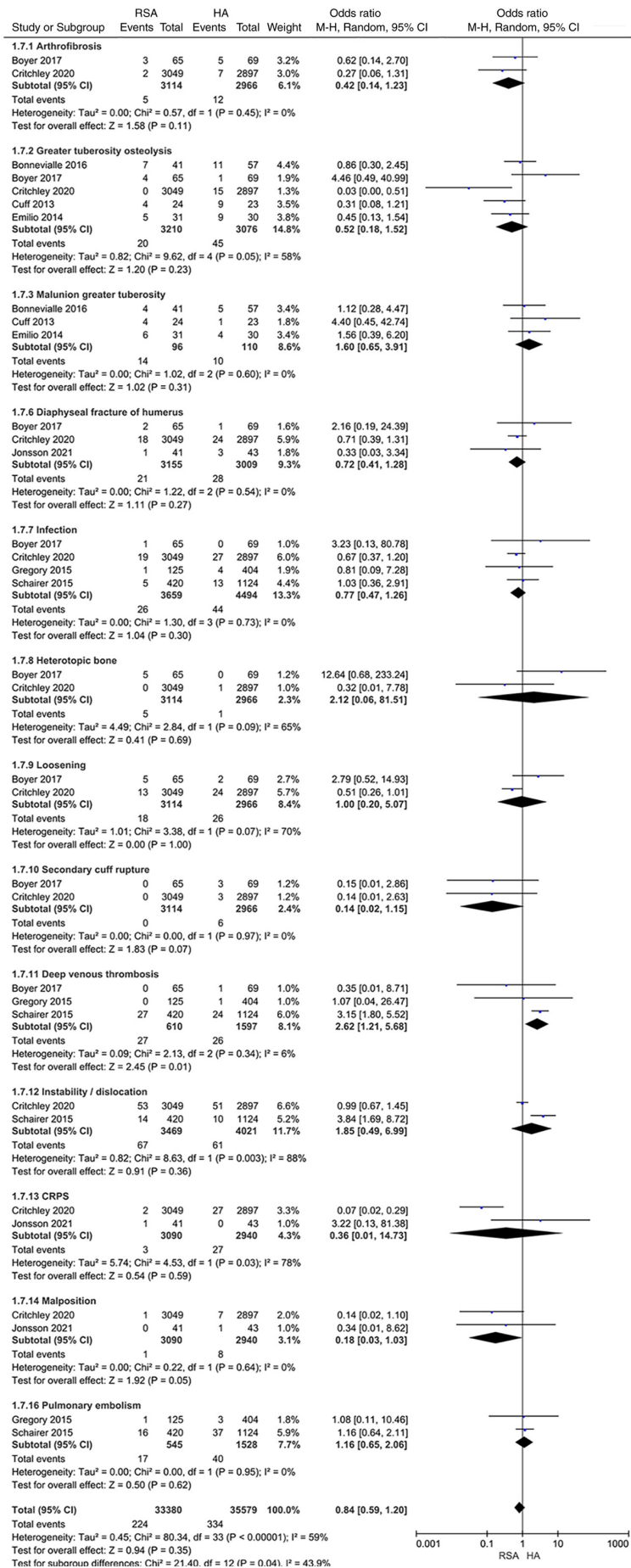


Figure 7. Meta-analysis of complications between RSA and HA in the treatment of elderly osteoporotic proximal humerus fractures. RSA, reverse shoulder arthroplasty; HA, hemiarthroplasty; CRPS, complex regional pain syndrome.



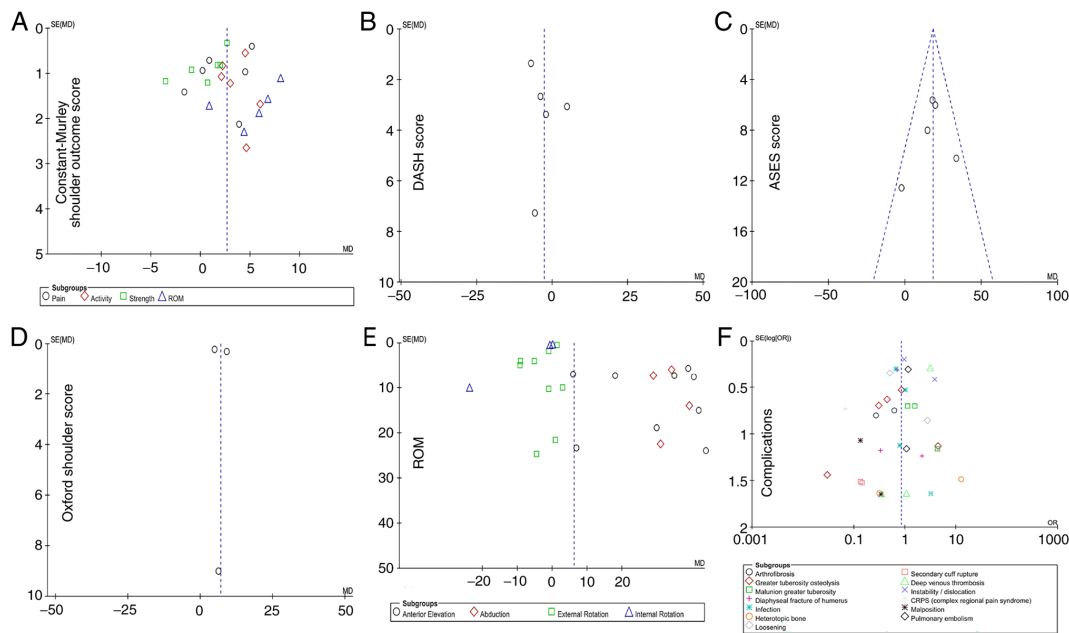


Figure 8. Funnel plots for evaluation of publication bias. (A) Funnel plot for Constant-Murley Shoulder Outcome Score; (B) funnel plot for DASH score; (C) funnel plot for ASES score; (D) funnel plot for Oxford Shoulder score; (E) funnel plot for shoulder ROM; (F) funnel plot for complications. ASES, American Shoulder and Elbow Surgeons; ROM, range of motion; DASH, Disabilities of the Arm, Shoulder and Hand; CRPS, complex regional pain syndrome.

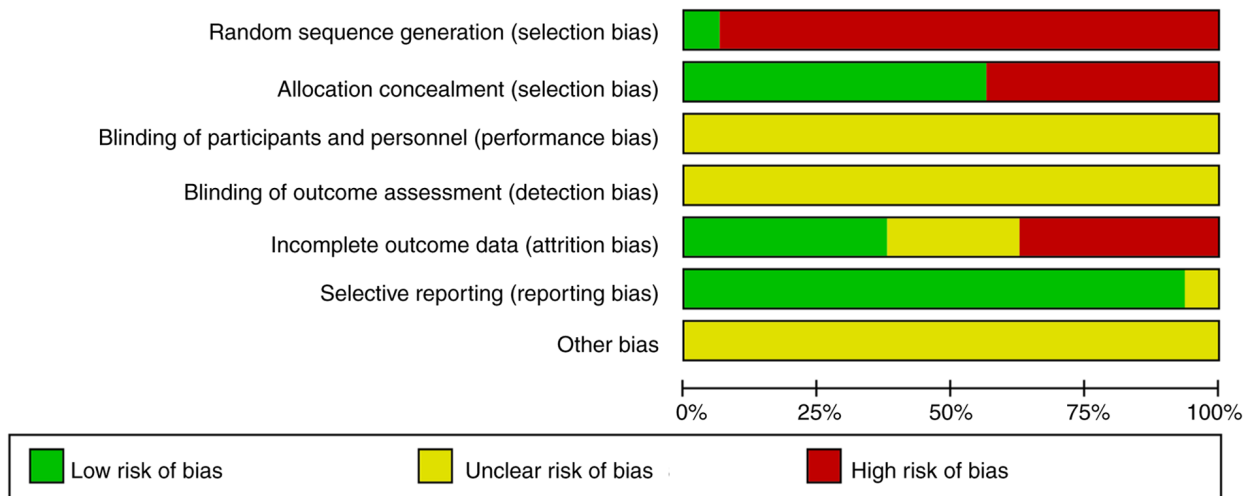


Figure 9. Risk of bias graph. Each risk of bias item is presented as a percentage across all included studies and indicates the proportional level for each risk of bias item.

by shifting the relationship between the glenohumeral joints and shifting the center of rotation downward. Although the requirement for rotator cuff integrity is lower than that of HA, the integrity of the greater tuberosity still has a significant effect on shoulder function after RSA (37). Additionally, RSA also has various complications such as periprosthetic fractures and shoulder loosening or dislocation (38).

The purpose of the present meta-analysis was to compare the efficacy of shoulder arthroplasty in the treatment of elderly osteoporotic proximal humerus fractures, as assessed by the Constant-Murley Shoulder Outcome Score, DASH score, ASES score and Oxford Shoulder score, as well as shoulder ROM and complications, in order to comprehensively and carefully compare the differences in postoperative

functional scores and complications between the RSA and HA groups. It was found that the RSA group had a significantly improved shoulder joint function Constant-Murley Shoulder Outcome Score (95% CI, 1.69-3.76;  $P < 0.001$ ), ASES score (95% CI, 11.81-24.88;  $P < 0.001$ ) and shoulder ROM (95% CI, 3.41-9.07;  $P < 0.001$ ), while the Oxford shoulder score [95% CI, 2.89-11.11],  $P < 0.001$ ] in the HA group was significantly improved compared with that in the RSA group. The present analysis did not find a significant difference in the DASH score and complications between the two groups.

Jain *et al* (39) suggested that healing of the greater tubercle of the shoulder joint is key to the recovery of ROM after shoulder arthroplasty, and the degree of dispersion of shoulder joint mobility after HA was greater than that of RSA.

	Random sequence generation (selection bias)	Allocation concealment (selection bias)	Blinding of participants and personnel (performance bias)	Blinding of outcome assessment (detection bias)	Incomplete outcome data (attrition bias)	Selective reporting (reporting bias)	Other bias
Baudi 2014	+	+	?	?	+	+	?
Bonnevalle 2016	-	-	?	?	+	+	?
Boyer 2017	-	+	?	?	?	+	?
Boyle 2012	-	-	?	?	-	+	?
Critchley 2020	-	+	?	?	-	+	?
Cuff 2013	-	+	?	?	+	+	?
Eduard 2014	-	-	?	?	-	+	?
Emilio 2014	-	+	?	?	+	+	?
Gallinet 2009	-	+	?	?	+	?	?
Garrigues 2012	-	+	?	?	?	+	?
Gregory 2015	-	-	?	?	-	+	?
Jonsson 2021	+	+	?	?	?	+	?
Michael 2017	-	-	?	?	-	+	?
Schairer 2015	-	-	?	?	-	+	?
Solomon 2016	-	-	?	?	?	+	?
Young 2010	-	+	?	?	+	+	?

Figure 10. Risk of bias summary. Methodological quality of the included studies according to a risk of bias tool that assessed randomization (sequence generation and allocation concealment), blinding (participants, personnel and outcome assessors), completeness of outcome data, selection of outcomes reported and other sources of bias. The items were scored with ‘yes’, ‘no’ or ‘unclear’.

It was concluded that HA had improved postoperative clinical outcomes compared with RSA in cases without complications. Wang *et al* (40) suggested that RSA is a preferable treatment option compared with HA in the treatment of complex proximal humerus fractures. In particular, RSA has obvious advantages in postoperative functional score and ROM of

anterior elevation, which is consistent with the results of the present study. Moreover, since the present meta-analysis performed a more systematic and detailed comparison on the ROM of shoulder joint abduction, internal/external rotation, etc., it was found that RSA was also superior to HA in abduction ROM, which may be related to the fact that RSA affects the deltoid muscle less and thus retains the complete abduction ability of the shoulder joint, while with the overfilled HA prosthesis, it is easy to put extra pressure on the rotator cuff, thus affecting part of the abduction function (41). Shukla *et al* (42) obtained similar results further confirming the outcomes of this meta-analysis. In addition, Wang *et al* (40) found that RSA also has obvious advantages in terms of postoperative complications. However, the present study found no significant difference in postoperative complications between the two groups. We hypothesize that this may be more common for RSA in cases of severe rotator cuff injury due to less soft tissue-induced instability, which increases the complication rates. As the biomechanical principles of RSA become more understood in the future, it is considered that the incidence of RSA complications will continue to decline. Similarly, the study by Kleim *et al* (43) also showed that postoperative function and score of RSA are improved compared with those of HA. RSA not only ensured the postoperative ROM of the shoulder joint but also greatly improved the quality of life of patients after surgery, which is consistent with the results of the present study. In summary, although there have been literature reports on associated topics in the past, the present study included a larger number of original literature studies and more qualified case samples. Therefore, it is suggested that the conclusions made on the present updated meta-analysis are more reliable to evaluate the difference between RSA and HA with respect to their therapeutic effects.

Shoulder arthroplasty has a good postoperative clinical effect in the treatment of elderly osteoporotic proximal humerus fractures. The present meta-analysis revealed that the postoperative functional score of most cases in the RSA group was greater than that in the HA group (44). We hypothesize that RSA has obvious advantages over HA in the treatment of elderly osteoporotic proximal humerus fractures. However, the present meta-analysis could not determine whether one surgical method was superior to the other in terms of postoperative complications. For example, one study showed that RSA has a risk of postoperative shoulder dislocation higher than that in HA (45). Considering that such fractures vary in the degree of severity due to the age of the patients and degree of osteoporosis among individual cases, the selection of specific surgical methods should still follow the principle of individualized treatment.

The present study has the following limitations, which need to be further improved upon: i) A total of 16 foreign literature studies were included in the meta-analysis evaluation system, of which only 1 randomized controlled trial was included with a low evidence level, while the combined analysis of retrospective studies, prospective studies and randomized controlled studies were bound to cause some bias in the results; ii) some of the literature included by using the NOS scale were of low quality; iii) among the outcome evaluation indexes, the same evaluation method included 9 publications at most and 3 at least, the heterogeneity between the groups also increased

slightly and the final follow-up time for outcome measures varied between different studies; iv) clinical studies require informed consent to participate from the patients; and v) this systematic review has not been prospectively registered in an appropriate registry (such as the PROSPERO database of the National Institute for Health Research). When it comes to the selection of specific treatment plans and medical ethics, low literature quality evaluation may also result in inevitable bias and affect the reliability of meta-analysis conclusions. Therefore, the aforementioned conclusions need to be further verified by larger sample, randomized controlled studies.

### Acknowledgements

Not applicable.

### Funding

The present study was supported by the Doctoral Research Start-Up Fund Project (grant no. BS202004).

### Availability of data and materials

The datasets used and/or analyzed during the current study are available from the corresponding author on reasonable request.

### Authors' contributions

PFH and SY were responsible for the design of the current study, and both performed the statistical analysis. PFH and SY confirm the authenticity of all the raw data. YPW, XDH and YL were responsible for the acquisition of data and were involved in the data analysis. XYL performed the interpretation of data. All authors have read and approved the final manuscript.

### Ethics approval and consent to participate

Not applicable.

### Patient consent for publication

Not applicable.

### Competing interests

The authors declare that they have no competing interests.

### References

- Lee S, Shin D and Hyun Y: Unrecognized bony bankart lesion accompanying a dislocated four-part proximal humerus fracture before surgery: A case report. *Clin Shoulder Elb* 25: 68-72, 2022.
- Erpala F, Tahta M, Öztürk T and Zengin Ç: Comparison of treatment options of three- and four-part humerus proximal fractures in patients over 50 years of age. *Cureus* 13: e17516, 2021.
- Stoddart M, Pearce O, Smith J, McCann P, Sheridan B and Al-Hourani K: Proximal humerus fractures: Reliability of Neer versus AO classification on plain radiographs and computed tomography. *Cureus* 12: e8520, 2020.
- Yang TC, Su YP and Chang MC: The elderly have similar outcomes compared to younger patients after ORIF with locking plate for comminuted proximal humerus fracture. *Acta Orthop Traumatol Turc* 53: 1-5, 2019.
- Schairer WW, Nwachukwu BU, Lyman S and Gulotta LV: Arthroplasty treatment of proximal humerus fractures: 14-Year trends in the United States. *Phys Sportsmed* 45: 92-96, 2017.
- Peker B, Polat AE, Carkci E, Senel A, Soydan C and Tuzuner T: Functional outcomes and complication analysis of plate osteosynthesis versus hemiarthroplasty in three-part and four-part proximal humerus fractures. *J Pak Med Assoc* 72: 57-61, 2022.
- Hao KA, Wright TW, Schoch BS, Wright JO, Dean EW, Struk AM and King JJ: Rate of improvement in shoulder strength after anatomic and reverse total shoulder arthroplasty. *JSES Int* 6: 247-252, 2021.
- Iordens GI, Mahabier KC, Buisman FE, Schep NW, Muradin GS, Beenen LF, Patka P, Van Lieshout EM and Den Hartog D: The reliability and reproducibility of the Hertel classification for comminuted proximal humeral fractures compared with the Neer classification. *J Orthop Sci* 21: 596-602, 2016.
- Kirkley A, Griffin S and Dainty K: Scoring systems for the functional assessment of the shoulder. *Arthroscopy* 19: 1109-1120, 2003.
- Page MJ, McKenzie JE, Bossuyt PM, Boutron I, Hoffmann TC, Mulrow CD, Shamseer L, Tetzlaff JM, Akl EA, Brennan SE, *et al*: The PRISMA 2020 statement: An updated guideline for reporting systematic reviews. *J Clin Epidemiol* 134: 178-189, 2021.
- Higgins JP, Altman DG, Gøtzsche PC, Jüni P, Moher D, Oxman AD, Savovic J, Schulz KF, Weeks L, Sterne JA, *et al*: The cochrane collaboration's tool for assessing risk of bias in randomised trials. *BMJ* 343: d5928, 2011.
- Stang A: Critical evaluation of the Newcastle-Ottawa scale for the assessment of the quality of nonrandomized studies in meta-analyses. *Eur J Epidemiol* 25: 603-605, 2010.
- Ioannidis JP, Haidich AB, Pappa M, Pantazis N, Kokori SI, Tektonidou MG, Contopoulos-Ioannidis DG and Lau J: Comparison of evidence of treatment effects in randomized and nonrandomized studies. *JAMA* 286: 821-830, 2001.
- Baudi P, Campochiaro G, Serafini F, Gazzotti G, Matino G, Rovesta C and Catani F: Hemiarthroplasty versus reverse shoulder arthroplasty: Comparative study of functional and radiological outcomes in the treatment of acute proximal humerus fracture. *Musculoskelet Surg* 98 (Suppl 1): S19-S25, 2014.
- Bonneville N, Tournier C, Clavert P, Ohl X, Sirveaux F and Saragaglia D: la Société française de chirurgie orthopédique et traumatologique: Hemiarthroplasty versus reverse shoulder arthroplasty in 4-part displaced fractures of the proximal humerus: Multicenter retrospective study. *Orthop Traumatol Surg Res* 102: 569-573, 2016.
- Boyer E, Menu G, Loisel F, Saadnia R, Uhring J, Adam A, Rochet S, Clappaz P, Baudouin E, Lascar T, *et al*: Cementless and locked prosthesis for the treatment of 3-part and 4-part proximal humerus fractures: Prospective clinical evaluation of hemi- and reverse arthroplasty. *Eur J Orthop Surg Traumatol* 27: 301-308, 2017.
- Boyle MJ, Youn SM, Frampton CM and Ball CM: Functional outcomes of reverse shoulder arthroplasty compared with hemiarthroplasty for acute proximal humeral fractures. *J Shoulder Elbow Surg* 22: 32-37, 2013.
- Critchley O, McLean A, Page R, Taylor F, Graves S, Lorimer M, Peng Y, Hatton A and Bain G: Reverse total shoulder arthroplasty compared to stemmed hemiarthroplasty for proximal humeral fractures: A registry analysis of 5946 patients. *J Shoulder Elbow Surg* 29: 2538-2547, 2020.
- Cuff DJ and Pupello DR: Comparison of hemiarthroplasty and reverse shoulder arthroplasty for the treatment of proximal humeral fractures in elderly patients. *J Bone Joint Surg Am* 95: 2050-2055, 2013.
- Alentorn-Geli E, Guirro P, Santana F and Torrens C: Treatment of fracture sequelae of the proximal humerus: Comparison of hemiarthroplasty and reverse total shoulder arthroplasty. *Arch Orthop Trauma Surg* 134: 1545-1550, 2014.
- Sebastiá-Forcada E, Cebrián-Gómez R, Lizaur-Utrilla A and Gil-Guillén V: Reverse shoulder arthroplasty versus hemiarthroplasty for acute proximal humeral fractures. A blinded, randomized, controlled, prospective study. *J Shoulder Elbow Surg* 23: 1419-1426, 2014.
- Gallinet D, Clappaz P, Garbuio P, Tropet Y and Obert L: Three or four parts complex proximal humerus fractures: Hemiarthroplasty versus reverse prosthesis: A comparative study of 40 cases. *Orthop Traumatol Surg Res* 95: 48-55, 2009.
- Garrigues GE, Johnston PS, Pepe MD, Tucker BS, Ramsey ML and Austin LS: Hemiarthroplasty versus reverse total shoulder arthroplasty for acute proximal humerus fractures in elderly patients. *Orthopedics* 35: e703-e708, 2012.

24. Cvetanovich GL, Chalmers PN, Verma NN, Nicholson GP and Romeo AA: Open reduction internal fixation has fewer short-term complications than shoulder arthroplasty for proximal humeral fractures. *J Shoulder Elbow Surg* 25: 624-631.e3, 2016.
25. Jonsson EÖ, Ekholm C, Salomonsson B, Demir Y and Olerud P; Collaborators in the SAPF Study Group: Reverse total shoulder arthroplasty provides better shoulder function than hemiarthroplasty for displaced 3- and 4-part proximal humeral fractures in patients aged 70 years or older: A multicenter randomized controlled trial. *J Shoulder Elbow Surg* 30: 994-1006, 2021.
26. van der Merwe M, Boyle MJ, Frampton CMA and Ball CM: Reverse shoulder arthroplasty compared with hemiarthroplasty in the treatment of acute proximal humeral fractures. *J Shoulder Elbow Surg* 26: 1539-1545, 2017.
27. Schairer WW, Nwachukwu BU, Lyman S, Craig EV and Gulotta LV: Reverse shoulder arthroplasty versus hemiarthroplasty for treatment of proximal humerus fractures. *J Shoulder Elbow Surg* 24: 1560-1566, 2015.
28. Solomon JA, Joseph SM, Shishani Y, Victoroff BN, Wilber JH, Gobezie R and Gillespie RJ: Cost analysis of hemiarthroplasty versus reverse shoulder arthroplasty for fractures. *Orthopedics* 39: 230-234, 2016.
29. Young SW, Segal BS, Turner PC and Poon PC: Comparison of functional outcomes of reverse shoulder arthroplasty versus hemiarthroplasty in the primary treatment of acute proximal humerus fracture. *ANZ J Surg* 80: 789-793, 2010.
30. Vrotsou K, Ávila M, Machón M, Mateo-Abad M, Pardo Y, Garin O, Zaror C, González N, Escobar A and Cuéllar R: Constant-Murley score: Systematic review and standardized evaluation in different shoulder pathologies. *Qual Life Res* 27: 2217-2226, 2018.
31. Chelli M, Levy Y, Lavoué V, Clowez G, Gonzalez JF and Boileau P: The 'auto-constant': Can we estimate the Constant-Murley score with a self-administered questionnaire? A pilot study. *Orthop Traumatol Surg Res* 105: 251-256, 2019.
32. Atıcı T, Ermutlu C, Yerebakan S, Özyalçın A and Durak K: Primary treatment of complex proximal humerus fractures using humelock cementless reversible shoulder arthroplasty in the elderly. *Ulus Travma Acil Cerrahi Derg* 27: 457-464, 2021.
33. Ratajczak K, Szczęsny G and Małydyk P: Comminuted fractures of the proximal humerus-principles of the diagnosis, treatment and rehabilitation. *Ortop Traumatol Rehabil* 21: 77-93, 2019.
34. Davey MS, Hurley ET, Anil U, Condren S, Kearney J, O'Tuile C, Gaafar M, Mullett H and Pauzenberger L: Management options for proximal humerus fractures-a systematic review & network meta-analysis of randomized control trials. *Injury* 53: 244-249, 2022.
35. Fraser AN, Bjørndal J, Wagle TM, Karlberg AC, Lien OA, Eilertsen L, Mader K, Apold H, Larsen LB, Madsen JE and Fjalestad T: Reverse shoulder arthroplasty is superior to plate fixation at 2 years for displaced proximal humeral fractures in the elderly: A multicenter randomized controlled trial. *J Bone Joint Surg Am* 102: 477-485, 2020.
36. Pokorný D, Fulín P, Heřt J, Landor I, Štefan J and Sosna A: Reverse total shoulder arthroplasty: 14-Year clinical experience with 496 performed arthroplasties. *Acta Chir Orthop Traumatol Cech* 88: 401-411, 2021.
37. Hochreiter B, Hasler A, Hasler J, Kriechling P, Borbas P and Gerber C: Factors influencing functional internal rotation after reverse total shoulder arthroplasty. *JSES Int* 5: 679-687, 2021.
38. Boileau P: Complications and revision of reverse total shoulder arthroplasty. *Orthop Traumatol Surg Res* 102 (1 Suppl): S33-S43, 2016.
39. Jain NP, Mannan SS, Dharmarajan R and Rangan A: Tuberosity healing after reverse shoulder arthroplasty for complex proximal humeral fractures in elderly patients-does it improve outcomes? A systematic review and meta-analysis. *J Shoulder Elbow Surg* 28: e78-e91, 2019.
40. Wang J, Zhu Y, Zhang F, Chen W, Tian Y and Zhang Y: Meta-analysis suggests that reverse shoulder arthroplasty in proximal humerus fractures is a better option than hemiarthroplasty in the elderly. *Int Orthop* 40: 531-539, 2016.
41. Goetti P, Denard PJ, Collin P, Ibrahim M, Mazzolari A and Lädermann A: Biomechanics of anatomic and reverse shoulder arthroplasty. *EFORT Open Rev* 6: 918-931, 2021.
42. Shukla DR, McAnany S, Kim J, Overley S and Parsons BO: Hemiarthroplasty versus reverse shoulder arthroplasty for treatment of proximal humeral fractures: A meta-analysis. *J Shoulder Elbow Surg* 25: 330-340, 2016.
43. Kleim BD, Garving C and Brunner UH: RSA, TSA and PyC hemi-prostheses: Comparing indications and clinical outcomes using a second-generation modular short-stem shoulder prosthesis. *Arch Orthop Trauma Surg* 141: 1639-1648, 2021.
44. Nelson PA, Kwan CC, Tjong VK, Terry MA and Sheth U: Primary versus salvage reverse total shoulder arthroplasty for displaced proximal humerus fractures in the elderly: A systematic review and meta-analysis. *J Shoulder Elb Arthroplast* 4: 2471549220949731, 2020.
45. Salazar DH, Bialek SE and Garbis NG: Acromioclavicular cerclage in reverse total shoulder arthroplasty for recurrent instability. *J Shoulder Elbow Surg* 31: e376-e385, 2022.



This work is licensed under a Creative Commons Attribution-NonCommercial-NoDerivatives 4.0 International (CC BY-NC-ND 4.0) License.