

ORIGINAL ARTICLE

Alagille syndrome and risk for hepatocellular carcinoma: Need for increased surveillance in adults with mild liver phenotypes

Emma A. Schindler¹  | Melissa A. Gilbert²  | David A. Piccoli³ |
Nancy B. Spinner² | Ian D. Krantz¹ | Kathleen M. Loomes³

¹Division of Human Genetics, Roberts Individualized Medical Genetics Center, Children's Hospital of Philadelphia and The Perelman School of Medicine at the University of Pennsylvania, Philadelphia, Pennsylvania

²Division of Genomic Diagnostics, Department of Pathology and Laboratory Medicine, Children's Hospital of Philadelphia and The Perelman School of Medicine at the University of Pennsylvania, Philadelphia, Pennsylvania

³Division of Pediatric Gastroenterology, Hepatology and Nutrition, Children's Hospital of Philadelphia and Department of Pediatrics, The Perelman School of Medicine at the University of Pennsylvania, Philadelphia, Pennsylvania

Correspondence

Kathleen M. Loomes, Division of Pediatric Gastroenterology, Hepatology, and Nutrition, The Children's Hospital of Philadelphia, 3401 Civic Center Boulevard, Philadelphia, PA, 19104, USA.
Email: loomes@email.chop.edu

Funding information

Fred and Suzanne Biesecker Pediatric Liver Center at the Children's Hospital of Philadelphia, Grant/Award Number: n/a; National Institutes of Health, Grant/Award Number: R01-DK053104

Abstract

Alagille syndrome (ALGS) is a multisystem autosomal dominant developmental disorder caused predominantly by pathogenic variants in *JAGGED1* (*JAG1*), and also by pathogenic variants in *NOTCH2* in a much smaller number of individuals. Clinical presentation is highly variable and includes liver, heart, eye, skeleton, and facial abnormalities, with a subset of individuals also presenting with kidney, vascular, and central nervous system phenotypes. Hepatocellular carcinoma (HCC) is a rare complication of ALGS, though little is known about its incidence or etiology among affected individuals. Previous reports have identified HCC occurrence in both pediatric and adult cases of ALGS. We present a case report of HCC in a 58-year-old woman with a pathogenic *JAG1* variant and no overt hepatic features of ALGS. Through a comprehensive literature review, we compile all reported pediatric and adult cases, and further highlight one previously reported case of HCC onset in an adult ALGS patient without any hepatic disease features, similar to our own described patient. Our case report and literature review suggest that ALGS-causing variants could confer risk for developing HCC regardless of phenotypic severity and highlight a need for a cancer screening protocol that would enable early detection and treatment in this at-risk population.

KEYWORDS

cholestasis, hepatocellular carcinoma, *JAG1*, liver disease, notch signaling

1 | INTRODUCTION

Alagille syndrome (ALGS, OMIM #118450), also known as syndromic bile duct paucity or arteriohepatic dysplasia, is a multisystem autosomal dominant developmental disorder with highly variable expression. This syndrome was first reported by Alagille et al. in 1969 with an emphasis on the hepatic manifestations, and has since been identified as the most common form of genetic cholestatic liver disease (Alagille et al., 1987; Alagille, Habib, & Thomassin, 1969). ALGS is also

characterized by abnormalities of the heart, eye, and skeleton, including a characteristic facial appearance, as well as less common features involving the kidneys, vasculature, and central nervous system (Emerick et al., 1999; Emerick et al., 2005). The disease has been recognized as a dysfunction of the Notch signaling pathway, an integral developmental process involved in cell fate determination (Huang, Li, Zheng, & Wei, 2019; Morell, Fiorotto, Fabris, & Strazzabosco, 2013). The majority of ALGS-associated pathogenic variants (94.3%) have been identified in the *JAGGED1* (*JAG1*) gene, which encodes a Notch

This is an open access article under the terms of the Creative Commons Attribution-NonCommercial-NoDerivs License, which permits use and distribution in any medium, provided the original work is properly cited, the use is non-commercial and no modifications or adaptations are made.

© 2020 The Authors. *American Journal of Medical Genetics Part A* published by Wiley Periodicals LLC.

ligand, with a smaller percentage of pathogenic variants (2.5%) identified in the *NOTCH2* gene, which encodes a Notch receptor (Gilbert et al., 2019; Kamath et al., 2012; Li et al., 1997; McDaniell et al., 2006; Oda et al., 1997; Saleh, Kamath, & Chitayat, 2016). A small number (3.2%) of individuals meet the clinical criteria for ALGS, but do not have a pathogenic variant detected in either disease-causing gene (Gilbert et al., 2019).

To date, 694 pathogenic variants in *JAG1* and 19 pathogenic variants in *NOTCH2* have been described in individuals with clinical features of ALGS (Gilbert et al., 2019). *JAG1* variants are most typically protein-truncating, and haploinsufficiency is believed to be the disease-causing mechanism (Oda et al., 1997; Saleh et al., 2016; Spinner et al., 2001). The mechanism by which *NOTCH2* variants cause ALGS is not clear, as only 19 have been described, although limited functional analysis has demonstrated reduced Notch signaling for a handful of described variants (Gilbert et al., 2019; Kamath et al., 2012). No studies have shown a definitive correlation between type of mutation and ALGS phenotype or severity (Crosnier et al., 1999; McDaniell et al., 2006; Mitchell, Gilbert, & Loomes, 2018; Spinner et al., 2001).

Isolated case reports point to an association of hepatocellular carcinoma (HCC) among individuals with ALGS (Békássy, Garwicz, Wiebe, Hägerstrand, & Jensen, 1992; Bhadri et al., 2005; Chiaretti, Zampino, Botto, & Polidori, 1992; Kim et al., 2005; Pérez Becerra et al., 1991; Rabinovitz, Imperial, Schade, & Van Thiel, 1989; Schwarzenberg, Grothe, Sharp, Snover, & Freese, 1992; Syed, Khalili, & Guindi, 2008; Tsai et al., 2010; Valampampil, Shanmugam, Vij, Reddy, & Rela, 2020; Wegmann, Evison, Schaub, Kist, & Vest, 1996). HCC has been documented in children and adults with ALGS phenotypes ranging from mild to severe and with differing degrees of liver involvement. The occurrence of HCC in multiple individuals with subtle clinical features (and some with little to no apparent liver involvement) has caused some to suggest that ALGS-causing variants could contribute to the development of HCC by interfering with Notch signaling. Abnormalities in Notch signaling have previously been implicated in HCC and intrahepatic cholangiocarcinoma, and mutations in *JAG1* and *NOTCH2* have been identified in a variety of human tumor tissues (Lu et al., 2016; Tate et al., 2019). However, the exact role of Notch in the development of HCC remains unclear (Morell et al., 2013).

We present a case of advanced HCC in a 58-year-old woman with a pathogenic *JAG1* variant and subtle clinical features of ALGS as well as a comprehensive review of all reported cases ($n = 34$) of HCC in individuals with ALGS, in order to highlight the high degree of phenotypic variability among ALGS patients who develop HCC. We also summarize all *JAG1* and *NOTCH2* pathogenic variants reported in HCC and other cancers and investigate possible mechanisms by which ALGS-causing variants could predispose affected individuals to developing HCC, with a particular emphasis on those with mild liver phenotypes. Finally, we highlight a previously published case report of HCC occurring in a 46-year-old man who, similarly to the proband we describe, has very mild features of ALGS including an absence of hepatic phenotypes (Keeffe, Pinson, Ragsdale, & Zonana, 1993). This report draws attention to the heightened risk for the development of HCC among individuals with ALGS, cautions that liver disease severity

is not necessary for HCC onset, and recommends a more targeted cancer screening protocol for individuals with ALGS.

2 | METHODS

2.1 | Literature review

A literature search was performed on PubMed, with a last check on November 9, 2020 for all instances of HCC and Alagille syndrome, without language or date restrictions. A query using the terms “hepatocellular carcinoma” and “Alagille syndrome” or “arteriohepatic dysplasia” yielded 28 publications representing 34 unique cases published between 1986 and 2020. Reference lists from cited publications were manually checked for additional cases. Complete text was unavailable for two of the 28 publications. For these cases, ALGS and HCC were confirmed and limited clinical information was obtained from the abstract and citing articles.

All included individuals were confirmed to have intrahepatic bile duct paucity and three of the five clinical criteria established by Alagille et al., an affected first-degree family member and two of the clinical criteria, and/or a confirmed *JAG1* or *NOTCH2* mutation (Alagille et al., 1987; Alagille, Odievre, Gautier, & Dommergues, 1975; Emerick et al., 1999; Saleh et al., 2016). In all cases, HCC was confirmed by imaging and/or pathology. In most cases, malignancy was also reflected by elevated serum α -fetoprotein levels.

A comprehensive list of *JAG1* and *NOTCH2* variants previously identified in human tumor tissues, including HCC, was curated using the Catalogue of Somatic Mutations in Cancer (COSMIC) database (cancer.sanger.ac.uk; Tate et al., 2019). Allele frequency was obtained for each variant using the Genome Aggregation Database (gnomAD; <https://gnomad.broadinstitute.org>; Karczewski et al., 2020).

2.2 | Ethical considerations

This study was approved by the Institutional Review Board at the Children's Hospital of Philadelphia, and written informed consent was obtained from parents or subjects 18 years or older in accordance with the Declaration of Helsinki.

3 | RESULTS

3.1 | Case report

A 58-year-old woman with ALGS presented with a persistent productive cough, reflux, and weight loss and was referred for complete abdominal ultrasound as well as frontal and lateral radiographs of the chest. She was diagnosed with ALGS around age 35 by molecular confirmation of a pathogenic *JAG1* variant, identified in genomic DNA from whole blood, after the same variant (c.693_694del; p.Arg231Serfs*10) was identified in her two sons (Li et al., 1997, see

TABLE 1 Summary of the presented case and ALGS-affected family members

Patient	Age ALGS diagnosed	Current age	Cirrhosis (Y/N)	Bile duct paucity (Y/N)	Cholestasis (Y/N)	Other features	Genetic findings	Age HCC diagnosed	AFP (ng/ml)	Treatment/outcome
Proband	35	Deceased	N	N	N	Facies, benign heart murmur, posterior embryotoxon	JAG1 c.693_694del (p. Arg231Serfs*10)	58	3.1	Declined HCC treatment and died at age 59
Son 1	14 months	34	Y	Y	Y	Facies, pulmonic stenosis, posterior embryotoxon, butterfly vertebrae, end stage liver disease requiring LT at age 19	JAG1 c.693_694del (p. Arg231Serfs*10)	NA	NA	NA
Son 2	1 month	32	Y	Y	Y	Facies, pulmonic stenosis, posterior embryotoxon, end stage liver disease requiring LT at age 13	JAG1 c.693_694del (p. Arg231Serfs*10)	NA	NA	NA

Abbreviations: AFP, α -fetoprotein; ALGS, Alagille syndrome; HCC, hepatocellular carcinoma; LT, liver transplantation; NA, not applicable.

“Family 1”). Both sons had classic features of ALGS, including severe cholestasis and progressive liver disease requiring transplantation, whereas she presented with mild clinical features and had no history of hepatic complications. Despite her mild presentation, we do not have evidence to suggest that the proband was mosaic for the JAG1 variant (Li et al., 1997). Phenotypic features of the proband and her sons are summarized in Table 1.

An abdominal ultrasound revealed a large heterogeneous hyper-vascular mass in the right lobe of the liver measuring 10.8 × 12.9 × 11.8 cm as well as mild bilateral renal cortical atrophy. The mass was initially presumed to be a cavernous hemangioma, with HCC also in the differential diagnosis. Subsequent multiplanar magnetic resonance imaging (MRI) with contrast performed 4 months later revealed that the mass had grown to measurements of 14.3 × 10.9 × 14.2 cm, occupying most of the right hepatic lobe, suspicious for hepatocellular neoplasm (Figure 1). The proband had no history of known risk factors for developing HCC, such as obesity, alcoholism, Hepatitis B infection (HBV), Hepatitis C infection (HCV), or non-alcoholic fatty liver disease (NAFLD; Desai, Sandhu, Lai, & Sandhu, 2019).

At the time of the MRI, the proband presented with elevated gamma-glutamyltransferase as well as abnormal levels of albumin, direct bilirubin, alkaline phosphatase, aspartate aminotransferase (AST), and alanine aminotransferase (ALT), summarized in Table 2. Serum levels of tumor marker α -fetoprotein were within normal range. The MRI was consistent with HCC and she was referred to Hepatology and Gastroenterology specialists for management of

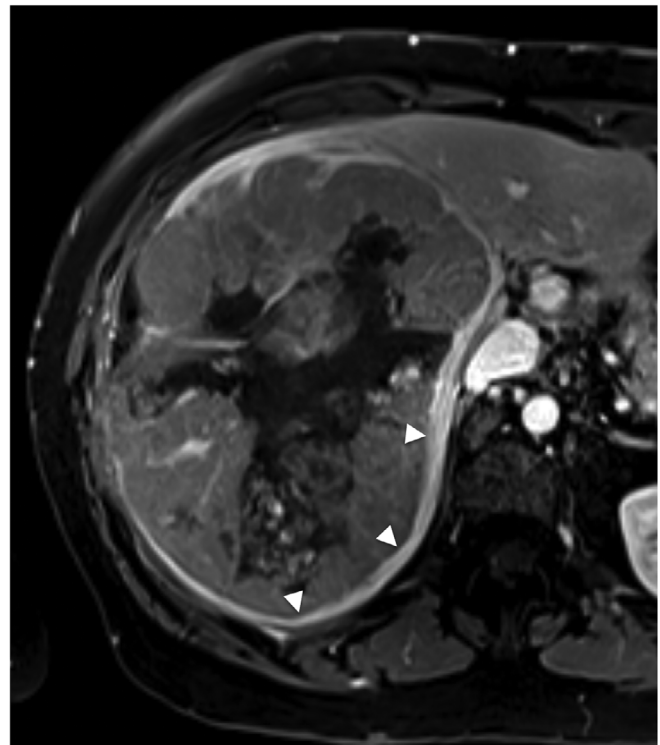


FIGURE 1 T1-weighted abdominal MRI reveals a large heterogeneous mass occupying most of the right hepatic lobe. Features consistent with HCC include washout in the portal venous phase, as well as rim enhancement (arrowheads)

TABLE 2 Summary of abnormal laboratory test results in the proband

Test	Normal range	At initial MRI	Time since initial MRI		
			2 months	6 months	15 months
Hepatic function panel					
Albumin (g/dl)	3.6–5.1	2.9	3.3	2.9	2.7
Total bilirubin (mg/dl)	0.2–1.2	0.9	0.8	1.3	1.5
Direct bilirubin (mg/dl)	≤0.2	0.3	0.2	0.6	0.8
Alkaline phosphatase (U/L)	33–130	237	286	869	1,256
AST (U/L)	10–35	309	108	119	265
ALT (U/L)	6–29	142	38	60	102
GGT (U/L)	3–70	250	–	–	–
Tumor marker					
AFP (ng/ml)	<6.0	3.1	3.7	3.5	–

Abbreviations: AFP, alpha-fetoprotein; ALT, alanine aminotransferase; AST, aspartate aminotransferase; GGT, gamma-glutamyltransferase.

Sample	Variant	Amino acid change	Reported in ALGS?	gnomAD frequency ^a
1	c.48C > A	p.(=)	No	2.31×10^{-5}
2	c.82-85C > G	p.?	No	Absent
3	c.429 T > C	p.(=)	No	Absent
4	c.886 + 94A > C	p.?	No	Absent
5	c.2889del	p.Phe963Leufs*7	No ^b	Absent
6	c.3647A > G	p.Tyr1216Cys	No	Absent

Note: <http://cancer.sanger.ac.uk>.

^a<https://gnomad.broadinstitute.org>.

^bAlthough not reported in ALGS, this frameshift would be expected to cause ALGS. It is possible that this patient had undiagnosed ALGS.

TABLE 5 Summary of JAG1 variants identified in human HCC samples

related complications. The size of the tumor at initial diagnosis precluded consideration of liver transplantation (LT) as a therapeutic option. The proband declined chemotherapy, ablation, or other therapeutic interventions, and no biopsy or tumor resection was performed. Somatic cancer testing was therefore unavailable.

She presented with abdominal pain 6 months later, at which time a second MRI with contrast revealed that the mass had grown to measurements of $15.6 \times 11.3 \times 16.6$ cm, exerting a stable mass effect on the right kidney. A repeat hepatic function panel obtained at this time revealed abnormal albumin, bilirubin, alkaline phosphatase, ALT, and AST (Table 2). Of note, serum α -fetoprotein levels remained within normal range throughout the course of illness. Alkaline phosphatase, AST, and ALT levels continued to increase over time (Table 2). Five months after the second MRI, the proband presented to the emergency department with acute kidney injury, hyperkalemia, and ascites. She was transitioned to home palliative care the following day and died 5 months later at the age of 59, 15 months following diagnosis.

3.2 | Literature review

We identified 28 publications describing 21 cases of HCC in children with AGLS, and 13 in adults (Tables 3 and 4). All pediatric patients

with a described liver phenotype had paucity of intrahepatic bile ducts and cholestasis prior to developing HCC. The majority of adult patients with a described liver phenotype also had bile duct paucity and cholestasis, with the exception of one patient who, like our proband, had an attenuated form of ALGS with no overt liver involvement (Keeffe et al., 1993). Most pediatric cases arose on a background of a cirrhotic liver ($n = 16$, of 18 cases that described presence or absence of cirrhosis). In contrast, only a few adult cases arose on a background of cirrhosis ($n = 4$, of nine cases that described this information). The presence and severity of other syndromic features, including characteristic facies and eye, heart, or skeletal abnormalities, was highly variable in both children and adults.

ALGS was identified prior to the diagnosis of HCC in the majority of cases, with the exception of one patient who died of HCC, where ALGS was diagnosed at postmortem evaluation (Wegmann et al., 1996).

Many of the reports pre-dated the discovery of JAG1 as the primary disease gene in 1997, and genetic data, obtained from screening genomic DNA extracted from whole blood, were available for only five patients, including the proband. Three had confirmed pathogenic JAG1 variants, including: an unspecified de novo variant in a protein-coding region (Patient 12, Table 3), the previously described, known pathogenic, missense variant c.551 G > A; p.Arg184His (Patient

TABLE 3 Summary of HCC cases reported in pediatric patients with ALGS

Patient	Age (years)	AFP (ng/ml)	Cirrhosis (Y/N)	Bile duct		Cholestasis (Y/N)	Other features	Family history	Genetic findings	Treatment/outcome	Reference
				paucity (Y/N)	paucity (Y/N)						
1	3.5	31,800	Y	Y	Y	Y	Facies, pulmonic stenosis, pruritus, jaundice, xanthomas, growth delay	Mother and maternal grandmother with ALGS. Mother had pulmonic stenosis and no neonatal cholestasis.	NR	Tumor invasion precluded LT; patient died	Kaufman et al., 1987; Ong, Williams, Anderson, & Kaplan, 1986
2	16	NR	Y	Y	Y	Y	Facies, pulmonic stenosis, pruritus, jaundice, delayed puberty, history of giant cell hepatitis	Brother and sister with ALGS and HCC. Second sister with ALGS and suspected HCC.	NR	Died of variceal hemorrhage	Rabinovitz et al., 1989
3	2	NR	Y	NR	NR	NR	Facies, systolic murmur, jaundice	Brother and sister with ALGS and HCC. Second sister with ALGS and suspected HCC.	NR	Metastasis precluded LT; patient died	Rabinovitz et al., 1989
4	4	927.3	Y	Y	Y	Y	Facies, vertebral abnormalities, posterior embryotoxon, pulmonic stenosis, pruritus, jaundice	NR	NR	Died waiting for LT	Békássy et al., 1992
5	7	NR	NR	Y	Y	Y	Facies, xanthomas	NR	NR	NR; patient died from rupture of HCC	Castañeda et al., 1992
6	17	400	N	Y	Y	Y	Facies, posterior embryotoxon, pulmonic stenosis, growth delay	NR	NR	Chemotherapy; patient died	Chiaretti et al., 1992
7	1.4	2,890	Y	NR	NR	NR	Facies, posterior embryotoxon, pulmonic stenosis, jaundice	No family history	NR	LT; stable 20 months post-op	Kim et al., 2005
8	4	414	Y	Y	NR	NR	Facies, vertebral abnormalities, pulmonic stenosis, jaundice	No family history	NR	No treatment; patient died	Kim et al., 2005

(Continues)

TABLE 3 (Continued)

Patient	Age (years)	AFP (ng/ml)	Cirrhosis (Y/N)	Bile duct paucity (Y/N)	Cholestasis (Y/N)	Other features	Family history	Genetic findings	Treatment/outcome	Reference
9	7	344.43	Y	Y	NR	Facies, vertebral abnormalities, growth delay, corneal opacity, pruritus, jaundice	Younger brother with growth delay but no confirmed ALGS	NR	No treatment; patient died	Kim et al., 2005
10	4	264,200	N	NR	Y	Facies, pulmonic stenosis, pruritus, jaundice	No family history	NR	No treatment; patient died	Bhadri et al., 2005
11	4	8,155	Y	NR	Y	Facies, vertebral abnormalities, pulmonic stenosis, pruritus	Father and father's sister with ALGS. Father's sister died of associated congenital heart disease.	No <i>JAG1</i> pathogenic variant	LT; died 3 months post-op of <i>Escherichia coli</i> septicemia	Bhadri et al., 2005
12	3	NR	Y	Y	NR	Facies, vertebral abnormalities, pulmonic stenosis, jaundice	No family history	de novo pathogenic <i>JAG1</i> variant in a protein-coding region	LT; outcome NR	Wetli, Gralla, Schibli, & Stranzinger, 2010
13	15	1	Y	NR	NR	NR	NR	NR	Transarterial chemoembolization	Pham, Gallo, Conception, Esquivel, & Bonham, 2015
14	8	1,650	Y	NR	NR	NR	NR	NR	LT; alive	Geramizadeh et al., 2017
15	15	2	Y	NR	NR	NR	NR	NR	Transarterial chemoembolization followed by LT; alive	Weiss et al., 2018
16	13	2.1	Y	NR	NR	NR	NR	NR	LT; alive	D'Souza et al., 2018
17	1.5	3.1	Y	Y	Y	Facies, vertebral abnormalities, pulmonic stenosis, xanthomas, decompensated liver disease	No family history	<i>JAG1</i> c.551G > A (p.Arg184His)	LT; alive	Valamparampil et al., 2019; Valamparampil et al., 2020
18	1.7	2	Y	Y	NR	Aortic stenosis, xanthomas, decompensated liver disease	No family history	NR	LT; alive	Valamparampil et al., 2019; Valamparampil et al., 2020

TABLE 3 (Continued)

Patient	Age (years)	AFP (ng/ml)	Cirrhosis (Y/N)	Bile duct paucity (Y/N)	Cholestasis (Y/N)	Other features	Family history	Genetic findings	Treatment/outcome	Reference
19	2	1	Y	Y	Y	Vertebral abnormalities, pulmonary stenosis, decompensated liver disease	No family history	NOTCH2 c.5830G > A (p. Gly1944Ser)	LT; alive	Valamparampil et al., 2019; Valamparampil et al., 2020
20	9	NR	Y	NR	NR	NR	NR	NR	Neoadjuvant chemo followed by LT; died from dialysis complication	D'Souza et al., 2020
21	3	NR	Y	NR	NR	NR	NR	NR	Neoadjuvant chemo followed by LT; died from relapse in lung and abdomen	D'Souza et al., 2020

Abbreviations: AFP, α -fetoprotein; ALGS, Alagille syndrome; HCC, hepatocellular carcinoma; LT, liver transplantation; NR, not reported.

17, Table 3), and the frameshift variant c.693_694del; p. Arg231Serfs*10 described in the proband (Table 1). One patient had a suspected pathogenic *NOTCH2* variant, c.5830G > A (p.Gly1944Ser; Patient 19, Table 3). Genetic testing revealed no pathogenic variant in one patient, despite having a family history of ALGS (Patient 11, Table 3). Four of these five patients had severe liver disease, with the proband being the exception. Of the patients with confirmed *JAG1* or *NOTCH2* variants, only the proband had a family history of ALGS (Table 1). Somatic cancer testing of tumor samples was not available in any of the case reports or for our proband.

When the additional reports that do not contain genetic data are added to this group, a total of seven patients (20%) had a family history of ALGS, including the proband. Three of these were siblings with severe ALGS who all developed HCC (Patients 2 and 3, Table 3; Patient 24, Table 4). Eight patients (23%) had no family history of ALGS and this information was unavailable for the remaining 20 patients (57%; Tables 3 and 4).

3.3 | Somatic variant review

A search of the Catalogue of Somatic Mutations in Cancer (COSMIC) database (cancer.sanger.ac.uk) yielded 719 human tumor samples (out of 38,357 sequenced) with *JAG1* variants (1.9%) and 2,457 human tumor samples (out of 59,346 sequenced) with *NOTCH2* variants (4.1%). *JAG1* variants have been described in 28 unique tissue types, with variants in the liver, breast, large intestine, endometrium, and skin occurring at the highest frequency (Tate et al., 2019). Of those variants, 44.9% were missense, 3.9% were nonsense, and 3.4% were frameshift. Other types of *JAG1* variants described in cancer are summarized in Table S1. Of the 20,411 liver tumor samples included in COSMIC, 3,289 were obtained from HCC. Six HCC samples had *JAG1* variants and 24 had *NOTCH2* variants (Tables 5 and 6; Tate et al., 2019). No *JAG1* or *NOTCH2* variants described in human HCC samples have also been identified in individuals with ALGS. However, the *JAG1* frameshift p.Phe963Leufs*7 reported in Table 5 would be expected to cause ALGS and it is possible that this patient had undiagnosed ALGS.

4 | DISCUSSION

We describe an individual with mild ALGS who presented with HCC and no overt ALGS liver phenotype. In addition, we highlight a similar case report of a second adult with mild ALGS presenting with HCC who also did not have an overt ALGS liver phenotype (Keeffe et al., 1993). Though their incidence is unknown, hepatic lesions are believed to be rare complications of ALGS (Rapp, Bellah, Maya, Pawel, & Anupindi, 2017). Lesions can manifest as regenerative nodules, as a form of compensatory hyperplasia, or as HCC. Regenerative nodules are relatively benign, homogenous masses that do not usually necessitate clinical intervention (Alhammad, Kamath, Chami, Ng, & Chavhan, 2016; Bhadri et al., 2005; Ennaifer et al., 2016; Rapp

TABLE 4 Summary of HCC cases reported in adult patients with ALGS

Patient	Age (year)	AFP (ng/ml)	Cirrhosis (Y/N)	Bile duct		Cholestasis (Y/N)	Other features	Family history	Genetic findings	Treatment/outcome	Reference
				paucity (Y/N)	paucity (Y/N)						
22	36	275	N	Y	Y	Pruritis, jaundice	NR	NR	Chemotherapy; outcome NR	Adams, 1986	
23	31	NR	NR	Y	NR	Facies, vertebral abnormalities, posterior embryotoxon, pulmonic stenosis	NR	NR	Metastasis precluded LT; patient died	duCret, Cefalu, Alford, Drake, & Boudreau, 1988	
24	25	207,000	N	Y	Y	Facies, posterior embryotoxon, pulmonic stenosis, jaundice, growth delay, skeletal abnormalities	Two brothers with ALGS and HCC. Sister with ALGS and suspected HCC.	NR	Died of variceal hemorrhage	Rabinovitz et al., 1989	
25	48	2,800	N	Y	NR	Facies, previous HCC (resected), jaundice (spontaneous resolution in adolescence)	NR	NR	NR	Bail et al., 1990	
26	43	NR	NR	Y	NR	NR	Son with ALGS	NR	NR	Pérez Becerra et al., 1991	
27	31	NR	N	Y	NR	Facies, posterior embryotoxon, pulmonic stenosis, developmental delay, growth delay, pruritus	NR	NR	NR; patient died	Schwarzenberg et al., 1992	
28	46	901	NR	N	N	Facies	NR	NR	LT; outcome NR	Keeffe et al., 1993	
29	31	NR	NR	NR	NR	NR; ALGS not diagnosed until postmortem evaluation of medical history	NR	NR	NR; patient died	Wegmann et al., 1996	
30	42	NR	Y	Y	NR	Pruritus	NR	NR	NR	Syed et al., 2008	
31	29	2,500	N	Y	Y	Facies, pulmonic stenosis	NR	NR	Successful resection	Tsai et al., 2010	
32	25	NR	Y	NR	NR	NR	NR	NR	LT; patient died of sepsis	Vinayak et al., 2017	
33	41	3.7	Y	Y	NR	NR	NR	NR	Transarterial chemoembolization followed by LT due to recurrence; alive	Galvez et al., 2020	
34	38	187	Y	NR	NR	NR	NR	NR	Right hepatectomy; patient died of infectious complications	(Schoen, Porta, & Horvat, 2021)	

Abbreviations: AFP, α -fetoprotein; ALGS, Alagille syndrome; HCC, hepatocellular carcinoma; LT, liver transplantation; NR, not reported.

TABLE 6 Summary of *NOTCH2* variants identified in human HCC samples

Sample	Variant	Amino acid change	Reported in ALGS?	gnomAD frequency ^a
1	c.61G > A	p.Ala21Thr	No	0.115
2	c.155 + 5264A > G	p.?	No	Absent
3	c.155 + 10578C > T	p.?	No	Absent
4	c.344G > A	p.Cys115Tyr	No	Absent
5	c.415 + 14C > T	p.?	No	Absent
6	c.416-2,629 T > C	p.?	No	Absent
7	c.444C > T	p.(=)	No	3.99×10^{-6}
8	c.614A > G	p.Tyr205Cys	No	Absent
9	c.760G > A	p.Gly254Arg	No	Absent
10	c.832G > T	p.Gly278Trp	No	Absent
11	c.875-8376G > T	p.?	No	Absent
12	c.921 T > C	p.(=)	No	7.97×10^{-6}
13	c.1082C > G	p.Ser361Cys	No	Absent
14	c.1362G > C	p.Glu454Asp	No	Absent
6	c.2026 + 650G > C	p.?	No	Absent
15	c.2704G > T	p.Gly902Cys	No	Absent
16	c.2752 + 1,182 T > A	p.?	No	Absent
17	c.2771G > T	p.Gly924Val	No	Absent
18	c.3184-1246A > T	p.?	No	Absent
19,20	c.3376 T > C	p.Cys1126Arg	No	Absent
21	c.3424A > G	p.Thr1142Ala	No	Absent
5	c.3656-345G > T	p.?	No	Absent
22	c.4391C > T	p.Ala1464Val	No	Absent
23	c.5360G > A	p.Arg1787Gln	No	3.98×10^{-6}
24	c.5533A > C	p.Ser1845Arg	No	Absent

Note: <http://cancer.sanger.ac.uk>.

^a<https://gnomad.broadinstitute.org>.

et al., 2017; Syed et al., 2008; Wetli et al., 2010). On the other end of the spectrum, HCCs are malignant, characterized by one or more heterogeneous tumor(s) prone to necrosis, hemorrhage, and metastasis (Kaufman et al., 1987; Kim et al., 2005; Syed et al., 2008). Malignancy is often, but not always (as in the case of our proband), reflected in elevated serum α -fetoprotein as well. HCCs are largely resistant to chemotherapy; however, extensive invasion of healthy liver tissue often precludes resection or transplantation and the probability of recurrence is high (Bail et al., 1990; Bhadri et al., 2005; Desai et al., 2019; Kaufman et al., 1987; Viatour et al., 2011). Screening and early intervention are therefore essential for a favorable prognosis.

It was initially hypothesized that HCC developed as a result of cholestasis associated with ALGS (Békássy et al., 1992; Chiaretti et al., 1992). However, there is no evidence that a seemingly milder ALGS phenotype correlates with a reduced risk for developing HCC. Our observation of HCC in two mildly-affected patients (i.e., without overt liver involvement) points to a possible disease association, with the argument that ALGS-causing germline variants could predispose affected individuals to HCC by interfering with Notch signaling (Bhadri et al., 2005; Tsai et al., 2010). Notch signaling is important in liver

disease, where it has been shown to signal hepatic progenitor cell differentiation in the setting of cirrhosis with increased necroinflammation and fibrosis (Huang et al., 2019; Morell et al., 2013). Extensive upregulation of this repair pathway can result in malignant transformation of hepatic progenitor cells into cancer stem cells (Huang et al., 2019; Morell et al., 2013). Additionally, *JAG1* is the predominant ligand stimulating Notch activation in injured livers (Fabris et al., 2007; Geisler & Strazzabosco, 2015; Morell et al., 2013). In *JAG1* pathogenic variant-positive ALGS, the absence of functional protein results in a buildup of hepatic progenitor cells with an intermediate hepatobiliary phenotype incapable of differentiating into biliary cells (Fabris et al., 2007). Inability to repair damage could facilitate the progression of preexisting liver disease and subsequent development of HCC.

Notch signaling dysfunction is already well-described in cancer, with perturbations in Notch signaling found in solid liver, pancreatic, breast, and ovarian tumors, as well as in melanoma and glioblastoma (Lu et al., 2016; Tate et al., 2019). However, whether Notch signaling plays an oncogenic or tumor-suppressing role depends on the tissue type, surrounding microenvironment, and cooperation with other

pathways (Che et al., 2016; Huang et al., 2019; Lu et al., 2016; Morell et al., 2013; Zhu et al., 2017). Some studies suggest that Notch acts as a tumor suppressor by inhibiting HCC proliferation (Huang et al., 2019; Lu et al., 2016; Qi et al., 2003; Viatour et al., 2011; Wang et al., 2009). On the other hand, in vitro studies using HCC cell lines suggest that Notch activation promotes HCC development based on the observation of an upregulation in progenitor cell differentiation, which has led some to propose Notch inhibition as a cancer therapy (Lu et al., 2016; Morell et al., 2013; Zhu et al., 2017). Conflicting findings warrant further examination of the downstream impacts of Notch dysfunction, as the mechanism of its involvement in HCC is likely complex.

Insertional mutagenesis studies support the specification of mouse analog *Jag1* as a cancer-causing gene, however, *JAG1* is not an established cancer gene in humans (Tate et al., 2019). Regardless, *JAG1* variants have been described in human tumor tissue and its potential involvement in cancer cannot be ruled out. Our query of somatic *JAG1* variants across cancer types indicates a low degree of tissue specificity; therefore, *JAG1* could be implicated in the development of multiple cancer types, including HCC. Of note, the same *JAG1* variant described in the proband (c.693_694del; p.Arg231Serfs*10) has been recorded in a sample of urinary tract carcinoma, supporting its possible role in carcinogenesis (Tate et al., 2019). Similarly, the missense *JAG1* variant c.551G > A (p.Arg184His) reported in Patient 17 (Table 3) has also been recorded in adenocarcinoma of the large intestine (Tate et al., 2019). Of the *JAG1* variants described in human cancer, missense variants occurred at the highest frequency (44.9%; Table S1). In contrast, the most common ALGS-causing pathogenic *JAG1* variants are protein-truncating, including frameshift, nonsense, exon deletions, and splice site mutations. Only 15% of the *JAG1* variants described in ALGS are missense variants (Gilbert et al., 2019). Interestingly, missense variants appear to be more common in cancer, but less common in ALGS. This observation could explain why HCC is a rare finding in ALGS.

No somatic *JAG1* or *NOTCH2* variants described in HCC have also been identified as germline in individuals with ALGS, and the majority of these *JAG1* variants (4/6) result in deep intronic or synonymous protein changes that are unlikely to be pathogenic for ALGS, which is caused by gene haploinsufficiency (Table 5). Nine of the recorded somatic *NOTCH2* variants in HCC were deep intronic, two resulted in synonymous protein changes, and 14 were rare missense variants (Table 6). Whether these somatic variants could be causative for ALGS is unclear, as only 19 *NOTCH2* variants have been described in ALGS to date and the mechanism of pathogenesis is unclear. Moreover, germline pathogenic variants identified in ALGS cause abnormalities to arise during development in all tissues, in contrast to later-arising somatic variants that are confined to specific tissues. The *JAG1* and *NOTCH2* variants reported in the COSMIC database are somatic changes identified in tumor tissue, which could explain a lack of systemic ALGS as well as why the types of *JAG1* and *NOTCH2* variants observed in cancer differ significantly from those seen in ALGS.

Although in this report we are specifically focused on HCC, we also reviewed the frequency of *JAG1* and *NOTCH2* variants in hepatocellular adenoma and biliary tract carcinoma recorded in the COSMIC

database. Pacheco et al. describe the first recorded *NOTCH2* variant in an individual with ALGS and hepatocellular adenoma (p.C286S), however, this appears to be a variant of uncertain significance for ALGS, thus the disease association is weak (Pacheco, Monroe, & Horslen, 2018). There are 26 and 36 biliary tract carcinoma samples with *JAG1* or *NOTCH2* variants, respectively, reported in COSMIC ($n = 3,069$ human tumor samples). The majority of these variants occur at a high population frequency, are deep intronic variants, or else have not been described in ALGS. Thus, there is little evidence to suggest an association between *JAG1* and *NOTCH2* variants identified in hepatocellular adenoma or biliary tract carcinoma and ALGS, and the occurrence of liver cancer in individuals with ALGS appears to be confined to HCC, as we and others have now reported.

Among ALGS patients who present with severe liver manifestations, close monitoring of liver enzymes, tumor-marker α -fetoprotein, and periodic ultrasound and CT scan or MRI is standard protocol (Bhadri et al., 2005; Kaufman et al., 1987; Kim et al., 2005; Schwarzenberg et al., 1992; Tsai et al., 2010). However, no screening protocol currently exists for patients with attenuated ALGS phenotypes (Tsai et al., 2010). In the proband described, lack of severe hepatic symptoms prior to developing HCC precluded periodic cancer screening that could have enabled detection early enough for resection or transplantation to be viable. Keeffe et al. (1993) describe a similar case of a 46-year-old man with mild ALGS and no hepatic symptoms who developed HCC (Patient 28, Table 4). Like our proband, he was asymptomatic and was not diagnosed with ALGS until after the diagnosis of his more severely affected child. HCC was identified upon his initial physical examination, and although he underwent a successful LT, he died of recurrent HCC 14 months later. Given that AFP levels in our proband remained within a normal range during the course of her illness, its reliability as a tumor marker is questionable, and indeed we report eight cases of HCC in ALGS in which AFP levels stayed within a normal range (D'Souza et al., 2018; Galvez et al., 2020; Pham et al., 2015; Schwarzenberg et al., 1992; Valampampil et al., 2020; Weiss et al., 2018). The development of HCC in two adults with mild ALGS and no liver involvement identifies an unmet need for increased surveillance of all individuals with an ALGS-associated *JAG1* or *NOTCH2* mutation, and also underscores the importance of genetic screening of family members to identify those who may be asymptomatic carriers of a pathogenic variant.

Conversely, it may also be prudent to consider the diagnosis of ALGS in patients presenting with HCC. The prevalence of HCC in the United States is roughly 7.7 cases per 100,000, with the prevalence of ALGS estimated at roughly one in 30,000 (Rich, Yopp, Singal, & Murphy, 2020; Saleh et al., 2016). It is well documented that ALGS is under-diagnosed in individuals with mild or sub-clinical symptoms and it is possible that some of these undiagnosed adults may be contributing to the prevalence of apparently isolated HCC, as we see in our proband and in Patient 28 (Saleh et al., 2016). Given the likelihood of other similar cases of HCC in adult asymptomatic ALGS that go unreported, it is possible that the incidence is significantly higher than has been predicted from case reports. Additionally, Wegmann et al. describe a patient with HCC who was not diagnosed with ALGS until

a postmortem evaluation of the medical history revealed characteristic clinical features (Wegmann et al., 1996). These cases suggest that ALGS should be considered in the differential diagnosis for individuals presenting with HCC, especially in those without a concomitant underlying risk factor or with a suspected or confirmed family history of ALGS, as this would change counseling.

To the best of our knowledge, only 35 cases of HCC in ALGS have been reported to date, including our proband. None of these cases address potential underlying risk factors for HCC, such as NAFLD, HBV or HCV infection, obesity, or alcoholism (Desai et al., 2019). Our research was limited by a lack of correlated genetic data, with 12 cases (36.3%) published prior to the discovery of *JAG1* as the disease-causing gene in 1997 (Li et al., 1997). Even in reports published after 1997, the majority of diagnoses were based solely on clinical manifestations without molecular genetic confirmation. Consequently, there is no genotype–phenotype correlation between type of mutation and HCC risk. Finally, none of the cases presented address possible somatic mosaicism. Mosaicism of ALGS-causing variants could be associated with a milder phenotype and may explain the observation of HCC in adults with milder ALGS phenotypes (Giannakudis et al., 2001). Future sequencing studies should focus on uncovering possible molecular etiologies of HCC among individuals with ALGS in order to help affected individuals understand their risk and guide the clinical management of ALGS. Additionally, care should be taken when screening family members of those with ALGS for HCC, with an emphasis on imaging as a diagnostic tool over AFP, to ensure that this at-risk population is appropriately screened.

ACKNOWLEDGMENTS

The authors would like to thank the patients and families who have helped further our understanding of Alagille syndrome through participating in research, especially Theresa Guidotti and her family, without whom this work would not be possible. Dr. Michael Acord helped with radiologic analysis of the patient's MRI. Drs. Spinner, Gilbert, Piccoli and Loomes receive support from the Fred and Suzanne Biesecker Pediatric Liver Center at the Children's Hospital of Philadelphia. This work was supported in part by R01-DK053104 (N.B.S.) as well as the Fred and Suzanne Biesecker Pediatric Liver Center at the Children's Hospital of Philadelphia.

CONFLICT OF INTEREST

The authors declare no conflict of interest.

AUTHOR CONTRIBUTIONS

David A. Piccoli, Ian D. Krantz, and Kathleen M. Loomes reviewed the patient's medical records. Emma A. Schindler, Ian D. Krantz, and Melissa A. Gilbert conducted the literature review. Emma A. Schindler and Ian D. Krantz drafted the initial manuscript and Emma A. Schindler, Kathleen M. Loomes, and Melissa A. Gilbert edited the draft based on recommendations from co-authors and reviewers. Nancy B. Spinner performed genomic analysis for the proband and affected family members. All authors read and approved the final version of the manuscript.

DATA AVAILABILITY STATEMENT

Data sharing is not applicable to this article as no new data were created or analyzed in this study.

ORCID

Emma A. Schindler  <https://orcid.org/0000-0002-3610-7868>

Melissa A. Gilbert  <https://orcid.org/0000-0001-5345-1911>

REFERENCES

- Adams, P. C. (1986). Hepatocellular carcinoma associated with arteriohepatic dysplasia. *Digestive Diseases and Sciences*, 31(4), 438–442. <http://dx.doi.org/10.1007/bf01311683>.
- Alagille, D., Habib, E., & Thomassin, N. (1969). L'atresie des voies biliaires intrahepatiques avec voies biliaires extrahepatiques permeables chez l'enfant. *Journal Paris Pédiatriques*, 301, 301–318.
- Alagille, D., Odievre, M., Gautier, M., & Dommergues, J. P. (1975). Hepatic ductular hypoplasia associated with characteristic facies, vertebral malformations, retarded physical, mental, and sexual development, and cardiac murmur. *The Journal of Pediatrics*, 86(1), 63–71. [https://doi.org/10.1016/s0022-3476\(75\)80706-2](https://doi.org/10.1016/s0022-3476(75)80706-2)
- Alagille, D., Estrada, A., Hadchouel, M., Gautier, M., Odievre, M., & Dommergues, J. P. (1987). Syndromic paucity of interlobular bile ducts (Alagille syndrome or arteriohepatic dysplasia): Review of 80 cases. *The Journal of Pediatrics*, 110(2), 195–200. [https://doi.org/10.1016/s0022-3476\(87\)80153-1](https://doi.org/10.1016/s0022-3476(87)80153-1)
- Alhammad, A., Kamath, B. M., Chami, R., Ng, V. L., & Chavhan, G. B. (2016). Solitary hepatic nodule adjacent to the right portal vein: A common finding of Alagille syndrome? *Journal of Pediatric Gastroenterology and Nutrition*, 62(2), 226–232. <https://doi.org/10.1097/MPG.0000000000000945>
- Bail, B. L., le Bail, B., Bioulac-Sage, P., Bioulac-Sage, P., Arnoux, R., Arnoux, R., ... Balabaud, C. (1990). Late recurrence of a hepatocellular carcinoma in a patient with incomplete alagille syndrome. *Gastroenterology*, 99(5), 1514–1516. [https://doi.org/10.1016/0016-5085\(90\)91185-9](https://doi.org/10.1016/0016-5085(90)91185-9)
- Békássy, A. N., Garwicz, S., Wiebe, T., Hägerstrand, I., & Jensen, O. A. (1992). Hepatocellular carcinoma associated with arteriohepatic dysplasia in a 4-year-old girl. *Medical and Pediatric Oncology*, 20(1), 78–83. <https://doi.org/10.1002/mpo.2950200118>
- Bhadri, V. A., Stormon, M. O., Arbuckle, S., Lam, A. H., Gaskin, K. J., & Shun, A. (2005). Hepatocellular carcinoma in children with Alagille syndrome. *Journal of Pediatric Gastroenterology and Nutrition*, 41(5), 676–678. <https://doi.org/10.1097/01.mpg.0000179759.60048.c4>
- Castañeda, C., Fragoso, T., Gra, B., Guerra, L., Castellanos, O., & Trujillo, M. E. (1992). Alagille's syndrome in Cuba. A report of 9 cases. *G.E.N.*, 46(4), 341–346.
- Che, L., Fan, B., Pilo, M. G., Xu, Z., Liu, Y., Cigliano, A., ... Chen, X. (2016). Jagged 1 is a major notch ligand along cholangiocarcinoma development in mice and humans. *Oncogene*, 35(12), 8. <https://doi.org/10.1038/oncsis.2016.73>
- Chiaretti, A., Zampino, G., Botto, L., & Polidori, G. (1992). Alagille syndrome and hepatocarcinoma: A case report. *Acta Paediatrica*, 81(11), 937–937. <https://doi.org/10.1111/j.1651-2227.1992.tb12141.x>
- Crosnier, C., Driancourt, C., Raynaud, N., Dhorne-Pollet, S., Pollet, N., Bernard, O., ... Meunier-Rotival, M. (1999). Mutations in *JAGGED1* gene are predominantly sporadic in Alagille syndrome. *Gastroenterology*, 116(5), 1141–1148. [https://doi.org/10.1016/s0016-5085\(99\)70017-x](https://doi.org/10.1016/s0016-5085(99)70017-x)
- Desai, A., Sandhu, S., Lai, J. P., & Sandhu, D. S. (2019). Hepatocellular carcinoma in non-cirrhotic liver: A comprehensive review. *World Journal of Hepatology*, 11(1), 1–18. <https://doi.org/10.4254/wjh.v11.i1.1>
- D'Souza, A. M., Shah, R., Gupta, A., Towbin, A. J., Alonso, M., Nathan, J. D., ... Geller, J. I. (2018). Surgical management of children

- and adolescents with upfront completely resected hepatocellular carcinoma. *Pediatric Blood & Cancer*, 65(11), e27293. <https://doi.org/10.1002/abc.27293>
- D'Souza, A. M., Towbin, A. J., Gupta, A., Alonso, M., Nathan, J. D., Bondoc, A., & Geller, J. I. (2020). Clinical heterogeneity of pediatric hepatocellular carcinoma. *Pediatric Blood & Cancer*, 67(6), e28307. <http://dx.doi.org/10.1002/abc.28307>.
- duCret, R. P., Cefalu, J. B., Alford, B. A., Drake, G., & Boudreau, R. J. (1988). Hepatocarcinoma in Association with the Alagille Syndrome. *Clinical Nuclear Medicine*, 13(12), 920–921. <http://dx.doi.org/10.1097/00003072-198812000-00019>.
- Emerick, K. M., Rand, E. B., Goldmuntz, E., Krantz, I. D., Spinner, N. B., & Piccoli, D. A. (1999). Features of alagille syndrome in 92 patients: Frequency and relation to prognosis. *Hepatology*, 29(3), 822–829. <https://doi.org/10.1002/hep.510290331>
- Emerick, K. M., Krantz, I. D., Kamath, B. M., Darling, C., Burrows, D. M., Spinner, N. B., ... Piccoli, D. A. (2005). Intracranial vascular abnormalities in patients with Alagille syndrome. *Journal of Pediatric Gastroenterology and Nutrition*, 41(1), 99–107. <https://doi.org/10.1097/01.mpg.0000162776.67758.2f>
- Ennaifer, R., Ben Farhat, L., Cheikh, M., Romdhane, H., Marzouk, I., & Belhadji, N. (2016). Focal liver hyperplasia in a patient with Alagille syndrome: Diagnostic difficulties. A case report. *International Journal of Surgery Case Reports*, 25, 55–61. <https://doi.org/10.1016/j.ijscr.2016.03.032>
- Fabris, L., Cadamuro, M., Guido, M., Spirli, C., Fiorotto, R., Colledan, M., ... Strazzabosco, M. (2007). Analysis of liver repair mechanisms in Alagille syndrome and biliary atresia reveals a role for notch signaling. *The American Journal of Pathology*, 171(2), 641–653. <https://doi.org/10.2353/ajpath.2007.070073>
- Galvez, D., Ruch, B., Sharma, A., Sydnor, M., Levy, M., & Sharma, A. (2020). Recurrent hepatocellular carcinoma in an adult with Alagille syndrome treated with liver resection followed by liver transplantation: A rare case report. *Transplantation Direct*, 6(10), e606. <https://doi.org/10.1097/TXD.000000000000000>.
- Geisler, F., & Strazzabosco, M. (2015). Emerging roles of notch signaling in liver disease. *Hepatology*, 61(1), 382–392. <https://doi.org/10.1002/hep.27268>
- Geramizadeh, B., Kashkoe, A., Bahador, A., Dehghani, S. M., Shamsaefar, A., Kazemi, K., & Malekhosseini, S. A. (2017). Pediatric Hepatocellular Carcinoma, a Single Center Study from the South of Iran: Case Series. *Hepatitis Monthly*, 17(8), e11837. <http://dx.doi.org/10.5812/hepatmon.11837>.
- Giannakudis, J., Ropke, A., Kujat, A., Krajewska-Walasek, M., Hughes, H., Fryns, J. P., ... Hansmann, I. (2001). Parental mosaicism of JAG1 mutations in families with Alagille syndrome. *European Journal of Human Genetics*, 9(3), 209–216. <https://doi.org/10.1038/sj.ejhg.5200613>
- Gilbert, M. A., Bauer, R. C., Rajagopalan, R., Grochowski, C. M., Chao, G., McEldrew, D., ... Spinner, N. B. (2019). Alagille syndrome mutation update: Comprehensive overview of JAG1 and NOTCH2 mutation frequencies and insight into missense variant classification. *Human Mutation*, 40(12), 2197–2220. <https://doi.org/10.1002/humu.23879>
- Huang, Q., Li, J., Zheng, J., & Wei, A. (2019). The carcinogenic role of the notch signaling pathway in the development of hepatocellular carcinoma. *Journal of Cancer*, 10(6), 1570–1579. <https://doi.org/10.7150/jca.26847>
- Kamath, B. M., Bauer, R. C., Loomes, K. M., Chao, G., Gerfen, J., Hutchinson, A., ... Spinner, N. B. (2012). NOTCH2 mutations in Alagille syndrome. *Journal of Medical Genetics*, 49(2), 138–144. <https://doi.org/10.1136/jmedgenet-2011-100544>
- Karczewski, K. J., Francioli, L. C., Tiao, G., Cummings, B. B., Alfoldi, J., ... MacArthur, D. G. (2020). The mutational constraint spectrum quantified from variation in 141,456 humans. *Nature*, 581(7809), 434–443. <http://dx.doi.org/10.1038/s41586-020-2308-7>
- Kaufman, S. S., Wood, R. P., Shaw, B. W., Jr., Markin, R. S., Gridelli, B., & Vanderhoof, J. A. (1987). Hepatocarcinoma in a child with the Alagille syndrome. *American Journal of Diseases of Children*, 141(6), 698–700. <https://doi.org/10.1001/archpedi.1987.04460060114050>
- Keeffe, E. B., Pinson, C. W., Ragsdale, J., & Zonana, J. (1993). Hepatocellular carcinoma in arteriohepatic dysplasia. *The American Journal of Gastroenterology*, 88(9), 1446–1449. <https://doi.org/10.1111/j.1572-0241.1993.tb07624.x>
- Kim, B., Park, S. H., Yang, H. R., Seo, J. K., Kim, W. S., & Chi, J. G. (2005). Hepatocellular carcinoma occurring in alagille syndrome. *Pathology, Research and Practice*, 201(1), 55–60. <https://doi.org/10.1016/j.prp.2004.11.007>
- Li, L., Krantz, I. D., Deng, Y., Genin, A., Banta, A. B., Collins, C. C., ... Spinner, N. B. (1997). Alagille syndrome is caused by mutations in human Jagged1, which encodes a ligand for Notch1. *Nature Genetics*, 16(3), 243–251. <https://doi.org/10.1038/ng0797-243>
- Lu, J., Xia, Y., Chen, K., Zheng, Y., Wang, J., Lu, W., ... Guo, C. (2016). Oncogenic role of the notch pathway in primary liver cancer (review). *Oncology Letters*, 12, 4278. Retrieved from https://link.gale.com/apps/doc/A473383746/AONE?u=upenn_main&sid=AONE&xid=5a1c219c
- McDaniell, R., Warthen, D. M., Sanchez-Lara, P. A., Pai, A., Krantz, I. D., Piccoli, D. A., & Spinner, N. B. (2006). NOTCH2 mutations cause Alagille syndrome, a heterogeneous disorder of the NOTCH signaling pathway. *American Journal of Human Genetics*, 79(1), 169–173. <https://doi.org/10.1086/505332>
- Mitchell, E., Gilbert, M., & Loomes, K. M. (2018). Alagille Syndrome. *Clinics in Liver Disease*, 22(4), 625–641. <https://doi.org/10.1016/j.cld.2018.06.001>
- Morell, C. M., Fiorotto, R., Fabris, L., & Strazzabosco, M. (2013). Notch signalling beyond liver development: Emerging concepts in liver repair and oncogenesis. *Clinics and Research in Hepatology and Gastroenterology*, 37(5), 447–454. <https://doi.org/10.1016/j.clinre.2013.05.008>
- Oda, T., Elkahoul, A. G., Pike, B. L., Okajima, K., Krantz, I. D., Genin, A., ... Chandrasekharappa, S. C. (1997). Mutations in the human Jagged1 gene are responsible for Alagille syndrome. *Nature Genetics*, 16(3), 235–242. <https://doi.org/10.1038/ng0797-235>
- Ong, E., Williams, S. M., Anderson, J. C., & Kaplan, P. A. (1986). MR imaging of a hepatoma associated with Alagille syndrome. *Journal of Computer Assisted Tomography*, 10(6), 1047–1049. <https://doi.org/10.1097/00004728-198611000-00032>
- Pacheco, M. C., Monroe, E. J., & Horslen, S. P. (2018). Hepatic adenoma arising in a patient with Alagille syndrome: A case report. *Pediatric and Developmental Pathology*, 21(6), 585–589. <https://doi.org/10.1177/1093526618762550>
- Pérez Becerra, E., Fuster, M., Fraga, M., Antúnez, J., Pintos, E., Pavón, P., & Forteza, J. (1991). Alagille's syndrome: A family case and its association with hepatocellular carcinoma. *Revista Clínica Española*, 188(9), 459–462.
- Pham, T. A., Gallo, A. M., Concepcion, W., Esquivel, C. O., & Bonham, C. A. (2015). Effect of liver transplant on long-term disease-free survival in children with hepatoblastoma and hepatocellular cancer. *JAMA Surgery*, 150(12), 1150–1158. <https://doi.org/10.1001/jamasurg.2015.1847>
- Qi, R., An, H., Yu, Y., Zhang, M., Liu, S., Xu, H., ... Cao, X. (2003). Notch1 signaling inhibits growth of human hepatocellular carcinoma through induction of cell cycle arrest and apoptosis. *Cancer Research*, 63(23), 8323–8329. Retrieved from <https://cancerres.aacrjournals.org/content/canres/63/23/8323.full.pdf>
- Rabinovitz, M., Imperial, J. C., Schade, R. R., & van Thiel, D. H. (1989). Hepatocellular carcinoma in Alagille's syndrome: A family study. *Journal of Pediatric Gastroenterology and Nutrition*, 8(1), 26–30. <https://doi.org/10.1097/00005176-198901000-00006>
- Rapp, J. B., Bellah, R. D., Maya, C., Pawel, B. R., & Anupindi, S. A. (2017). Giant hepatic regenerative nodules in Alagille syndrome. *Pediatric Radiology*, 47(2), 197–204. <https://doi.org/10.1007/s00247-016-3728-2>

- Rich, N. E., Yopp, A. C., Singal, A. G., & Murphy, C. C. (2020). Hepatocellular carcinoma incidence is decreasing among younger adults in the United States. *Clinical Gastroenterology and Hepatology*, 18(1), 242–248.e245. <https://doi.org/10.1016/j.cgh.2019.04.043>
- Saleh, M., Kamath, B. M., & Chitayat, D. (2016). Alagille syndrome: Clinical perspectives. *The Application of Clinical Genetics*, 9, 75–82. <https://doi.org/10.2147/TACG.S86420>
- Schoen, K., de Freitas Ribeiro, C. M., Gonçalves, M. C., de Souza, A. R. M., Porta, G., & Horvat, N. (2021). Hepatocellular carcinoma in an adult with Alagille syndrome: Case report and literature review. *Radiology Case Reports*, 16(1), 90–93. <https://doi.org/10.1016/j.radcr.2020.09.027>
- Schwarzenberg, S. J., Grothe, R. M., Sharp, H. L., Snover, D. C., & Freese, D. (1992). Long-term complications of arteriohepatic dysplasia. *The American Journal of Medicine*, 93(2), 171–176. [https://doi.org/10.1016/0002-9343\(92\)90047-f](https://doi.org/10.1016/0002-9343(92)90047-f)
- Spinner, N. B., Colliton, R. P., Crosnier, C., Krantz, I. D., Hadchouel, M., & Meunier-Rotival, M. (2001). Jagged1 mutations in Alagille syndrome. *Human Mutation*, 17(1), 18–33. [https://doi.org/10.1002/1098-1004\(2001\)17:1<18::Aid-humu3>3.0.Co;2-t](https://doi.org/10.1002/1098-1004(2001)17:1<18::Aid-humu3>3.0.Co;2-t)
- Syed, M. A., Khalili, K., & Guindi, M. (2008). Regenerating nodules in arteriohepatic syndrome: A case report. *The British Journal of Radiology*, 81(963), e79–e83. <https://doi.org/10.1259/bjr/63424939>
- Tate, J. G., Bamford, S., Jubb, H. C., Sondka, Z., Beare, D. M., Bindal, N., ... Forbes, S. A. (2019). COSMIC: The catalogue of somatic mutations in cancer. *Nucleic Acids Research*, 47(D1), D941–D947. <https://doi.org/10.1093/nar/gky1015>
- Tsai, S., Gurakar, A., Anders, R., Lam-Himlin, D., Boitnott, J., & Pawlik, T. M. (2010). Management of large hepatocellular carcinoma in adult patients with Alagille syndrome: A case report and review of literature. *Digestive Diseases and Sciences*, 55(11), 3052–3058. <https://doi.org/10.1007/s10620-009-1123-7>
- Valampampil, J. J., Shanmugam, N., Vij, M., Reddy, M. S., & Rela, M. (2020). Hepatocellular carcinoma in paediatric patients with Alagille syndrome: Case series and review of literature. *Journal of Gastrointestinal Cancer*, 51, 1047–1052. <https://doi.org/10.1007/s12029-020-00391-2>
- Valampampil, J. J., Reddy, M. S., Shanmugam, N., Vij, M., Kanagavelu, R. G., & Rela, M. (2019). Living donor liver transplantation in Alagille syndrome—Single center experience from south Asia. *Pediatric Transplantation*, 23(8), e13579. <http://dx.doi.org/10.1111/ptr.13579>
- Viatour, P., Ehmer, U., Saddic, L. A., Dorrell, C., Andersen, J. B., Lin, C., ... Sage, J. (2011). Notch signaling inhibits hepatocellular carcinoma following inactivation of the RB pathway. *The Journal of Experimental Medicine*, 208(10), 1963–1976. <https://doi.org/10.1084/jem.20110198>
- Vinayak, R., Cruz, R. J., Jr., Ranganathan, S., Mohanka, R., Mazariegos, G., Soltys, K., ... Sindhi, R. (2017). Pediatric liver transplantation for hepatocellular cancer and rare liver malignancies: US multicenter and single-center experience (1981-2015). *Liver Transplantation*, 23(12), 1577–1588. <https://doi.org/10.1002/lt.24847>
- Wang, C., Qi, R., Li, N., Wang, Z., An, H., Zhang, Q., ... Cao, X. (2009). Notch1 signaling sensitizes tumor necrosis factor-related apoptosis-inducing ligand-induced apoptosis in human hepatocellular carcinoma cells by inhibiting Akt/Hdm2-mediated p53 degradation and up-regulating p53-dependent DR5 expression. *The Journal of Biological Chemistry*, 284(24), 16183–16190. <https://doi.org/10.1074/jbc.M109.002105>
- Wegmann, W., Evison, J., Schaub, N., Kist, L., & Vest, M. (1996). Liver cell carcinoma as a late complication of Alagille syndrome (arterio-hepatic dysplasia). *Leber Magen Darm*, 26(3), 157.
- Weiss, K. E., Sze, D. Y., Rangaswami, A. A., Esquivel, C. O., Concepcion, W., Lebowitz, E. A., ... Lungren, M. P. (2018). Transarterial chemoembolization in children to treat unresectable hepatocellular carcinoma. *Pediatric Transplantation*, 22(4), e13187. <https://doi.org/10.1111/ptr.13187>
- Wetli, S. C., Gralla, E. S., Schibli, S., & Stranzinger, E. (2010). Hepatocellular carcinoma and regenerating nodule in a 3-year-old child with Alagille syndrome. *Pediatric Radiology*, 40(10), 1696–1698. <https://doi.org/10.1007/s00247-010-1784-6>
- Zhu, B., Sun, L., Luo, W., Li, M., Coy, D. H., Yu, L., & Yu, W. (2017). Activated notch signaling augments cell growth in hepatocellular carcinoma via up-regulating the nuclear receptor NR4A2. *Oncotarget*, 8(14), 23289–23302. <https://doi.org/10.18632/oncotarget.15576>

SUPPORTING INFORMATION

Additional supporting information may be found online in the Supporting Information section at the end of this article.

How to cite this article: Schindler EA, Gilbert MA, Piccoli DA, Spinner NB, Krantz ID, Loomes KM. Alagille syndrome and risk for hepatocellular carcinoma: Need for increased surveillance in adults with mild liver phenotypes. *Am J Med Genet Part A*. 2021;185A:719–731. <https://doi.org/10.1002/ajmg.a.62028>