

Trauma and reconstruction

## Horseshoe kidney splitting technique for transplantation

Pedro De Pablos-Rodríguez<sup>\*</sup>, José Francisco Suárez, Lluís Riera Canals, Pol Sanz-Serra, Francisco Vigués

Hospital Universitari de Bellvitge, Carrer de la Feixa Llarga, 08907, L'Hospitalet de Llobregat, Barcelona, Spain



## ARTICLE INFO

## Keywords:

Transplant  
Horseshoe kidney  
Congenital kidney abnormality

## ABSTRACT

Shortage of donors has led to an expansion of the criteria for acceptability of deceased-donor organs including the use of kidneys with anatomical variations such as horseshoe kidneys (HSKs). Transplantation can be accomplished either en bloc or after division of the HSK. Little is known about the most appropriate technique to split the kidney and minimize risk of bleeding or urinary fistula. In this report we present two renal transplants after division of a HSK with a different splitting technique.

## Introduction

The shortage of donors has led to an expansion of the criteria for the acceptability of deceased-donor organs, including the use of horseshoe kidneys (HSK). The HSK is one of the most common anatomical variations of the kidney resulting from anomalous fusion at the lower poles (95% cases). Vascular and urinary tract abnormalities that usually accompany these kidneys have always been a concern for primary non-function based on technical failure. According to Eurotransplant data, more than one-third of HSKs from deceased donors were discarded because of their complex vascular anatomy and urinary collecting system injury.<sup>1</sup>

Once deciding to transplant a HSK, there are two approaches: transplantation after splitting the HSK or transplantation en bloc. The kidney's division maximizes the potential value; however, depending on the vessels' anatomy and the collecting system, it may not be possible. Several techniques for splitting the HSK have been described.<sup>2-4</sup>

This study reports two renal transplants cases using a HSK from a deceased donor and our fusion division method.

## Case presentation

A 49-year-old man that suffered a prolonged cardiac arrest from an acute myocardial infarction was elected for Maastricht-III non-heart-beating donation. Although the ultrasound revealed a normal kidney appearance, a HSK was identified intraoperatively. The kidney was harvested en bloc with a segment of the aorta and vena cava (Fig. 1). The

hilum of both kidneys had two main arteries and an inferior polar artery. The right kidney had three veins, while the left kidney had a single one. Both collecting systems crossed the isthmus anteriorly. An isthmic artery came from the right common iliac artery, which was accidentally sectioned and ligated during extraction.

To get the most of the kidney, we decided to split it in two. Following division, the vessels exposed were selectively sutured with a 3.0 Prolene® (Fig. 2). The cut ends were approached with simple stitches of 3.0 V-lock® and, to tighten the suture without tearing renal parenchyma, hem-o-locks® were placed pressing from each side (Fig. 3).

The first recipient was a 51-year-old man with hypertension, type 2 diabetes, dyslipidemia, and obesity. He had been in hemodialysis for a year due to diabetic nephropathy. Left kidney transplantation was performed in his left iliac fossa to keep the collecting system anteriorly. The renal vein was anastomosed to the external iliac vein. Both main arteries were anastomosed in the same patch, and the polar inferior artery was anastomosed in-dependently. All three were anastomosed to the external iliac artery. Lich-Gregoir technique was used to implant the ureter. The perfusion of the graft was successful. No bleeding was detected from the transected surface. Cold ischemic time was 11 hours, and the time of anastomosis was 46 minutes. The recipient developed delayed graft function (DGF), and the laboratory test showed acute tubular necrosis with good arterial perfusion demonstrated in doppler ultrasonography. He was discharged on day nine after surgery after satisfactory evolution. Creatinine levels after one month are 1.4mg/dL.

The second recipient was a 58-year-old-man with a history of hypertension, dyslipidemia, and ESRD due to membranous

<sup>\*</sup> Corresponding author.

E-mail addresses: [pdepablos@bellvitgehospital.cat](mailto:pdepablos@bellvitgehospital.cat) (P. De Pablos-Rodríguez), [jfsuarez@bellvitgehospital.cat](mailto:jfsuarez@bellvitgehospital.cat) (J.F. Suárez), [lriera@bellvitgehospital.cat](mailto:lriera@bellvitgehospital.cat) (L. Riera Canals), [psanzs@bellvitgehospital.cat](mailto:psanzs@bellvitgehospital.cat) (P. Sanz-Serra), [fvigues@bellvitgehospital.cat](mailto:fvigues@bellvitgehospital.cat) (F. Vigués).

<https://doi.org/10.1016/j.eucr.2021.101604>

Received 18 January 2021; Received in revised form 3 February 2021; Accepted 9 February 2021

Available online 12 February 2021

2214-4420/© 2021 The Authors.

Published by Elsevier Inc.

This is an open access article under the CC BY-NC-ND license

(<http://creativecommons.org/licenses/by-nc-nd/4.0/>).

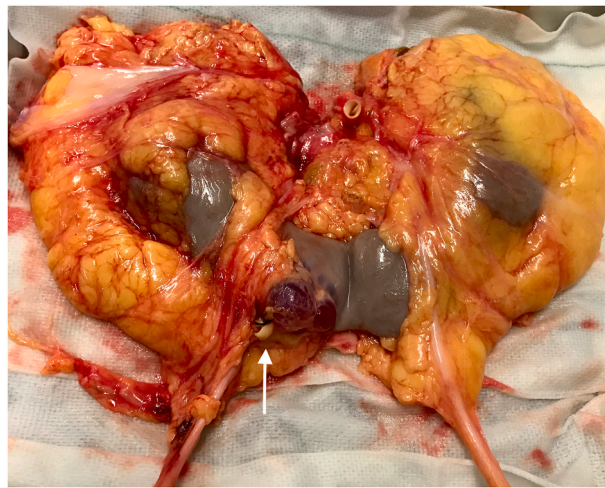

Fig. 1. Horseshoe kidney harvested en bloc. Artery accidentally injured during extraction (arrow).

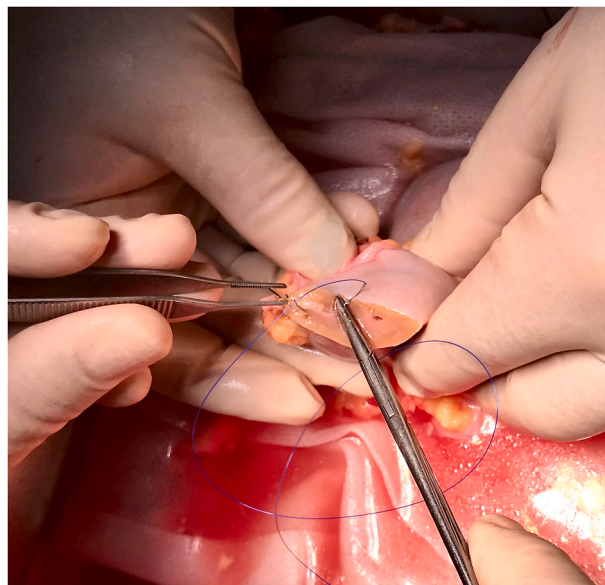


Fig. 2. Selective simple stitches to visible arteries.

glomerulonephritis. He had been in peritoneal dialysis for four years. The right kidney was transplanted to his right iliac fossa. Vena cava was used to enlarge the three renal veins and make a single anastomosis to the external iliac vein. The two main renal arteries, in a single patch, and the inferior polar artery were anastomosed to the external iliac artery. The same ureterovesical anastomosis technique was performed. Adequate graft perfusion was established, and there was no significant bleeding. Cold ischemia time was 15 hours, and the time of anastomosis was 45 minutes. Postoperative evolution was similar to the preceding case. He also developed DGF with doppler revealing adequate parenchyma perfusion. He was discharged on day eight after surgery. After one month, his creatinine is maintained in 1.3mg/dL.

**Discussion and conclusion**

The literature reveals an increasing number of reports of successfully transplanted HSKs, but little information is available on such kidneys' preparation. There are two possible surgical techniques in HSK transplantation, either en bloc or after splitting the kidney. Previous studies showed that the transplantation of a HSK, either en bloc or separated,

produced the same results compared with the transplantation of a regular kidney.<sup>1</sup>

Split technique transplantation is important due to the scarcity of the organs required for transplantation. However, depending on factors like the number or position of the vessels or the urinary system's anatomical characteristics, there might be a high risk of technical failure.

Most concerning complications after splitting a HSK include bleeding and urinary fistula from the cut edges. We can assume that the thicker the isthmus is, the greater risk we take. There is not any review that compares percentages of complications between transplant of regular kidneys or HSK. Nevertheless, we believe that, nowadays, there are enough alternatives to achieve well-sealed edges.

Running sutures in one or more layers is the most common technique proposed in the literature<sup>2</sup>; however, excessive tightening could tear the renal parenchyma apart. Other devices, such as a stapler<sup>3</sup> or a harmonic scalpel,<sup>4</sup> have also been used for this purpose.

In both recipients, we selectively sutured vessels exposed after isthmus incision and performed simple stitches with hem-o-locks® on each side to bring the edges together. Applying this technique, we could achieve good tension of the suture minimizing the risk of lacerating the

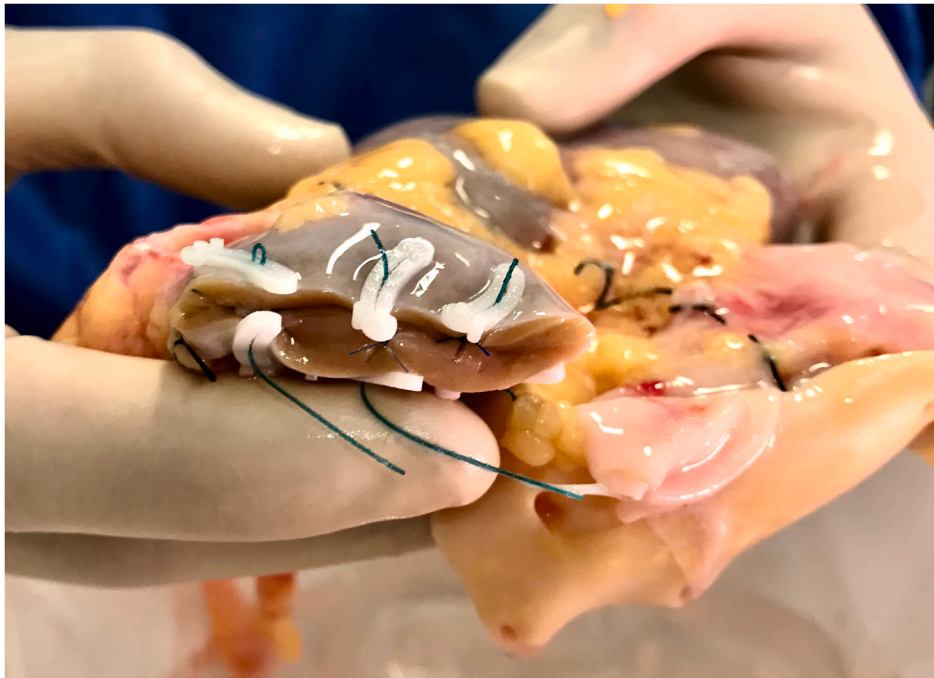

Fig. 3. Isthmus final appearance after hem-o-lock placement.

parenchyma. It is equivalent to the renorrhaphy performed after partial nephrectomies, where it is not uncommon to see large parenchymal defects that frequently include urinary collecting system.

Once transplantation of a HSK has been decided and the feasibility to divide it has been assessed, it is imperative to obtain properly sealed edges. We believe that this technique represents a cheap, safe, and effective horseshoe kidney division method.

#### References

1. Stroosma OB, Smits JM, Schurink GW, et al. Horseshoe kidney transplantation within the Eurotransplant region: a case control study. *Transplantation*. 2001;72:1930–1933. <https://doi.org/10.1097/00007890-200112270-00011>.
2. Vasconcelos Ordoñez F, Yamamoto H, Ivo Pajolli P, et al. Transplanting a horseshoe kidney: a case report and review of surgical strategies. *Urol Case Rep*. 2018 Sep 22;21: 119–121. <https://doi.org/10.1016/j.eucr.2018.09.011>.
3. Sozener Ulas. Transplantation of a horseshoe kidney from a living donor using stapler for transection. *J Surg Case Rep*. 2019;Issue 11:rjz299. <https://doi.org/10.1093/jscr/rjz299>. November 2019.
4. Justo-Janeiro JM, Orozco EP, Reyes FJ, et al. Transplantation of a horseshoe kidney from a living donor: case report, long term outcome and donor safety. *Int J Surg Case Rep*. 2015;15:21–25. <https://doi.org/10.1016/j.ijscr.2015.08.008>.