



Open Access

ORIGINAL ARTICLE

Operational Andrology

Diagnosis, treatment, outcome, and reasons for delayed treatment of cryptorchidism with torsion in children: a 16-year retrospective study in a large pediatric medical center

Meng Yang^{1,2,3,*}, Sheng Wen^{1,2,3,*}, Tao Lin^{1,2,3}, Xing Liu^{1,2,3}, De-Ying Zhang^{1,2,3}, Feng Liu^{1,2,3}, Sheng-De Wu^{1,2,3}, Guang-Hui Wei^{1,2,3}, Pei-Ru He¹, Yi Hua^{1,2,3}

We describe and summarize the diagnosis, treatment, and reasons for delayed treatment of children with cryptorchidism torsion in Children's Hospital of Chongqing Medical University. The study included 19 cases of cryptorchidism torsion. The age of the children ranged from 16 days to 12 years (median: 6 years). The interval from diagnosis to surgery varied from 4 h to 16 days (median: 3 days). Ultrasound was performed in all cases. Fifteen cases had cryptorchidism torsion, 2 cases had a soft tissue mass in the inguinal region, and 2 cases had an inguinal/abdominal teratoma. Five cases were treated with an orchidopexy, 12 cases were treated with orchiectomy, and 2 cases received resection of a testicular tumor. The 5 children with an orchidopexy were followed up from 1 month to 7 years (median: 3 years), with 1 child having a testis retraction and no blood supply. Of the 12 children who had an orchiectomy, three had delayed diagnosis due to family unawareness of the condition, while other delays were due to delayed referral from primary care facilities. The relative rarity and insufficient awareness of cryptorchidism torsion resulted in a low rate of testicular salvage. Therefore, hospitals of all levels should be fully aware of cryptorchidism with torsion and ensure a male child's genital system and inguinal region are examined to improve the success rate of testicular salvage.

Asian Journal of Andrology (2022) 24, 386–389; doi: 10.4103/aja202184; published online: 17 December 2021

Keywords: children; cryptorchidism; testicular torsion

INTRODUCTION

Cryptorchidism is by far the most common congenital genitourinary disease.¹ Complications of cryptorchidism include inguinal hernia, testicular trauma, low fertility, testicular cancer, and testicular torsion.^{2,3} The majority of previous studies have focused on low fertility and malignancy, although it should be recognized that cryptorchidism with testicular torsion is also a very important complication. Prompt diagnosis and treatment are essential for preserving the testis. This study referred to previous studies and describes cases in our tertiary care center who had a history of cryptorchidism with testicular torsion. The aims of the study were to summarize the characteristics of cryptorchidism with testicular torsion and to improve the diagnosis rate and treatment outcome of the disease, including the success rate of testicular salvage. Because the Children's Hospital of Chongqing Medical University (Chongqing, China) is the largest tertiary pediatric medical center in Southwest China, we were able to collect a large number of cases in the study.

PATIENTS AND METHODS

This study was approved by the Medical Research Ethics Committee of the Children's Hospital of Chongqing Medical University (No. 2020261). All the family members of the children signed the informed consent at the same time as the surgical consent. Data of cases with cryptorchidism and testicular torsion were collected at the Children's Hospital of Chongqing Medical University between May 2005 and March 2021. Inclusion criteria were: (1) surgically confirmed cryptorchidism with testicular torsion; and (2) children with at least one follow-up visit. All children underwent preoperative ultrasound. The parameters analyzed included age, clinical presentation, duration of symptoms, imaging, surgical data, pathology, concomitant diseases, outcomes, and the reasons for a delay in diagnosis and treatment. All the children with suspected cryptorchidism and testicular torsion attending our center underwent surgical exploration. At least three experienced surgeons made the diagnosis of necrotic testicles before orchiectomy. Ultrasound imaging was used for the postoperative follow-up to determine the blood supply and position of the testis.

¹Department of Urology, Children's Hospital of Chongqing Medical University, Chongqing 400000, China; ²Pediatrics Research Institute, Children's Hospital of Chongqing Medical University; Ministry of Education Key Laboratory of Child Development and Disorders; National Clinical Research Center for Child Health and Disorders; China International Science and Technology Cooperation Base of Child Development and Critical Disorders; Children's Hospital of Chongqing Medical University, Chongqing 400000, China; ³Chongqing Key Laboratory of Pediatrics, Chongqing Key Laboratory of Children Urogenital Development and Tissue Engineering, Chongqing 400000, China.

*These authors contributed equally to this work.

Correspondence: Dr. Y Hua (huayi730@sina.cn)

Received: 24 April 2021; Accepted: 13 October 2021

Statistical analyses

All statistics were analyzed by SPSS 23.0 (SPSS Inc., Chicago, IL, USA). For non-normally distributed continuous variables the median (range) is used. Categorical variables are denoted by *n* (%).

RESULTS

A total of 19 children with cryptorchidism and testicular torsion were included in the study. The age ranged from 16 days to 12 years (median: 6 years). The most common presentations were pain and/or a mass in the inguinal region. The duration of symptoms ranged from 4 h to 16 days (median: 3 days). Ultrasound was performed before surgery and indicated that 15 cases had cryptorchidism with torsion, equivalent to a 78.9% ultrasound diagnosis rate. Of the 19 cases, 5 cases had an orchidopexy, 12 cases had an orchiectomy, 1 case had a resection of testicular teratoma, and 1 case had a resection of dermatomal cyst, resulting in a 26.3% testicular salvage success rate. All the children underwent contralateral testicular fixation/descending fixation. Four cases had bilateral cryptorchidism and unilateral cryptorchidism with torsion, 1 case had hypospadias, and 2 cases had a testicular teratoma. The pathology in all the cases was hemorrhagic necrosis of the testis, and in the two cases of combined teratoma, the pathology showed a mature testicular teratoma. Follow-up of the 12 cases who had orchiectomy varied from 3 months to 15 years (median: 4 years) confirmed they all had a good blood supply to the contralateral testis that was in the normal position (**Table 1**).

Of the 5 children who had an orchidopexy, the duration of symptoms was 4 h, 1 day, 2 days, 3 days, and 16 days, respectively. The blood supply was relatively good after incision of the tunica albuginea in the child who had 4 h of torsion. In the remaining four cases, warm saline was applied with decreased blood supply being observed after the incision. The details of these children's treatment are shown in **Table 1**. The 5 children that had an orchidopexy were followed up from 1 month to 7 years (median: 3 years), among which, 1 child had testis retraction with no blood supply, while the remaining 4 children had good outcomes during follow-up (**Table 1**). The four children with preserved testicles had ultrasound to assess testicular size before surgery and at follow-up (**Table 2**).

A telephone follow-up was used to retrospectively investigate the reasons for treatment delays in the children. Of the 12 children who had an orchiectomy, 3 cases had a delay in treatment because their parents were unaware of the presence of cryptorchidism, while 9 cases were delayed due to a delayed referral from primary medical facilities.

DISCUSSION

Pathogenesis

Cryptorchidism with torsion is a specific type of testicular torsion. Williamson⁴ reported that cryptorchidism with torsion accounted for 5%–15% of testicular torsions. He also showed that the risk of cryptorchidism with torsion was 10 times higher than that of scrotal testicular torsion.⁴ The pathogenesis of cryptorchidism is unclear and may be related to the following factors: (1) abnormal contraction and spasm of the cremaster,⁵ with previous reports showing patients with neuromuscular disease or cerebral palsy appear to be more susceptible to torsion;^{6,7} in our study, no child had either cerebral palsy or neuromuscular disease, although this result may be attributable to differences in the sample size of the studies. (2) Torsion can occur in association with the altered testicular weight if cryptorchidism is combined with a testicular tumor.⁸ This pathogenesis is corroborated by the fact that our study included two cases of cryptorchidism combined with a testicular teratoma.

Table 1: Case information (n=19)

Clinical and demographic feature	Value
Age, range (median)	16 days–12 years (6 years)
Clinical presentation, <i>n</i> (%)	
Pain and/or mass in the inguinal region	18 (94.7)
Abdominal mass	1 (5.3)
Duration of symptoms, range (median)	4 h–16 days (3 days)
Ultrasound, <i>n</i> (%)	
Cryptorchidism with torsion	15 (78.9)
Soft tissue mass in the inguinal region	2 (10.5)
Teratoma of the inguinal region/ intra-abdominal cavity	2 (10.5)
Surgery, <i>n</i> (%)	
Orchidopexy	5 (26.3)
Testicular tumor resection	2 (10.5)
Orchiectomy	12 (63.2)
Torsion angle, range (median)	270°–1080° (720°)
Location of cryptorchidism, <i>n</i> (%)	
Inguinal canal	18 (94.7)
Abdomen	1 (5.3)
Comorbidity, <i>n</i> (%)	
Bilateral cryptorchidism	4 (21.1)
Hypospadias	1 (5.3)
Teratoma of the testis	2 (10.5)
Follow-up of children with orchidopexy	
Time, range (median)	1 month–7 years (3 years)
Good blood supply, <i>n</i> (%)	4 (80.0)
No blood supply and atrophy, <i>n</i> (%)	1 (20.0)
Follow-up of children with orchiectomy	
Time, range (median)	3 months–15 years (4 years)
Normal position and good blood supply to the contralateral testicle, <i>n</i> (%)	12 (100.0)

Table 2: Testicular size of four children with preserved testicles at preoperation and follow-up

Preoperative testicular size (cm ³)	Testicular size at the last follow-up (cm ³)	Follow-up time
1.8×1.2×1.0	1.7×1.2×1.0	1 month
1.6×1.2×0.9	2.3×1.9×1.4	7 years
1.0×0.8×0.6	1.2×0.8×0.7	2 years
2.0×1.6×1.1	3.0×2.1×1.5	6 years

(3) The abnormality of cryptorchidism causes the testis to lose normal anatomical fixation. In addition, polar attachment of the testicular gubernaculum and increased testicular mobility make the cryptorchidism more susceptible to torsion.

Age of patients with cryptorchidism

Cryptorchidism with torsion can occur at all ages as previous studies have reported cases even in the neonatal/infant period. For example, Singal *et al.*⁹ reported six cases of cryptorchidism with torsion aged from 4 months to 2 years (median: 7.5 months), while Kargl and Haid¹⁰ reported a total of 11 cases at a dual medical center with a mean age of 9.4 months (range: 1–22 months). A study by Ito *et al.*⁷ also reported the age of children with the condition ranged from 1 year to 20 years (median: 15 years). Our study also showed a wide age range from 16 days to 12 years (median: 6 years). Taken together, these findings confirm that torsion can occur at any age in children with cryptorchidism before an orchidopexy is performed. Therefore,



in children with a clear diagnosis of cryptorchidism, especially those with delayed surgery due to clinical and economic factors, such as living in a poor area or those with uncomplicated urinary tract disease or an inguinal hernia/synovial effusion,¹¹ it is important that their families should be aware of not only the possibility of testicular malignancy, testicular atrophy, and low fertility but also the likelihood of cryptorchidism with torsion. This awareness and timely detection by parents are important for saving the testis.

Clinical features and diagnosis

Clinical presentation and physical examination are important methods for early detection of cryptorchidism with torsion and to achieve successful testicular salvage. Most cases of cryptorchidism with torsion in our report occurred in the inguinal canal (94.7%), which was consistent with that reported by Dupond-Athénor *et al.*¹² (93%). The typical clinical presentations are therefore a mass in the inguinal region with pain and ipsilateral scrotal emptiness. A small number of cryptorchidism with torsions are located in the abdomen or near the internal ring, so in some children, it may not be possible to palpate the mass, with these cases presenting with an acute abdomen, gastrointestinal symptoms, fever, and local inflammation.¹² Ultrasound is the first method used to examine the blood supply of the testis and is also the primary adjunct for identifying inguinal hernias, lymphadenitis, appendicitis, acute intestinal obstruction, and other conditions. However, clinicians should not rely too much on ultrasound because its sensitivity to diagnose cryptorchidism with torsion is related closely to the experience and skill of the ultrasonographer, and therefore may vary between hospitals and individual ultrasonographers. In our study, ultrasound diagnosed cryptorchidism with torsion in 15 cases (78.9%), similar to previous studies that reported a sensitivity of 42.1%–100%.^{10,12,13} Therefore, once a clinician suspects cryptorchidism with torsion, surgical exploration is worthwhile even if the ultrasound does not support this diagnosis. Computed tomography or ^{99m}Tc testicular scintigraphy have also been reported to assist with diagnosis,^{14,15} although these procedures are prolonged and may delay surgery and are therefore not used as routine adjunctive examinations.

Treatment

Surgery is the only way to save the testis. Salvage success rates correlate to both the time and the angle of torsion. An angle of torsion >360° increases the risk of testicular necrosis.¹³ A salvage success rate of 97.2% was achieved within 0–6 h of resuscitation,¹⁶ with the risk of testicular necrosis increasing by approximately 5% with every 10 min of delay in surgical resuscitation.¹⁷ Our testicular salvage rate was very low at 26.3% compared with the salvage rate of 0–50% reported in previous studies.^{7,9,10,12,13,18,19} We performed orchidopexy on 5 children, with time from onset to surgery and angle of torsion being: (1) 24 h and 270° (**Figure 1**), (2) 48 h and 720°, (3) 36 h and 450°, (4) 16 days and 360°, and (5) 4 h and 360°. The successful testicular salvage in child (5) was within our expectations, whereas we did not anticipate a successful salvage in the other four children. In addition, four children had a long onset and large torsional angles. Noting this unexpected outcome, we pursued the history of testicular pain and found that three children, except child (4) (a neonate), had a pattern of pain-remission-pain in the inguinal region. It was therefore considered that they may have an intermittent testicular torsion (ITT). Previous reports of ITT cases have been associated with scrotal testicular torsion; however, this article might be the case of ITT associated with cryptorchidism. The diagnosis of cryptorchidism with ITT is more difficult because

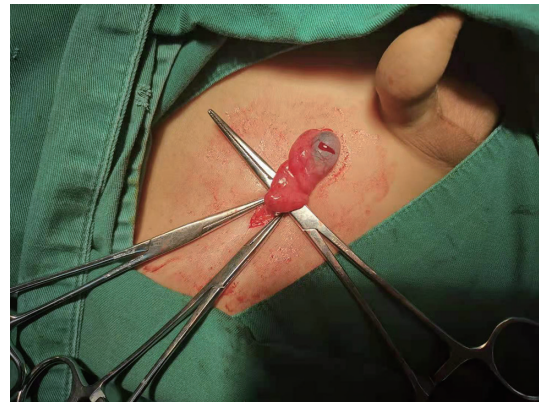


Figure 1: The child (1), with preoperative pain in the right inguinal region for 24 h, whose right testicle was found intraoperatively to be twisted 270°. There was blood supply on incision.

the physical examination and ultrasound may be completely normal during the intermittent period, with typical clinical and ultrasound findings observed only in cases of acute torsion. Therefore, if a child with cryptorchidism presents with a pain-remission-pain pattern, the possibility of cryptorchidism with ITT should be considered after other diagnoses have been excluded. In acute torsion of cryptorchidism with ITT, surgery is also the first choice because repeated ischaemic nonspecific injury and postischaemic reperfusion injury can lead to testicular atrophy that is characterized by varicocele fibrosis and azoospermia.²⁰ We, therefore, consider that it is beneficial in cases of cryptorchidism with ITT for the child to undergo early orchidopexy, even in the intermittent period. At our center, contralateral testicular fixation was performed simultaneously in all cases, and we advocate this approach, as do most scholars because it prevents the loss of the contralateral testis in the event of unpredictable adverse events.¹⁸

Outcomes and reasons for delayed treatment

The children were divided into orchidopexy and orchiectomy groups for follow-up. In the orchidopexy group, there was one case of atrophy while the other children had good outcomes. In the orchiectomy group, we followed up for the presence of contralateral testis and found that none of the children had this abnormality.

We investigated the causes of delayed treatment in 12 children with orchiectomy and found 75.0% were due to delayed referral from primary medical care and 25.0% were due to family unawareness. This result showed that lack of awareness about cryptorchidism with torsion in some primary medical facilities was a major factor for delaying diagnosis and treatment. Therefore, hospitals of all levels should be aware of the possibility of cryptorchidism with torsion. To avoid the increased risk of testicular loss due to delayed referral, it is essential to examine the genital system and inguinal region and investigate surgically as soon as possible if cryptorchidism with torsion is suspected. It is also important to educate parents so that they acquire a knowledge of cryptorchidism in children and are sufficiently aware of the need to seek timely medical help in emergency cases of cryptorchidism with torsion.

Limitations

This was a retrospective clinical analysis and therefore may have the following limitations: (1) we could not avoid missing some eligible cases when collecting data, and (2) when investigating the causes of delayed diagnosis and treatment, we used late telephone follow-ups, which may have resulted in recall bias in the families.

CONCLUSIONS

Medical institutions of all levels and family members should be fully aware of the possibility of testicular loss due to cryptorchidism with torsion. Ultrasound is an important diagnostic tool, although the results may vary according to the experience and skills of the ultrasonographers. In addition, the clinical presentation and examination of the genital system should be the main focus in these cases. Once cryptorchidism with torsion is suspected, it is important to immediately perform a surgical investigation.

AUTHOR CONTRIBUTIONS

MY contributed to manuscript writing, data analysis, and project development. SW contributed to project development and manuscript review. XL, SDW, and PRH contributed to manuscript editing. TL performed literature search and data collection. DYZ performed literature search. GHW contributed to manuscript editing and data analysis. FL reviewed the manuscript. YH participated in manuscript editing, project development and manuscript review. All authors read and approved the final manuscript.

COMPETING INTERESTS

All authors declare no competing interests.

ACKNOWLEDGMENTS

This study was supported by the Basic Research and Frontier Exploration Project of Chongqing Science and Technology Bureau of Yuzhong District (No. 20200151).

REFERENCES

- Gurney JK, McGlynn KA, Stanley J, Merriman T, Signal V, *et al*. Risk factors for cryptorchidism. *Nat Rev Urol* 2017; 14: 534-48.
- Cheng L, Albers P, Berney DM, Feldman DR, Daugaard G, *et al*. Testicular cancer. *Nat Rev Dis Primers* 2018; 4: 29.
- Leslie SW, Sajjad H, Villanueva CA. Cryptorchidism. Treasure Island (FL): StatPearls Publishing; 2021. p8.
- Williamson RC. Torsion of the testis and allied conditions. *Br J Surg* 1976; 63: 465-76.
- Naouar S, Braiek S, El Kamel R. Testicular torsion in undescended testis: a persistent challenge. *Asian J Urol* 2017; 4: 111-5.

- Guida E, Verzotti E, Codrich D, Pederiva F, Di Grazia M, *et al*. Voiceless disability: a worth case of bilateral inguinal testicular torsion in a patient with cerebropalsy. *Ann Med Surg (Lond)* 2018; 33: 47-9.
- Ito T, Matsui F, Fujimoto K, Matsuyama S, Yazawa K, *et al*. Acquired undescended testis and possibly associated testicular torsion in children with cerebral palsy or neuromuscular disease. *J Pediatr Urol* 2018; 14: 402-6.
- Ghobashy A, Hasan D, AbdElsalam A, Ahmed A, Arafat A, *et al*. Acute abdomen caused by rupture of a torqued intra-abdominal testicular mass: case report. *Int J Surg Case Rep* 2020; 68: 224-7.
- Singal AK, Jain V, Dubey M, Deshpande P. Undescended testis and torsion: is the risk understated? *Arch Dis Child* 2013; 98: 77-9.
- Kargl S, Haid B. Torsion of an undescended testis - a surgical pediatric emergency. *J Pediatr Surg* 2020; 55: 660-4.
- Zhao TX, Liu B, Wei YX, Wei Y, Tang XL, *et al*. Clinical and socioeconomic factors associated with delayed orchidopexy in cryptorchid boys in China: a retrospective study of 2423 cases. *Asian J Androl* 2019; 21: 304-8.
- Dupond-Ath  nor A, Peycelon M, Abbo O, Rod J, Haraux E, *et al*. A multicenter review of undescended testis torsion: a plea for early management. *J Pediatr Urol* 2021; 17: 191.e1-6.
- Deng T, Zhang X, Wang G, Duan S, Fu M, *et al*. Children with cryptorchidism complicated by testicular torsion: a case series. *Urol Int* 2019; 102: 113-7.
- Klang E, Kanaan N, Soudack M, Kleinbaum Y, Heiman Z, *et al*. Torsed and nontorsed inguinal undescended testis: comparison of computed tomography findings. *J Comput Assist Tomogr* 2017; 41: 633-7.
- Shayegani H, Divband G, Tavakkoli M, Banihasan M, Sadeghi R. Torsion of the undescended testis detected by ^{99m}Tc testicular scintigraphy: a case report. *Nucl Med Rev Cent East Eur* 2016; 19: 24-5.
- Mellick LB, Sinex JE, Gibson RW, Mears K. A systematic review of testicle survival time after a torsion event. *Pediatr Emerg Care* 2019; 35: 821-5.
- Gold DD, Lorber A, Levine H, Rosenberg S, Duvdevani M, *et al*. Door to detorsion time determines testicular survival. *Urology* 2019; 133: 211-5.
- Zilberman D, Inbar Y, Heyman Z, Shinhar D, Bilik R, *et al*. Torsion of the cryptorchid testis - can it be salvaged? *J Urol* 2006; 175: 2287-9.
- Pogoreli   Z, Mrkli   I, Juri   I, Bio  i   M, Furlan D. Testicular torsion in the inguinal canal in children. *J Pediatr Urol* 2013; 9: 793-7.
- Hayn MH, Herz DB, Bellinger MF, Schneck FX. Intermittent torsion of the spermatic cord portends an increased risk of acute testicular infarction. *J Urol* 2008; 180: 1729-32.

This is an open access journal, and articles are distributed under the terms of the Creative Commons Attribution-NonCommercial-ShareAlike 4.0 License, which allows others to remix, tweak, and build upon the work non-commercially, as long as appropriate credit is given and the new creations are licensed under the identical terms.

  The Author(s)(2022)

