

An unusual case report of brain abscess caused by *prevotella loescheii* identified using the metagenomic next-generation sequencing

Shuixiang Deng^a, Hongda Zhu^b, Yuming Li^a, Feng Zhao^a, Umut Ocak^c, Ye Gong^{a,*}

^a Department of Critical Care Medicine, Huashan Hospital Affiliated to Fudan University, Shanghai, China

^b Department of Neurosurgery, Huashan Hospital Affiliated to Fudan University, Shanghai, China

^c Department of Emergency Medicine, University of Health Sciences, Bursa Yuksek Ihtisas Training and Research Hospital, Bursa, 16290, Turkey

ARTICLE INFO

Article history:

Received 13 October 2019

Received in revised form 1 December 2019

Accepted 21 March 2020

Keywords:

Brain abscess

Prevotella loescheii

Metagenomic next-generation sequencing

ABSTRACT

Objectives: Brain abscess (BA) is a rare and life-threatening disease which remains to be a challenge for physicians despite recent advances in both the diagnosis and treatment strategies. Appropriate management of brain abscesses requires a combined surgical and medical approach to prevent associated life-threatening complications. In clinical practice, new diagnostic techniques, such as metagenomic next-generation sequencing (mNGS) and quantitative electroencephalogram (qEEG), can help physicians identify the causative pathogens of brain abscesses in order to provide early pathogen-targeted therapy. **Clinical presentation:** Here, we report a case of a 27-year-old Chinese woman with a *Prevotella loescheii* brain abscess into ventricular system. The diagnosis of the causative pathogen was identified by mNGS of abscess drainage fluid, leading to precise and targeted antimicrobial therapy and successful management of the abscess. We, therefore, avoided devastating consequences of the intraventricular rupture of the brain abscess.

Conclusion: Appropriate management of BA requires a combination of both surgical and medical approaches. The increasing availability of molecular diagnostic techniques, such as the mNGS that is used to elucidate the microbial composition of the abscesses for definitive diagnosis, is likely to drive the future development of optimal treatment strategies for BA.

© 2020 The Author(s). Published by Elsevier Ltd. This is an open access article under the CC BY-NC-ND license (<http://creativecommons.org/licenses/by-nc-nd/4.0/>).

Introduction

Brain abscess (BA), accounting for 15–25 % of all intracranial bacterial infections, is a rare but life-threatening disease, which remains to be a challenge for physicians [1]. Previously reported mortality rates in patients with rupture BA into the ventricular system ranged between 27–85 % [2]. As a result of the advances in antibiotic treatment, brain imaging techniques, as well as minimally invasive neurosurgical procedures, the mortality of BA has declined from 40 % to 10 %–20 % during the past decade [3]. As BA can be caused by various micro-organisms, failure to obtain a timely and precise diagnosis may result in delaying in the targeted antimicrobial treatment, leading to unnecessary use of broad-spectrum antibiotic which then induces antimicrobial resistance, and causes a high cost burden to the health care system [4].

Metagenomic next-generation sequencing (mNGS) is a promising approach that can theoretically identify a broad range of pathogens in the cerebrospinal fluid (CSF) and provide definitive-information for the physician [5]. Here, we describe a case of BA caused by *prevotella loescheii* which was identified by mNGS and was successfully treated at our institution.

Clinical presentation

A 27-year-old female patient presented to our hospital complaining of progressive headache and vomiting. The symptoms had started 2-week ago. She also complained of fevers along with chills and night sweats for the past 2 days. The medical history of the patient was unremarkable except for giving birth vaginally to a full-term baby five months ago. She denied any history of smoking or alcohol and/or drug as well as comorbid diseases.

Physical examination

Her vitals were as follows: axillary temperature 38.8 °C, heart rate 101 bpm, blood pressure of 118/60 mmHg and oxygen saturation of 100 % on room air. Her neurologic examination upon

* Corresponding author at: Department of Critical Care Medicine, Huashan Hospital Affiliated to Fudan University, 200040, No.12 Middle Urumqi Road, Shanghai, China.

E-mail addresses: shuixiang2@126.com (S. Deng), drgongyeicu@163.com (Y. Gong).

arrival revealed a Glasgow Coma Scale(GCS)score of 14. Then, her consciousness started to decrease, and she experienced a tonic-clonic epileptic seizure which lasted for 2 min and stopped by diazepam. She had no facial weakness and neck stiffness. The rest of her physical examination was unremarkable.

Diagnostic assessment

The computerized tomography (CT) scan of the head revealed a 2-cm hyperintense lesion located at the midline at the level of the 3rd ventricle. The lesion was hypointense to the brain parenchyma

on T1-weighted (T1W1) magnetic resonance (MR) imaging and was associated with significant peri-lesional edema (Fig. 1A–D). Single voxel MR spectroscopy (MRS) showed a slightly increases choline peak of right thalamic mass (Fig. 1E–F). Continuous quantitative EEG showed normal bilateral cerebral blood flow with no significant epileptiform activity (Fig. 1M).

Her initial lab results revealed a white blood cell count 21×10^9 cells/ μ L. The C-reactive protein level was 155 mg/L, procalcitonin was 1.96 ng/mL, and erythrocyte sedimentation rate was 35 mm/h. Blood and urine cultures were all negative. Blood gas analysis and liver, kidney, and cardiac function as well as blood electrolyte tests

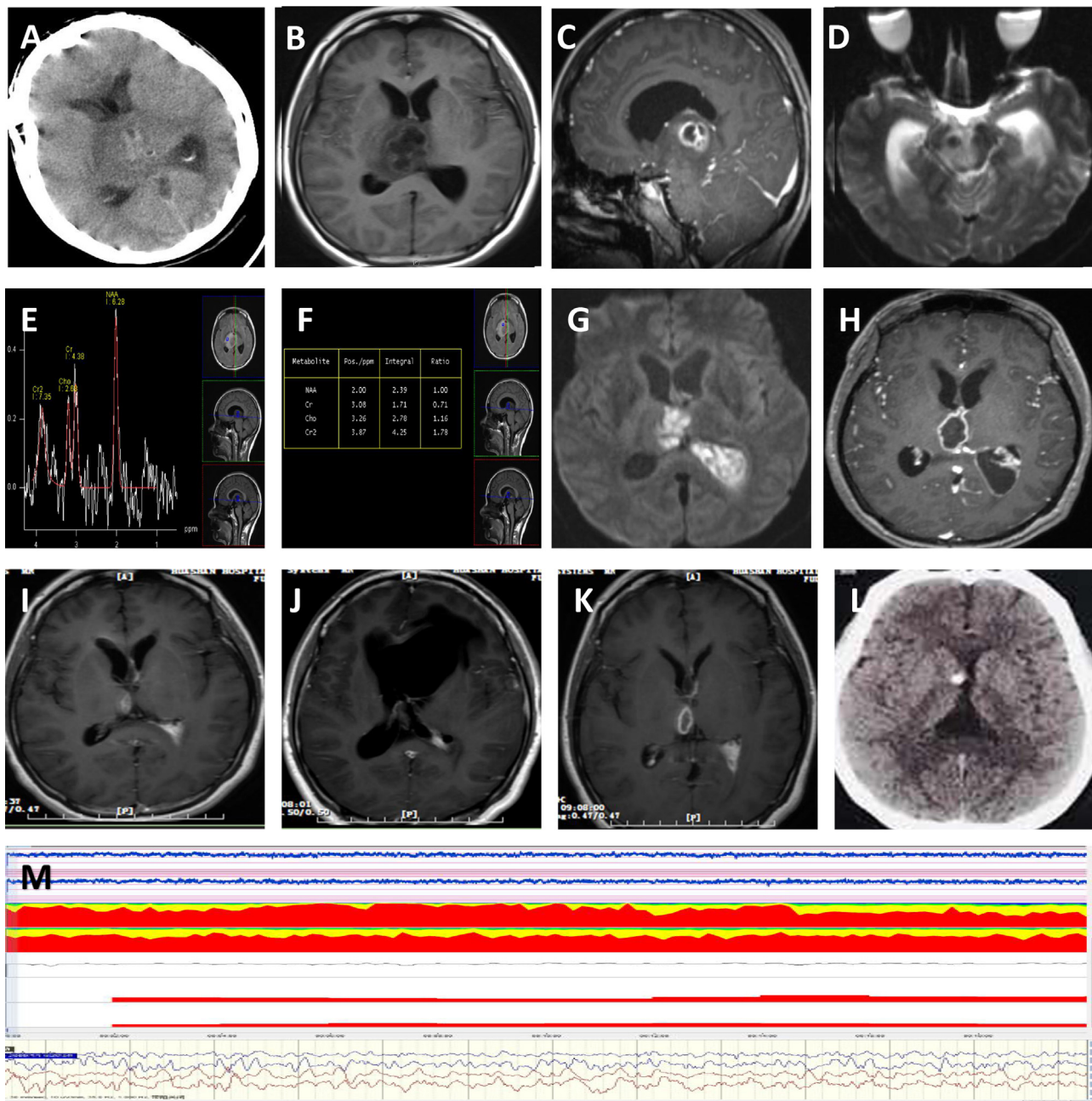


Fig. 1. (A) Pre-admission non-contrast CT scan of the patient, revealing a 2-cm hyperdense lesion located at the midline at the level of the 3rd ventricle. (B) Axial, non-contrast T1-weighted(T1W1)MRI, (C) Coronal, post-contrast T1WI MRI and (D) Diffusion-weighted MRI were obtained upon admission, demonstrating a hypodense multiloculated lesion in the left thalamus with annular enhancement of the abscess wall. (E) and (F) Single voxel MR spectroscopy (MRS) showing decreased N-acetylaspartate peak and a slightly increased choline peak of the right thalamic mass. (G) Axial, post-contrast T1WI MRI and (H) Diffusion-weighted MRI on day 14, demonstrating restricted diffusion and rim enhancement. Axial post-contrast MRI (I) one week, (J) 1 month, (K) 2 months following the drainage of the abscess and (L) Axial non-contrast CT scan obtained at 6-month follow-up. (M) Continuous quantitative EEG monitoring showing normal bilateral cerebral blood flow with no significant epileptiform activity.

were within normal limits. The first mNGS(The Beijing Genomics Institute, China) of the blood 1day after admission was also negative.

Therapeutic intervention

The patient was started on empirical antibiotic therapy with vancomycin (500 mg q12 h iv), and meropenem (1.0 g q6h iv). Antiepileptic drug Levetiracetam (0.5 g q12 h po) was gave to prevent seizure. After treatment the fever was control. On hospital day 14, the patient had aggravation of consciousness to coma with GCS 3 and she was intubated and mechanical assistance. Coronal MR imaging demonstrated that the lesion centered on the right thalamus was opened into the occipital horn of the left frontal ventricle. The opening of the abscess into the ventricle was confirmed by diffusion weighted MR imaging (Fig. 1G–H).

She underwent minimally invasive surgical drainage for thalamic cerebral abscess and external ventricular drainage. Cerebrospinal fluid analyses revealed a cell count of 4044×10^6 cells /L and protein 4+ with normal glucose levels. Examination of CSF with Gram, acid-fast, and ink stains as well as cultures for aerobic, mycobacterial, and fungal were all negative. The second mNGS was applied to the CSF obtained from the surgical drainage material, which showed *prevotella loescheii* with the number of sequences 175. Repeated post-contrast MR imaging one week after the drainage of the abscess revealed that the lesion reduced in size (Fig. 1I). After the precise diagnosis obtained by mNGS, the antibiotics were switched to ceftazidime (2.0 g q12 h iv), metronidazole (0.5 g q12 h iv) and vancomycin (500 mg q12 h iv) on day 15. It is worth noting that with the identification of *Prevotella loescheii*, the antimicrobials were narrowed but given the condition of the patient overall broad coverage was retained.

Follow-up and outcomes

MR imaging obtained on day 30 following the drainage of the abscess, revealed a further decrease in size of the lesion compared to previous images (Fig. 1J). Given the concomitantly improved neurologic status of the patient, the ventricular drainage catheter was removed on day 35. After a 3-month course of treatment, coronal MR imaging showed complete resorption of the lesion (Fig. 1K). At 6-month follow-up, the patient made excellent recovery with no residual or recurrent abscess (Fig. 1L).

Discussion

Strengths of mNGS

In this present case, *prevotella loescheii* was identified in the brain abscess fluid by mNGS which provided the microbiological diagnosis although the CSF and blood cultures for this bacterium were negative. The rate of positive CSF cultures in the literature vary, which report microorganisms' growth in a wide range between 2.8 % and 44 % [6]. Previous literature also demonstrated that mNGS yielded a higher sensitivity for the identification of the causative pathogen when compared to traditional methods and it was less affected by prior antibiotic exposure, thereby emerging as a promising approach for the diagnosis of infectious diseases [7,8].

“Take-away” lessons

Intraventricular rupture of brain abscess was previously reported to be associated with unfavorable outcome [2,9]. In the present case, the patient's neurologic condition deteriorated 2 weeks after the initiation of the treatment and repeated MRI

showed that the abscess was opened into the ventricle. We, therefore, consulted the patient with the neurosurgery department for a possible intervention for the drainage of the abscess, which would also make a microbiological diagnosis possible as early aspiration of brain abscesses. Hence, in cases without clinical and radiological improvement of the abscess within 1–2 weeks of the initiation of the antimicrobial treatment, a neurosurgical intervention should be considered [10].

Management of BA

Currently, there are no accurate guidelines in the management of BA. The most commonly used antimicrobials are cephalosporines (95 %), nitroimidazoles (72 %), meropenem (31 %) and vancomycin (28 %) [11]. Although there is no consensus regarding the course of the treatment, an overall treatment of 4–6 weeks for patients who underwent surgical intervention and a parenteral therapy of 6–8 weeks for patients who were treated with medical therapy only were recommended previously [12]. In the present case, a 3-month course of ceftazidime, metronidazole and vancomycin combined with the drainage of the abscess were considered for this patient. The patient recovered completely despite the potentially devastating complications of abscess rupture into the ventricle, so we believe appropriate management of BA requires a combination of both surgical and medical approaches.

Conclusion

BA caused by bacteria continues to be a potentially devastating disease process that requires rapid recognition and initiation of the treatment by clinicians to prevent potentially life-threatening complications. The increasing availability of molecular diagnostic techniques, such as mNGS that is used to elucidate the microbial composition of the abscesses for definitive diagnosis in the present case, is likely to drive the future development of optimal treatment strategies for BA.

Author statement

We would like to submit the enclosed manuscript entitled “An unusual case report of brain abscess caused by *prevotella loescheii* identified using the metagenomic next-generation sequencing”, which we wish to be considered for publication in “IDcase”. No conflict of interest exists in the submission of this manuscript, and manuscript is approved by all authors for publication. All the authors listed have approved the manuscript that is enclosed.

Consent for publication

We have obtained the written consent of patient to publish.

Funding

This work was supported by the Shanghai Science and Technology Committee. The grants No. are 18140901100, 2018YFC1312600, 2018YFC1312604 and 20184Y0064.

Declaration of Competing Interest

None.

Appendix A. Supplementary data

Supplementary material related to this article can be found, in the online version, at doi:<https://doi.org/10.1016/j.idcr.2020.e00758>.

References

- [1] Brouwer MC, van de Beek D. Epidemiology, diagnosis, and treatment of brain abscesses. *Curr Opin Infect Dis* 2017;30(February (1)):129–34.
- [2] Tunthanathip T, Kanjanapradit K, Sae-Heng S, Oearsakul T, Sakarunchai I. Predictive factors of the outcome and intraventricular rupture of brain abscess. *J Med Assoc Thai* 2015;98(February (2)):170–80.
- [3] Laulajainen-Hongisto A, Lempinen L, Farkkila E, et al. Intracranial abscesses over the last four decades; changes in aetiology, diagnostics, treatment and outcome. *Infect Dis (Lond, England)* 2016;48(April (4)):310–6.
- [4] Brouwer MC, Coutinho JM, van de Beek D. Clinical characteristics and outcome of brain abscess: systematic review and meta-analysis. *Neurology* 2014;82(March (9)):806–13.
- [5] Wilson MR, Sample HA, Zorn KC, et al. Clinical metagenomic sequencing for diagnosis of meningitis and encephalitis. *N Engl J Med* 2019;380(June (24)):2327–40.
- [6] Brouwer MC, Tunkel AR, McKhann 2nd GM, van de Beek D. Brain abscess. *N Engl J Med* 2014;371(July (5)):447–56.
- [7] Forbes JD, Knox NC, Ronholm J, Pagotto F, Reimer A. Metagenomics: the next culture-independent game changer. *Front Microbiol* 2017;8:1069.
- [8] Miao Q, Ma Y, Wang Q, et al. Microbiological diagnostic performance of metagenomic next-generation sequencing when applied to clinical practice. *Clin Infect Dis* 2018;67(November (suppl_2)):S231–s240.
- [9] Takeshita M, Kawamata T, Izawa M, Hori T. Prodromal signs and clinical factors influencing outcome in patients with intraventricular rupture of purulent brain abscess. *Neurosurgery* 2001;48(February (2)):310–6 discussion 316–317.
- [10] Zhai Y, Wei X, Chen R, Guo Z, Raj Singh R, Zhang Y. Surgical outcome of encapsulated brain abscess in superficial non-eloquent area: a systematic review. *Br J Neurosurg* 2016;30(1):29–34.
- [11] Bodilsen J, Brouwer MC, Nielsen H, Van De Beek D. Anti-infective treatment of brain abscess. *Expert Rev Anti Infect Ther* 2018;16(July (7)):565–78.
- [12] Xia C, Jiang X, Niu C. May short-course intravenous antimicrobial administration be as a standard therapy for bacterial brain abscess treated surgically? *Neurol Res* 2016;38(May (5)):414–9.