

Contents lists available at [ScienceDirect](https://www.sciencedirect.com)

International Journal of Surgery Case Reports

journal homepage: www.casereports.com

Internal hernia of the small intestine around biliary catheter after living-donor liver transplantation: A case report

Mohamed Abdel Wahab^a, Ahmed Shehta^{a,*}, Reham Adly^b, Mohamed Elshoubary^a, Tarek Salah^a, Amr M. Yassen^c, Mohamed Elmorshedi^c, Moataz M. Emara^c, Mostafa Abdelkhalek^c, Mahmoud Elsedeiq^c, Usama Shiha^d, Ahmed N. Elghawalby^a, Mohamed Eldesoky^a, Ahmed Monier^a, Rami Said^a

^a Department of Surgery, Gastrointestinal Surgery Center, College of Medicine, Mansoura University, Egypt

^b Department of Hepatology, Gastrointestinal Surgery Center, College of Medicine, Mansoura University, Egypt

^c Department of Anesthesia and Intensive Care, Gastrointestinal Surgery Center, College of Medicine, Mansoura University, Egypt

^d Diagnostic & Interventional Radiology Department, Gastrointestinal Surgery Center, College of Medicine, Mansoura University, Egypt

ARTICLE INFO

Article history:

Received 9 May 2018

Accepted 22 June 2018

Available online 28 June 2018

Keywords:

Living donor liver transplantation

Trans-anastomotic biliary catheter

Intestinal obstruction

ABSTRACT

INTRODUCTION: Biliary reconstruction is a cornerstone of living-donor liver transplantation (LDLT). The routine uses of trans-anastomotic biliary catheters in biliary reconstruction had been a controversial issue. We describe a rare complication related to the use of trans-anastomotic biliary catheter after LDLT. In this case, intestinal obstruction occurred early after LDLT due to internal herniation of the small bowel around trans-anastomotic biliary catheter.

PRESENTATION: A 42 years male patient with end stage liver disease underwent LDLT utilizing a right hemi-liver graft. Biliary reconstruction was done by single duct-to-duct anastomosis over trans-anastomotic biliary catheter. The patient was doing well apart from early postoperative ascites that was managed medically.

Three weeks after surgery, the patient developed severe agonizing central abdominal pain not responding to anti-spasmodics and analgesics. The decision was to proceed for surgical exploration. Exploration revealed internal herniation of the small bowel loops around the trans-anastomotic biliary catheter without strangulation. Reduction of the internal hernia was done by releasing the fixation of the biliary catheter from the anterior abdominal wall. Small bowel resection was not required. The patient had smooth postoperative course and was discharged 10 days after surgery.

DISCUSSION: Awareness regarding this rare complication plus early surgical intervention can prevent the development of postoperative morbidity and mortality. To the best of our knowledge this is the first report to describe such a complication after LDLT.

CONCLUSION: We report the first case of internal herniation of small bowel around biliary catheter early after LDLT.

© 2018 The Authors. Published by Elsevier Ltd on behalf of IJS Publishing Group Ltd. This is an open access article under the CC BY-NC-ND license (<http://creativecommons.org/licenses/by-nc-nd/4.0/>).

1. Introduction

Liver transplantation is considered the only effective treatment for patients with end stage liver disease and selected hepatic malignancies. Nowadays, living-donor liver transplantation (LDLT) is

considered an acceptable and safe alternative option to deceased donor liver transplantation [1–3].

Biliary reconstruction is a cornerstone of LDLT. It is performed most commonly by a duct-to-duct anastomosis. Despite the accumulating experience in LDLT, the incidence of biliary complications remains high [4,5].

The routine uses of trans-anastomotic biliary catheters in duct-to-duct biliary reconstruction had been a controversial issue, and most of studies did not prove a real advantage of its routine use [6–8]. In our center, we routinely use trans-anastomotic biliary catheters during duct-to-duct biliary anastomosis [9]. The advantages of its routine use are to facilitate healing of the anastomosis, decrease the incidence of anastomotic biliary leakage, and allows easy evaluation of biliary anastomosis by cholangiogram. However,

Abbreviations: LDLT, living-donor liver transplantation; MELD, model for end stage liver disease; CT, computed tomography; GRWR, graft to recipient weight ratio; US, ultrasound.

* Corresponding author at: Liver Transplantation Unit, Gastrointestinal Surgery Center, College of Medicine, Mansoura University, Gehan Street, Mansoura, 35516, Egypt.

E-mail address: ahmedshehta@mans.edu.eg (A. Shehta).

<https://doi.org/10.1016/j.ijscr.2018.06.023>

2210-2612/© 2018 The Authors. Published by Elsevier Ltd on behalf of IJS Publishing Group Ltd. This is an open access article under the CC BY-NC-ND license (<http://creativecommons.org/licenses/by-nc-nd/4.0/>).

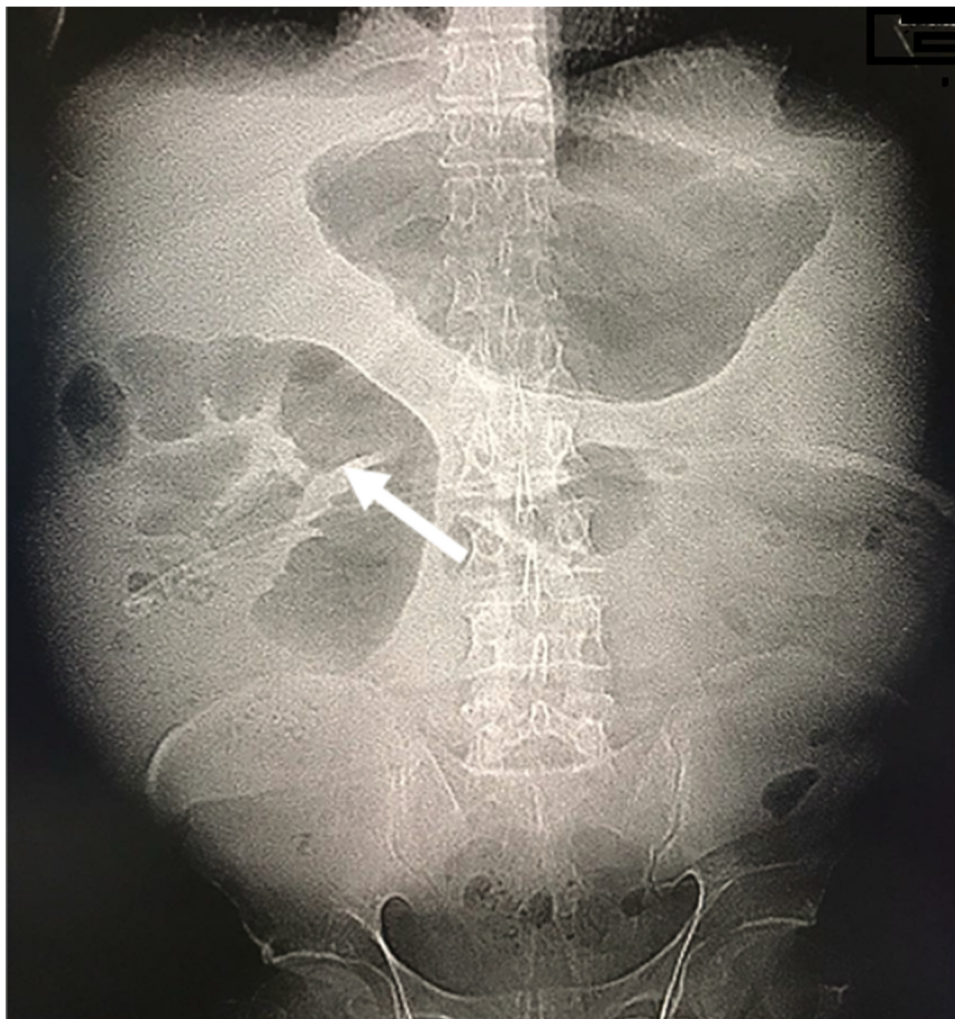


Fig. 1. Plain abdominal radiograph (erect) showing fixed dilated small bowel loop in the right hypochondrial region (arrow).

several disadvantages related to its use had been reported including cholangitis, biliary leakage at the site of its exit, cholangiogram related complications, and the development of non-anastomotic biliary strictures [6].

In this report, we describe a rare complication related to the use of trans-anastomotic biliary catheter after LDLT. In this case, intestinal obstruction occurred early after LDLT due to internal herniation of the small bowel around trans-anastomotic biliary catheter. To the best of our knowledge this is the first report to describe such complication after LDLT. This work has been reported in line with the SCARE criteria [10].

2. Case presentation

42 years male patient with end-stage liver disease due to chronic hepatitis C virus infection. He was planned for LDLT. His preoperative Child-Pugh score was 10 (class C), and model for end stage liver disease (MELD) was 15. Preoperative triphasic abdominal computed tomography (CT) showed markedly cirrhotic liver, markedly enlarged spleen, and mild pelvic ascites.

He received a right hemi-liver graft without the middle hepatic vein from his nephew (33 years old). The actual graft weight was 1056 g and graft weight to recipient weight ratio (GRWR) was 1.15.

The graft had a single dominant right hepatic vein (30 mm) and was anastomosed to the recipient right hepatic vein with venoplasty (30 mm). The recipient main portal vein stump (14 mm) was

anastomosed, in end to end fashion, to the graft portal vein (8 mm). Then arterial reconstruction was done between the graft right hepatic artery (2 mm) and the recipient right hepatic artery (3 mm).

Doppler ultrasound (US) was performed upon completion of all vascular anastomoses and showed sound anastomoses and adequate inflow and outflow without congestion.

Biliary reconstruction was done by duct-to-duct anastomosis between the graft right hepatic duct (4 mm) and the recipient right hepatic duct (4 mm) over trans-anastomotic biliary catheter (4 french) exiting through a separate opening into the common bile duct. Completion cholangiogram showed adequate biliary anastomosis with no leakage.

Postoperatively, the patient was transferred to the intensive care unit. Extubation was done in the first postoperative day. The patient has smooth postoperative course and was transferred to the ward on the fifth postoperative day.

In the ward, the patient was doing well apart from early postoperative ascites that was managed by intravenous albumin 4% infusion daily and monitoring of serum electrolytes. Doppler US was performed daily to check patency of all vascular anastomoses and adequate inflow and outflow to the graft.

On the 25th postoperative day, the patient developed severe agonizing central abdominal pain. There was no vomiting or constipation. Abdominal examination was free. Serum total leucocytic count was normal. The patient received intravenous anti-spasmodics and analgesics with no improvement of the abdominal pain.

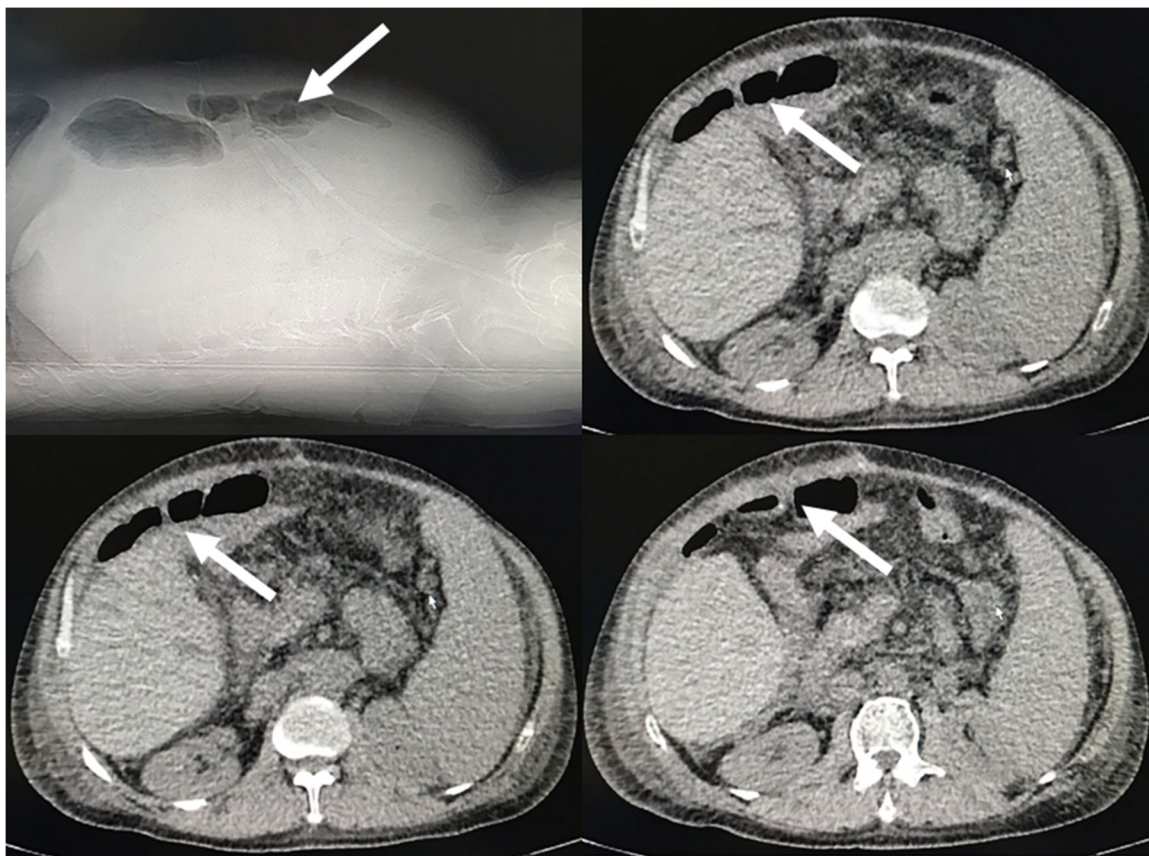


Fig. 2. Preoperative non-contrast abdominal computed tomography showing fixed dilated small bowel loop (arrow).

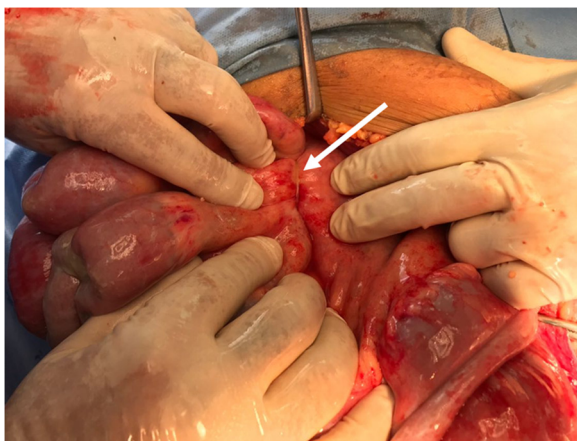


Fig. 3. Operative photo showing herniated small bowel loops through the biliary catheter (arrow) obstructing the bowel mesentery with no signs of strangulation.

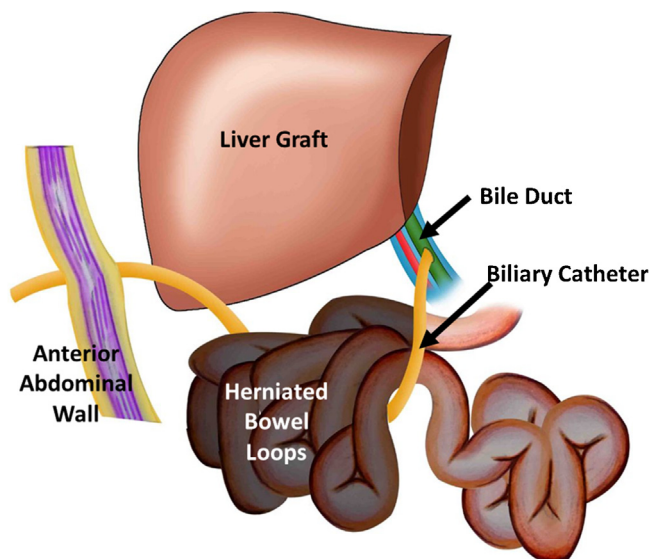


Fig. 4. Diagram illustrating internal hernia of the small bowel loops around trans-anastomotic biliary catheter obstructing its mesentery.

Plain abdominal radiograph was ordered and showed gas shadow inside the stomach and dilated small bowel loop at the right hypochondrial region (Fig. 1). Non-contrast abdominal CT confirmed the presence of the dilated jejunal loop with no definite obstructing cause (Fig. 2). Doppler US was done and confirmed patency of all vascular anastomoses. The decision was to proceed for surgical exploration.

Emergency abdominal exploration was done on the 25th postoperative day. Exploration revealed internal herniation of the small bowel loops around the trans-anastomotic biliary catheter without strangulation (Figs. 3 and 4). The herniated bowel loops were markedly congested from obstruction of the small bowel mesen-

teric vessels. Reduction of the internal hernia was done by releasing the fixation of the biliary catheter from the anterior abdominal wall. The color of the small bowel returned normal indicating its viability, and small bowel resection was not required. No biliary leakage was detected around site of exit of the catheter from the bile duct and check cholangiogram confirmed absence of biliary leakage.

The patient had smooth postoperative course. Intestinal sounds were regained on the second postoperative day and allowed oral

fluids. Follow up abdominal radiographs and Doppler US were sound. The patient was discharged 10 days after surgery.

3. Discussion

Intestinal obstruction after LDLT is serious rare complication. Generally, the incidence of intestinal obstruction after different abdominal operations is about 3–5% in previous reports. The development of post-operative intra-abdominal adhesions is the most common reported cause [11,12]. On the other hand, intestinal obstruction after LDLT is a rarely reported post-operative complication, and the incidence increases in pediatric more than adult patients. [12]

Different causes are reported for intestinal obstruction after LDLT. Liu et al. and Sakamoto et al. reported intestinal obstruction due to incarcerated Petersen's hernia following hepaticojejunostomy Roux-en-Y for biliary reconstruction [13,14]. Okajima et al. reported intestinal obstruction due to diaphragmatic hernia after LDLT [15]. Mukai et al. reported the development of intestinal obstruction after LDLT due to unconjugated ursodeoxycholic acid enterolith [16]. In our case, intestinal obstruction early after LDLT was due to internal herniation of the small bowel around trans-anastomotic biliary catheter.

The routine uses of trans-anastomotic biliary catheters in duct-to-duct biliary reconstruction in LDLT had been a controversial issue. Many studies did not prove a real advantage of its routine use [6–8]. In our center, we routinely use trans-anastomotic biliary catheters that exit through a separate choledochotomy in the common bile duct during duct-to-duct biliary anastomosis [9]. The catheter is passed through the abdominal wall to be fixed to the skin. We maintain the shortest segment of the trans-anastomotic biliary catheter inside the abdomen to avoid such internal herniations. In this case, we think that the presence of early postoperative ascites allowed small bowel loops to move upwards to the supra-colic compartment and become herniated around the catheter.

In absence of the definite signs of intestinal obstruction, the diagnosis of internal hernia of the small bowel is a difficult clinical situation. Symptoms like vague abdominal pain or discomfort are non-specific and are usually attributed to other causes especially in early post-operative period [17]. In our case, the patient presented with severe agonizing abdominal pain in absence of significant clinical findings on examination. The suspicion of ischemic pain or a closed loop syndrome was our first differential diagnosis. The suspicion was confirmed with abdominal radiographs.

In conclusion, small bowel obstruction due to internal hernia of the small bowel around trans-anastomotic biliary catheter is an unusual life-threatening complication after LDLT. Awareness regarding such complication plus early surgical intervention can prevent severe postoperative morbidity and mortality. Also, it should be considered as an important cause in the differential diagnosis of intestinal obstruction in liver transplant recipients.

Conflicts of interest

All authors declared that there are no conflicts of interest. This work has been reported in line with the scare criteria.

Sources of funding

No external funding resources.

Ethical approval

This case report was accepted by the local ethical committee.

Consent

We obtained a written informed consent from the patient for the publication of this case report and accompanying images. A copy of this written consent is available for review by the editor-in-chief of the international journal of surgery case reports on request.

Author contribution

Conception and design of the study: Shehta A, Wahab MA.

Collection and assembly of the data: Shehta A.

Data analysis and interpretation: Shehta A, Wahab MA.

Drafting the manuscript: All authors.

Critical revision of the manuscript for important intellectual content: All authors.

Final approval of the manuscript: All authors.

Study supervision: Wahab MA.

Registration of research studies

NA

Guarantor

Mohamed Abdel Wahab.

Ahmed Shehta.

Acknowledgments

None

References

- [1] K.M. Olthoff, R.M. Merion, R.M. Ghobrial, for A2ALL Study Group, et al., Outcomes of 385 adult-to-adult living donor liver transplant recipients: a report from the A2ALL consortium, *Ann. Surg.* 242 (2005) 314–323.
- [2] E.A. Pomfret, J.P. Fryer, C.S. Sima, et al., Liver and intestine transplantation in the United States, 1996–2005, *Am. J. Transplant.* 7 (s1) (2007) 1376–1389.
- [3] M.A. Wahab, A. Shehta, M. Elshoubary, et al., Living donor liver transplantation in hepatitis C virus era: a report of 500 consecutive cases in a single center, *Transplant. Proc.* (March) (2018).
- [4] N. Akamatsu, Y. Sugawara, D. Hashimoto, Biliary reconstruction, its complications and management of biliary complications after adult liver transplantation: a systematic review of the incidence, risk factors and outcome, *Transpl. Int.* 24 (2011) 379–392.
- [5] S. Sharma, A. Gurakar, N. Jabbour, Biliary strictures following liver transplantation: past, present and preventive strategies, *Liver Transpl.* 14 (2008) 759–769.
- [6] K.S. Kumar, J.S. Mathew, D. Balakrishnan, et al., Intraductal transanastomotic stenting in duct-to-duct biliary reconstruction after living-donor liver transplantation: a randomized trial, *J. Am. Coll. Surg.* 225 (December (6)) (2017) 747–754.
- [7] O. Scatton, B. Meunier, D. Cherqui, et al., Randomized trial of choledochocholedochostomy with or without a T tube in orthotopic liver transplantation, *Ann. Surg.* 233 (2001) 432–437.
- [8] S. Weiss, S.-C. Schmidt, F. Ulrich, et al., Biliary reconstruction using a side-to-side choledochocholedochostomy with or without T-tube in deceased donor liver transplantation: a prospective randomized trial, *Ann. Surg.* 250 (2009) 766–771.
- [9] T. Salah, A.M. Sultan, O.M. Fathy, et al., Outcome of right hepatectomy for living liver donors: a single Egyptian center experience, *J. Gastrointest. Surg.* 16 (June (6)) (2012) 1181–1188.
- [10] R.A. Agha, A.J. Fowler, A. Saeta, et al., The SCARE statement: consensus-based surgical case report guidelines, *Int. J. Surg.* 1 (October (34)) (2016) 180–186.
- [11] J.J. Duron, N.J. Silva, S.T. du Montcel, et al., Adhesive postoperative small bowel obstruction: incidence and risk factors of recurrence after surgical treatment: a multicenter prospective study, *Ann. Surg.* 244 (2006) 750–757.
- [12] T.M. Earl, J.R. Wellen, C.D. Anderson, et al., Small bowel obstruction after pediatric liver transplantation: the unusual is the usual, *J. Am. Coll. Surg.* 212 (1) (2011) 62–67.
- [13] C.L. Liu, C.M. Lo, S.C. Chan, et al., Internal hernia of the small bowel after right-lobe live donor liver transplantation, *Clin. Transplant.* 18 (2) (2004) 211–213.
- [14] S. Sakamoto, R. Goto, N. Kawamura, et al., Petersen's hernia after living donor liver transplantation, *Surg. Case Rep.* 3 (1) (2017) 89.

- [15] H. Okajima, S. Hayashida, H. Iwasaki, et al., Bowel obstruction due to diaphragmatic hernia in an elder child after pediatric liver transplantation, *Pediatr. Transplant.* 11 (3) (2007) 324–326.
- [16] S. Mukai, T. Onoe, H. Tashiro, et al., Small bowel obstruction due to an unconjugated ursodeoxycholic acid enterolith following living donor liver transplantation: report of a case, *Hepatol. Res.* 45 (7) (2015) 818–822.
- [17] S. Nishida, A.G. Pinna, J.R. Nery, et al., Internal hernia of the small bowel around infrarenal arterial conduits after liver transplantation, *Clin. Transplant.* 16 (5) (2002) 334–338.

Open Access

This article is published Open Access at [sciencedirect.com](https://www.sciencedirect.com). It is distributed under the [IJSCR Supplemental terms and conditions](#), which permits unrestricted non commercial use, distribution, and reproduction in any medium, provided the original authors and source are credited.