



Case Study

Non-surgical reduction of lumbar hyperlordosis, forward sagittal balance and sacral tilt to relieve low back pain by Chiropractic BioPhysics® methods: a case report

PAUL A. OAKLEY, DC, MSc^{1)*}, NIOUSHA NAVID EHSANI, MD¹⁾, DEED E. HARRISON, DC²⁾

¹⁾ Private Practice: Newmarket, ON, L3Y 8Y8, Canada

²⁾ CBP NonProfit, Inc., USA

Abstract. [Purpose] To present the reduction of both lumbar spine hyperlordosis and anterior sagittal balance in a symptomatic patient as treated by Chiropractic BioPhysics® technique. [Participant and Methods] A 46 year old reported with low back and hip pains for six years. Oswestry disability index scored 28%. Radiographic assessment revealed pronounced anterior sagittal balance with lumbar hyperlordosis. The patient was treated by Chiropractic BioPhysics technique to reverse the spinal deformity subluxation via mirror image corrective exercises and spinal traction, as well as spinal manipulative therapy. [Results] Assessments after 36 and 74 treatments corresponding to the 4-month and 13-month check-ups demonstrated a continuous structural improvement in lumbar spine bio-mechanical parameters. There was a near complete resolution in low back and hip pains with an Oswestry score of 4%. [Conclusion] This case documents the reduction of lumbar spine hyperlordosis and forward sagittal balance by contemporary spine rehabilitation methods. It is essential to screen spinal subluxation patterns via standing radiography which obviously, as demonstrated in this case determines treatment approach as most low back pain patients present with lumbar hypolordosis. Routine initial and repeat radiography is safe in the screening and monitoring of treatment efficacy and is the standard for evidence-based, patient-centred structural rehabilitation.

Key words: Lumbar hyperlordosis, Low back pain, Anterior sagittal balance

(This article was submitted Jun. 13, 2019, and was accepted Jul. 27, 2019)

INTRODUCTION

Low back pain (LBP) is an important source of disability in the modern world¹⁾. Although there are many non-surgical treatments for low back disorders²⁾, few have evidence of successfully improving the proper biomechanical alignment after treatment³⁻⁶⁾. Chiropractic BioPhysics® (CBP®) technique has evolved into one of the most evidence base techniques aimed at restoring the normal biomechanical alignment to the human spine via mirror image® therapeutic approaches that features corrective spinal traction, exercises, and spinal adjustments⁷⁻⁹⁾.

Lumbar spine hyperlordosis is associated with LBP and facet arthrosis¹⁰⁾. Biomechanically it is also associated with a forward postural sagittal balance and increased pelvic tilt (sacral base angle)¹¹⁾. In asymptomatic and normally postured subjects, this postural subluxation pattern can easily be reproduced by anteriorly translating the thoracic cage over the pelvis. Despite teachings within the CBP technique system on correcting this type of subluxation pattern¹²⁾, there is a paucity of data on treating patients with lumbar spine hyperlordosis.

We present a case showing the reduction of lumbar spine hyperlordosis and the reduction of forward sagittal balance coinciding with the alleviation of chronic low back and hip pains by CBP treatment methods.

*Corresponding author. Paul A. Oakley (E-mail: docoakley.icc@gmail.com)

©2019 The Society of Physical Therapy Science. Published by IPEC Inc.



This is an open-access article distributed under the terms of the Creative Commons Attribution Non-Commercial No Derivatives (by-nc-nd) License. (CC-BY-NC-ND 4.0: <https://creativecommons.org/licenses/by-nc-nd/4.0/>)

PARTICIPANT AND METHODS

On March 9, 2018 a 47-year-old female presented with a primary complaint of LBP and hip pains that have been constant for the last 5–6 years which corresponded with the patient's first pregnancy. The patient described the pain as an ache as well as a tightness and described it feeling 'locked.' Prolonged sitting aggravated the back and also caused a numbness and tingling into the legs and feet. The pain felt better if she hung herself at hip height. The LBP was rated a 3/10 (0=no pain; 10=worst pain ever) at the time of the exam, and would go up to a 6/10 at worst.

Physical assessment showed restricted lumbar range of motion (ROM) in extension and bilateral bending, with discomfort in the back with extension and tightness in bilateral rotation. Bilaterally, the paraspinal musculature felt tight upon manual palpation. All lumbosacral orthopedic tests were negative including the straight leg raiser. The patient scored a 28% on the revised Oswestry chronic low back pain disability questionnaire (ODI)¹³.

A radiographic assessment was performed and the biomechanical alignment was assessed by using the PostureRay software (Trinity, FL, USA). This system uses the Harrison posterior tangent method (lines drawn on the posterior vertebral body margins) to measure the lateral lumbar intersegmental angles and global lordosis. This method is reliable with a low standard error of measurement^{14, 15}. The patient was diagnosed with lumbar spine hyperlordosis having an L1–L5 absolute rotation angle (ARA) of -54.9° (vs. -40° normal^{16, 17}), an increased sacral tilt (sacral base angle) of 52.9° (vs. 40° normal¹⁷), and an anteriorly translated thoracic posture (anterior sagittal balance) as measured by the horizontal distance from the posterior inferior body corner of T12 to a vertical line drawn from the posterior inferior S1 body corner of 25 mm (vs. 0 mm normal¹⁸) (Fig. 1).

The patient was treated using CBP methods^{12, 19, 20} aimed at reversing the spinal subluxation. As discussed, since anteriorly translating the thorax will create the deformity diagnosed on the radiograph, spinal traction was in the opposite manner (Fig. 2). Posterior thoracic translation traction was performed with the patient laying supine, the lower thoracic cage was strapped down to a bench and the pelvis was lifted from underneath. A strap was placed on the anterior superior ischial spine in order to also rotate the pelvis posteriorly. Traction was performed for 10-minutes each treatment session.

Mirror image posterior thoracic translation exercises were also performed, 50 repetitions per session that were held for 3 seconds (Fig. 3). The patient stood with their back to a wall and placed a firm block half way down their buttocks, the patient would lean their upper back against the wall and then attempt to 'pull' their lumbar spine to the wall. By doing these exercises, the spine would be exercised into a flexion position, and the pelvis was also rotated posteriorly. The patient also received lumbar spinal manipulation each session. The patient consented to the publication of these results.

RESULTS

A re-assessment was performed after the patient received 35 treatments over 4 months. The patient reported marked improvement in LBP and hip pain, in fact she stated the pains were 'virtually gone.' Her low back was a 0–1/10 and would only rise to a 2/10 at worst in the last month, and she scored a 12% on the ODI. Lumbar ROM was normal with no reported pain or discomforts. A follow-up lateral lumbar radiograph showed a 5° reduction in lumbar lordosis (-50.0° vs. 54.9°), a 10 mm reduction in forward sagittal balance (15.3 mm vs. 25.0mm), and a 6° reduction in sacral tilt (47.3° vs. 52.9°). The patient elected to continue treatment in the attempt to achieve further structural correction to the lumbar sagittal alignment.

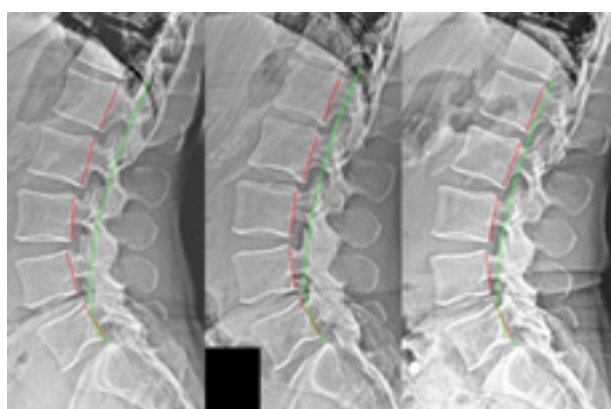


Fig. 1. Lateral lumbar views. Left: Initial image showing pronounced forward sagittal balance and lumbar hyperlordosis; Middle: Follow-up after 36 treatments; Right: Follow-up after 73 treatments. Red line is patient, green line is ideal alignment.



Fig. 2. Traction set-up. Patient lays supine with the lower ribs held down to the bench with a strap. The pelvis is elevated by a couple straps underneath lower buttocks, and the pelvis is allowed to rock backwards with the strap placed on the anterior superior ischial spine of the pelvis. Traction was performed for 10 minutes.

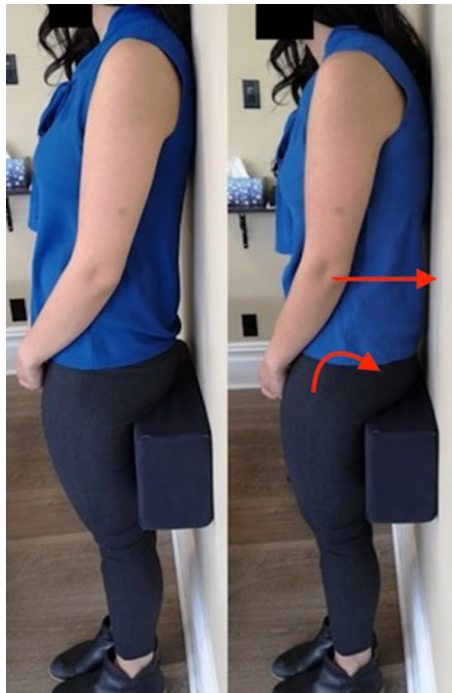

Fig. 3. Mirror image exercise. Left: The patient stands with a block trapped midway down buttocks to the wall. The patient is leaning backwards so the shoulders are touching the wall. Right: The exercise is performed when the patient attempts to pull the lumbar spine to the wall; this creates a posterior pelvic tilt and a posterior thoracic translation position. Exercises were performed for 50 repetitions and held for three seconds.

A second follow-up assessment 9 months after the last exam (13 months overall) and after 38 further treatments (73 treatments overall) demonstrated that she continued to get well. She reported her LBP and hip pains rarely bothered her; only on occasions where she would ‘over do it,’ and even then it would only be a minor ache for a short time period. She rated her pains a 0/10 on average and a 1–2/10 at worst and scored a 4% on the ODI. All other tests were unremarkable. The second follow-up lateral lumbar radiograph showed continued biomechanical improvements from the initial subluxation pattern. Overall, (since the initial assessment) the lumbar spine hyperlordosis reduced 8° (-47.1° vs. -54.9°), the forward sagittal balance reduced 17.4 mm (7.6 mm vs. 25.0mm), and the sacral tilt reduced 5° (48.1° vs. 52.9°).

DISCUSSION

This case documents the significant improvement in lumbar sagittal alignment in a patient presenting with anterior sagittal balance, lumbar hyperlordosis, and increased sacral tilt. The improvement in subluxated posture resulted in dramatic reduction of pain and an increase in functional ability after 73 treatments over a 13-month time period.

Although there is much evidence on CBP methods employed to increase lumbar lordosis in patients suffering from LBP with hypolordosis (2 RCTs^{4–6}), 1 nRCT³), 2 case series^{21, 22}), 6 case reports^{23–28}), there are no pubmed CBP cases showing the reduction of lordosis in patients suffering with LBP with hyperlordosis. Thus, this case is unique as it shows the correction of a spine deformity not previously documented by CBP non-surgical methods. Further research is necessary to verify if this approach is as consistent as the methods have been shown to be for increasing the lumbar lordosis in patients presenting with loss of curve^{3–6, 21–28}).

Considering it has been observed that CBP case reports have mimicked results from RCTs in the improvement in lordosis in the cervical spine⁷) and lumbar spine⁸) when assessing the dose-response in terms of treatment number to degree of spine change, it is likely that the amount of lordosis reduction in the current case may show a similar dose-response to future studies on this subluxation type. This highlights the importance of improving spine alignment towards the ideal configuration; thus, re-assessment and further treatment would be dictated by the biomechanical alignment (improvement) seen on follow-up radiographs. The estimation of needed treatment based on initial spine deformity has been presented²⁰) and should be used as a rough guideline at the outset of CBP care as the actual results measured from repeat follow-up radiographs would dictate further treatment needs.

It is known that lumbar spine hypolordosis is causal for LBP and low back disorders^{29, 30}). The diagnosis, however, between LBP sufferers having ‘hypo’ versus ‘hyper’ lordosis is an essential step in attaining a proper biomechanical diagnosis

of the subluxation in order to provide spine-specific, customized treatment to obtain the best structural based outcome. This is true whether for surgical³¹⁾ or non-surgical structural treatments¹²⁾ in the attempt to correct lumbar spine curvature and biomechanical parameters. Thus, routine initial radiographic imaging is recommended and indeed essential in efforts to achieve the best evidence-based and patient-centered care in the modern treatment of spine deformity³²⁾.

A common consideration in the use of initial and repeated X-rays are the exposures to radiation. Although too large a topic to adequately address herein, it has been discussed elsewhere that X-ray exposures are very small and within inescapable background exposures, they are not cumulative as the body's adaptive repair systems quickly repair any damage done, and they can be 100–1,000 times less than the known carcinogenic threshold, and thus, are too low a dose to be considered harmful^{33–36)}. Thus, we agree with Bess et al. and the International Spine Study Group who state: “accurate assessment of adult spinal deformity requires a thorough radiographic evaluation³²⁾”.

Limitations to this case are that this is just a single case, and there is no long-term follow-up. Further research is necessary to verify the results of this approach for the reduction of lumbar spine hyperlordosis in those suffering from low back disorders.

Conflict of interest

Dr. Paul Oakley (PAO) is a paid consultant to CBP NonProfit, Inc.; Dr. Deed Harrison (DEH) teaches chiropractic rehabilitation methods and sells products to physicians for patient care as used in this manuscript.

REFERENCES

- 1) Buchbinder R, Blyth FM, March LM, et al.: Placing the global burden of low back pain in context. *Best Pract Res Clin Rheumatol*, 2013, 27: 575–589. [[Medline](#)] [[CrossRef](#)]
- 2) Bogduk N: Management of chronic low back pain. *Med J Aust*, 2004, 180: 79–83. [[Medline](#)]
- 3) Harrison DE, Cailliet R, Harrison DD, et al.: Changes in sagittal lumbar configuration with a new method of extension traction: nonrandomized clinical controlled trial. *Arch Phys Med Rehabil*, 2002, 83: 1585–1591. [[Medline](#)] [[CrossRef](#)]
- 4) Moustafa IM, Diab AA: Extension traction treatment for patients with discogenic lumbosacral radiculopathy: a randomized controlled trial. *Clin Rehabil*, 2013, 27: 51–62. [[Medline](#)] [[CrossRef](#)]
- 5) Diab AA, Moustafa IM: Lumbar lordosis rehabilitation for pain and lumbar segmental motion in chronic mechanical low back pain: a randomized trial. *J Manipulative Physiol Ther*, 2012, 35: 246–253. [[Medline](#)] [[CrossRef](#)]
- 6) Diab AA, Moustafa IM: The efficacy of lumbar extension traction for sagittal alignment in mechanical low back pain: a randomized trial. *J Back Musculoskeletal Rehabil*, 2013, 26: 213–220. [[Medline](#)] [[CrossRef](#)]
- 7) Harrison DE, Moustafa IM, Oakley PA: Systematic review of Chiropractic Biophysics® (CBP®) methods employed in the rehabilitation of cervical lordosis. Proceedings from the 14th International SOSORT meeting, San Francisco, CA, April 25–27, 2019. Poster 23, p 156.
- 8) Harrison DE, Moustafa IM, Oakley PA: Systematic review of Chiropractic Biophysics® (CBP®) methods employed in the rehabilitation of lumbar lordosis. Proceedings from the 14th International SOSORT meeting, San Francisco, CA, April 25–27, 2019. Poster 24, p 157.
- 9) CBP Nonprofit website. www.cbpprofit.com/research
- 10) Jentzsch T, Geiger J, König MA, et al.: Hyperlordosis is associated with facet joint pathology at the lower lumbar spine. *Clin Spine Surg*, 2017, 30: 129–135. [[Medline](#)] [[CrossRef](#)]
- 11) Harrison DE, Cailliet R, Harrison DD, et al.: How do anterior/posterior translations of the thoracic cage affect the sagittal lumbar spine, pelvic tilt, and thoracic kyphosis? *Eur Spine J*, 2002, 11: 287–293. [[Medline](#)] [[CrossRef](#)]
- 12) Harrison DE, Betz JW, Harrison DD, et al.: CBP structural rehabilitation of the lumbar spine. Harrison Chiropractic Biophysics Seminars, Inc., 2007.
- 13) Fairbank JC, Couper J, Davies JB, et al.: The Oswestry low back pain disability questionnaire. *Physiotherapy*, 1980, 66: 271–273. [[Medline](#)]
- 14) Harrison DE, Harrison DD, Cailliet R, et al.: Radiographic analysis of lumbar lordosis: centroid, Cobb, TRALL, and Harrison posterior tangent methods. *Spine*, 2001, 26: E235–E242. [[Medline](#)] [[CrossRef](#)]
- 15) Harrison DE, Holland B, Harrison DD, et al.: Further reliability analysis of the Harrison radiographic line-drawing methods: crossed ICCs for lateral posterior tangents and modified Risser-Ferguson method on AP views. *J Manipulative Physiol Ther*, 2002, 25: 93–98. [[Medline](#)] [[CrossRef](#)]
- 16) Harrison DD, Cailliet R, Janik TJ, et al.: Elliptical modeling of the sagittal lumbar lordosis and segmental rotation angles as a method to discriminate between normal and low back pain subjects. *J Spinal Disord*, 1998, 11: 430–439. [[Medline](#)] [[CrossRef](#)]
- 17) Janik TJ, Harrison DD, Cailliet R, et al.: Can the sagittal lumbar curvature be closely approximated by an ellipse? *J Orthop Res*, 1998, 16: 766–770. [[Medline](#)] [[CrossRef](#)]
- 18) Harrison DE, Colloca CJ, Harrison DD, et al.: Anterior thoracic posture increases thoracolumbar disc loading. *Eur Spine J*, 2005, 14: 234–242. [[Medline](#)] [[CrossRef](#)]
- 19) Harrison DD, Janik TJ, Harrison GR, et al.: Chiropractic biophysics technique: a linear algebra approach to posture in chiropractic. *J Manipulative Physiol Ther*, 1996, 19: 525–535. [[Medline](#)]
- 20) Oakley PA, Harrison DD, Harrison DE, et al.: Evidence-based protocol for structural rehabilitation of the spine and posture: review of clinical biomechanics of posture (CBP) publications. *J Can Chiropr Assoc*, 2005, 49: 270–296. [[Medline](#)]
- 21) Harrison DE, Oakley PA: Non-operative correction of flat back syndrome using lumbar extension traction: a CBP® case series of two. *J Phys Ther Sci*, 2018, 30: 1131–1137. [[Medline](#)] [[CrossRef](#)]
- 22) Brown JE, Jaeger JO, Polatis TA, et al.: Increasing the lumbar lordosis by seated 3-point bending traction: a case series utilizing Chiropractic BioPhysics technique. *Chiropr J Aust*, 2017, 45: 144–154.

- 23) Troyanovich SJ, Buettner M: A structural chiropractic approach to the management of diffuse idiopathic skeletal hyperostosis. *J Manipulative Physiol Ther*, 2003, 26: 202–206. [[Medline](#)] [[CrossRef](#)]
- 24) Paulk GP, Harrison DE: Management of a chronic lumbar disk herniation with chiropractic biophysics methods after failed chiropractic manipulative intervention. *J Manipulative Physiol Ther*, 2004, 27: 579. [[Medline](#)] [[CrossRef](#)]
- 25) Fedorchuk C, Mohammed H: Improvement in GERD following reduction of vertebral subluxations & improved sagittal alignment utilizing chiropractic biophysics protocol. *Ann Vertebr Subluxat Res*, 2014, 2014: 99–109.
- 26) Oakley PA, Harrison DE: Lumbar extension traction alleviates symptoms and facilitates healing of disc herniation/sequestration in 6-weeks, following failed treatment from three previous chiropractors: a CBP® case report with an 8 year follow-up. *J Phys Ther Sci*, 2017, 29: 2051–2057. [[Medline](#)] [[CrossRef](#)]
- 27) Betz JW, Oakley PA, Harrison DE: Relief of exertional dyspnea and spinal pains by increasing the thoracic kyphosis in straight back syndrome (thoracic hypokyphosis) using CBP® methods: a case report with long-term follow-up. *J Phys Ther Sci*, 2018, 30: 185–189. [[Medline](#)] [[CrossRef](#)]
- 28) Weiner MT, Oakley PA, Dennis AK, et al.: Increasing the cervical and lumbar lordosis is possible despite overt osteoarthritis and spinal stenosis using extension traction to relieve low back and leg pain in a 66-year-old surgical candidate: a CBP® case report. *J Phys Ther Sci*, 2018, 30: 1364–1369. [[Medline](#)] [[Cross-Ref](#)]
- 29) Chun SW, Lim CY, Kim K, et al.: The relationships between low back pain and lumbar lordosis: a systematic review and meta-analysis. *Spine J*, 2017, 17: 1180–1191. [[Medline](#)] [[CrossRef](#)]
- 30) Sadler SG, Spink MJ, Ho A, et al.: Restriction in lateral bending range of motion, lumbar lordosis, and hamstring flexibility predicts the development of low back pain: a systematic review of prospective cohort studies. *BMC Musculoskelet Disord*, 2017, 18: 179. [[Medline](#)] [[CrossRef](#)]
- 31) Winter RB, Lonstein JE: The surgical correction of thoracic and lumbar hyperlordosis deformities. *Iowa Orthop J*, 1998, 18: 91–100. [[Medline](#)]
- 32) Bess S, Protosaltis TS, Lafage V, et al. International Spine Study Group: Clinical and radiographic evaluation of adult spinal deformity. *Clin Spine Surg*, 2016, 29: 6–16. [[Medline](#)] [[CrossRef](#)]
- 33) Oakley PA, Harrison DE: Radiogenic cancer risks from chiropractic x-rays are zero: 10 reasons to take routine radiographs in clinical practice. *Annals of Vert Sublux Res*, 2018, March 10: 48–56.
- 34) Oakley PA, Harrison DE: Radiophobia: 7 reasons why radiography used in spine and posture rehabilitation should not be feared or avoided. *Dose Response*, 2018, 16: 1559325818781445. [[Medline](#)] [[CrossRef](#)]
- 35) Oakley PA, Cuttler JM, Harrison DE: X-ray imaging is essential for contemporary chiropractic and manual therapy spinal rehabilitation: radiography increases benefits and reduces risks. *Dose Response*, 2018, 16: 1559325818781437. [[Medline](#)]
- 36) Oakley PA, Ehsani NN, Harrison DE: The scoliosis quandary: are radiation exposures from repeated x-rays harmful? *Dose Response*, 2019, 17: 1559325819852810. [[Medline](#)] [[CrossRef](#)]