

Case Report

Fracture dislocation of the humerus with intrathoracic humeral head fragment – A case report and review of the literature

A. Frodl^{a,*}, H. Eberbach^a, Ö. Senbaklavaci^b, H. Schmal^{a,c}, M. Jaeger^a^a Department of Orthopedics and Traumatology, Freiburg University Hospital, Freiburg, Germany^b Department of Thoracic Surgery, Freiburg University Hospital, Freiburg, Germany^c University Hospital Odense, Dep. Of Orthopedic Surgery, Sdr. Boulevard 29, 5000 Odense C, Denmark

ARTICLE INFO

Keywords:

Humeral fracture
Reverse shoulder arthroplasty
Fracture dislocation
Intrathoracic humeral head fragment

ABSTRACT

We present a rare case of humeral fracture dislocation with intrathoracic humeral head fragment. A 74-year old female was transferred to a major trauma facility after falling on her arm while gardening. An intrathoracic humeral head fragment was diagnosed after initial imaging. In correspondence with the department of thoracic surgery, the decision was made to remove the intrathoracic fragment thoroscopically and succeed with a reverse total shoulder arthroplasty.

Background

Intrathoracic fracture dislocation of the humeral head is a very rare injury. Hematopneumothorax and fragment proximity to the lung and pulmonary vessels can cause life threatening conditions. It was first described by West in 1949, there are only 28 documented case-reports to this type of upper extremity lesion [1,2]. Most cases reported high-energy trauma of patients suffering from fall from height or following a motor vehicle accident [3]. The lack of predilection of age groups and due to the low number of reported cases, there is no guideline or standard for treatment [4]. The existing literature presents a variety of treatment options for this injury pattern. Even whether the intrathoracic humeral head has to be removed or not, is still on debate [5]. In the following case report the authors present the case of a 74 years old woman with a minor trauma resulting in intrathoracic fracture dislocation of the humeral head fragment and hereby discuss possible approaches in elderly patients.

Case report

A 74-year-old female diabetic patient with known asthma bronchiale was transported to a major regional trauma facility after falling on her right arm while gardening. Physical examination showed a hemodynamic stable patient with decreased breath sounds over the right chest. The Glasgow Coma Scale was 15. There was no laceration of the skin but had a clinical prominent emphysema over the right shoulder. At admission vascular and neurological examinations of the right arm were normal. Plain radiographs of the arm and chest showed a proximal humeral head fracture with absence of parts of the humeral head, rib fractures of costa 2 and 3 and a right sided hematopneumothorax. Given this diagnosis, a chest drainage was placed. Review of the x-Rays showed an intrathoracic displaced humeral head lying apical to the right lung (Fig. 1). The CT-scan evidenced no laceration or compression of pulmonary vessels (Fig. 4). Subsequently, the patient was taken to intermediate care unit for further monitoring. Three days after trauma and stabilization

* Corresponding author at: Hugstetterstrasse 55, 79106 Freiburg i.B., Germany.

E-mail address: Andreas.Frodl@uniklinik-freiburg.de (A. Frodl).

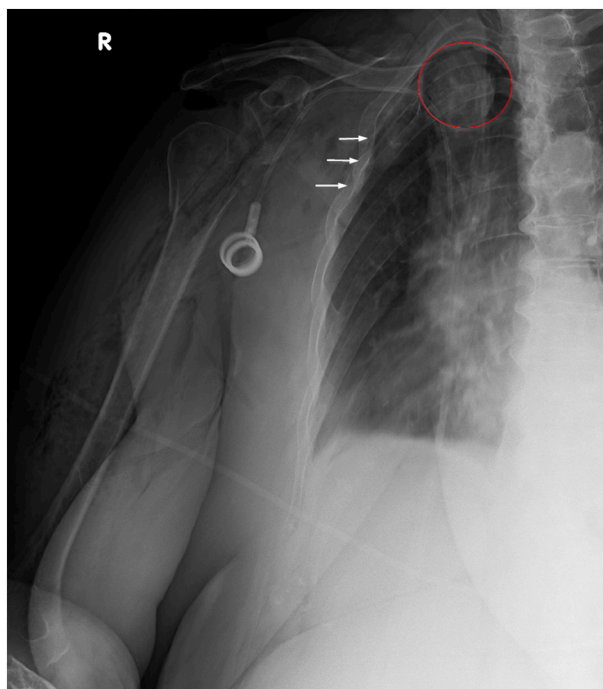


Fig. 1. X-ray of the shoulder (white arrows: rib fractures; red circle: humeral head fragment).

Table 1

Trauma mechanisms and concomitant injuries.

Author	High energy trauma	Ipsilateral rib fracture	Respiratory distress
Chen et al. 2015	Y (falling of a stage)	Y (2nd–5th rib)	Y
Tsai et al. 2014	Y (vehicle accident)	Y (2nd–5th rib)	Y
Salhiyyah et al. 2011	N (fall on outstretched arm)	N	Y
Maroney et al. 2009	Y (fall down flight of stairs)	NI	Y
Schoffl et al. 2009	N (falling down a bench)	Y (1st–5th rib)	Y
Daffner et al. 2008	Y (fall 6 ft of ladder)	NI	Y
Sola Junior et al. 2017	Y (vehicle accident)	Y (1st–6th rib)	Y
Simpson et al. 1998	Y (vehicle accident)	NI	NI
Hardcastle et al. 1981	Y (vehicle accident)	Y (2nd–3rd)	Y
Harman et al. 2004	Y (vehicle accident)	Y (multiple, not further stated)	Y

Legends: Y: yes, N: no; NI: no information [8,9].

of the patient, definitive fracture treatment and removal of the humeral head were initiated. The procedure was done interdisciplinary in collaboration with thoracic surgeons. For surgery, a double lumen tube was installed to deflate the right lung during fragment removal. Thoracoscopically the humeral head was seen on the apex of the lung. The fragment then was carefully taken out with a gripper (Fig. 5). The lung showed no sign of active bleeding or further laceration.

After thoracoscopic recovering of the humeral fragment, insertion of an additional thoracic drainage, full arthroplasty of the humerus via deltopectoral approach was performed using a cemented reverse shoulder prosthesis (Mathys Affinis Fracture invers, 6x125mm cemented shaft, 39 + 0 mm Metaphysis in 155°/10°) (Fig. 6). The right arm was then placed in a 15° abduction cushion with range of motion limited to passive abduction of 90° for six weeks. Postoperatively the patient was referred to intermediate care, where she was discharged 5 days after, but stayed hospitalized for 5 consecutive days. The Patient was seen 3 months postoperatively for routine follow up examination. She reported that initial swelling of the arm had decreased rapidly and vanished during the first week at home. Pain medication was just taken on demand and fully disposed with discharge. At 6 month postoperatively range of motion was reported as abduction/adduction 120°/0/40°, retro-/anteversion 120°/0/20°, internal/external rotation 60°/0/20. Due to the corona pandemic the patient wasn't able to continue with physiotherapy in the time between the examinations.

Table 2
Treatment modalities.

Author	Surgical intervention	Intervention type	Outcome 1 year postoperative ROM
Chen et al. 2015	Yes	Hemiarthroplasty	Ante/retroversion: 105-0-0 internal, external rotation: 40-0-35
Tsai et al. 2014	Yes	Hemiarthroplasty	No information
Salhiyyah et al. 2011	Yes	Hemiarthroplasty	Reduced shoulder mobility; no detailed information
Maroney et al. 2009	Yes	Total shoulder arthroplasty	Full ROM
Schoffl et al. 2009	Yes	Total shoulder arthroplasty	No information
Daffner et al. 2008	Yes	Hemiarthroplasty	No information
Sola Junior et al. 2017	Yes	Total shoulder Arthroplasty	No information
Simpson et al. 1998	Yes	ORIF	Limited active mobility, no further detailed information
Hardcastle et al. 1981	Yes	ORIF	Avascular Necrosis of humeral head Limited ROM with 30° abduction
Harman et al. 2004	Yes	Hemiarthroplasty	No information
Kaar et al. 1998	No	Cuff and collar sling	Painful arm movement, ROM limited to 40° abduction

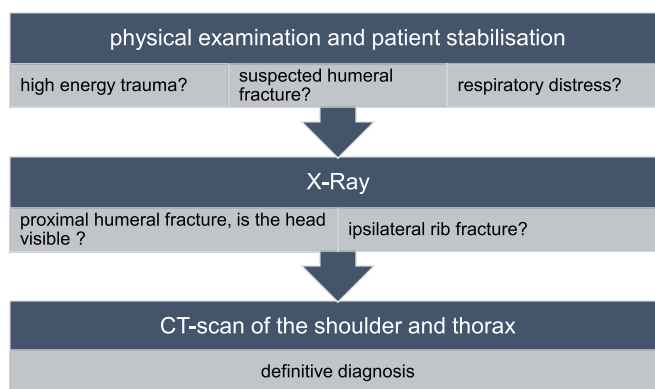


Fig. 2. Diagnostic flow-chart.

Discussion

Patients

The first documented and reported case of an intrathoracic humeral head fragment was published by West 1949. He presented a case of a 27-year-old man falling from an elevated stage [1]. In 1963 Patel et al. published an article of a 74-year-old woman with inability of movement of the arm after falling down a flight of stairs. Due to radiological examination the diagnosis of 2 part humeral fracture with displaced fragments in the left thoracic cavity was made [6]. Given those reports as example, a wide range concerning the patient age is witnessed. More recent cases reported by Simpson et al. (14 years) and Harman et al. (56 years) clarify this finding [4,7]. Review of literature confirms no age or gender predilection with this type of injury. Thus, different treatment modalities and approaches to fracture fixation and even concepts for removing the intrathoracic fragment exist (Table 2).

Diagnostics

Anterior fracture dislocation with intrathoracic head fragment is – as already mentioned earlier – an extremely rare injury. Without additional imaging of the ipsilateral hemithorax and thoughtful awareness, this entity is likely to be overseen. Review of literature points out some key findings during radiological and physical examination which should raise attention for intrathoracic fracture dislocation (see Table 1:). The first diagnostic step after physical examination and patient stabilization is conventional x-ray. If the x-ray depicts a combination of proximal humeral fracture with ipsilateral rib fracture and the humeral head is not clearly visible or even “missing”, a CT-scan of shoulder and thorax should be done. A flow chart for possible diagnostic routines is depicted in Fig. 2.

Treatment

In Al-Kaar et al. and Wiesler et al. case reports the patient underwent surgery [8,9]. In the acute phase a chest drainage was installed to resolve the hemato-pneumothorax. Operative treatment in both cases was first to remove the fragment in the thoracic cavity to prevent further parenchymal or vascular damage and second by hemiarthroplasty of the glenohumeral joint. Open reduction and internal fixation as done by Hardcastle et al. was also reported as a possible treatment option [10]. Intact circumflex vessels of the humerus are inevitable for this intervention type. If the vascular connection to the humeral head gets impaired, avascular necrosis of the humeral head is likely. In contrast, Patel et al., Kaar et al. as well as West preferred nonsurgical treatment [1,6,11]. Those cases

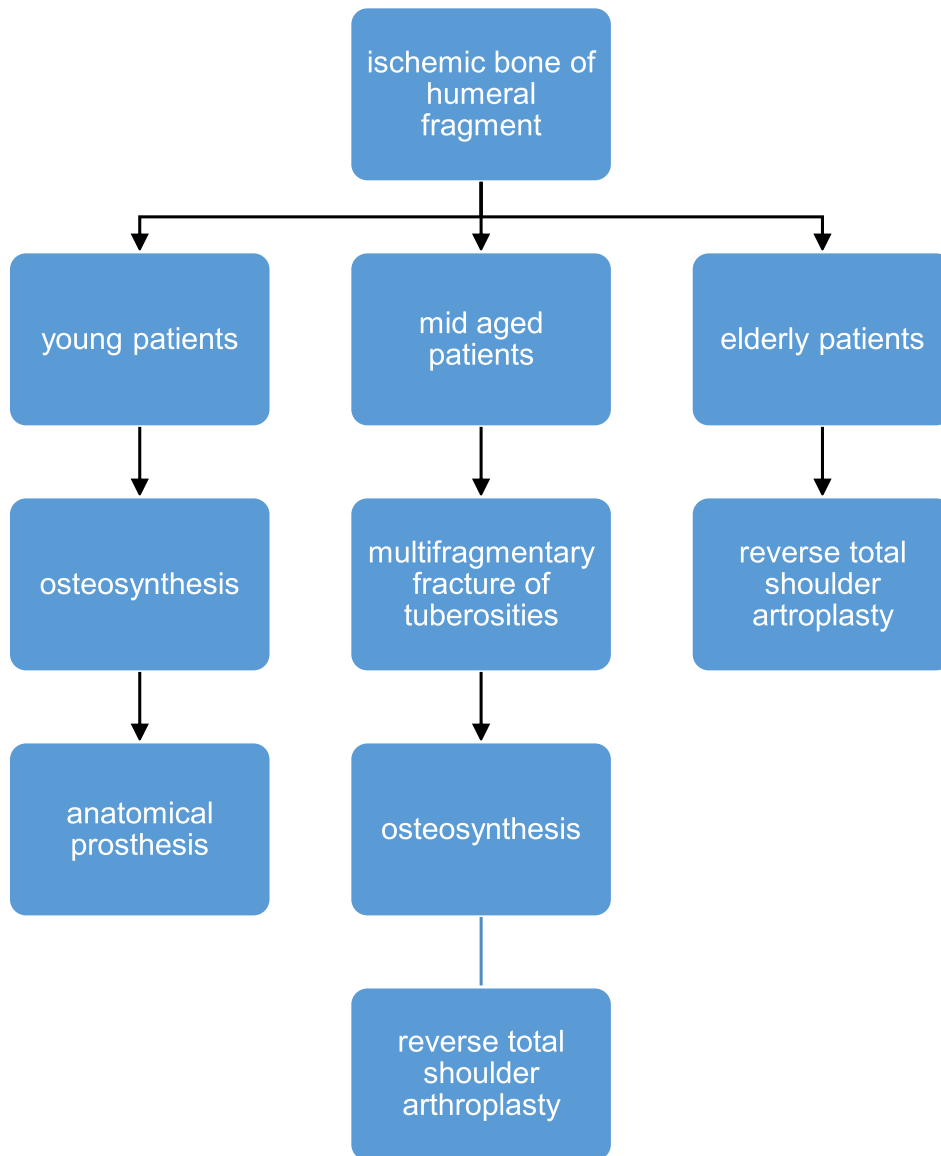


Fig. 3. Assistive flow chart for choosing procedure.

reported a trapped humeral head or neck between two costal ribs, which were treated with by manual reposition and immobilization.

Noteworthy, the procedure regarding the reconstruction of the humerus must be influenced by patient age and functional expectations of the patient. In cases of older patients arthroplasty done by implantation of anatomical or reverse prosthesis accounted for good outcomes [8,12]. In younger patients anatomical reconstruction should be the primary goal. For adequate shoulder functionality the healing and consolidation of the tuberosities are of high importance. In case of avascular necrosis, secondary conversion to an anatomical arthroplasty can be done. Avulsion fractures of the tuberosities into small fragments complicate osteosynthesis [13]. Hemiarthroplasty can be an appropriate alternative. But still, the chance of secondary dislocation of the tuberosities is high. With secondary dislocation functionality of the shoulder decreases and conversion into reverse total shoulder arthroplasty should be performed. In elderly, cases in which ORIF was done resulted in avascular necrosis of the humeral head as seen in Simpson et al. and Hardcastle [4,10]. The integrity of the circumflex humeral arteries is the key for bone regeneration and fracture healing. Due to fracture dislocation the vascular connection for the humeral head is torn apart and further nutrition required for the bone regeneration hindered. Thus, the authors recommend avoiding ORIF in elderly patients and in cases where vascular integrity is in doubt or the medial hinge is not preserved [14].

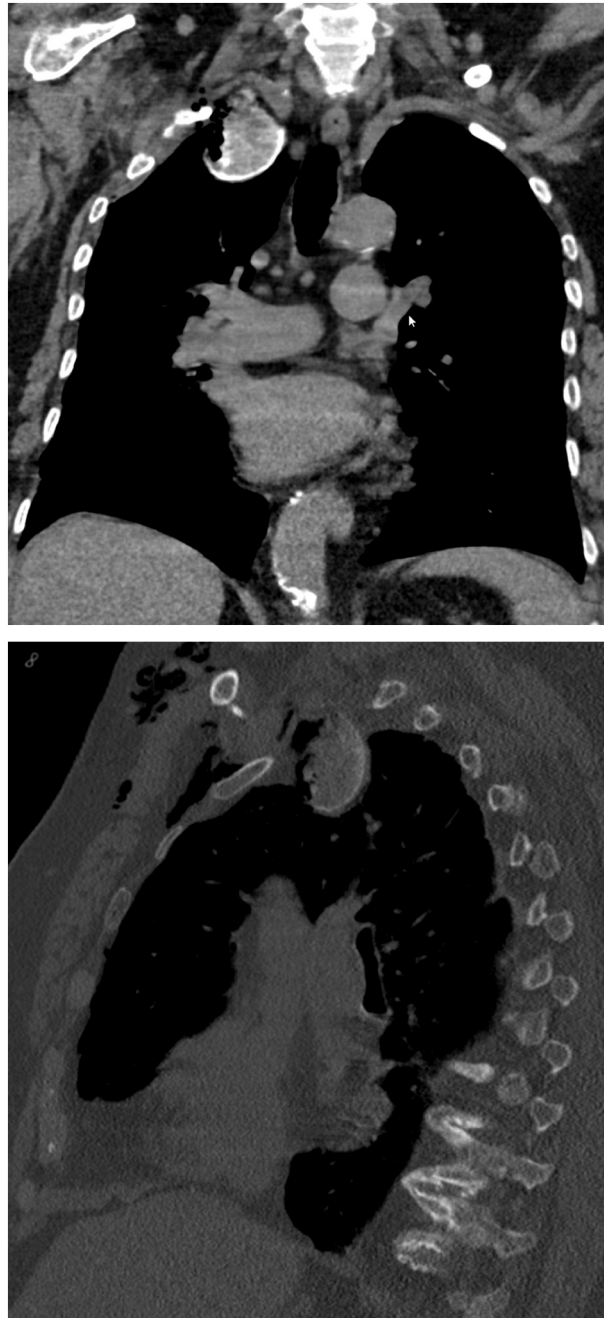

Fig. 4. CT-scan showing an intrathoracic humeral head fragment on the right apex.

Handling of the intrathoracic fragment

What to do with the intrathoracic fragment? High energy trauma is necessary to penetrate the humerus into the chest cavity. Following the mechanism how the humerus enters the thorax there are several structures at risk. First there is the brachial plexus where different entity of nerve palsy may arise depending on the location of fracture or severity of traction force [3,11,15]. Ribs, subcostal vessels, subcostal nerves and the intercostal muscles represent the first gatekeeper to the thorax. Thus, costal fracture with laceration of the underlying arteries or veins may occur, because of the humeral head pushing into the intercostal space. With concomitant laceration of the lung a hemothorax or hemothorax will be the consequence [16]. Once the humerus has entered the chest cavity, a humeral fragment, is in close proximity to vital anatomic structures and can cause life threatening or even lethal injuries. On the vascular side pulmonary vessels and the aorta could be at risk. On the other hand, the bronchi can be damaged as well. Hayes et al.

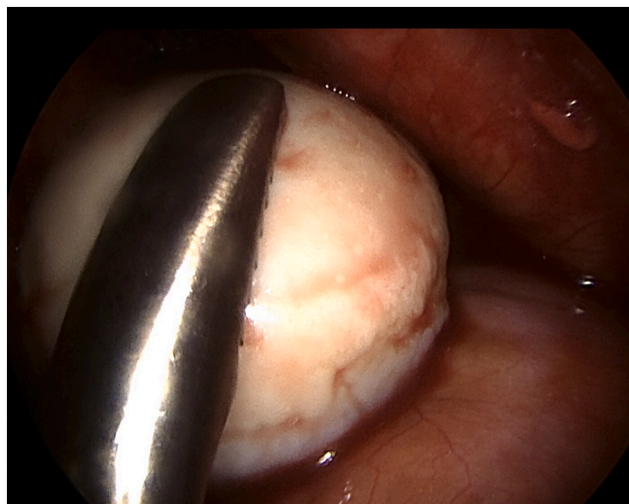

Fig. 5. Thoracoscopic removal of the humeral head with a gripper.

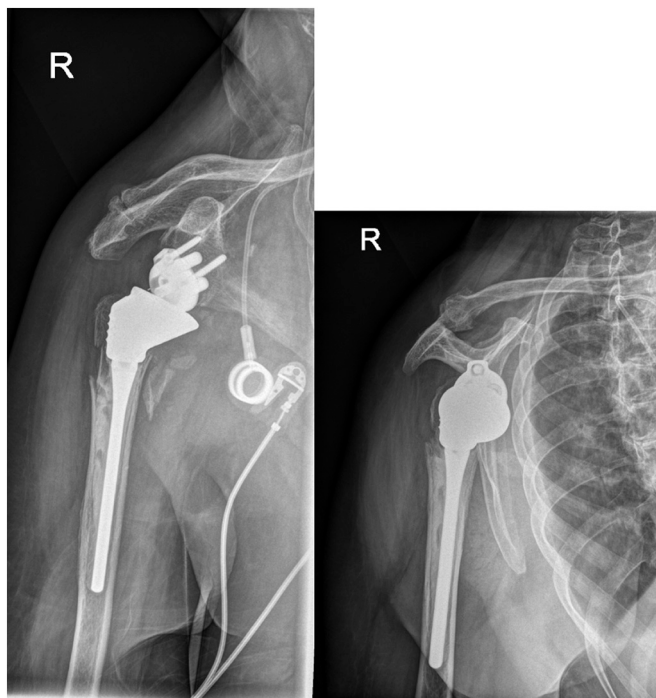


Fig. 6. X-ray after implantation of a reverse shoulder prosthesis.

reported the rupture of the ipsilateral main bronchus following fracture dislocation of an intrathoracic humerus, highlighting the potential threat of a humeral fragment within the chest cavity [17]. Some authors suggest not to remove the fragment if no intrathoracic complication is witnessed [5,18]. There are several options for removal, depending on the intrathoracic position of the fragment. With an apical fragment the direct way would be retroclavicular access to the apex of the lung. In proximity to the clavicle there is the subclavian vein and artery as well as the brachial plexus, making this a high risk procedure and thus should be avoided. Lateral or basal intrathoracic fragments can be reached by local thoracotomy or thoracoscopically. In favor of less invasiveness, a thoracoscopic approach should be chosen whenever possible.

Conclusion

Our case report demonstrates that these rare injuries can also occur in elderly patients after a common fall. Therefore, the treating

surgeon should be alert, especially when typical radiological signs are present. Given the information above, it is hard to conclude a standardized guideline how to address the entity of intrathoracic fracture dislocation of humeral head fractures. The authors recommend, especially when bone quality is diminished and the rotator cuff is torn, the implantation of a reverse shoulder prosthesis in elderly patients (see Fig. 3). Concerning the intrathoracic fragment the authors highly recommend removal to prevent potential life threatening complications. Nowadays, removal can be done by minimal invasive thoracoscopic surgery, minimizing operational risk and additional trauma.

Acknowledgments

The article processing charge was funded by the Baden-Wuerttemberg Ministry of Science, Research and Art and the University of Freiburg in the funding programme Open Access Publishing.

References

- [1] E.F. West, Intrathoracic dislocation of the humerus, *J Bone Joint Surg Br.* 31B (1) (1949 Feb) 61.
- [2] W.C. Sola Junior, P.S. dos Santos, Intrathoracic fracture-dislocation of the humerus – case report and literature review, *Rev. Bras. Ortop.* 52 (2) (2017 Feb 5) 215–219.
- [3] M.A. Wirth, K.L. Jensen, A. Agarwal, R.J. Curtis, C.A. Rockwood, Fracture-dislocation of the proximal part of the humerus with retroperitoneal displacement of the humeral head. A case report, *J. Bone Joint Surg. Am.* 79 (5) (1997 May) 763–766.
- [4] N.S. Simpson, J.R. Schwappach, E.B. Toby, Fracture-dislocation of the humerus with intrathoracic displacement of the humeral head. A case report, *J. Bone Joint Surg. Am.* 80 (6) (1998 Jun) 889–891.
- [5] N. Du Plessis, S. Rajendran, S.A. Naqi, R. Cahill, Intrathoracic fracture-dislocation of the humeral head. Is removal of the humeral head necessary? *BMJ Case Rep.* 2012 (2012 Dec 21).
- [6] M.R. Patel, M.L. Pardee, R.C. Singerman, Intrathoracic dislocation of the head of the humerus, *J. Bone Joint Surg. Am.* 45 (1963 Dec) 1712–1714.
- [7] B.D. Harman, N.G. Miller, R.A. Probe, Intrathoracic humeral head fracture-dislocation, *J. Orthop. Trauma* 18 (2) (2004 Feb) 112–115.
- [8] J. Garcia, H.G. Khan, C. Manueddu, M. al-Kaar, [Intrathoracic dislocation fracture of the head of the humerus], *J. Radiol.* 79 (1) (1998 Jan) 57–59.
- [9] E.R. Wiesler, A.M. Smith, J.S. Shilt, Humeral head fracture-dislocation into the thoracic outlet: case report and review of the literature, *J. Shoulder Elb. Surg.* 13 (5) (2004 Sep 1) 576–579.
- [10] P.H. Hardcastle, T.R. Fisher, Intrathoracic displacement of the humeral head with fracture of the surgical neck, *Injury* 12 (4) (1981 Jan 1) 313–315.
- [11] T.K. Kaar, J.J. Rice, G.B. Mullan, Fracture-dislocation of the shoulder with intrathoracic displacement of the humeral head, *Injury* 26 (9) (1995 Nov) 638–639.
- [12] C.P. Ebersson, T. Ng, A. Green, Contralateral intrathoracic displacement of the humeral head. A case report, *J. Bone Joint Surg. Am.* 82 (1) (2000 Jan) 105–108.
- [13] A. Klug, D. Wincheringer, J. Harth, K. Schmidt-Horlohé, R. Hoffmann, Y. Gramlich, Complications after surgical treatment of proximal humerus fractures in the elderly—an analysis of complication patterns and risk factors for reverse shoulder arthroplasty and angular-stable plating, *J. Shoulder Elb. Surg.* 28 (9) (2019 Sep) 1674–1684.
- [14] F. Gadea, L. Favard, P. Boileau, C. Cuny, T. d'Ollone, D. Saragaglia, et al., Fixation of 4-part fractures of the proximal humerus: can we identify radiological criteria that support locking plates or IM nailing? Comparative, retrospective study of 107 cases, *Orthop. Traumatol. Surg. Res.* 102 (8) (2016) 963–970.
- [15] C. Ulrich, G. Helbing, O. Wörsdörfer, L.H. Lampl, Intrathoracic dislocation of the head of the humerus, *Langenbecks Arch. Chir.* 367 (3) (1986) 197–202.
- [16] J. Chen, Intrathoracic dislocation of the humeral head accompanied by polytrauma: How to treat it? *Turk J Trauma Emerg Surg [Internet]* [cited 2020 Aug 26]; Available from: https://www.journalagent.com/travma/pdfs/UTD-72566-CASE_REPORTS-CHEN.pdf, 2015.
- [17] N. Hayes, J. White, P. Lillie, J.S. Bennetts, C.G. Tu, G.I. Bain, Intrathoracic shoulder dislocation causing rupture of the right main bronchus, *Arch. Orthop. Trauma Surg.* 140 (4) (2020 Apr) 443–447.
- [18] J.F. Abellan, E. Melendreras, D.J. Gimenez, F.J. Carrillo, L. Ruano, J. Rivkin, Intrathoracic fracture-dislocation of the humeral head: a case report, *J. Orthop. Surg. Hong Kong* 18 (2) (2010 Aug) 254–257.