

CLINICAL REVIEW

Retinal Findings of Hospitalized Neonates Recovered from COVID-19 Infection: A Prospective, Observational, Descriptive Study

Filiz Aktürk Acar , MD,¹ Mahmut Cenap Esenülkü, MD,² and Berna Hekimoğlu, MD¹

¹Division of Neonatology, Department of Pediatrics, Health Sciences University, Kanuni Training and Research Hospital, Trabzon 61000, Turkey

²Department of Ophthalmology, Health Sciences University, Kanuni Training and Research Hospital, Trabzon 61000, Turkey
Correspondence: Filiz Aktürk Acar, Division of Neonatology, Department of Pediatrics, Health Sciences University, Kanuni Training and Research Hospital, Trabzon 61000, Turkey. Tel: +90 462 230 23 00. E-mail <drakturk@hotmail.com>.

ABSTRACT

Purpose: Coronavirus disease 2019 (COVID-19) that is caused by severe acute respiratory syndrome coronavirus 2 can cause microvascular alterations that can lead to irreversible complications in multiple tissues and organs. Detrimental effects of COVID-19 on retinal structure have recently been reported in adult population. However, literature data about neonatal population is very scarce. Thus, we aimed to assess possible retinal changes of neonates recovered from COVID-19 infection in this prospective, observational, descriptive study.

Methods: The neonates recovered from COVID-19 infection were included to the study between 01 September 2020 and 30 April 2021. Their initial ophthalmological examination was made after a negative real-time reverse transcription-polymerase chain reaction obtained and all patients were re-examined 1 month later. All examinations were performed by same retina specialist using a binocular indirect ophthalmoscopy.

Results: A total of 15 neonates [9 (60%) male, 6 (40%) female, mean gestational age of 38.9 ± 0.9 weeks (ranging from 37 to 40 week)] were evaluated in the study. The mean age at the time of hospitalization was 17.5 ± 8.7 days (ranging from 2 to 29 days), and the mean duration of hospitalization was 12.5 ± 6.2 days (ranging from 4 to 27 days). Except for one patient with bilateral avascular area in Zone-III, no further retinal manifestation related to COVID-19 was found in the study.

Conclusion: COVID-19 infection can cause retinal damage in neonates. Therefore, these patients should be closely monitored for signs of ocular involvement.

KEYWORDS: COVID-19 infection, neonates, retinal findings

INTRODUCTION

The whole world has been struggling with the Corona Virus Disease 2019 (COVID-19) caused by severe acute respiratory syndrome coronavirus 2 (SARS-CoV-2) since March 2020 after the World Health Organization declared it as a ‘pandemic’ [1]. Although the most known effects of COVID-19 are related to the respiratory system because of life-threatening potency, it can also affect other organ systems such as the gastrointestinal, cardiovascular, neurological and even ocular systems [2–4].

COVID-19 infection was initially more common in adults and elderly, but juvenile and neonatal cases have increased during the last year [5]. Its clinical course is ranging from asymptomatic situation to severe life-threatening pulmonary disease in both adult and pediatric population. Fortunately, a lot of experience for the management of COVID-19 disease in both populations has been obtained during pandemic. However, the findings and clinical course of this disease are still non-specific and less understood in neonates [6]. Therefore, it has been proposed that neonates with COVID-19 infection should be closely followed for its permanent detrimental effects [6].

Viral infections, such as coronaviruses, can lead to permanent eye damage by external ocular or retinal complications through various mechanisms [7–9]. Unfortunately, it has recently been shown that SARS-CoV-2 can cause retinal damage in adult population [7–15]. However, what is known about possible ocular effects of SARS-CoV-2 in neonates is very limited [16]. Therefore, in this study, we aimed to evaluate the presence of retinal and retinal vascular changes in neonates recovered from COVID-19.

METHODS

Study population

This prospective, observational, and descriptive, single-center study was carried out in Health Sciences University Trabzon Kanuni Training and Research Hospital Tertiary Neonatal Intensive Care Unit (NICU). Neonates who were hospitalized because of the COVID-19 infection were included to the study between 01 September 2020 and 30 April 2021. The legal permission for the study was obtained from the Ministry of Health (no: 2021-03-02T11_02_19). Study protocol was approved by the

regional scientific research ethics committee (no: 2021/67). Parents of the neonates were informed by the researcher physicians and informed consent was obtained from all. The inclusion criteria were (i) gestational age of ≥ 37 weeks and appropriate for gestational age; (ii) being 0–30 days old; (iii) having a positive result on real-time reverse transcription-polymerase chain reaction (RT-PCR) of a nasopharyngeal swab specimen for SARS-CoV-2 nucleic acid; (iv) being symptomatic and hospitalized patients. The neonates with negative RT-PCR results, positive RT-PCR results but asymptomatic situation, asphyxia, congenital anomalies or congenital eye problems were excluded from the study.

There were 16 neonates who met all criteria. However, one neonate was excluded from the study because he did not have a control eye examination (Fig. 1). All neonates were managed with the guidelines of the Turkey Ministry of Health and the Turkish Neonatal Society [17, 18]. Demographic findings (gestational week, age, gender, etc.); medical history (antenatal, natal and postnatal risk factors, and perinatal course); contact history with COVID-19 patients (including family members, caregivers, medical staff or visitors); clinical and laboratory findings; treatment applied and their outcomes were recorded for all patients. The neonates were admitted from home. The mothers of neonates had no

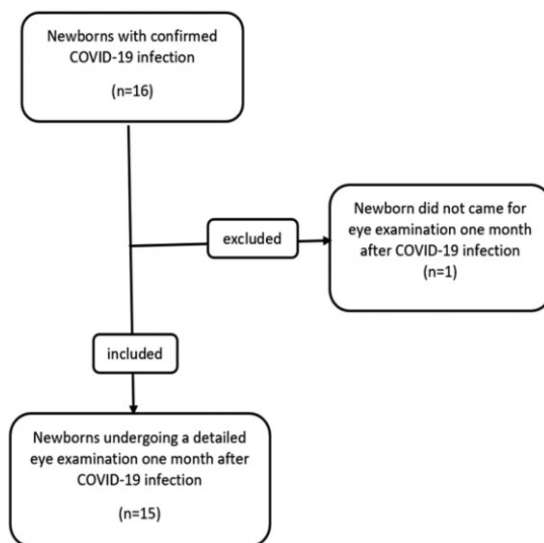


Fig. 1. Patients flow diagram.

comorbidities such as gestational diabetes, preeclampsia, hypertension, chorioamnionitis, early membrane rupture or a history of COVID-19 infection during pregnancy.

All study patients were screened for neonatal sepsis via biochemical parameters, blood cultures and chest radiographs. The vital signs and clinical symptoms were closely monitored in all of the patients. Supportive treatments such as fluid-electrolyte treatment; empirical antibiotic therapy until sepsis was ruled out; atypical pneumonia agents such as clarithromycin, azithromycin or oseltamivir; and supplemental oxygen treatment (oxygen hood, nasal continuous positive airway pressure) were administered according to the needs of the patients.

Eye examination

The first eye examinations of the neonates were performed during hospitalization after negative RT-PCR result obtained. Pharmacological dilation of the pupils was done by using tropicamide 10 mg/ml eye drop. Fundus examination of both eyes was performed by a retina specialist using binocular indirect ophthalmoscope and handheld condensing a 28-diopter lens after dilation of the pupils. The control ocular assessment was made one month later.

Statistical analysis

Statistical analyses were performed by IBM Statistical Package for the Social Sciences statistics software, version 24 (SPSS, IBM Corp, Armonk, NY, USA). Descriptive data were presented as the mean (\pm standard deviation), maximum and minimum values while categorical data are presented as a percentage.

RESULTS

Thirty eyes of 15 neonates post COVID-19 infection were evaluated. Of these, 9 (60%) were male, 6 (40%) were female. The mean gestational age was 38.9 ± 0.9 weeks (ranging from 37 to 40 weeks). The mean age at the time of hospitalization was 17.5 ± 8.7 days (ranging from 2 to 29 days) and the mean duration of hospitalization was 12.5 ± 6.2 days (ranging from 4 to 27 days). Four patients (26.7%) had bilateral conjunctivitis at hospitalization. Seven (46.7%) patients had pathological chest radiograph

findings, which were consolidation or infiltration. Only two (13.3%) patients required supplemental oxygen. Almost all of neonates had normal retinal and retinal vasculature findings, except one who had an avascular area in Zone-III in the fundus examination before discharge and after 1 month. The demographic characteristics and retinal findings of the neonates are shown in [Table 1](#).

DISCUSSION

This is the first prospective, observational and descriptive study that investigated retinal abnormalities associated with SARS-CoV-2 in neonates who recovered from COVID-19 infection. We found normal retinal and retinal vasculature findings in all neonates, except for one patient who had the bilaterally avascular area in Zone-III. He had no other risk factor that can account for his retinal finding such as prematurity, low birth weight, a requirement of supplemental oxygen, blood transfusion or intraventricular hemorrhage.

It is already known that coronaviruses cause retinal damage such as retinal vasculitis, retinal degeneration and optic neuritis in animal models [19]. However, SARS-CoV-2 is a novel type coronavirus and there is no previous data about its ocular effect. After the beginning of COVID-19 outbreak, the possible ocular effects of SARS-CoV-2 have been investigated in many studies. Almost all of these studies were performed on adult population and thus data about neonates is very rare.

Many structural ocular damages have been reported in adult population who have COVID-19 in different studies. The presence of retinal lesions including cotton wool spots (CWS), retinal microhemorrhages and hyper-reflective lesions have been reported in a small number of COVID-19 patients [20]. In a recently published case series of 108 COVID-19 patients in which microhemorrhages, retinal vascular tortuosity and CWS were detected in 25 eyes, even in asymptomatic patients with normal vital signs [21]. They have also suggested that these conditions were related to possible cardiovascular and thrombotic alterations caused by SARS-CoV-2 [21]. In addition, Caporossi *et al.* [8] examined 28 eyes of 15 adult patients with COVID-19 who were intubated for acute respiratory distress syndrome.

Table 1. The demographic characteristics and retinal findings of the neonates with COVID-19 infection

Patient no.	AH (days)	Sex	GW (wk)	BW (g)	Clinical symptoms	DH (days)	Radiological findings	Requirement for supplemental oxygen	Retinal findings	CGA (wk)
1	10	M	39	3530	Fever	10	+	None	None	46
2	20	F	40	3960	Fever, diarrhea, nasal discharge	9	+	None	None	49
3	5	M	38	3600	Diarrhea, nasal discharge	16	None	None	None	46
4	26	M	40	3910	Fever, cough	23	None	None	None	51
5	6	F	39	3350	Fever, cough, conjunctivitis	16	None	None	None	46
6	22	M	37	3200	Nasal discharge, tachypnea	27	+	Oxygen hood	None	48
7	13	M	39	3000	Fever, conjunctivitis	13	+	None	None	47
8	25	M	38	4060	Nasal discharge, feeding problems	14	None	None	None	48
9	18	F	40	2990	Nasal discharge, cough	14	None	None	None	49
10	25	F	39	3250	Fever, feeding problems, vomiting, diarrhea, conjunctivitis	10	None	None	Bilateral avascular area in Zone-III	48
11	25	M	39	3700	Nasal discharge, tachypnea, grunting	7	+	None	None	48
12	13	F	38	3100	Fever	10	+	None	None	46
13	29	F	39	3055	Fever, conjunctivitis	8	None	None	None	48
14	2	M	38	2900	Feeding problems	4	+	None	None	43
15	24	M	40	3700	Nasal discharge, cough, tachypnea, retractions	7	None	N-CPAP	None	49

AH, age at hospitalization; BW, birth weight; CGA, corrected gestational age at the time of retinal examination 1 month after COVID-19 infection; DH, duration of hospitalization; F, female; GW, gestational age; M, male; N-CPAP, nasal continuous positive airway pressure.

There were no vascular lesions in the macular region of any of the patients, but four of them had vascular lesions such as intraretinal microvascular abnormalities, arterial saccular dilatation, CWS and microhemorrhages in the retinal mid-periphery. They concluded that their findings could potentially be associated with microangiopathy that might be secondary to serious COVID-19 infections. In another study, retinal assessment showed microhemorrhages, flame-shaped hemorrhages and nerve fiber layer infarcts in five eyes of 25 hospitalized severely or critically ill COVID-19 patients, which were attributed to comorbidities, clinical interurrences or the robust immune response, rather than a direct effect of SARS-CoV-2 [22]. However, some authors suggested that these findings may not be specific for COVID-19 infection; they may reflect normal findings or incidental findings in chronic diseases [23]. Additionally, Invernizzi *et al.* [7] detected retinal hemorrhages, CWS, dilated veins and tortuous vessels in 31 of 54 severe and non-severe cases with COVID-19, and explained that these results could be related to COVID-19 or other conditions. They also reported that retinal vein diameter was positively correlated with disease severity and negatively correlated with time interval.

Until today, there is only one study on COVID-19-related ocular involvement in neonates in literature. Kiappe *et al.* [16] performed ocular examination by binocular indirect ophthalmoscopy in 165 neonates who were exposed to maternal COVID-19 infection during pregnancy in the first 18 days after birth. They found that ophthalmoscopy exam of six neonates who had positive SARS-CoV-2 PCR assay result was normal. However, 10 neonates (gestational age between 26 and 40 weeks) who had negative PCR had ocular abnormalities including retinal hemorrhages, retinopathy of prematurity, vascular tortuosity and venous engorgement. But, whether these findings were associated with maternal COVID-19 infection was not clear, because two neonates with retinopathy of prematurity had a history of premature birth at 26 and 29 gestational weeks, respectively [16]. Whereas, in our patient, there was no underlying reason explaining the avascular area in Zone-III other than COVID-19 infection.

On the other hand, it is well-known that angiotensin-converting enzyme 2 (ACE-2) receptor offering an attachment point to virus on the cell surface is an important role in the SARS-CoV-2 induced cell damage in lungs. Conjunctiva, retina and choroid cells also express ACE-2 receptor on their surface as well as many other organs [7, 14, 15]. Thus, we consider that ACE-2 receptor plays a critical role in the development of ocular damage during COVID-19. After entering ocular cells, tissue ischemia induced by microvascular dysfunction and endothelial cell damage can be proposed as a responsible mechanism of cellular damage [14, 15]. Because, according to some current optical coherence tomography angiography (OCTA) results, the retinal structures and microvasculature were affected in patients who had recovered from COVID-19 infection [11, 18, 19, 21–23]. Abrishami *et al.* [24] used OCTA analysis at least 2 weeks after recovery from COVID-19 patients, who had relatively mild course, with a majority of patients not requiring hospitalization, mean superficial (SCP) vessel density (VD) and deep retinal capillary plexus (DCP). VD was significantly reduced in the patients versus control group. They also found that the area of the foveal avascular zone (FAZ) was greater in the COVID group than in healthy controls, but this did not achieve statistical significance. Turker *et al.* [25] detected by OCTA research that hospitalized patients with a recent history of COVID-19 had significantly lower VD in the parafoveal SCP (nasal and superior quadrants) and DCP (all four quadrants) compared with controls, whereas in terms of FAZ similar results were found in both groups. In the present study, we detected a bilateral avascular area in Zone-III in one patient, although was by direct fundus examination one month after recovery from COVID-19.

Also, conjunctivitis related to COVID-19 infection was reported at a variable rate ranging from 0.8% to 3.6% [13]. In our study, conjunctivitis was present in 26.7% of our patients at hospitalization, including a neonate whose pathological retinal findings were detected one month later. Based on some reports, it has been proposed that patients infected with COVID-19 should closely follow-up for long-term because its ocular manifestations, especially

retinal damage, can emerge even in the middle or late stage of the disease [12, 26].

In conclusion, we thought that our results have a clinical importance. Because, reports of retinal findings such as microvascular abnormalities in patients with mild to severe COVID-19 highlight the importance of evaluating retinal involvement in all ages, especially in neonates, and indicate the need for long-term follow-up of retinal examination after COVID-19. Additionally, the presence of ocular symptoms at admission should be meticulously evaluated, as they reflect the necessity for a retinal examination during hospitalization and long-term follow-up. The pathological retinal finding in this study may have developed due to COVID-19 or perhaps a coincidental finding. If a fundus examination had been performed at the time of admission, we could have said that this finding may have developed due to COVID-19. An important limitation of our study was the absence of fundus findings in the acute phase. Further multi-centric studies on neonates with larger series and longer duration of follow-up are needed to determine the spectrum of retinal involvement caused by COVID-19.

REFERENCES

- World Health Organization. Emergency WHO Director General's Opening Remarks at the Media Briefing on COVID-19-11 March 2020. [https://www.who.int/director-general-speeches-detail-who-director-generals-opening-remarks-at-the-media-briefing-on-covid-19-\(11-march-2020\)](https://www.who.int/director-general-speeches-detail-who-director-generals-opening-remarks-at-the-media-briefing-on-covid-19-(11-march-2020)), date last accessed).
- Lai CC, Ko WC, Lee PI, *et al.* Extra-respiratory manifestations of COVID-19. *Int J Antimicrob Agents* 2020;56:106024.
- Loon SC, Teoh SC, Oon LL, *et al.* The severe acute respiratory syndrome coronavirus in tears. *Br J Ophthalmol* 2004;88:861–3.
- Yeo C, Kaushal S, Yeo D. Enteric involvement of coronaviruses: is faecal-oral transmission of SARS-CoV-2 possible? *Lancet Gastroenterol Hepatol* 2020;5:335–7.
- Cui X, Zhao Z, Zhang T, *et al.* A systematic review and meta-analysis of children with coronavirus disease 2019 (COVID-19). *J Med Virol* 2021;93:1057–69.
- Wang L, Shi Y, Xiao T, *et al.*; Working Committee on Perinatal and Neonatal Management for the Prevention and Control of the 2019 Novel Coronavirus Infection. Chinese expert consensus on the perinatal and neonatal management for the prevention and control of the 2019 novel coronavirus infection (first edition). *Ann Transl Med* 2020;8:47.
- Invernizzi A, Torre A, Parrulli S, *et al.* Retinal findings in patients with COVID-19: results from the SERPICO-19 study. *EClinicalMedicine* 2020;27:100550.
- Caporossi T, Bacherini D, Tartaro R, *et al.* Retinal findings in patients affected by COVID 19 intubated in an intensive care unit. *Acta Ophthalmol* 2020;12:30.
- Kurup SP, Khan S, Gill MK. Spectral domain optical coherence tomography in the evaluation and management of infectious retinitis. *Retina* 2014;34:2233–41.
- Seah I, Agrawal R. Can the coronavirus disease 2019 (COVID-19) affect the eyes? A review of coronaviruses and ocular implications in humans and animals. *Ocul Immunol Inflamm* 2020;28:391–5.
- Chen L, Liu M, Zhang Z, *et al.* Ocular manifestations of a hospitalised patient with confirmed 2019 novel coronavirus disease. *Br J Ophthalmol* 2020;104:748–51.
- Douglas KAA, Douglas VP, Moschos MM. Ocular manifestations of COVID-19 (SARS-CoV-2): a critical review of current literature. *In Vivo* 2020;34:1619–28.
- Bertoli F, Veritti D, Danese C, *et al.* Ocular findings in COVID-19 patients: a review of direct manifestations and indirect effects on the eye. *J Ophthalmol* 2020;2020:4827304.
- Sim SS, Cheung CMG. Does COVID-19 infection leave a mark on the retinal vasculature? *Can J Ophthalmol* 2021;56:4–5.
- Karamelas M, Dalamaga M, Karampela I. Does COVID-19 involve the retina? *Ophthalmol Ther* 2020;9:693.
- Kiappe OP, Santos da Cruz NF, Rosa PAC, *et al.* Ocular assessments of a series of newborns gestationally exposed to maternal COVID-19 infection. *JAMA Ophthalmol* 2021;139:e211088.
- Turkey Ministry of Health. Management of COVID-19 in Children. https://covid19bilgi.saglik.gov.tr/depo/rehberler/COVID-19_Rehberi.pdf (22 March 2020, date last accessed).
- Erdeve Ö, Çetinkaya M, Baş AY, *et al.* The Turkish Neonatal Society proposal for the management of COVID-19 in the neonatal intensive care unit. *Turk Arch of Pediatr* 2020;55:86–92.
- Wang Y, Detrick B, Yu ZX, *et al.* The role of apoptosis within the retina of coronavirus-infected mice. *Invest Ophthalmol Vis Sci* 2000;41:3011–8.
- Marinho PM, Marcos AAA, Romano AC, *et al.* Retinal findings in patients with COVID-19. *Lancet* 2020;395:1610.
- Sim R, Cheung G, Ting D, *et al.* Retinal microvascular signs in COVID-19. *Br J Ophthalmol* 2021. <https://doi.org/10.1136/bjophthalmol-2020-318236>.
- Lani-Louzada R, Ramos CDVF, Cordeiro RM, *et al.* Retinal changes in COVID-19 hospitalized cases. *PLoS One* 2020;15:e0243346.
- Vavvas DG, Sarraf D, Satta SR, *et al.* Concerns about the interpretation of OCT and fundus findings in COVID-19

- patients in recent Lancet publication. *Eye (Lond)* 2020; 34:2153–4.
24. Abrishami M, Emamverdian Z, Shoeibi N, *et al.* Optical coherence tomography angiography analysis of the retina in patients recovered from COVID-19: a case-control study. *Can J Ophthalmol* 2021;56:24–30.
 25. Turker IC, Dogan CU, Guven D, *et al.* Optical coherence tomography angiography findings in patients with COVID-19. *Can J Ophthalmol* 2021;56:83–7.
 26. Jin YP, Trope GE, El-Defrawy S, *et al.* Ophthalmology-focused publications and findings on COVID-19: a systematic review. *Eur J Ophthalmol* 2021;8:1120672121992949.