



Case Report

Role of neuropsychology in identification of CSWS in a school-aged child with a remote neurological insult

Emily J. Kalscheur^{a,b,*}, Raquel Farias-Moeller^{a,c}, Jennifer Koop^{a,b}^a Department of Neurology, Medical College of Wisconsin, United States^b Section of Pediatric Neuropsychology, Children's Wisconsin, United States^c Division of Pediatric Neurology, Children's Wisconsin, United States

ARTICLE INFO

Article history:

Received 31 August 2021

Revised 18 November 2021

Accepted 2 December 2021

Available online 8 December 2021

Keywords:

CSWS

ESES

Neuropsychological assessment

Pediatric epilepsy

Pediatric stroke

ABSTRACT

Electrical status epilepticus of slow-wave sleep (ESES) is characterized by excessive interictal spike-wave discharges on EEG during sleep and can occur in the absence of overt clinical seizures. Continuous spike-wave during slow wave sleep (CSWS), an epilepsy syndrome associated with ESES, is associated with a plateau/decline in cognitive development and increases in behavioral and emotional dysregulation. Here we present a case in which neuropsychological (NP) evaluation initially ordered based on memory and attention concerns led to the identification of subclinical seizure activity and an evolving epileptic encephalopathy in an 11-year-old child with a history of remote neurological insult. The patient was referred for an initial NP evaluation at age 8 which revealed weaknesses in functions typically mediated by the dominant (usually left) hemisphere juxtaposed with her left hemiparesis. EEG was recommended which showed independent, multifocal spike and sharp wave discharges exacerbated by sleep. Follow-up NP evaluations over the following 26 months, during which time aggressive treatment was initiated, coincided with EEG findings of an evolving epileptic encephalopathy in the patient who continued to remain free from clinical seizures. This case highlights the importance of comprehensive epilepsy care and routine involvement of neuropsychology in the management of complex epilepsy patients.

© 2021 The Author(s). Published by Elsevier Inc. This is an open access article under the CC BY-NC-ND license (<http://creativecommons.org/licenses/by-nc-nd/4.0/>).

Introduction

Neuropsychological evaluation has long played an important role in management of cognitive sequelae of epilepsy in adult and pediatric patients. Historically, neuropsychological evaluations were used to assist in the identification of the epileptogenic onset zone. As that role was replaced with more advanced electrographic and imaging techniques, neuropsychological evaluations remained an important component of the pre- and post-surgical epilepsy evaluation to assist in determining degree of risk for change and recovery from surgical intervention. Even outside of the surgical evaluation, neuropsychological assessment can be useful in determining the impact of seizures on cognitive functioning [1,2]. This is true for overt as well as subclinical seizure activity.

Continuous spike-wave during slow wave sleep (CSWS) is an epilepsy syndrome characterized by abundant, sleep-potentiated spike and wave discharges occurring during slow wave sleep causing potentially reversible neurodevelopmental disabilities such as

neurocognitive and behavioral deficits [3,4]. An electroencephalographic pattern called electrical status epilepticus of sleep (ESES) is necessary for the diagnosis of CSWS. In ESES there is significant sleep potentiation of spike-waves during non-rapid eye movement sleep [5]. There is debate regarding the criteria necessary to diagnose ESES, but most use a spike wave index (SWI, percent of 10 second bins in non-rapid eye movement sleep containing at least 1 spike) of at least 50–85% [4]. ESES can occur in the absence of any overt clinical seizures.

The etiology of ESES is varied and includes structural brain abnormalities, such as stroke, cortical malformations, hydrocephalus, or thalamic lesions, as well as genetic etiologies [6]. Treatment includes antiseizure medicines (ASM) such as benzodiazepines, corticosteroids, ketogenic diet and epilepsy surgery in those who meet certain criteria [7,8]. The hypothesis behind sleep potentiation of epileptic activity includes abnormal hyperactivation of the thalamic oscillatory circuit and abnormal interplay between inhibitory GABAergic reticular thalamic neurons and excitatory glutaminergic dorsal thalamic neurons. During sleep potentiation there is disruption of the cortical information processing triggering learning and memory impairments [8].

* Corresponding author at: Department of Neurology, Medical College of Wisconsin, 8701 Watertown Plank Rd., Milwaukee, WI 53226, United States.

E-mail address: ekalscheur@mcw.edu (E.J. Kalscheur).

The occurrence of ESES has been strongly linked to cognitive and behavioral changes in children [9,10]. More specifically, it has been documented that children with ESES often exhibit a plateau in cognitive development, if not a frank decline or regression in skills, following onset [11]. Additionally, many children exhibit significant increase in behavioral and emotional dysregulation while experiencing ESES [10,12]. Cognitive changes are thought to be related to disruption of the normal sleep cycle, which is necessary for learning, encoding and retaining novel information whereas behavioral changes have been attributed to the resulting sleep deprivation [13]. Often these functional changes, be they cognitive or behavioral, are identified prior to documentation of changes on EEG [12].

We present a case in which serial neuropsychological assessments assisted in the identification and management of CSWS.

Case presentation

The patient is an 11-year-old right-handed, English-speaking caucasian female with a history of neonatal cardiac arrest and resulting in bilateral cerebral watershed infarcts with a sequela of left spastic hemiplegic cerebral palsy (CP). She was the product of a full-term, uncomplicated pregnancy and weighed 8lbs, 14 oz at birth. At 3 weeks of life, she was identified as having supraventricular tachycardia and required cardiopulmonary resuscitation and extracorporeal membrane oxygenation (ECMO) due to cardiac arrest. Computed Tomography (CT) of the head immediately after the arrest, showed small extra-axial hemorrhage along the floor of the right middle cranial fossa, as well as decreased attenuation along the parietal occipital region, bilaterally, suggestive of watershed infarct. She was hospitalized for approximately three weeks, during which time she experienced seizure activity. She was treated with phenobarbital monotherapy until 18 months of age at which time the medication was successfully weaned. She experienced no subsequent overt clinical seizures. She received early interventional services beginning at 3 months of age. Early language and motor milestones were achieved within the expected time frames.

First Neuropsychological Evaluation (T1)

At age 8, she was referred for a neuropsychological evaluation by her Physical Medicine & Rehabilitation physician due to changes in short term memory and longstanding difficulties with inattention and executive dysfunction. She was in the 2nd grade at a public elementary school and received speech therapy and some special education academic support through an Individualized Education Program. Her grades were noted to be at or above grade level. Minimal emotional and behavioral concerns were reported. Results of the initial evaluation indicated average overall intellectual ability with intact basic language abilities, and inconsistent attention regulation, executive control and memory skills (visual stronger than verbal). Based on the results of the evaluation, including a clear weakness in verbal memory on formal testing, which could suggest dysfunction within the dominant (usually left) hemisphere, juxtaposed with her left hemiparesis, an updated neurological examination was recommended.

Neurological evaluation excluded newly acquired causes for the change in memory functioning reported by the patient's mother and corresponding memory difficulties noted on cognitive testing including poor sleep, obstructive sleep apnea, hypothyroidism. Differential diagnoses included sequelae of hypoxic ischemic brain injury during her event at age 3 weeks or localization-related epilepsy with subtle seizures. MRI of the brain and routine EEG were ordered. MRI of the brain (Fig. 1) indicated an

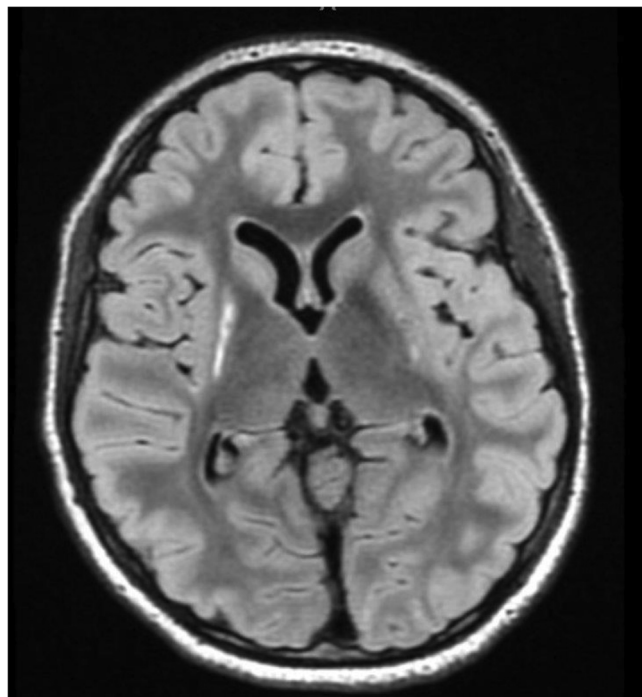


Fig. 1. Axial fluid-attenuated inversion recovery (FLAIR) MRI. Ill-defined long T2 hyperintensity and minimal volume loss in the lentiform nuclei, head of caudate nuclei (right more than left); and ill-defined long T2 hyperintensity in the subcortical white matter of right posterior insula and right periorlandic region indicative of remote ischemic brain injury.

ill-defined long T2 hyperintensity and minimal volume loss in the lentiform nuclei, head of caudate nuclei (right more than left); and an ill-defined long T2 hyperintensity in the subcortical white matter of right posterior insula and right periorlandic region indicative of remote ischemic brain injury. Short-term video EEG (Fig. 2) demonstrated high amplitude bi-synchronous frontally predominant spike-and-wave discharges with greater amplitude on the right hemisphere; and broad field generalized spike-and-wave discharges in sleep with no ESES pattern.

Though she had not had any clinical seizure episodes since infancy, ASM management was recommended due to the high level of interictal burden; increased risk for epilepsy due to remote history of stroke; as well as the possibility that she could be experiencing unrecognized subclinical seizures, as they reported brief inattentive events at school. Oxcarbazepine therapy was initiated.

Second Neuropsychological Evaluation (T2)

Follow-up neuropsychological evaluation was completed 18 months later. Parent report indicated persistent difficulties with staying on task, managing assignments, keeping track of materials, retaining information and recalling information independently/without prompting. They also reported the patient had been struggling with reading comprehension and writing out her ideas during school. Results of the follow-up evaluation showed appropriate developmental progress on tasks of verbal functioning but a lack of developmental progress, as evidenced by lower standardized scores, on tasks of nonverbal fluid reasoning. Increased attention difficulties and a lack of developmental progress, again as evidenced by lower standardized scores, on verbal and visual spatial memory tasks were also noted. Her cognitive profile, at that point suggesting lateralized dysfunction to the non-dominant, presumably right hemisphere based on below average nonverbal reasoning compared to average verbal reasoning perfor-

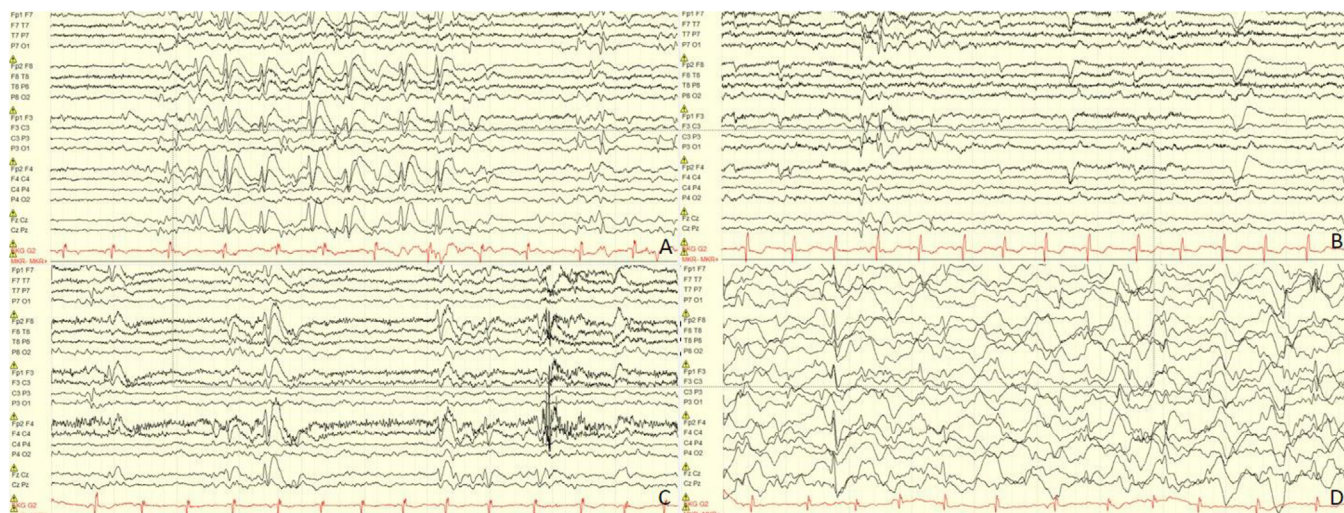


Fig. 2. Initial EEG. A: Awake portion demonstrating high amplitude bi-synchronous frontally predominant spike and wave discharges with greater amplitude on the right hemisphere. B. Awake portion demonstrating spike and wave discharges in the left hemisphere. C. Awake portion demonstrating spike-and-wave discharges independently the right and left hemisphere. D. Sleep portion demonstrating broad field generalized spike and wave with no ESES pattern. EEG settings: Bipolar montage; LP 1 Hz, HP 50 Hz, 15uV/mm, 10seconds/page.

mance, was consistent with the known greater right hemispheric impact of her prior infarct. Given this lack of appropriate developmental progress, there was concern that she was experiencing significant nocturnal epileptiform burden (i.e., ESES) and overnight continuous video-EEG monitoring was requested.

Long-term video-EEG monitoring revealed an abnormal EEG (Fig. 3 panel A) due to bifrontal epileptiform activity in the awake state and sleep exacerbation of right frontal epileptiform activity with the spike wave index calculated at 60%. The patient was then started on clobazam and underwent several EEG assessments over the following months with modifications in her ASM. Fig. 3 panel B shows spike wave index calculated at 70–80%, which led to a high dose diazepam trial and discontinuation of oxcarbazepine. Fig. 3 panel C shows a spike wave index calculated at 90–95% which led to a corticosteroid trial. Finally, Fig. 3 panel D shows 24-hour video EEG with no interictal discharges.

Based on the results of the second neuropsychological evaluation and the subsequent findings on serial EEG, the apparent change in the patient’s neuropsychological strengths and weak-

nesses between evaluations was likely multifactorial in nature. That is, the patient’s significant inattention that was noted in the first evaluation may have impacted her performance on verbal measures more so than visual spatial measures, thereby leading to the concern for possible dominant hemisphere dysfunction. In the context of additional data (i.e., MRI and EEG, subsequent neuropsychological evaluation), a clearer profile emerged (e.g., greater stagnation in visual-spatial abilities and concurrent improvement in verbal abilities). This pattern of findings is thought to reflect the evolution and persistence of lateralized ESES.

Third Neuropsychological Evaluation (T3)

A year later, and nine days following initiation of corticosteroid administration (Fig. 3 after panel C and before panel D), a third neuropsychological evaluation was completed as a part of a pre-surgical work-up. As such, the battery of tests administered was modified slightly according to the institution’s presurgical epilepsy battery. Importantly, the patient had been started on stimulant

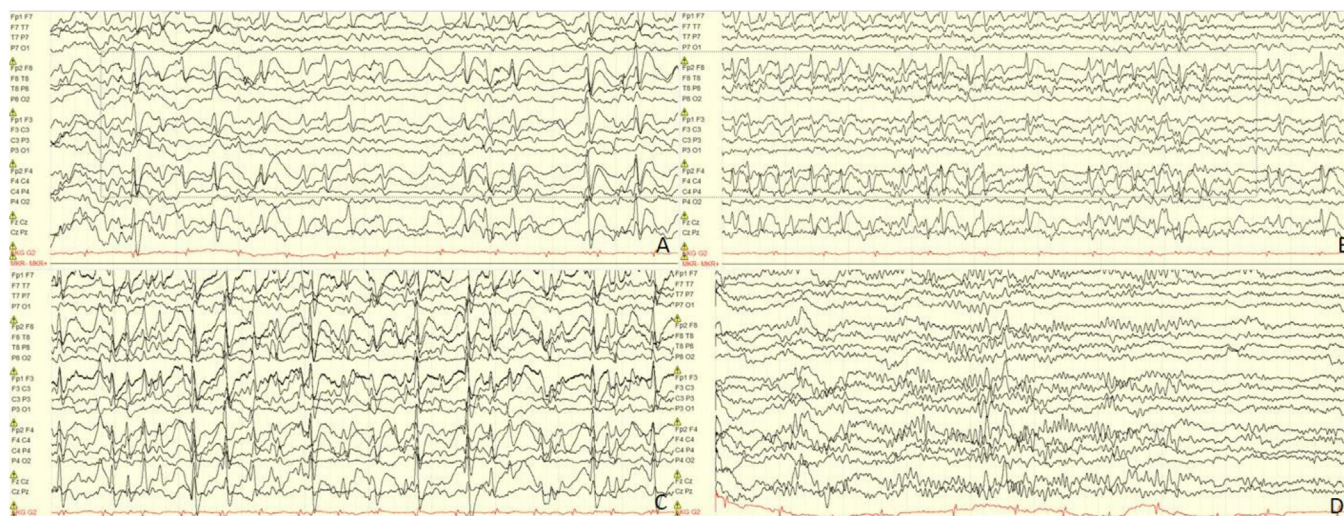

Fig. 3. Subsequent sleep EEGs and treatment modifications A. Spike-wave index calculated at 60% leading to clobazam initiation. B. Several weeks later, spike wave index calculated at 70–80% leading to high dose diazepam trial and oxcarbazepine discontinuation. C. Several weeks later spike wave index calculated at 90–95% leading to corticosteroid trial. D. Several weeks later no interictal discharges noted on 24 hour video EEG. EEG settings: Bipolar montage; LP 1 Hz, HP 50 Hz, 15uV/mm, 10seconds/page.

medication (lisdexamfetamine) between the second and third neuropsychological evaluations, which she took the morning of the evaluation. . At that time, parent report continued difficulties with reading comprehension, writing and math word problems. Improvement in attention and task completion were reported since the initiation of stimulant medication.

Direct comparison of the latest results with those attained in the evaluation conducted 1 year prior (T1) reflected appropriate developmental progress in all domains. She demonstrated significant improvement in her attention and nonverbal fluid reasoning skills, with her performances on tasks within these domains improving from the well below average range to the average range. These changes were thought to be attributable to improved attention and focus as her performances in the previous evaluation

reflected significant variability across tasks. With additional work-up of visual-spatial skills compared to previous evaluations, the patient demonstrated a more isolated/focal, deficit in visual-spatial skills (e.g., ability to recognize spatial relationships). There was also evidence of a subtle decline in visual-spatial reasoning over time. With regard to motor functioning, it is important to note that her dexterity with her right hand, although still much better than with her left hand, also declined compared to prior testing. Overall, findings corresponded well with the localization of maximal ESES discharges within the right posterior frontal-parietal region on prior EEG studies.

Of note, follow-up long-term monitoring EEG completed 7 weeks after initiating steroid treatment was normal, without epileptiform discharges or electroclinical seizures recorded,

Table 1
Neuropsychological measures administered at each of the three different neuropsychological evaluations.

	T1, age 8 <i>Clinical Evaluation</i>	T2, age 10 <i>Clinical follow-up</i>	T3, age 11 <i>Presurgical evaluation</i>	T4, age 11 <i>Targeted follow-up</i>
Intellectual Functioning	<ul style="list-style-type: none"> • Wechsler Intelligence Scales for Children, 5th Ed., 10 core subtests 	<ul style="list-style-type: none"> • Wechsler Intelligence Scales for Children, 5th Ed., 7 core subtests 	<ul style="list-style-type: none"> • Wechsler Intelligence Scales for Children, 5th Ed. 10 core subtests + Cancellation subtest 	<ul style="list-style-type: none"> • Wechsler Intelligence Scales for Children, 5th Ed. VSI, WMI and PSI indices
Motor Examination	<ul style="list-style-type: none"> • Grooved Pegboard 	<ul style="list-style-type: none"> • Grooved Pegboard 	<ul style="list-style-type: none"> • Grooved Pegboard 	
Attention & Impulse Control	<ul style="list-style-type: none"> • Conners Continuous Performance Task, 3rd Ed. 	<ul style="list-style-type: none"> • Conners Continuous Performance Task, 3rd Ed. 	<ul style="list-style-type: none"> • Conners Continuous Performance Task, 3rd Ed. 	
Executive Functioning	<ul style="list-style-type: none"> • NEPSY-II, Auditory Attention & Response Set subtest 	<ul style="list-style-type: none"> • NEPSY-II, Inhibition subtest 		
Language	<ul style="list-style-type: none"> • Clinical Evaluation of Language Fundamentals, 5th Ed., Following Directions and Formulated Sentences Subtests • Wechsler Intelligence Scales for Children, 5th Ed. Similarities and Vocabulary subtests 	<ul style="list-style-type: none"> • Tower of London DX, 2nd Ed. • Wechsler Intelligence Scales for Children, 5th Ed. Similarities and Vocabulary subtests 	<ul style="list-style-type: none"> • Wechsler Intelligence Scales for Children, 5th Ed. Similarities and Vocabulary subtests • NEPSY-II, Comprehension of Instructions subtest • Kaufman Assessment Battery for Children, 2nd Ed. Normative Update, Expressive Vocabulary subtest • Wide Range Assessment of memory & Learning, 2nd Ed., Sentence Memory subtest 	
Visual Spatial Abilities	<ul style="list-style-type: none"> • Wechsler Intelligence Scales for Children, 5th Ed. Block Design and Visual Puzzles subtests 	<ul style="list-style-type: none"> • Wechsler Intelligence Scales for Children, 5th Ed. Block Design and Visual Puzzles subtests 	<ul style="list-style-type: none"> • Wechsler Intelligence Scales for Children, 5th Ed. Block Design and Visual Puzzles subtests • Benton Judgement of Line Orientation • Beery Developmental Test of Visual Perception • Benton Facial Recognition Test 	<ul style="list-style-type: none"> • Wechsler Intelligence Scales for Children, 5th Ed. Block Design and Visual Puzzles subtests • Benton Judgement of Line Orientation
Visual Motor Integration	<ul style="list-style-type: none"> • Beery Developmental Test of Visual-Motor Integration 	<ul style="list-style-type: none"> • Beery Developmental Test of Visual-Motor Integration 	<ul style="list-style-type: none"> • Beery Developmental Test of Visual-Motor Integration 	<ul style="list-style-type: none"> • Beery Developmental Test of Visual-Motor Integration
Memory	<ul style="list-style-type: none"> • Children's Memory Scale Dot Locations, Stories and Faces subtests • California Verbal Learning Test-Children's 	<ul style="list-style-type: none"> • Children's Memory Scale, Stories and Faces subtests • California Verbal Learning Test-Children's 	<ul style="list-style-type: none"> • Child and Adolescent Memory Profile, Lists and Objects subtests 	<ul style="list-style-type: none"> • Child and Adolescent Memory Profile, Lists and Objects subtests
Academic Achievement		<ul style="list-style-type: none"> • Wechsler Individual Achievement Test, 3rd Ed., Word Reading, Numerical Operations and Reading Comprehension subtests 	<ul style="list-style-type: none"> • Wechsler Individual Achievement Test, 4th Ed., Word Reading, Numerical Operations and Spelling subtests 	
Adaptive Functioning		<ul style="list-style-type: none"> • Adaptive Behavior Assessment System, 3rd Ed., Parent form 		
Emotional/ Behavioral Functioning	<ul style="list-style-type: none"> • ADHD Rating Scale, 4th Ed. Home and School versions • Achenbach Child Behavior Checklist & Teacher's Report Form • Behavior Rating Inventory of Executive Function, 2nd Ed. parent and teacher forms 	<ul style="list-style-type: none"> • Behavioral Assessment System for Children, 3rd Ed. Parent and Teacher forms 	<ul style="list-style-type: none"> • Behavioral Assessment System for Children, 3rd Ed. Parent and Teacher forms 	<ul style="list-style-type: none"> • Behavioral Assessment System for Children, 3rd Ed. Parent form

Note: Ed. = Edition.

indicative of complete resolution of her ESES following steroid treatment. As such, she was not offered surgery.

Fourth neuropsychological evaluation (T4)

Six months later, following resolution of her ESES and while still receiving steroid treatment, a fourth (targeted) neuropsychological evaluation was completed. The patient again had taken her

stimulant medication as prescribed on the day of testing. Compared to her previous evaluation, the patient demonstrated significant improvement in her processing speed and delayed memory recognition for verbal stimuli. Although the differences in performances did not reach statistical significance, the patient also demonstrated a trend toward improved visual-spatial reasoning, visual spatial processing, and delayed memory for visual stimuli with these performances now scoring in the broadly average range.

Table 2
Relevant neuropsychological test data at each of the three different neuropsychological evaluations and comparisons between performances where possible.

	T1, age 8 <i>Clinical evaluation</i>		T2, age 10 <i>Clinical follow-up</i>		T3, age 11 <i>Presurgical evaluation</i>		T4, age 11 <i>Targeted follow-up</i>		RCIs		
	<u>Raw</u>	<u>SS</u>	<u>Raw</u>	<u>SS</u>	<u>Raw</u>	<u>SS</u>	<u>Raw</u>	<u>SS</u>	<u>T1 v T2</u>	<u>T2 v T3</u>	<u>T3 v T4</u>
INTELLECTUAL ABILITY											
Wechsler Intelligence Scales for Children, 5th Ed.											
Verbal Comprehension Index		92		95		95			0.45	0	-
Similarities	14	7	20	7	24	8			0	0.61	-
Vocabulary	19	10	29	11	29	10			0.57	-0.57	-
Visual Spatial Index		92				72		81	-	-	1.41
Block Design	14	8	18	6	14	4	22	7	-1.36	-1.36	1.72
Visual Puzzles	11	9			11	6	11	6	-	-	-
Fluid Reasoning Index		112		74		100			-7.31*	5.00*	-
Matrix Reasoning	21	14	11	4	18	9			-7.11*	3.55*	-
Figure Weights	16	10	14	7	24	11			-2.89*	3.85*	-
Working Memory Index		97				76		81	-	-	0.83
Digit Span	22	10	19	7	20	6	21	7	-2.24*	-0.75	0.79
Picture Span	20	9			21	6	25	8	-	-	1.18
Processing Speed Index		105				75		100	-	-	3.40*
Coding	39	13	36	8	44	9	54	11	-2.57*	0.51	1.08
Symbol Search	15	9			8	2	26	9	-	-	3.60*
MOTOR EXAMINATION											
Grooved Pegboard											
	<i>2 rows</i>		<i>5 rows</i>		<i>5 rows</i>						
Right Hand	37"	98	78"	91	116"	< 45			-1.04	-6.86*	-
Left Hand	Discontinued		Discontinued		Discontinued				-	-	-
ATTENTION & IMPULSE CONTROL											
Conners Continuous Performance Test-3											
Detectability		T 54		T 76		T 51			-22*	3	-
Omissions		T 53		T 90		T 52			-37*	1	-
Commissions		T 51		T 49		T 45			2	6	-
Perseverations		T 44		T 81		T 47			-37*	-3	-
Hit Reaction Time		T 66		T 84		T 57			-18*	9	-
VISUOSPATIAL SKILLS											
Benton Judgement of Line Orientation											
					<u>Raw</u>	<u>SS</u>	<u>Raw</u>	<u>SS</u>	<u>T1 v T2</u>	<u>T2 v T3</u>	<u>T3 v T4</u>
					13	74	16	83	-	-	1.32
Benton Facial Recognition Test											
					25	97			-	-	-
Beery Developmental Test of Visual Perception											
					47	115			-	-	-
VISUAL-MOTOR COORDINATION											
Beery Developmental Test of Visual-Motor Integration											
	<u>Raw</u>	<u>SS</u>	<u>Raw</u>	<u>SS</u>	<u>Raw</u>	<u>SS</u>	<u>Raw</u>	<u>SS</u>	<u>T1 v T2</u>	<u>T2 v T3</u>	<u>T3 v T4</u>
	18	89	19	79	23	93			-1.36	1.91	-
MEMORY											
Children's Memory Scale											
Stories											
Immediate Recall	27	8	35	6					-1.01	-	-
Delayed Recall	22	7	22	4					-1.31	-	-
Delayed Recognition	22	7	22	6					-0.46	-	-
Faces											
Immediate Recall	32	12	33	7					-2.27*	-	-
Delayed Recall	31	12	27	4					-3.70*	-	-
California Verbal Learning Test-Children's											
Immediate Recall											
List A Total Trials 1-5	35	T 45	30	T30					-2.04*	-	-
Delayed Recall											
List A Long Delay Free Recall	1	55	3	55					0.00	-	-
List A Long Delay Cued Recall	1	55	3	63					0.59	-	-
Delayed Recognition											
Correct Recognition Hits	11	85	8	63					-1.32	-	-
Discriminability	75.56	78	75.56	63					-1.05	-	-
Child and Adolescent Memory Profile											
Immediate Memory											
Lists					16	6	17	6	-	-	0.00
Objects					42	10	38	8	-	-	-0.79
Delayed Memory											
Lists Delayed					5	6	5	6	-	-	0.00
Lists Recognition					9	1	14	9	-	-	2.59*
Objects Delayed					14	4	20	8	-	-	1.31

Note: SS = standardized score (standard score, scaled score or T-score, as appropriate); **significant decrease between times***; **significant increase between times***.

These stable or possible mild improvements were thought to be related to cessation of her ESES. Continued low average performances on tasks of visual spatial reasoning were consistent with her history of right hemisphere involvement.

A list of tests administered across all four evaluations are presented in Table 1. Additionally, relevant test results (intellectual functioning, attention, visual-spatial/visual-motor integration and memory domains) are presented in Table 2. Where appropriate, reliable change indices (RCI) are provided comparing T0, T1 and T2 performances. RCIs for the Wechsler Intellectual Scale, 5th Edition, California Verbal Learning Test-Children's, Beery Developmental Test of Visual-Motor Integration and Child and Adolescent Memory Profile were calculated using Zahra's RCI calculator, as described in a recent review [14]. The values reported for the Conners Continuous Performance Test, 3rd Edition are based on critical values for significant change provided in the test manual [15]. Both the RCIs calculated by the Zahra RCI calculator and the critical values reported in the Conners Continuous Performance Test, 3rd Edition manual are based on the RCI formula provided by Jacobson and Truax [16]. Grooved pegboard RCIs are based on test-retest reliabilities reported elsewhere in the literature [17]. The task of fine motor dexterity was discontinued due to difficulties utilizing the left upper extremity, consistent with her history of left spastic hemiplegic CP.

Discussion

This case demonstrates a scenario in which neuropsychological evaluation ordered on the basis of cognitive and behavioral concerns led to the identification of an evolving epileptic syndrome, assisted in its management, and predicted improvement once treatment-responsive. This case highlights the importance of comprehensive epilepsy care and routine longitudinal involvement of neuropsychology in the management of complex epilepsy patients.

Neuropsychological assessments are useful in not only understanding the patient's individual pattern of cognitive strengths and weaknesses, but also in parsing out the impact of medical, developmental, and psychosocial factors on the patient's clinical presentation. Within the broader epilepsy population, neuropsychological evaluation can also provide information about lateralization of cognitive functioning as well specific areas of cognitive dysfunction and their association with seizure foci [1,2]. Longitudinal neuropsychological assessment is especially important given the inherent variability of cognitive developmental trajectories and possibility of neuroanatomical functional reorganization within the pediatric epilepsy population [18].

With regard to patients with CSWS specifically, neuropsychological assessment is especially important for a number of reasons, several of which were demonstrated within our case. First, patients with CSWS may or may not present with clinical seizure burden [3,8]. As such, in those instances in which the patient is not experiencing clinical seizures, neuropsychological evaluation based on concerns for changes in behavior or cognition may be the route through which these patients are brought to the attention of the neurology team.

Second, CSWS is associated with changes in behavioral functioning such as hyperactivity and aggression, likely as a result of chronic sleep deprivation secondary to the disruption of the quality of sleep by epileptiform activity [13]. Given that these behaviors are not specific to CSWS, a thorough understanding of the timeline of symptom onset within the context of the patients' developmental, family and psychosocial history is imperative in order to differentiate between a developmental or behavioral disorders such as Attention-Deficit/Hyperactivity Disorder, Oppositional Defiant Disorder, Depression or Anxiety.

Third, CSWS is associated with changes in cognitive development and functioning, seemingly as a result of the disruption of sleep-dependent processes that support the consolidation of newly learned information [4,9,10]. Cognitive change can be characterized as a plateau or lack of developmental progress, global loss of skill or, in the case of localized ESES discharges, specific deficits [11]. Just as in the case of presurgical neuropsychological evaluations, having an assessment early in the course of epilepsy is essential to identify each child's cognitive functioning baseline against which changes in cognitive functioning over time can be measured [1,18]. While it is certainly possible to quantify such changes in a single neuropsychological assessment, longitudinal assessment, especially when there is direct comparison between evaluation (i.e., repeating the same tests), allows for tracking developmental progress, better identification of emerging cognitive impairments or plateaus in development, and increased understanding of the impact of other contributing factors on the patient's profile. Identification and treatment of CSWS is important as resolution of this electrographic pattern has been shown to be associated with better cognitive outcomes despite the low clinical seizure burden in many patients [8,10,12,19].

This case presentation is limited by a number of factors, including the inherent nature of a single case report. Over the course of these evaluations, the patient's medication regimen was modified to include both changes in ASM dosages as well as the introduction of a stimulant medication to treat significant inattention identified on her second NP evaluation. Similarly, the timing of the NP evaluations and EEG studies did not directly coincide. As such, it is not possible to draw conclusions as to what specifically impacted longitudinal changes on EEG or whether the results of the third NP evaluation reflected resolution of her CSWS.

Conclusion

This case highlights the importance of comprehensive epilepsy care and routine involvement of neuropsychology in the management of complex epilepsy patients. Neuropsychological evaluation and regular re-evaluations can be helpful in identifying subclinical seizures and CSWS in otherwise healthy children with remote history of neurological insult by monitoring developmental progress and changes in the neuropsychological profile over time.

Take-Home

Longitudinal neuropsychological evaluations can be helpful in identifying subclinical seizure activity and CSWS in otherwise healthy children with remote history of neurological insult.

Human and animal rights

The authors declare that the work described has not involved experimentation on humans or animals.

Informed consent and patient details

The authors declare that this report does not contain any personal information that could lead to the identification of the patient(s) and/or volunteers.

Funding

This work did not receive any grant from funding agencies in the public, commercial, or not-for-profit sectors.

Author contributions

All authors attest that they meet the current International Committee of Medical Journal Editors (ICMJE) criteria for Authorship.

Declaration of Competing Interest

The authors declare that they have no known competing financial interests or personal relationships that could have appeared to influence the work reported in this paper.

References

- [1] Jones-Gotman M, Smith M, Risse GL, Westerveld M, Swanson SJ, Giovagnoli AR, et al. The contribution of neuropsychology to diagnostic assessment in epilepsy. Vol. 18, *Epilepsy and Behavior*. 2010.
- [2] Morrison CE, Macallister WS, Barr WB. Neuropsychology Within a Tertiary Care Epilepsy Center. *Archives of Clinical Neuropsychology*. 2018;33(3).
- [3] Patry G, Lyagoubi S, Tassinari CA. Subclinical "electrical status epilepticus" induced by sleep in children: a clinical and electroencephalographic study of six cases. *Arch Neurol* 1971;24(3).
- [4] Tassinari CA, Rubboli G. Cognition and paroxysmal EEG activities: From a single spike to electrical status epilepticus during sleep. *Epilepsia* 2006;47(s2):40–3.
- [5] Tassinari CA, Rubboli G. Encephalopathy related to Status Epilepticus during slow Sleep: current concepts and future directions. *Epileptic Disorders* 2019;21(S1).
- [6] Sanchez Fernandez I, Takeoka M, Tas E, Peters JM, Prabhu SP, Stannard KM, et al. Early thalamic lesions in patients with sleep-potentiated epileptiform activity. *Neurology*. 2012;78(22):1721–7.
- [7] Samantha D, al Khalili Y. Electrical Status Epilepticus in Sleep. Treasure Island (FL); 2021 Jul.
- [8] Marashly A, Koop J, Loman M, Lee YW, Lew SM. Examining the utility of resective epilepsy surgery in children with electrical status epilepticus in sleep: long term clinical and electrophysiological outcomes. *Front Neurol* 2020 Jan;15:10.
- [9] Tassinari CA, Cantalupo G, Rios-Pohl L, Giustina E della, Rubboli G. Encephalopathy with status epilepticus during slow sleep: "the penelope syndrome." In: *Epilepsia*. 2009.
- [10] Yilmaz S, Serdaroglu G, Gokben S, Akcay A. Clinical characteristics and outcome of children with electrical status epilepticus during slow wave sleep. *J Pediatric Neurosci* 2014;9(2):105. <https://doi.org/10.4103/1817-1745.139266>.
- [11] Holmes GL, Lenck-Santini PP. Role of interictal epileptiform abnormalities in cognitive impairment. Vol. 8, *Epilepsy and Behavior*. 2006.
- [12] Raha S, Shah U, Udani V. Neurocognitive and neurobehavioral disabilities in Epilepsy with Electrical Status Epilepticus in slow sleep (ESES) and related syndromes. *Epilepsy Behav* 2012;25(3):381–5.
- [13] Stores G, Wiggs L, Campling G. Sleep disorders and their relationship to psychological disturbance in children with epilepsy. *Child Care Health Dev* 1998;24(1).
- [14] MacAllister WS, Murphy H, Coulehan K. Serial neuropsychological evaluation of children with severe epilepsy. *J Pediatric Epilepsy* 2016;6(1).
- [15] Conners CK. Conners Continuous Performance Test 3rd Edition Manual. North Tonawanda: Multi-Health Systems, Inc.; 2014.
- [16] Jacobson NS, Truax P. Clinical significance: a statistical approach to defining meaningful change in psychotherapy research. *J Consult Clin Psychol* 1991;59(1):12–9. <https://doi.org/10.1037//0022-006x.59.1.12>. PMID: 2002127.
- [17] Wang Y-C, Magasi SR, Bohannon RW, Reuben DB, McCreath HE, Bubela DJ, et al. Assessing dexterity function: a comparison of two alternatives for the NIH toolbox. *J Hand Ther* 2011;24(4):313–21.
- [18] MacAllister WS, Sherman EMS. Evaluation of Children and Adolescents with Epilepsy. In: Barr W, Morrison C, editors. *Handbook on the Neuropsychology of Epilepsy*. New York: Springer; 2015.
- [19] Pera MC, Brazzo D, Altieri N, Balottin U, Veggiotti P. Long-term evolution of neuropsychological competences in encephalopathy with status epilepticus during sleep: a variable prognosis. *Epilepsia* 2013;54:77–85.