

Results of intravitreal dexamethasone implant (Ozurdex®) for retinal vascular diseases with macular edema

An observational study of real-life situations

Pichai Jirattanasopa, MD* , Sakunjanut Jiranoppasakdawong, MD, Mansing Ratanasukon, MD, Patama Bhurayanontachai, MD, Wantanee Dangboon, MD

Abstract

To evaluate the efficacy of intravitreal dexamethasone implants (Ozurdex®) for the treatment of macular edema (ME) associated with retinal vascular diseases in real-life situations.

This retrospective study included patients with ME associated with retinal vascular occlusion (RVO) or diabetic macular edema (DME) treated with dexamethasone implants. Demographic data, best-corrected visual acuity (BCVA), and central retinal thickness (CRT) at baseline and at 1, 3, and 6 months postoperatively were collected and analyzed, and the adverse events were recorded.

Forty-four eyes, 42 patients were included in the study. The mean logMAR BCVA improved from 0.79 ± 0.38 at baseline to 0.60 ± 0.34 ($P < 0.001$), 0.72 ± 0.38 ($P = .002$), and 0.72 ± 0.37 ($P = .002$) at 1, 3, and 6 months, respectively. The CRT decreased from 526.70 ± 159.58 μm at baseline to 279 ± 66.23 , 422.91 ± 206.99 , and 350.23 ± 151.51 μm at 1, 3, and 6 months, respectively ($P < 0.001$, all visits). The average number of injections was 1.43 ± 0.5 . Nineteen eyes (43.18%) received second injections at an interval of 4.20 ± 0.61 months. The mean logMAR BCVA was greater in RVO than in DME patients and in treatment-naïve eyes than in previously treated ones. The baseline CRT of the reinjection group was significantly higher than that of the single-injection group for both the RVO ($P < 0.001$) and DME groups ($P = .002$). Nine eyes (20.45%) with increasing intraocular pressure (IOP) were well controlled with medication, and cataract progression was observed in five eyes (21.73%) during follow-up.

The dexamethasone implant was effective for the treatment of macular edema secondary to RVO and DME in terms of visual acuity and CRT improvement over 6 months. The visual acuity was greater in the RVO and treatment-naïve eyes. Reinjection may be associated with a high baseline CRT. The increase in the occurrence of IOP and cataract progression was similar to that reported in previous studies.

Abbreviations: BCVA = Best-corrected visual acuity, CRT = central retinal thickness, DME = Diabetic macular edema, DR = Diabetic retinopathy, IOP = Intraocular pressure, ME = Macular edema, RVO = Retinal vascular occlusion, SD-OCT = Spectral-domain optical coherence tomography, VEGF = Vascular endothelial growth factor.

Keywords: dexamethasone implant, diabetic macular edema, macular edema, Ozurdex®, retinal vascular disease, retinal vein occlusion

1. Introduction

Macular edema is the main cause of vision loss in retinal vascular diseases, such as retinal vein occlusion (RVO) and diabetic retinopathy (DR).^[1–4] An important factor in the pathogenesis

of retinal vascular diseases associated with macular edema is inflammation, which breaks the blood-retinal barrier and increases the vascular permeability of perifoveal capillaries. Subsequently, fluid accumulates in the macular and there is an increase in the macular thickness.^[5–7]

Funding: This research was supported by a grant from the Faculty of Medicine, Prince of Songkla University, Songkhla, Thailand.

Consent to participate: For this type of study, formal consent was waived.

Consent for publication: The authors consent to the publication of this manuscript.

The authors of this work have nothing to disclose.

The authors declare that they have no conflict of interest.

The datasets generated during and/or analyzed during the current study are available from the corresponding author on reasonable request.

Availability of data and materials: The datasets generated and/or analyzed during the current study are available from the corresponding author upon reasonable request.

Ethics approval: Ethics approval was provided by the Ethics Committee, Faculty of Medicine, Prince of Songkla University (REC number 62-047-2-4).

Department of Ophthalmology, Faculty of Medicine, Prince of Songkla University, Songkhla, Thailand.

*Correspondence to: Pichai Jirattanasopa, Department of Ophthalmology, Faculty of Medicine, Prince of Songkla University, Songkhla, Thailand 90110 (e-mail: jirarapichai@gmail.com).

Copyright © 2022 the Author(s). Published by Wolters Kluwer Health, Inc. This is an open-access article distributed under the terms of the Creative Commons Attribution-Non Commercial License 4.0 (CCBY-NC), where it is permissible to download, share, remix, transform, and build upon the work provided it is properly cited. The work cannot be used commercially without permission from the journal.

How to cite this article: Jirattanasopa P, Jiranoppasakdawong S, Ratanasukon M, Bhurayanontachai P, Dangboon W. Results of intravitreal dexamethasone implant (Ozurdex®) for retinal vascular diseases with macular edema: an observational study of real-life situations. *Medicine* 2022;101:27(e29807).

Received: 26 June 2021 / Received in final form: 6 May 2022 / Accepted: 27 May 2022

<http://dx.doi.org/10.1097/MD.00000000000029807>

Intravitreal corticosteroids may be beneficial in treating macular edema because of their anti-inflammatory action, as they can block the production of vascular endothelial growth factor (VEGF) and other inflammatory mediators. Additionally, they can improve the blood-retinal barrier function, which results in reduced fluid accumulation and decreased macular thickness.^[8,9]

Dexamethasone is a potent corticosteroid. However, it has high water solubility and a short half-life (<4 hours) when used in intravitreal injections. Therefore, a sustained-release dexamethasone implant was developed to prolong its action and reduce the number of intravitreal injections. The intravitreal dexamethasone implant Ozurdex® (Allergan Plc, Irvine, CA) is a sustained-release, biodegradable intravitreal implant approved by the US Food and Drug Administration (FDA) for the treatment of macular edema related to retinal vascular disease due to RVO and DR.^[10] The Ozurdex® implant releases potent corticosteroids via the NOVADUR® solid polymer drug delivery system into the vitreous over a period of ≤ 6 months.^[10-12] Previous studies have shown that Ozurdex® implants effectively manage macular edema due to retinal vascular disease for up to 6 months.^[13-16] Nevertheless, there are complications associated with the use of corticosteroid intravitreal injections, such as an increase in intraocular pressure (IOP), cataract progression, and risk of endophthalmitis.^[13-16]

Several studies concerning the effectiveness of intravitreal Ozurdex® implants in real-life situations have been conducted in many countries^[17-21]; however, there is a lack of studies on this topic in Thailand. Therefore, the main purpose of this study was to evaluate the efficacy of intravitreal Ozurdex® implants for the treatment of macular edema associated with RVO and diabetic macular edema (DME) in real-life situations within the Thai context. In addition, the other purposes were to evaluate the safety of the drug and the factors of different patients that may affect the outcomes.

2. Methods

2.1. Patients and data collection

We retrospectively reviewed the medical records and images of patients who received intravitreal Ozurdex® implants for macular edema associated with RVO and DR between April 2015 and December 2019 at the department of ophthalmology, Songklanagarind hospital, Prince of Songkla University (PSU), Songkhla province, Thailand. Our study was approved by the institutional review board of Songklanagarind hospital, PSU, which waived the need for written informed consent from the participants; the study adhered to the guidelines of the declaration of Helsinki.

The inclusion criteria were as follows: (1) age ≥ 18 years, (2) macular edema secondary to RVO or DME treated with

monotherapy intravitreal Ozurdex® implants during the study period, and (3) macular edema proven and measured using spectral-domain optical coherence tomography (SD-OCT).

The exclusion criteria were as follows: (1) patients treated with other intravitreal anti-VEGF injections or triamcinolone injections within 3 and 6 months before the first Ozurdex® injection, respectively; (2) macular edema from other causes, such as Irvine-Gass syndrome, uveitic macular edema, age-related macular degeneration, and vitreomacular traction; (3) patients with a history of glaucoma or steroid-induced glaucoma in the study eye; and (4) follow-up of <6 months or missing data, including best-corrected visual acuity (BCVA), IOP, and OCT images (at baseline and 1, 3, or 6 months after treatment).

We collected the following data: age; sex; underlying disease; affected eye; diagnosis of macular edema; previous intravitreal injections; BCVA; number of injections; IOP; CRT; and lens status at baseline and 1, 3, and 6 months after treatment. Cataract progression was defined as an increase in the natural lens grading from baseline medical records.

The degree of macular edema and CRT were evaluated using an SD-OCT machine (Spectralis®; heidelberg engineering, Heidelberg, Germany or CIRRUS OCT®; Carl Zeiss Meditec, Inc., Dublin, CA). We used the same OCT machine for each patient during the follow-up.

2.2. Statistical analysis

Statistical analysis was performed using STATA version 14 (StataCorp LP, College Station, TX). Demographic data and adverse events were analyzed using descriptive statistics, including mean and standard deviation (SD). The variables are summarized in frequency and percentage tables. Linear fixed and random-effects models were used to compare the BCVA and CRT between the baseline and each follow-up and the differences in the mean BCVA from the baseline between each group. Linear fixed and random-effects models were also used to compare the mean number of injections between the two groups. The percentages of patients who had phakia or pseudophakia and received a single injection or reinjection were tested using Fisher exact test. Statistical significance was set at $P < 0.05$. Any adverse events during the study were analyzed using descriptive statistics.

3. Results

3.1. Demographic data

A total of 80 eyes (75 patients) with a diagnosis of macular edema associated with RVO or DR, who were treated with

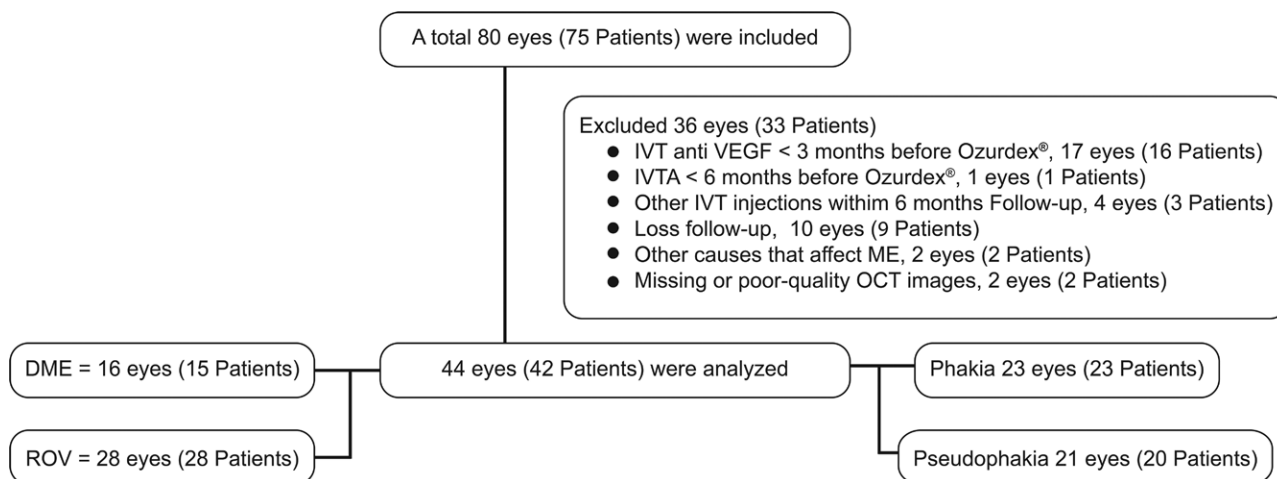


Figure 1. Flowchart of patients and eyes included in and excluded eye from the study.

intravitreal Ozurdex® implants, were included in the study. Of these, 36 eyes (33 patients) were excluded for receiving intravitreal antiVEGF injections within 3 months (17 eyes, 16 patients) or intravitreal triamcinolone injection within 6 months (1 eye) prior to patient inclusion, incomplete follow-up at 6 months (10 eyes, 9 patients), other causes that may affect the macular edema (2 eyes, 2 patients), missing OCT images for some visits during follow-up (2 eyes, 2 patients), and received other intravitreal injections within the 6 months of the study period (4 eyes, 3 patients). Finally, data from 44 eyes (42 patients) were analyzed (Fig. 1).

The baseline demographic data and clinical characteristics of the patients are summarized in Table 1. Macular edema due to RVO and DME was observed in 28 (63.6%) and 16 (36.4%) eyes, respectively. The baseline lens status was phakia in 23 (52.3%) and pseudophakia in 21 (47.7%) eyes. In the RVO group, 14/28 eyes (50%) were diagnosed with CRVO,

and 19/28 eyes (66.86%) had previously received intravitreal antiVEGF injections. In the DME group, 10/16 eyes (62.5%) were diagnosed with severe nonproliferative diabetic retinopathy (NPDR), and 15/16 eyes (93.75%) had previously received intravitreal antiVEGF injections before being enrolled into the study.

3.2. Efficacy

Overall, intravitreal Ozurdex® injections showed statistically significant improvement in BCVA and CRT reduction at 1, 3, and 6 months when compared with the baseline values. Nineteen eyes (43.2%) received a second Ozurdex® injection. A mean (± SD) of 1.43 ± 0.5 injections were administered, and the average interval until the next injection was 4.20 ± 0.61 months (3.03–5.03 months); generally, all patients received a second injection 3 months after receiving the first injection (Table 2).

3.3. Efficacy in RVO and DME groups

The BCVA significantly improved after intravitreal Ozurdex® injections at 1, 3, and 6 months when compared with the baseline values in the RVO group ($P < 0.001$, $P < 0.001$, and $P = .014$, respectively) and at 1 and 6 months when compared with the baseline in the DME group ($P < 0.001$, $P = .047$). The CRT significantly decreased after intravitreal Ozurdex® injections at 1, 3, and 6 months ($P < 0.001$, $P = .005$, and $P < 0.001$, respectively) when compared with the baseline values in both groups. Additionally, greater improvement in BCVA and CRT was observed at 1 month after the initial injections in both groups.

The mean number of injections, percentage of patients who received a second injection, and baseline lens status did not show any statistically significant difference between the DME and RVO groups (Table 3).

3.4. Subgroup analysis: number of injections; single and reinjection groups

In both the RVO and DME groups, at the 6-month follow-up, the BCVA significantly improved only in the reinjections group when compared with the 1 injection group ($P = .020$, 0.233 in RVO and $P = .011$, 0.342 in DME), respectively. In addition, the CRT was significantly lower in the reinjection group than in the single injection group ($P < 0.001$ vs $P = .092$ in RVO and $P < 0.001$ vs $P = .153$ in DME). However, the reinjection group showed worsening BCVA and CRT at 3 months and required reinjection. The baseline CRT in the reinjection group was significantly thicker than that in the single injection group ($P < 0.001$ in both the RVO and DME groups).

Table 1
Demographic data.

44 eyes, 42 patients	N (%)
Sex, No. (%)	
Male	21 (50.0)
Female	21 (50.0)
Age (mean ± SD)	68.29 ± 8.30
Lateral, No. (%)	
RE	21 (47.7)
LE	23 (52.3)
RVO (eyes), No. (%)	28/44 (63.6)
Types	
CRVO	14 (50.0)
BRVO	12 (42.9)
HRVO	2 (7.1)
Prior treatment	
Naive No. (%)	9 (32.14)
IVT No. (%)	19 (66.86)
Number of injections (mean ± SD)	5.58 ± 4.56
Duration, months (mean ± SD)	16.42 ± 13.54
DME (eyes), No. (%)	16/44 (36.4)
Severity	
Mild NPDR	1 (6.25)
Moderate NPDR	3 (18.75)
Severe NPDR	10 (62.5)
PDR	2 (12.5)
Prior treatment	
Naive No. (%)	1 (6.25)
IVT No. (%)	15 (93.75)
Number of injections (mean ± SD)	10.27 ± 4.28
Duration, months (mean ± SD)	31.53 ± 12.91
Diabetes mellitus, No. (%)	23 (54.8)
Hypertension, No. (%)	34 (81.0)
Dyslipidemia, No. (%)	20 (47.6)
Other, No. (%)	
Heart diseases (ischemic heart diseases, arrhythmia, valvular heart disease, congestive heart failure)	11 (25.00)
Stroke	9 (20.45)
Asthma	3 (6.82)
Chronic kidney diseases	2 (4.54)
Gout	2 (4.54)
Baseline VA logMAR (mean ± SD)	0.78 ± 0.37
Baseline CRT (µm) (mean ± SD)	526.70 ± 159.58
Baseline IOP (mm Hg) (mean ± SD)	12.65 ± 3.10
Baseline lens status, No (%)	
pseudophakic (IOL)	21 (47.7)
phakic (Non-IOL)	23 (52.3)

Abbreviations: BCVA = best-corrected visual acuity, BRVO = branch retinal vein occlusion, CRT = central retinal thickness, CRVO = central retinal vein occlusion, DME = diabetic macular edema, HRVO = hemi-retinal vein occlusion, IOP = intraocular pressure, IOL = intraocular lens, IVT = intravitreal injection, logMAR = logarithm of the minimum angle of resolution, NPDR = nonproliferative diabetic retinopathy, PDR = proliferative diabetic retinopathy, RVO = retinal vein occlusion, SD = standard deviation, VA = visual acuity.

Table 2
Changes in the BCVA and CRT from baseline.

	BCVA (logMAR) mean±SD	CRT (µm) mean±SD
At baseline ^a	0.78 ± 0.38	526.70 ± 159.58
At 1 month ^b	0.60 ± 0.34	279.25 ± 66.23
At 3 months ^c	0.72 ± 0.38	422.91 ± 206.99
At 6 months ^d	0.72 ± 0.37	350.23 ± 151.51
P-value*	a-b, $P < 0.001$, a-c, $P = .002$, a-d, $P = 0.002$	a-b, $P < 0.001$, a-c, $P < 0.001$, a-d, $P < 0.001$
Number of injections, mean ± SD	1.43 ± 0.50	
One injection, eyes (%)	25 (56.8)	
Two injections, eyes (%)	19 (43.2)	
Time to second injections, months (mean ± SD) (min,max)	4.20 ± 0.61 (3.03–5.03)	

Abbreviations: BCVA = best-corrected visual acuity, CRT = central retinal thickness, logMAR = logarithm of the minimum angle of resolution, SD = standard deviation.
*P-value: Linear fixed and random effect model.

Table 3
Efficacy in ME due to RVO and DME.

	RVO (N = 28) (mean ± SD)	DME (N = 16) (mean ± SD)	P-value ⁽¹⁾⁻⁽²⁾
BCVA (logMAR)			
At baseline ^a	0.87 ± 0.40	0.63 ± 0.27	
At 1 month ^b	0.66 ± 0.36	0.49 ± 0.29	0.276*
At 3 months ^c	0.77 ± 0.40	0.62 ± 0.30	0.053*
At 6 months ^d	0.80 ± 0.40	0.56 ± 0.24	0.918*
P-value ^(e-d)	a-b, P < 0.001* a-c, P < 0.001* a-d, P = .014*	a-b, P < 0.001* a-c, P = .718* a-d, P = 0.047*	
CRT (µm)			
At baseline ^a	519.07 ± 176.03	540.06 ± 130.08	
At 1 month ^b	260.68 ± 54.64	311.75 ± 73.69	0.584*
At 3 months ^c	425.75 ± 235.05	417.94 ± 152.74	0.600*
At 6 months ^d	339.75 ± 168.37	368.56 ± 119.23	0.887*
P-value ^(e-d)	a-b, P < 0.001* a-c, P = .005* a-d, P < 0.001*	a-b, P < 0.001* a-c, P = .005* a-d, P < 0.001*	
Number of injections, (mean ± SD)	1.39 ± 0.50	1.50 ± 0.52	0.488*
Numbers of injections, eyes (%)			
One injection	17 (60.7)	8 (50.0)	0.540†
Two injection	11 (39.3)	8 (50.0)	
Baseline lens status			
Phakic	17 (60.7)	6 (26.1)	0.211†
Pseudophakic	11 (39.3)	10 (62.5)	

Abbreviations: BCVA = best-corrected visual acuity, CRT = central retinal thickness, DME = diabetic macular edema, IOP = intraocular pressure, logMAR = logarithm of the minimum angle of resolution, RVO = retinal vascular occlusion, SD = standard deviation.

*P-value: Linear fixed and random effect model.

†P-value: Fisher exact test.

The baseline lens status in both the DME and RVO groups showed no statistically significant difference ($P = .701$ in RVO and $P = .119$ in DME). (Tables 4, 5)

3.5. Subgroup analysis: patients with treatment-naïve eyes vs previous intravitreal treatment in the RVO group.

At the 6-month follow-up, the BCVA significantly improved only in the treatment-naïve group ($P = .034$ vs 0.145). The CRT significantly decreased in both groups ($P = .001$, and $P < 0.001$, respectively).

The mean number of injections, percentage of patients who received a second injection, and baseline lens status showed no statistically significant difference between the 2 groups (Table 6).

3.6. Safety of intravitreal Ozurdex® injections

Almost all eyes (79.5%) showed IOP elevation, which was less than or equal to 5 mm Hg compared with the baseline value, and only 5 eyes (12.8%) had IOP elevation ≥ 10 mm Hg. For the nine eyes (20.45%) requiring IOP-lowering medication, IOP was successfully controlled by medication (Table 7). Cataract

Table 4
DME subgroup analysis: number of injections.

	Single injection (N = 8) (mean ± SD)	Reinjections (N = 8) (mean ± SD)	P-value ⁽¹⁾⁻⁽²⁾
BCVA (logMAR)			
At baseline ^a	0.51 ± 0.22	0.76 ± 0.27	
At 1 month ^b	0.33 ± 0.18	0.64 ± 0.25	0.263*
At 3 months ^c	0.44 ± 0.23	0.81 ± 0.25	0.025*
At 6 months ^d	0.48 ± 0.26	0.66 ± 0.21	0.263*
P-value ^(e-d)	a-b, P < 0.001* a-c, P < 0.047* a-d, P = .342*	a-b, P < 0.002* a-c, P = .205* a-d, P = .011*	
CRT (µm)			
At baseline ^a	448.13 ± 89.44	632.00 ± 94.57	
At 1 month ^b	269.00 ± 47.88	354.50 ± 71.88	0.052*
At 3 months ^c	309.75 ± 64.78	526.13 ± 138.01	0.521*
At 6 months ^d	396.88 ± 149.45	340.25 ± 79.35	<0.001*
P-value ^(e-d)	a-b, P < 0.001* a-c, P < 0.001* a-d, P = .153*	a-b, P < 0.001* a-c, P = .003* a-d, P < 0.001*	
Baseline lens status			
Phakic	5 (62.5)	1 (12.5)	0.119†
Pseudophakic	3 (37.5)	7 (87.5)	

Abbreviations: BCVA = best-corrected visual acuity, CRT = central retinal thickness, IOP = intraocular pressure, logMAR = logarithm of the minimum angle of resolution, SD = standard deviation.

*P-value Linear fixed and random effect model.

†P-value Fisher exact test.

Table 5
RVO subgroup analysis: Number of injections.

	Single injection (N = 17) (mean ± SD)	Reinjections (N = 11) (mean ± SD)	P-value ⁽¹⁾⁻⁽²⁾
BCVA (logMAR)			
At baseline ^a	0.82 ± 0.41	0.95 ± 0.40	
At 1 month ^b	0.62 ± 0.36	0.75 ± 0.38	0.869*
At 3 months ^c	0.70 ± 0.36	0.89 ± 0.47	0.326*
At 6 months ^d	0.78 ± 0.39	0.85 ± 0.43	0.285*
P-value ^(a-d)	a-b, P < 0.001* a-c, P = .001* a-d, P = .233*	a-b, P < 0.001* a-c, P = .138* a-d, P = .020*	
CRT (µm)			
At baseline ^a	451.18 ± 128.15	624.00 ± 193.52	
At 1 month ^b	255.71 ± 55.36	268.36 ± 55.26	0.007*
At 3 months ^c	316.94 ± 116.40	593.91 ± 276.16	0.082*
At 6 months ^d	387.88 ± 196.07	265.36 ± 70.74	<0.001*
P-value ^(a-d)	a-b, P < 0.001* a-c, P < 0.001* a-d, P = .092*	a-b, P < 0.001* a-c, P = .519* a-d, P < 0.001*	
Baseline lens status			
Phakic	11(64.7)	6(54.5)	0.701†
Pseudophakic	6(35.3)	5(45.5)	

Abbreviations: BCVA = best-corrected visual acuity, CRT = central retinal thickness, IOP = intraocular pressure, logMAR = logarithm of the minimum angle of resolution, SD = standard deviation.

*P-value: Linear fixed and random effect model.

†P-value: Fisher exact test.

Table 6
RVO subgroup analysis: treatment-naïve eyes and previous intravitreal treatment eyes.

	Treatment-Naïve (N = 9) (mean ± SD)	Previous intravitreal treatment (N = 19) (mean ± SD)	P-value ⁽¹⁾⁻⁽²⁾
BCVA (logMAR)	BCVA (logMAR)	BCVA (logMAR)	BCVA (logMAR)
At baseline ^a	0.99 ± 0.47	0.82 ± 0.37	
At 1 month ^b	0.70 ± 0.41	0.65 ± 0.36	0.028*
At 3 months ^c	0.86 ± 0.54	0.74 ± 0.34	0.343*
At 6 months ^d	0.89 ± 0.53	0.77 ± 0.34	0.359*
P-value ^(a-d)	a-b, P < 0.001* a-c, P < 0.029* a-d, P = .034*	a-b, P < 0.001* a-c, P = .015* a-d, P = .145*	
CRT (µm)			
At baseline ^a	579.67 ± 191.92	490.37 ± 165.55	
At 1 month ^b	296.33 ± 56.71	243.79 ± 45.98	0.642*
At 3 months ^c	512.33 ± 342.99	384.74 ± 158.32	0.628*
At 6 months ^d	371.89 ± 189.36	324.53 ± 160.70	0.596*
P-value ^(a-d)	a-b, P < 0.001* a-c, P = .301* a-d, P = .001*	a-b, P < 0.001* a-c, P = .018* a-d, P < 0.001*	
Number of injections, (mean ± SD)	1.44 ± 0.53	1.37 ± 0.50	0.700*
Numbers of injections, eyes (%)			
One injection	5(55.6)	12(63.2)	1.00†
Two injection	4(44.4)	7(36.8)	
Baseline lens status			
Phakic	7(77.8)	10(52.6)	0.249†
Pseudophakic	2(22.2)	9(47.4)	

Abbreviations: BCVA = best-corrected visual acuity, CRT = central retinal thickness, IOP = intraocular pressure, logMAR = logarithm of the minimum angle of resolution, SD = standard deviation.

*P-value: Linear fixed and random effect model.

†P-value: Fisher exact test.

progression was found in 5 eyes (21.74%) and 2 eyes (8.70%), requiring cataract extraction after the end of this study.

The reinjection group showed a higher percentage than the single injection group in the eyes that required IOP-lowering medication (26.32% vs 16.0%) and cataract progression (28.57% vs 18.75%) but showed no statistically significant difference. (Table 7)

No other serious side effects associated with Ozurdex® injections, such as endophthalmitis, vitreous hemorrhage, retinal detachment, and implant migration, were observed.

4. Discussion

This study evaluated the efficacy of intravitreal Ozurdex® injection in Thai patients with macular edema secondary to retinal vascular diseases in real-life scenarios. Our study showed significant improvements in BCVA and CRT over a period of 6 months after intravitreal Ozurdex® injections. These results confirmed the efficacy of the implant and proved that inflammation is one of the major pathological processes involved in the development of macular edema associated with DR and RVO.^[8]

Table 7
Adverse events.

Peak elevated IOP compared with baseline, eyes (%)	Total 44 eyes		
≤ 5 mmHg	35 (79.5)		
5–10	4 (9.1)		
≥10	5 (11.4)		
Secondary ocular hypertension	Eyes	% (N = 9)	
Control IOP with medication			
1 drug	7	77.78	
2 drugs	1	11.11	
3 drugs	1	11.11	
	Single injection	Reinjection	P-value*
IOP-lowering medication	4/25 (16.0%)	5/19 (26.32%)	0.467
Cataract progression (Phakic eyes)	3/16 (18.75%)	2/7 (28.75%)	0.621

IOP = intraocular pressure.
*P-value: Fisher exact test.

Nagpal et al,^[17] studied the efficacy of single Ozurdex® injections in Indian patients with macular edema within 24 weeks in real-life scenarios. In addition to the CHROME study,^[18] they showed that intravitreal Ozurdex® injections worked much better in the RVO group than in the DME group up until 12 weeks. In the KKESH International Collaborative Retina Study Group,^[19] a single Ozurdex® injection for treating macular edema due to retinal vascular disease significantly improved the BCVA only at 1 month in the DME group and at 3 months in the RVO group. These results are consistent with those of our study, as the same tendency was observed. The improvement in BCVA at 3 months, compared with the baseline values, was greater in the RVO group than in the DME group after a single Ozurdex® injection. However, it should be noted that in our study, there was a high percentage of treatment-naïve patients in the RVO group.

Akincioglu et al^[20] reported that the BCVA showed significant improvement only at 1 month, while the CRT significantly decreased at 4 months in patients with recalcitrant DME. Similarly, the CHROME study^[18] conducted a real-world assessment of Ozurdex® implants in patients with macular edema. It showed that significant anatomical improvement was not correlated with significant improvement in the BCVA in the DME subgroup. In addition, in our study, the BCVA showed significant improvement only at 1 month, while the CRT still significantly decreased at 3 months in the DME group, where almost all the eyes had received multiple intravitreal injections. The anatomical improvement, without significant improvement in BCVA, can be explained by the fact that the retinal tissue in patients with refractory DME may be compromised by irreversible damage.

Nagpal et al^[17] concluded that the BCVA and CRT significantly improved up to 12 weeks after the baseline, and the duration of efficacy was found to be <24 weeks for a single Ozurdex® injection for the treatment of macular edema associated with DR and RVO. Similarly, Li et al^[21] conducted a randomized, sham-controlled, multicenter study to evaluate the efficacy of Ozurdex® injections for the treatment of macular edema associated with RVO in Chinese patients. In addition, the results of the KKESH international collaborative retinal study group^[19] also showed that the visual and anatomical outcomes improved only until 3 to 4 months after a single Ozurdex® injection. These results were similar to our results on the efficacy of a single Ozurdex® injection being significant until 3 months in both the DME and RVO groups. Moreover, Eter et al^[22] suggested that the optimal time for retreatment may be <6 months. Corresponding with our results, the duration of action of Ozurdex® was <6 months, and reinjection may be considered before 6 months in

real-world scenarios. In addition, our study found that eyes with a higher CRT at baseline will experience worsening of the BCVA and CRT at 3 months, and reinjection should be carried out. We postulated that high CRT at baseline represents high severity of disease and inflammatory mediators, poor prognostic factors, and risk of quick recurrence of macular edema.

However, in this study, we found a significant improvement in the BCVA at 6 months in both the DME and RVO groups; this is in contrast with the finding of the previous studies^[17,19–21] that reported no significant improvement at 6 months. This result could be attributed to the fact that nearly half of all eyes in our study underwent reinjection after the 3-month follow-up.

Our results showed that the improvement in BCVA was significantly better in treatment-naïve eyes than in previously treated eyes, but the CRT did not differ between these subgroups in the RVO group. Anatomical improvement does not affect functional outcomes because the previously treated eyes had long-standing macular edema, generally presenting as disruption of the external limiting membrane and IS-OS layer. These results are consistent with those of previous studies on Ozurdex® implants in treatment-naïve or refractory patients with DME, e.g., the study by Wang JK et al^[23] and the IRGREL-DEX study.^[24]

Many previous studies^[15,17–21] have reported the common complications of intravitreal Ozurdex® injections, such as an increase in IOP and cataract progression. In our study, the IOP increased by 23.08% but was successfully controlled with topical medications; no patient required glaucoma surgery. The cataract progression rate was 20.83%. In addition, the reinjection group showed a higher percentage of eyes that required IOP lowering medication and cataract progression. These results were consistent with those of the previous reports.^[15,18–21]

The limitations of this study were its retrospective nature, the small sample size of each group, and the short-term follow-up.

5. Conclusions

In conclusion, intravitreal Ozurdex® injections were effective for the treatment of ME due to RVO and DME, with continuous improvement in the BCVA and CRT over 6 months. Reinjections may be required before 6 months, especially for patients with thick CRT at baseline. Patients with ME due to RVO showed better BCVA improvement and more sustained action of the implant than those with ME due to DR. Additionally, greater improvement was observed in treatment-naïve eyes than in previously treated eyes. The occurrences of increasing IOP and cataract progression were similar to those reported in previous studies.

Acknowledgments

We would like to thank Ms. Parichat Damthongsuk and Ms. Sujinda Damthong for their assistance in data analysis. We would also like to thank Mr. Andrew Jonathan Tait and Editage (www.editage.com) for English language editing.

Author contributions

Conceptualization: Pichai Jirattanasopa, Sakunjanut Jiranoppasakdawong
 Formal analysis: Pichai Jirattanasopa, Sakunjanut Jiranoppasakdawong
 Supervision: Mansing Ratanasukon, Patama Bhurayanontachai, Wantanee Dangboon, Usanee Seepongphun
 Writing-original draft: Pichai Jirattanasopa, Sakunjanut Jiranoppasakdawong
 Writing- review & editing: Pichai Jirattanasopa, Mansing Ratanasukon, Patama Bhurayanontachai, Wantanee Dangboon, Usanee Seepongphun.

References

- [1] Early Treatment Diabetic Retinopathy Study Research Group. Photocoagulation for diabetic macular edema. Early treatment diabetic retinopathy study report no. 1. *Arch Ophthalmol*. 1985;103:1796–806.
- [2] Moss SE, Klein R, Klein BE. The 14-year incidence of visual loss in a diabetic population. *Ophthalmology*. 1998;105:998–1003.
- [3] Central Retinal Vascular Occlusion Study Group. Natural history and clinical management of central retinal vascular occlusion. *Arch Ophthalmol*. 1997;115:486–91.
- [4] Branch Vein Occlusion Study Group. Argon laser photocoagulation for macular edema in branch vein occlusion. The Branch Vein Occlusion Study Group. *Am J Ophthalmol*. 1984;98:271–82.
- [5] Erickson KK, Sundstrom JM, Antonetti DA. Vascular permeability in ocular disease and the role of tight junctions. *Angiogenesis*. 2007;10:103–17.
- [6] Klaassen I, Van Noorden CJ, Schlingemann RO. Molecular basis of the inner blood-retinal barrier and its breakdown in diabetic macular edema and other pathological conditions. *Prog Retin Eye Res*. 2013;34:19–48.
- [7] Kleinman ME, Baffi JZ, Ambati J. The multifactorial nature of retinal vascular disease. *Ophthalmologica*. 2010;224(suppl 1):16–24.
- [8] Wolfensberger TJ, Gregor ZJ. Macular edema-rationale for therapy. *Dev Ophthalmol*. 2010;47:49–58.
- [9] Nauck M, Karakiulakis G, Perruchoud AP, et al. Corticosteroids inhibit the expression of the vascular endothelial growth factor gene in human vascular smooth muscle cells. *Eur J Pharmacol*. 1998;341:309–15.
- [10] Chang-Lin JE, Attar M, Acheampong AA, et al. Pharmacokinetics and pharmacodynamics of a sustained-release dexamethasone intravitreal implant. *Invest Ophthalmol Vis Sci*. 2011;52:80–6.
- [11] Kuppermann BD. Sustained-release dexamethasone intravitreal implant for treatment of diabetic macular edema. *Expert Rev Ophthalmol*. 2011;118:609–14.
- [12] Gillies MC, Lim LL, Campain A, et al. A randomized clinical trial of intravitreal bevacizumab versus intravitreal dexamethasone for diabetic macular edema: the BEVORDEX study. *Ophthalmology*. 2014;121:2473–81.
- [13] Augustin AJ, Kuppermann BD, Lanzetta P, et al. Dexamethasone intravitreal implant in previously treated patients with diabetic macular edema: subgroup analysis of the MEAD study. *BMC Ophthalmol*. 2015;15:150–8.
- [14] Boyer DS, Yoon YH, Belfort R Jr, et al. Three-year, randomized, sham-controlled trial of dexamethasone intravitreal implant in patients with diabetic macular edema. *Ophthalmology*. 2014;121:1904–14.
- [15] Haller JA, Bandello F, Belfort R Jr, et al. Randomized, sham-controlled trial of dexamethasone intravitreal implant in patients with macular edema due to retinal vein occlusion. *Ophthalmology*. 2010;117:1134–1146.e3.
- [16] Haller JA, Bandello F, Belfort R Jr, et al. Dexamethasone intravitreal implant in patients with macular edema related to branch or central retinal vein occlusion twelve-month study results. *Ophthalmology*. 2011;118:2453–60.
- [17] Nagpal M, Mehrotra N, Juneja R, et al. Dexamethasone implant (0.7mg) in Indian patients with macular edema: real-life scenario. *Taiwan J Ophthalmol*. 2018;8:141–8.
- [18] Lam WC, Albani DA, Yoganathan P, et al. Real-world assessment of intravitreal dexamethasone implant (0.7mg) in patients with macular edema: the CHROME study. *Clin Ophthalmol*. 2015;9:1255–68.
- [19] Alshahrani ST, Dolz-Marco R, Gallego-Pinazo R, et al; KKESH International Collaborative Retinal Study Group. Intravitreal dexamethasone implant for the treatment of refractory macular edema in retinal vascular diseases: results of the KKESH international collaborative retinal study group. *Retina*. 2016;36:131–6.
- [20] Akincioglu D, Kucukcilioglu M, Durukan AH, et al. Outcomes of intravitreal dexamethasone implant in the treatment of recalcitrant diabetic macular edema. *Turk J Ophthalmol*. 2017;47:274–8.
- [21] Li X, Wang N, Liang X, et al. Safety and efficacy of dexamethasone intravitreal implant for treatment of macular edema secondary to retinal vein occlusion in Chinese patients: randomized, sham-controlled, multicenter study. *Graefes Arch Clin Exp Ophthalmol*. 2018;256:59–69.
- [22] Eter N, Mohr A, Wachtlin J, et al. Dexamethasone intravitreal implant in retinal vein occlusion: real-life data from a prospective, multicenter clinical trial. *Graefes Arch Clin Exp Ophthalmol*. 2017;255:77–87.
- [23] Wang JK, Huang TL, Hsu YR, et al. Effect of dexamethasone intravitreal implant for refractory and treatment-naïve diabetic macular edema in Taiwanese patients. *J Chin Med Assoc*. 2021;84:326–30.
- [24] Igllicki M, Busch C, Zur D, et al. Dexamethasone implant for diabetic macular edema in naïve compared with refractory eyes: the international retinal group real-life 24-month multicenter study. The IRGREL-DEX study. *Retina*. 2019;39:44–51.