


Obturator pyomyositis and labium majus cellulitis: A case report and literature review

SAGE Open Medical Case Reports
Volume 10: 1–5
© The Author(s) 2022
Article reuse guidelines:
sagepub.com/journals-permissions
DOI: 10.1177/2050313X211063781
journals.sagepub.com/home/sco



Yuko Moriuchi^{1,2} , Tatsuo Fuchigami¹, Chihiro Sugiyama^{1,2},
Satoko Takahashi^{1,2}, Yuko Ohashi¹, Ryuta Yonezawa^{1,2},
Waka Mizukoshi³ and Ichiro Morioka²

Abstract

Pyomyositis is a rare, subacute, deep bacterial infection of the skeletal muscle. When treatment is delayed, pyomyositis causes abscess formation and progresses to sepsis; therefore, its early diagnosis is important. However, the clinical presentation and laboratory findings of pyomyositis are not specific; hence, diagnosis often takes time. We encountered the case of a girl with obturator pyomyositis and redness and swelling of the labium majus, which we considered as potentially important symptoms for distinguishing obturator pyomyositis from septic hip arthritis. An 8-year-old Japanese girl presented to our hospital with fever and right hip pain. On physical examination, she had redness and swelling of the right labium majus and a right limp. She was diagnosed with obturator pyomyositis and labium majus cellulitis with magnetic resonance imaging. Her clinical presentation markedly improved after starting antibiotic therapy with intravenous cefazolin for 2 weeks and oral cefaclor for 1 week. Improvement in the inflammation of the obturator muscle and labium majus was confirmed with follow-up magnetic resonance imaging. She recovered fully with no long-term sequelae. In conclusion, obturator pyomyositis rather than septic hip arthritis should be considered in children with a limp and hip and perineal pain, particularly girls with redness and swelling of the labium majus. In addition, imaging studies, including magnetic resonance imaging, should be performed for early diagnosis.

Keywords

Infectious diseases, obturator pyomyositis, labium majus cellulitis, perineum, septic hip arthritis

Date received: 7 June 2021; accepted: 12 November 2021

Introduction

Pyomyositis, also known as “tropical pyomyositis,” was thought to be endemic to tropical countries. Recently, pyomyositis has been increasingly recognized in temperate climates.^{1–3} However, pyomyositis is unlikely to be considered as an initial diagnosis, and it often takes time to diagnose because of its rarity and nonspecific clinical presentation and laboratory findings. If pyomyositis is diagnosed early, antibiotic therapy is usually sufficient, but if the diagnosis is delayed, it causes abscess formation, and further progression leads to sepsis.^{4,5} Therefore, early diagnosis is important.

Several cases of obturator pyomyositis and/or obturator abscess with inflammation of the perineal zone have been reported.^{6–8} Similarly, we experienced the case of a girl with obturator pyomyositis accompanied by redness and swelling of the labium majus, and we considered that redness and swelling

of the labium majus might be important symptoms for distinguishing obturator pyomyositis from septic hip arthritis.

Case report

A previously healthy 8-year-old Japanese girl presented to the orthopedic clinic with fever, right hip pain, and a right limp a day before admission to our hospital. Viral myositis

¹Department of Pediatrics, IMS Fujimi General Hospital, Saitama, Japan

²Department of Pediatrics and Child Health, Nihon University School of Medicine, Tokyo, Japan

³Department of Radiology, IMS Fujimi General Hospital, Saitama, Japan

Corresponding Author:

Yuko Moriuchi, Department of Pediatrics, IMS Fujimi General Hospital, 1967-1 Tsuruma, Fujimi-shi, Saitama 354-0021, Japan.

Email: moriuchi.yuko@ims.gr.jp



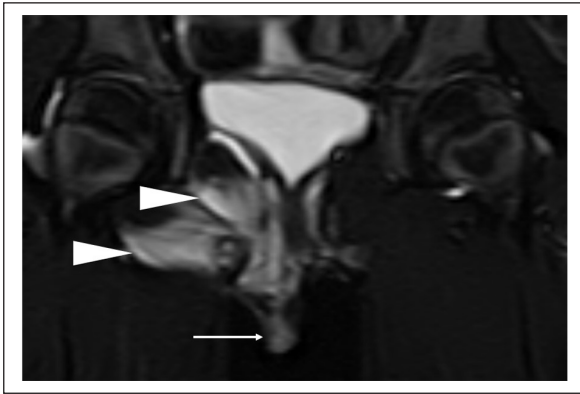

Figure 1. Short tau inversion recovery image, coronal. Diffuse high intensity of the right obturator internus and externus muscles (arrowhead) and the right labium majus (arrow) muscles by pelvic magnetic resonance imaging on hospital day 1.

was suspected, but her clinical presentation did not improve, and she was transferred to our hospital. She had no recent episodes of intensive exercise or local trauma. She had no significant medical or family history. However, she had been diagnosed with acute bronchitis 10 days earlier and had already been treated with oral administration of 12 mg/kg clarithromycin daily for 7 days.

On admission day, her initial physical examination revealed a temperature of 37.9°C and a heart rate of 128 beats/min. She had a stable general condition. Her tonsils were not enlarged and did not contain pus. Chest and abdominal examinations revealed no abnormal findings. The right hip pain worsened with external rotation. There was redness and swelling of the right labium majus, but no signs of vaginal trauma were found. There was no atopic dermatitis or skin abrasions. In addition, neurological, respiratory, cardiovascular, and digestive findings were normal.

Initial laboratory findings revealed a white blood cell (WBC) count of 16,100/ μ L (comprising 80.5% neutrophils), C-reactive protein (CRP) level of 9.17 mg/dL, and creatine phosphokinase (CK) concentration of 51 U/L. Serum electrolytes and renal and liver function were normal. Immunoglobulin and complement levels were normal. Antinuclear antibody and rheumatoid factor test results were negative. *Mycoplasma pneumoniae* antibody titer (particle agglutination method) was <40 times. She was negative for Influenza A/B antigen assayed by rapid antigen detection from a nasopharyngeal swab. Magnetic resonance imaging (MRI) was performed because of the suspicion of septic hip arthritis or labium majus cellulitis. MRI with short tau inversion recovery images showed a high-intensity area of the right obturator internus and externus muscles and right labium majus without any hip joint effusion (Figure 1). From her clinical presentations and MRI imaging findings, she was diagnosed with right obturator pyomyositis and right labium majus cellulitis.

Although she had already received antibiotic therapy before hospitalization, after obtaining blood and vaginal cultures, treatment with 100 mg/kg/day intravenous cefazolin (CEZ) was started, considering *Staphylococcus aureus* as the causative bacterium of obturator pyomyositis. Her fever subsided, right hip pain disappeared, redness and swelling of the right labium majus improved, and she could ambulate on hospital day 3. Laboratory findings showed a decrease in WBC count to 4800/ μ L and CRP level to 1.18 mg/dL on hospital day 5. Although cultures were negative at the time of hospitalization, anti-streptolysin O (ASO) and anti-streptokinase (ASK) titers were high at 811.7 IU/mL and 1:2560, respectively. These titers decreased to ASO 761.9 IU/mL and ASK 1:1,280 10 days later. Thus, *Streptococcus* might have caused pyomyositis, but their association with acute bronchitis could not be ruled out. Therefore, the causative bacteria were unknown. We continued intravenous CEZ administration for 2 weeks because of its therapeutic efficacy. On hospital day 13, follow-up MRI showed a nearly complete improvement of the obturator internus and externus and labium majus inflammation. On hospital day 15, antibiotics were switched from CEZ to oral administration of 30 mg/kg cefaclor (CCL) daily for a week. The patient was discharged on hospital day 16. The total length of antibiotic therapy with CEZ and CCL was 3 weeks. The patient recovered fully without long-term sequelae.

To our knowledge, nine cases (three boys, six girls) of obturator pyomyositis and/or obturator abscess with inflammation of the perineal zone have been reported in the past 30 years according to the PubMed database, including our patient (Table 1).⁶⁻⁸ Four girls had swelling of the labium majus, and two girls and three boys had pain and/or swelling in the perineal zone. During hospitalization, all patients had hip or thigh pain, and seven patients were suspected of having septic hip arthritis. Two patients with abdominal pain or vomiting were suspected of having gastrointestinal infections. However, all of them were finally diagnosed with obturator muscle abscess and/or obturator pyomyositis by imaging studies. MRI was useful in six cases, and computed tomography was useful in three cases. All patients improved by antibiotic therapy without sequelae.

Discussion

Pyomyositis is rarely found in the intrapelvic muscles and even more rarely in the obturator muscle.⁹ The obturator internus muscle arises from the inner aspect of the obturator membrane, runs through the lesser sciatic foramen and toward the rear, bends at the ischial spine at a right angle and toward the front, and inserts into the medial surface of the greater trochanter. Therefore, when the obturator internus muscle abducts and laterally rotates the hip joint, the obturator muscle is damaged easily at the bending site by friction during movement, and bacterial infection occurs easily.⁴ However, the obturator muscle is deeply situated;

Table 1. Summary of obturator muscle abscess/pyomyositis patients with inflammation in the perineal zone.

Patient no., reference	Age/sex (year)	Country	History of trauma or skin abrasions	Symptoms on hospitalization	Physical examination of the perineal zone on the affected side	Presumptive diagnosis	Diagnostic imaging study	Lesion	Causative bacteria	Treatment	Sequelae
1 ^{PR}	8/F	Japan	None	Fever, hip pain, limp	Redness and swelling of the labium majus	Septic hip arthritis, labium majus cellulitis	MRI	OI, OE	Unknown	CEZ, CCL	None
2 ⁶	9/F	USA	None	Fever, hip pain	Swelling of the labium majus	Septic hip arthritis	MRI	OI	<i>S. aureus</i>	CEZ, CEX	None
3 ⁷	6/F	USA	Skin abrasion	Fever, hip pain, abdominal pain, limp	Redness and swelling of the labium majus	Septic hip arthritis	CT	OI	Unknown	MPIPC, CTRX	None
4 ⁷	4/F	USA	Skin abrasion	Fever, groin pain, limp	Swelling of the labium majus	Septic hip arthritis	CT	OI, OE	<i>S. aureus</i>	NFPC, CTX, VCM	None
5 ⁸	11/F	Spain	None	Fever, hip pain, abdominal pain, limp	Tenderness in the perineal zone	Appendicitis, abdominal abscess	CT	OI, adductor magnus	<i>S. aureus</i>	MCIPC, CTX, GM	None
6 ⁸	6/F	Spain	None	Fever, hip pain, limp, vomiting	Tenderness in the perineal zone	Gastrointestinal infection	MRI	OI	Unknown	MCIPC, CTX	None
7 ⁸	10/M	Spain	None	Fever, inguinal pain, limp	Tenderness in the perineal zone	Septic hip arthritis	MRI	OI, adductor magnus	<i>S. aureus</i>	MCIPC	None
8 ⁸	7/M	Spain	None	Fever, thigh pain, abdominal pain, groin pain, limp	Tenderness in the perineal zone	Septic hip arthritis	MRI	OI	<i>S. aureus</i>	MCIPC	None
9 ⁸	11/M	Spain	None	Fever, thigh pain, limp	Tenderness in the perineal zone	Septic hip arthritis	MRI	OI, adductor magnus	<i>S. aureus</i>	MCIPC, CTX	None

CCL: cefaclor; CEX: cephalixin; CEZ: cefazolin; CT: computed tomography; CTRX: ceftriaxone; CTX: cefotaxime; GM: gentamicin; MCIPC: cloxacillin; MPIPC: cefoxitin; MRI: magnetic resonance imaging; NFPC: nafcillin; OE: obturator externus; OI: obturator internus; PR: present report; *S. aureus*: *Staphylococcus aureus*; VCM: vancomycin.

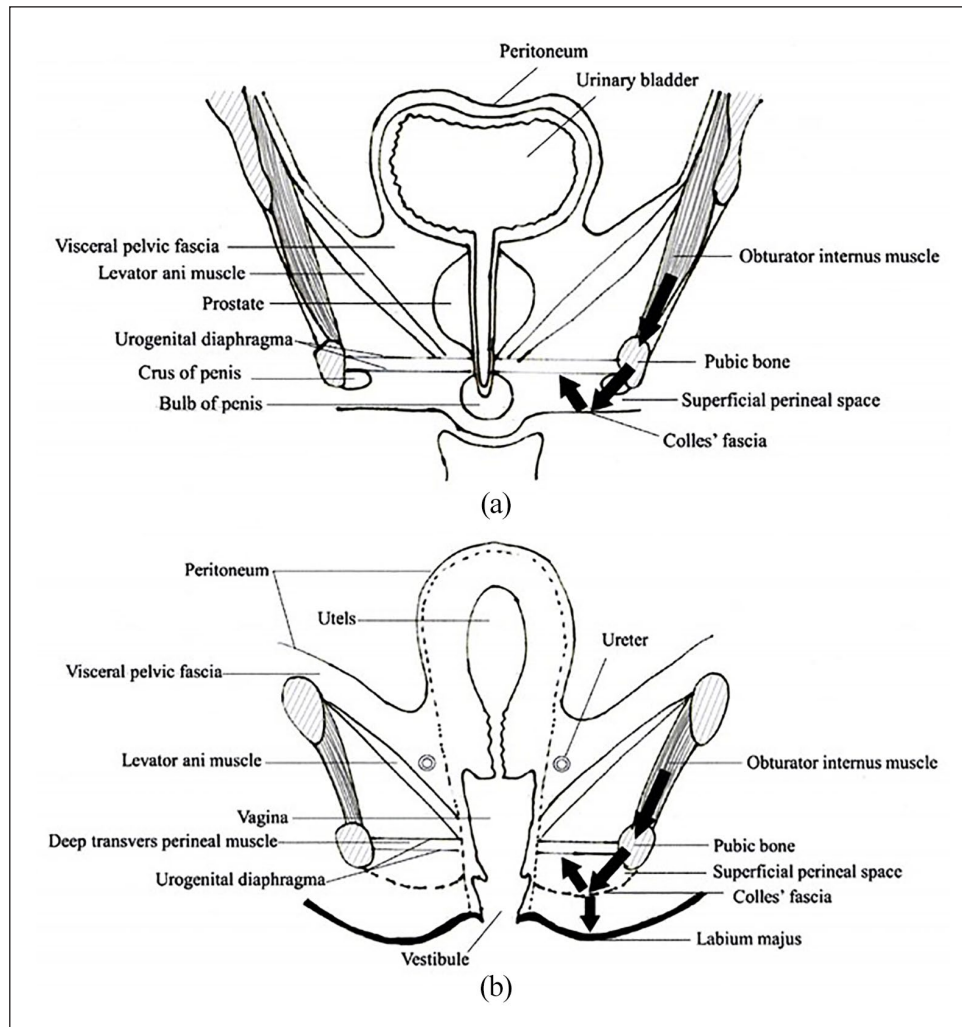


Figure 2. Anatomical location of pelvis (coronal section): (a) male and (b) female. Inflammation in the obturator internus muscle spreads to the pubic bone through the obturator membrane and further spreads to Colles' fascia, which is attached to the subcutaneous tissue of the labium majus or scrotum in the front, the pubic and sciatic branches on the side, and the trailing edge of the urogenital diaphragm and central perineal tendon in the back. This figure is based on a previous study.¹²

therefore, local signs are not apparent. Most patients with obturator pyomyositis present to the hospital with fever, hip pain, thigh pain, and a limp, which are also observed in patients with septic hip arthritis, transient synovitis, and osteomyelitis.^{10,11} In addition, in laboratory findings, the CRP level and erythrocyte sedimentation rate are increased, but this is not specific, and the CK level is often normal unless there is widespread inflammation. Therefore, we suspect that some cases cannot be diagnosed accurately due to the nonspecific clinical presentation and laboratory findings, and above all, the lack of awareness of this condition by general pediatricians.

The pathogenesis of perineal zone inflammation with obturator abscess and/or obturator pyomyositis might be as follows (Figure 2):¹² inflammation in the obturator internus muscle spreads to the pubic bone through the obturator membrane and further spreads to Colles' fascia,

which is attached to the subcutaneous tissue of the labium majus or scrotum in the front, the pubic and sciatic branches on the side, and the trailing edge of the urogenital diaphragm and central perineal tendon in the back. Therefore, if the inflammation of the obturator internus muscle extends to Colles' fascia, inflammation in the perineal zone, redness and swelling of the labium majus, and pain in the perineal zone or around the ischium will also occur. Permission to publish Figure 2 has been obtained from the copyright holder.

Moreover, we suggest the following reasons for the dearth of reports on obturator pyomyositis with inflammation of the perineal zone: (1) there is a possibility that only scrotitis is diagnosed based on the findings of the outer surface without reaching the diagnosis of obturator pyomyositis, which is a primary disease; and (2) obturator pyomyositis is possibly misdiagnosed as septic hip arthritis because of patient com-

plaints, such as fever or hip pain, without physical examination of the perineal zone.^{4,13}

With appropriate antibiotic therapy, the inflammatory lesion usually resolves without sequelae; however, if not treated appropriately, it can relapse¹⁴ or progress to acute compartmental syndrome and osteonecrosis,³ solid-organ impairment, and even septic shock and death.¹⁴ Therefore, if a patient presents with symptoms of inflammation (e.g. pain, redness, and swelling) in the perineal zone, in addition to fever and hip pain, we should consider obturator pyomyositis rather than hip arthritis as a primary disease and perform an MRI study. In particular, redness and swelling of the labium majus on the affected side were considered to be important findings in girls with obturator pyomyositis. Hakim et al.⁷ also found edema of the labium majus on the affected side to be a unique physical finding in their patients. This finding in girls, together with the point tenderness, a mass or bony tenderness on rectal examination,⁸ and swelling in the groin or thigh, should help differentiate obturator abscess, psoas abscess, or pelvic osteomyelitis from hip arthritis.

As a limitation of this report, we only described one case of obturator pyomyositis with redness and swelling of the labium majus; therefore, accumulating more cases is necessary.

Conclusion

Since pyomyositis is no longer an endemic disease in tropical countries, it should be recognized as an important bacterial infection even in temperate regions, such as Japan. Furthermore, in children with limp and hip and perineal pains, especially in girls with redness and swelling of the labium majus, obturator pyomyositis should be considered rather than septic hip arthritis, and imaging studies including MRI should be performed for early diagnosis.

Author contributions

All authors meet the ICMJE authorship criteria. Y.M., C.S., S.T., Y.O., and R.Y. provided medical care and contributed to the preparation of the manuscript. W.M. reported the magnetic resonance imaging findings. Y.M. and T.F. drafted the manuscript. T.F. designed the manuscript outline and provided conceptual advice. I.M. supervised the entire study. All authors read and approved the final manuscript.

Declaration of conflicting interests

The author(s) declared the following potential conflicts of interest with respect to the research, authorship, and/or publication of this article: The authors declare no conflicts of interest related to this study. However, outside the submitted work, Ichiro Morioka has received lecture fees from MSD Co., Ltd., Shionogi Co., Ltd., and AbbVie LLC and study grants from Atom Medical Corp.

Funding

The author(s) received no financial support for the research, authorship, and/or publication of this article.

Ethical approval

Our institution does not require ethical approval for reporting individual cases or case series.

Informed consent

Written informed consent was obtained from a legally authorized representative(s) for anonymized patient information to be published in this article.

ORCID iD

Yuko Moriuchi  <https://orcid.org/0000-0002-7668-9866>

References

1. Comegna L, Guidone PI, Prezioso G, et al. Pyomyositis is not only a tropical pathology: a case series. *J Med Case Rep* 2016; 10(1): 372.
2. Elzohairy MM. Primary pyomyositis in children. *Orthop Traumatol Surg Res* 2018; 104(3): 397–403.
3. Ovadia D, Ezra E, Ben-Sira L, et al. Primary pyomyositis in children: a retrospective analysis of 11 cases. *J Pediatr Orthop B* 2007; 16(2): 153–159.
4. de Bodman C, Ceroni D, Dufour J, et al. Obturator externus abscess in a 9-year-old child: a case report and literature review. *Medicine* 2017; 96(9): e6203.
5. Angelis S, Trellopoulos A, Kondylis AK, et al. Multifocal osteomyelitis localization after pyomyositis in children: importance of timely response. *Cureus* 2019; 11(4): e4463.
6. Viani RM, Bromberg K and Bradley JS. Obturator internus muscle abscess in children: report of seven cases and review. *Clin Infect Dis* 1999; 28(1): 117–122.
7. Hakim A, Graven M, Alsaed K, et al. Obturator internus abscess. *Pediatr Infect Dis J* 1993; 12(2): 166–168.
8. Garc a-a-Mata S, Hidalgo-Ovejero A and Esparza-Estaun J. Primary obturator-muscle pyomyositis in immunocompetent children. *J Child Orthop* 2012; 6(3): 205–215.
9. Bickels J, Sira B, Kessler A, et al. Primary pyomyositis. *J Bone Joint Surg Am* 2002; 84(12): 2277–2286.
10. Chong XL, Ashik M and Arjandas M. Obturator internus pyomyositis in a child: a case report. *Malays Orthop J* 2014; 8(1): 69–70.
11. Tawfik D and Hobson WL. Group A streptococcal pyomyositis in a previously healthy six-year-old girl. *Cureus* 2018; 10(2): e2168.
12. Ito T and Takano H. *Human anatomy-Kaibougaku Kougi*. 2nd ed. Tokyo, Japan: Nanzando, 2001, p. 466 (in Japanese).
13. Khoshhal K, Abdelmotaal HM and Alarabi R. Primary obturator internus and obturator externus pyomyositis. *Am J Case Rep* 2013; 14: 94–98.
14. Ameh EA. Pyomyositis in children: analysis of 31 cases. *Ann Trop Paediatr* 1999; 19(3): 263–265.