



The Impact of Abdominal Liposuction on Abdominally Based Autologous Breast Reconstruction: A Systematic Review

Evalina S. Bond, BS¹ Carol E. Soteropulos, MD¹ Samuel O. Poore, MD, PhD¹

¹Division of Plastic Surgery, Department of Surgery, University of Wisconsin School of Medicine and Public Health, Madison, Wisconsin

Arch Plast Surg 2022;49:324–331.

Address for correspondence Samuel O. Poore, MD, PhD, Division of Plastic Surgery, Department of Surgery, University of Wisconsin School of Medicine and Public Health, 600 Highland Avenue, CSC G5/347, Madison, WI 53792 (e-mail: poore@surgery.wisc.edu).

Abstract

Prior abdominal liposuction can be viewed as a relative or absolute contraindication to abdominally based autologous breast reconstruction given concerns for damaged perforators and scarring complicating intraoperative dissection. This systematic review aims to explore the outcomes of abdominally based breast reconstruction in patients with a history of abdominal liposuction. A Preferred Reporting Items for Systematic Reviews and Meta-Analyses-guided literature search was conducted using PubMed, Scopus, and Web of Science from the earliest available date through June 2020. Deep inferior epigastric perforator, muscle-sparing transverse rectus abdominis musculocutaneous (TRAM), superficial inferior epigastric artery, and pedicled TRAM flaps were included for evaluation. Complications included total or partial flap loss, fat necrosis, seroma, delayed wound healing, and donor site complications. After inclusion criteria were applied, 336 non-duplicate articles were screened, yielding 11 for final review, representing 55 flaps in 43 patients. There was no instance of total flap loss, eight (14.5%) flaps developed partial loss or fat necrosis, three (5.4%) flaps had delayed wound healing, and two (4.6%) patients had donor site complications. Most authors (8/11) utilized some type of preoperative imaging. Doppler ultrasonography was the most used modality, and these patients had the lowest rate of partial flap loss or flap fat necrosis (8%), followed by those without any preoperative imaging (10%). In conclusion, this review supports that patients undergoing abdominally based autologous breast reconstruction with a history of abdominal liposuction are not at an increased risk of flap or donor site complications. Although preoperative imaging was common, it did not reliably decrease complications. Further prospective studies are needed to address the role of imaging in improving outcomes.

Keywords

- ▶ autologous breast reconstruction
- ▶ liposuction
- ▶ suction assisted lipectomy
- ▶ DIEP flap
- ▶ MS-TRAM
- ▶ pedicled TRAM

Abdominally based autologous breast reconstruction is a safe and reliable option for patients following mastectomy, with superior breast satisfaction scores on the Breast-Q as compared with alloplastic reconstruction.^{1,2} A prior histo-

ry of abdominal liposuction can be a relative or absolute contraindication to this kind of reconstruction due to concerns of perforator disruption during the procedure, as well as significant scarring that may complicate the

DOI <https://doi.org/10.1055/s-0042-1748646>.
ISSN 2234-6163.

© 2022. The Korean Society of Plastic and Reconstructive Surgeons. All rights reserved.

This is an open access article published by Thieme under the terms of the Creative Commons Attribution-NonDerivative-NonCommercial-License, permitting copying and reproduction so long as the original work is given appropriate credit. Contents may not be used for commercial purposes, or adapted, remixed, transformed or built upon. (<https://creativecommons.org/licenses/by-nc-nd/4.0/>)

Thieme Medical Publishers, Inc., 333 Seventh Avenue, 18th Floor, New York, NY 10001, USA

dissection.³⁻¹⁰ Some surgeons have proposed alternate flap designs to circumvent these concerns including bipediced flaps,⁵ while others recommend avoiding the abdomen altogether and moving to a less common donor site such as gluteal flaps⁷ or the transverse upper gracilis flap.¹¹ Given that liposuction is one of the most frequently performed aesthetic procedures in western countries,¹² and has become a commonly used adjunctive procedure in patient who have undergone alloplastic breast reconstruction, it is imperative to understand whether these concerns are valid in this group of patients desiring autologous breast reconstruction. Therefore, this review aims to explore the total published literature on the outcomes of abdominally based breast reconstruction in patients with a history of abdominal liposuction.

Methods

A systematic review of abdominally based autologous breast reconstruction outcomes in patients with a history of abdominal liposuction was conducted using the Preferred Reporting Items for Systematic Reviews and Meta-Analyses guidelines (► Fig. 1).¹³ PubMed, Web of Science, and Scopus were searched from the earliest available date through June 2020. Search terms included the following: Deep Inferior Epigastric, DIEP, DIEAP, transverse rectus abdominis musculocutaneous, TRAM, MS-TRAM, free TRAM, pedicled TRAM, breast reconstruction, breast free flap, autologous breast reconstruction, liposuction, and suction assisted lipectomy.

Included articles were comprised of case reports, case series, case-control studies, and cohort studies which reported outcomes for women with a history of abdominal liposuction prior to abdominally based breast reconstruc-

tion. Deep inferior epigastric perforator (DIEP) flaps, superficial inferior epigastric artery (SIEA) flaps, and free and pedicled transverse rectus abdominis musculocutaneous (TRAM) flaps were included, as well as all types of anastomosis and recipient vessels. Imaging studies focused on assessing flap perforator vessels following liposuction were reviewed and included for discussion. Patients with a history of other abdominal surgery in addition to liposuction were not excluded as approximately 50% of women presenting for autologous breast reconstruction have abdominal scars from prior surgeries.¹⁴ Exclusion criteria included articles that did not state clinical outcomes, non-English language studies, cadaver studies, and animal models. After screening article titles for relevance, inclusion and exclusion criteria were applied to abstracts and then to full-text articles. Flap complications such as total flap loss, partial flap loss, flap fat necrosis, seroma, and delayed wound healing, as well as donor site complications were recorded. Given lack of clearly defined distinctions between flap fat necrosis and partial flap loss, these two complications were combined into one category. In studies describing outcomes of various flaps, those from donor sites other than the abdomen were removed when possible. Literature search and article selection was performed independently by two study authors (E.S.B. and C.E.S.) and then compared for final article inclusion.

Results

A total of 470 records were identified through database searching with the above listed terms, with 336 citations remaining following removal of duplicates. Titles were screened for relevance resulting in 67 citations. Inclusion and exclusion criteria were applied to these abstracts and 11 full-text articles were assessed for eligibility, all of which met

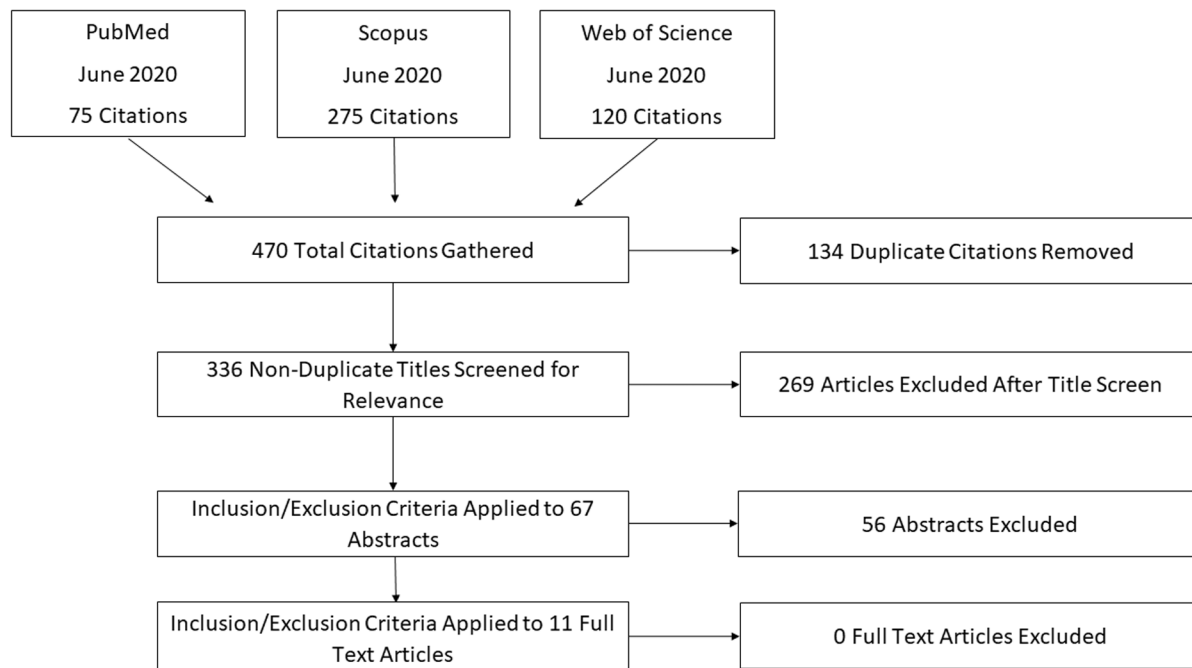


Fig. 1 Preferred Reporting Items for Systematic Reviews and Meta-Analyses (PRISMA) diagram detailing methodology of systematic review.

criteria and were included in this review (►Fig. 1). Of these, one article was a retrospective cohort study, while the other 10 were either case reports or case series (►Table 1). In total, 43 patients and 55 flaps were included. Reconstruction types included: 35 DIEP flaps, 12 free TRAM flaps, 5 pedicled TRAM flaps, 2 SIEA flaps, and 1 superior gluteal artery perforator (SGAP) flap. The range of time between liposuction and flap reconstruction in the articles where this was reported was 1.3 to 20 years (►Table 1).^{6,9,10,15-18}

Six articles specified total follow-up period with a range of 4 months to 9 years (►Table 1). All 11 included articles reported 100% flap survival. Of the total 54 abdominally based flap reconstructions, 9 flaps in 8 patients developed fat necrosis or partial flap loss, 1 flap developed a seroma, and 2 flaps had delayed healing (►Table 2). No other flap complications were reported in these studies. A minority (2/11) of studies reported donor site complications, accounting for two patients total.^{17,19} A summary of all complication findings are presented in ►Table 3.

A majority (8/11) articles utilized preoperative imaging in all patients (►Fig. 2).^{5,10,15-20} Among these studies, Doppler was the most commonly used modality, followed by computed tomography angiography (CTA).^{5,10,15,17-19} Two studies used magnetic resonance angiography (MRA) for three patients,^{10,16} and one study used methylene blue angiography in one patient.²⁰ Additionally, one article utilized intraoperative imaging with indocyanine green angiography (ICGA) in five patients (six flaps) in addition to preoperative Doppler.¹⁹

To evaluate the utility of preoperative imaging, articles with and without the use of preoperative imaging with any modality were compared. The imaging modalities included in this analysis are Doppler ultrasonography (US), CTA, MRA, and methylene blue angiography. Additionally, Doppler US alone, being the most commonly used modality, was also compared with the groups with and without any preoperative imaging. Doppler US alone had the lowest rate of partial flap loss or flap fat necrosis at 8%, while no imaging was second at 10%, and any preoperative imaging modalities (Doppler US alone, CTA alone, MRA alone, methylene blue angiography alone, or combined Doppler US and CTA) was third at 16% (►Table 4). The rates of flap delayed wound healing demonstrated higher rates in patients who did not undergo any type of preoperative imaging (20%), as compared with patients who underwent Doppler US alone (0%), and those who underwent any type of preoperative imaging (3%). Flap seroma and donor site complication rates did not range widely across the three groups (►Table 4).

Discussion

Impact of Prior Liposuction on Abdominal Flap Perfusion

In the current literature, some consider liposuction to be a relative or absolute contraindication to abdominally based breast reconstruction as it may damage perforator vessels, increasing the risk of flap ischemic complications.³⁻¹⁰ One of the most notable studies was performed in 1998 by İnceoğlu

et al, in which color Doppler US was used in 10 patients to evaluate the number and location of perforators before and after abdominal liposuction. Results demonstrated a 57.8% reduction in the number of perforators present at 2 weeks postliposuction, without improvement at 3 months postliposuction.²¹ This lack of regenerative potential contrasts with a similarly conducted study performed in 2001 by Ribuffo et al, which demonstrated 100% regeneration of all perforators 6 months after abdominoplasty in 10 women.²² Additionally, in 2005, Salgarello et al used color and pulse-wave Doppler in six patients before and 6 months after liposuction and found that all preoperatively identified perforators could be found in the same location postoperatively without significant differences in diameter or blood flow.⁸ These contrasting results may be explained by the 3-month difference in follow-up and reimaging intervals, supporting an argument for delaying abdominally based reconstruction in patients who have undergone liposuction at the donor site until they are at least 6 months out from the procedure, potentially allowing the damaged perforators time to regenerate.¹⁶

Of the seven articles that gave the length of time between a patient's most recent liposuction procedure and breast reconstruction surgery, 1.3 years was the shortest interval reported.^{6,9,10,15-18} Therefore, the question of whether or not time intervals less than 6 months between liposuction and reconstruction yields higher rates of ischemic flap complications cannot be explored. However, the need for a greater than 6-month interval does not seem well supported by more contemporary studies. Instead, recent articles have demonstrated that liposuction does not damage perforator vessels in a clinically significant way, meaning that any time interval between the procedures may be unnecessary.²³⁻²⁵ In a 2017 study, Akdeniz Doğan et al explored the impact of flap elevation and liposuction on flap perfusion by raising abdominally based perforator flaps in nine patients undergoing classic abdominoplasty.²³ They then used combined laser-Doppler spectrophotometry to evaluate perfusion in the raised flap, performed liposuction of the flap, and then reevaluated the tissue with the laser-Doppler spectrophotometer before removing the tissue to complete the abdominoplasty. They found that blood flow, velocity, capillary oxygen saturation, and the relative amount of hemoglobin in each zone of the raised flap did not significantly differ before and after the use of liposuction.²³

Importantly, liposuction of the abdominal flap is a common component of abdominoplasty (lipoabdominoplasty), and the impact of liposuction on flap perfusion has been extensively studied and debated in the literature. A 2019 meta-analysis of complication rates between conventional abdominoplasty and lipoabdominoplasty in 14,061 patients found that lipoabdominoplasty had equivalent rates of perfusion-related complications, deep vein thrombosis, and scar deformity, as well as significantly lower rates of hematoma and seroma formation.²⁵ Further, a 2018 study by Brauman et al stated that in the clinical observation of 593 patients undergoing liposuction-assisted abdominoplasty, liposuction deep to Scarpa's fascia did not disrupt perforating

Table 1 Details of all publications examined in this systematic review

Author	Study type	Patients	Flaps	Flap types	Age	Years since liposuction	Imaging use	Other abdominal surgeries	Months follow-up	Flap survival	Flap complications	Donor site complications
Casey et al 2015 ¹⁹	Retrospective cohort	11	13	13 DIEP	52.1 (36–67)	NR	Preoperative Doppler US or CTA in all patients. 5 of 11 patients evaluated with intraoperative ICG	NR	22	100%	Partial flap loss or fat necrosis in 5 flaps (in 4 patients) in the non-ICG group	One abdominal wound complication in the non-ICG group
De Frene et al 2006 ¹⁵	Case series	6	6	5 DIEP 1 SCAP	51 (41–58)	6.3 (3.5–11)	Preoperative Doppler US in all patients	NR	5.25 (4–7)	100%	None	None
Farid et al 2014 ¹⁶	Case report	2	2	2 DIEP	55.5 (54–57)	≥ 1.3	Preoperative CTA or MRA in all patients	NR	NR	100%	None	None
Godfrey and Godfrey 1994 ⁴	Case report	1	2	2 pedicled TRAM	56	NR	None	NR	NR	100%	None	None
Hamdi et al 2007 ⁵	Case series	3	3	3 bipedicled DIEP	NR	NR	Preoperative Doppler US in all patients. Additional preoperative spiral CT in later patients	NR	NR	100%	"Subclinical" fat necrosis in one flap	None
Hess et al 2004 ⁹	Case report	2	2	2 pedicled TRAM	42 (40–44)	8 (7–9)	None	Patient 1: Appendectomy, cesarean section Patient 2: Tubal ligation	5 (4–6)	100%	None	None
Jandali et al 2010 ⁶	Case series	3	6	1 DIEP 5 MS-TRAM	46 (42–49)	11 (9–14)	None	NR	NR	100%	One patient with delayed healing of mastectomy flaps. One patient with minimal fat necrosis in one flap	None
Karanas et al 2003 ¹⁷	Case report	3	5	5 MS-TRAM	63.3 (60–66)	≥ Several years	Preoperative Doppler US in all patients	NR	NR	100%	One patient with a small amount of fat necrosis in zone 4	One patient with small area of fat necrosis, healed without intervention
Kim et al 2004 ¹⁸	Case report	2	2	2 MS-TRAM	57 (54–60)	8 (6–10)	Preoperative color Doppler US in all patients	Patient 1: Cesarean section ×2	9.5 (7–12)	100%	None	None
May et al 1999 ²⁰	Case report	1	1	1 pedicled TRAM	61	NR	Preoperative angiography with methylene blue directly into the DIEA	NR	24	100%	None	None
Zavlin et al 2018 ¹⁰	Case series	9	13	11 DIEP 2 SIEA	47.7 (33–64)	2–20	Preoperative Doppler US, CTA, or MRA in all patients	NR	14.4 (6–115.2)	100%	One patient with breast seroma and delayed healing requiring drainage and closure. One patient with fat necrosis excised during revision	None

Abbreviations: CTA, computed tomography angiography; DIEA, deep inferior epigastric artery; DIEP, deep inferior epigastric perforator; ICG, indocyanine green; MRA, magnetic resonance angiography; MS-TRAM, muscle sparing free transverse rectus abdominis myocutaneous; NR, not reported; SCAP, superior gluteal artery perforator; SIEA, superior inferior epigastric artery; TRAM, transverse rectus abdominis myocutaneous; US, ultrasound.

Table 2 Complication rates of flap and donor site as reported by individual study

Author	Total flap loss ^a	Partial flap loss or fat necrosis ^a	Flap seroma ^a	Flap delayed wound healing ^a	Donor site complications ^b
Casey et al 2015 ¹⁹	0 (0%)	5 (38%)	0 (0%)	0 (0%)	1 (9%)
De Frene et al 2006 ¹⁵	0 (0%)	0 (0%)	0 (0%)	0 (0%)	0 (0%)
Farid et al 2014 ¹⁶	0 (0%)	0 (0%)	0 (0%)	0 (0%)	0 (0%)
Godfrey and Godfrey 1994 ⁴	0 (0%)	0 (0%)	0 (0%)	0 (0%)	0 (0%)
Hamdi et al 2007 ⁵	0 (0%)	1 (33%)	0 (0%)	0 (0%)	0 (0%)
Hess et al 2004 ⁹	0 (0%)	0 (0%)	0 (0%)	0 (0%)	0 (0%)
Jandali et al 2010 ⁶	0 (0%)	1 (17%)	0 (0%)	2 (33%)	0 (0%)
Karanas et al 2003 ¹⁷	0 (0%)	1 (20%)	0 (0%)	0 (0%)	1 (33%)
Kim et al 2004 ¹⁸	0 (0%)	0 (0%)	0 (0%)	0 (0%)	0 (0%)
May et al 1999 ²⁰	0 (0%)	0 (0%)	0 (0%)	0 (0%)	0 (0%)
Zavlin et al 2018 ¹⁰	0 (0%)	0 (0%)	1 (11%)	1 (11%)	0 (0%)

^aComplications reported by flap number.

^bComplications reported by patient number.

Table 3 Compiled complication rates in all patients with previous liposuction of the donor site

	N	(%)
Flap complications		
Total flap loss	0	(0)
Partial flap loss or fat necrosis	8	(14.5)
Flap seroma	1	(1.8)
Flap delayed healing	3	(5.4)
Donor site complications	2	(4.7)

vessels as their flexibility allows them to be pushed aside during the procedure, thereby avoiding ischemic complications of the remaining tissue.²⁴ This lack of increased ischemic complications with the addition of abdominal liposuction suggests that the inclusion of liposuction does not worsen flap vascularity in any clinically significant way.

Although no flap losses were reported in the studies reviewed, ischemic complications did occur including nine incidences of partial flap loss or fat necrosis in eight patients. However, to our knowledge, there is no study that prospectively compared outcomes in women with and without a history of liposuction, undergoing abdominal based breast reconstruction. Therefore, it is unknown if this patient population has a higher rate of fat necrosis. In this review, 14.5% of flaps, excluding the single SGAP flap, developed some level of partial flap loss or fat necrosis. In comparison, a review of 70 articles addressing outcomes in all abdominally based breast reconstructions by Khansa et al demonstrated an average fat necrosis rate per flap of 11.3% across all flap reconstructions.²⁶ Specifically, 14.4% in DIEP, 6.9% in muscle-sparing TRAM, 8.1% in SIEA, and 12.3% in pedicled TRAM

flaps.²⁶ Though we were not able to perform a meta-analysis on our data set, notably the rates are not significantly different from the 14.5% we see in this review.

Use of Preoperative Imaging

Within the scope of this review, the use of one or more preoperative imaging modalities did not significantly reduce complications. In fact, patients who had undergone any type of preoperative imaging including Doppler US, CTA, MRA, methylene blue angiography, or a combination of these modalities had increased rates of both partial flap loss and fat necrosis and delayed wound healing when compared with those who underwent Doppler US alone and those without any preoperative imaging (→Table 4). However, this finding is likely confounded by selection bias in that additional imaging may have been ordered in cases of concerning clinical history or exam findings, predisposing them to these complications.

Importantly, however, all patients who had undergone preoperative imaging demonstrated favorable anatomy, without any damaged or unusable perforators visualized to exclude them from abdominally based reconstruction. Therefore, the judicious use of preoperative imaging may skew the outcomes of this review as patients with unfavorable preoperative imaging may have been excluded from abdominally based reconstruction. Many authors agree that preoperative imaging of the donor site blood supply is mandatory in patients who have undergone prior liposuction.^{5,15,19,22} In this review, 8 of the 11 included studies used at least one type of imaging modality in all their patients, with the most common being Doppler US and CTA.

Casey et al found that in a group of 11 patients with a previous history of abdominal liposuction undergoing 13 DIEP flaps, the use of intraoperative ICGA decreased the rates

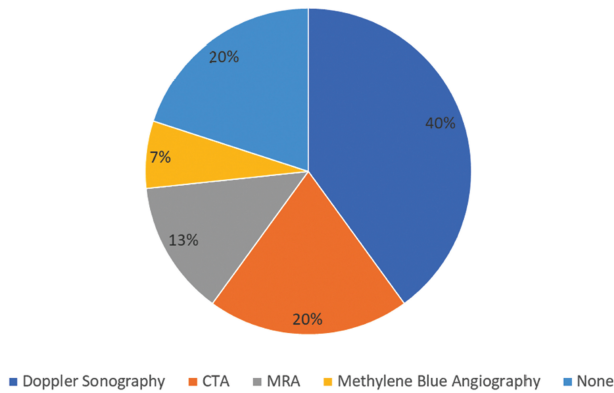


Fig. 2 Pie chart illustrating the frequency of use for each preoperative imaging modality.

of partial flap loss and flap fat necrosis from 71.4 to 0%. Additionally, all patients had a CTA which demonstrated excellent perforators in all patients. Despite this potentially useful finding, this study was limited due to the fact that the two groups (ICG and non-ICG) were separated by time (non-ICG first), giving the operating team more experience in free flap reconstruction before operating on the study group with the help of ICGA. Additionally, the study group was on average 8 years younger than the control group, making it more likely that the controls had higher rates of comorbidities that may have complicated wound healing.¹⁹

May et al describe evaluation of abdominal perfusion with intra-DIEA methylene blue angiography.²⁰ They argue for the utility of this method by stating that a well-perfused skin paddle will immediately show staining following injection of the dye, whereas poorly perfused tissue will show sluggish staining. While this method of analysis has obvious drawback including imprecise distinctions for well and poorly perfused tissue and inability to determine location or course of perforator vessels, it does offer a well-demarcated tissue area that can be taken into account for flap design, making this method a reasonable option for some high-risk patients undergoing TRAM reconstruction.²⁰

Overall, many of the articles included in this review note the importance of using preoperative or intraoperative im-

aging for perforator evaluation in this patient population as stated above. However, within the scope of this review, the use of any typical imaging modality did not obviously improve complication rates compared with patients who did not receive preoperative imaging, though overall complication rates were relatively low in all groups (► **Table 4**). Further research is needed to determine whether the use of preoperative imaging impacts outcomes in this patient population.

Limitations

The major limitation to this study is the low number of patients and flap reconstructions that could be included for evaluation, as well as the level of evidence of the reviewed studies, with the majority being case series. Additionally, the data provided from the studies that met inclusion criteria was not uniformly collected and reported, limiting this analysis to a systematic review of the available data at this time rather than a meta-analysis. In the future, with more homogeneous studies to analyze and a higher level of evidence to review, a meta-analysis could be conducted which could ultimately improve upon the results of this study.

The impact of preoperative imaging in this patient population is unable to be adequately assessed as a result of the selection bias inherent in the study design. Additional preoperative imaging may be ordered in cases of concerning clinical history or exam findings which predispose these patients to complications. On the other hand, intraoperative SPY angiography performed in cases of questionable perfusion has been shown to reduce complication rate in those patients who had this advanced imaging performed intraoperatively. A prospective, controlled trial would be needed to better understand the impact of preoperative imaging on patients presenting for abdominally based breast reconstruction after abdominal liposuction. This type of trial would also provide data on the timing of breast reconstruction after liposuction and how this may or may not impact flap complications.

Additionally, as with any surgical procedure, varying surgical techniques and tools including cannula size, aspirate volume, and use of tumescent among others were included together in this review, making it difficult to know how these aspects may play a role in patient

Table 4 The impact of type of preoperative imaging performed on flap and donor site complication rates

Preoperative imaging type	No. of articles	No. of patients	No. of flaps	Total flap loss ^a	Partial flap loss or flap fat necrosis ^a	Flap seroma ^a	Delayed flap wound healing ^a	Donor site complications ^b
None	3	6	10	0 (0%)	1 (10%)	0 (0%)	2 (20%)	0 (0%)
Doppler US	3	11	13	0 (0%)	1 (8%)	0 (0%)	0 (0%)	1 (9%)
All imaging modalities	7	33	38	0 (0%)	8 (21%)	1 (3%)	1 (3%)	2 (3%)

Abbreviation: US, ultrasound.

^aComplications given as a percentage of the number of flap reconstructions impacted.

^bComplications given as a percentage of the number of patients impacted.

outcomes. Finally, three patients within this review were reported to have undergone previous abdominal surgeries in addition to prior liposuction and although none of these patients experienced flap complications it is unclear to what extent prior surgery in addition to liposuction may also impact outcomes.

Conclusion

Abdominal liposuction is a common procedure which is considered by some surgeons to be a relative or absolute contraindication to abdominally based breast reconstruction. This systematic review examined 11 studies focusing on flap outcomes and complications to address the question of safety of abdominally based free tissue transfer in women with history of abdominal liposuction. The majority of studies utilized at least one type of preoperative imaging for perforator evaluation, most commonly either Doppler US or CTA. Although the current body of literature on this subject is limited in level of evidence and patient number, we report no published incidence of total flap loss in patients with a history of abdominal liposuction and low overall flap and donor site complication rates. Although this systematic review demonstrates that abdominally based breast reconstruction in patients who have undergone abdominal liposuction is safe and without significantly increased risk of flap or donor site complications, multi-institution, prospective studies on a larger number of women would provide significant clarity to this commonly encountered clinical scenario in microsurgical breast reconstruction.

Author Contributions

E.S.B.: Concept, design, data collection, data analysis, and manuscript drafting. C.E.S.: Concept, design, data analysis, manuscript drafting, and revision. S.O.P.: Concept, design, data analysis, and manuscript revision.

Funding

None.

Conflict of Interest

None declared.

References

- Toyserkani NM, Jørgensen MG, Tabatabaeifar S, Damsgaard T, Sørensen JA. Autologous versus implant-based breast reconstruction: a systematic review and meta-analysis of Breast-Q patient-reported outcomes. *J Plast Reconstr Aesthet Surg* 2020;73(02):278–285
- Eltahir Y, Krabbe-Timmerman IS, Sadok N, Werker PMN, de Bock GH. Outcome of quality of life for women undergoing autologous versus alloplastic breast reconstruction following mastectomy: a systematic review and meta-analysis. *Plast Reconstr Surg* 2020;145(05):1109–1123
- Avashia YJ, Desrosiers AE III, Flores JJ. A second superior gluteal artery perforator flap with previous liposuction to the same breast after resection of initial SGAP breast reconstruction due to cancer recurrence. *Microsurgery* 2012;32(06):482–484
- Godfrey PM, Godfrey NV. Transverse rectus abdominis musculocutaneous flaps after liposuction of the abdomen. *Ann Plast Surg* 1994;33(02):209–210
- Hamdi M, Khuthaila DK, Van Landuyt K, Roche N, Monstrey S. Double-pedicle abdominal perforator free flaps for unilateral breast reconstruction: new horizons in microsurgical tissue transfer to the breast. *J Plast Reconstr Aesthet Surg* 2007;60(08):904–912
- Jandali S, Nelson JA, Wu LC, Serletti JM. Free transverse rectus abdominis myocutaneous flap for breast reconstruction in patients with prior abdominal contouring procedures. *J Reconstr Microsurg* 2010;26(09):607–614
- LoTempio MM, Allen RJ. Breast reconstruction with SGAP and IGAP flaps. *Plast Reconstr Surg* 2010;126(02):393–401
- Salgarello M, Barone-Adesi L, Cina A, Farallo E. The effect of liposuction on inferior epigastric perforator vessels: a prospective study with color Doppler sonography. *Ann Plast Surg* 2005;55(04):346–351
- Hess CL, Gartside RL, Ganz JC. TRAM flap breast reconstruction after abdominal liposuction. *Ann Plast Surg* 2004;53(02):166–169
- Zavlin D, Jubbal KT, Ellsworth WA IV, Spiegel AJ. Breast reconstruction with DIEP and SIEA flaps in patients with prior abdominal liposuction. *Microsurgery* 2018;38(04):413–418
- Saint-Cyr M, Shirvani A, Wong C. The transverse upper gracilis flap for breast reconstruction following liposuction of the thigh. *Microsurgery* 2010;30(08):636–638
- Bellini E, Grieco MP, Rapisio E. A journey through liposuction and liposculpture: Review. *Review Ann Med Surg (Lond)* 2017;24:53–60
- Moher D, Liberati A, Tetzlaff J, Altman DG/PRISMA Group. Preferred reporting items for systematic reviews and meta-analyses: the PRISMA statement. *PLoS Med* 2009;6(07):e1000097
- Wes AM, Cleveland E, Nelson JA, et al. Do prior abdominal surgeries increase complications in abdominally based breast reconstructions? *Ann Plast Surg* 2015;75(05):526–533
- De Frene B, Van Landuyt K, Hamdi M, et al. Free DIEAP and SGAP flap breast reconstruction after abdominal/gluteal liposuction. *J Plast Reconstr Aesthet Surg* 2006;59(10):1031–1036
- Farid M, Nicholson S, Kotwal A, Akali A. DIEP breast reconstruction following multiple abdominal liposuction procedures. *Eplasty* 2014;14:e47
- Karanas YL, Santoro TD, Da Lio AL, Shaw WW. Free TRAM flap breast reconstruction after abdominal liposuction. *Plast Reconstr Surg* 2003;112(07):1851–1854
- Kim JY, Chang DW, Temple C, Beahm EK, Robb GL. Free transverse rectus abdominis musculocutaneous flap breast reconstruction in patients with prior abdominal suction-assisted lipectomy. *Plast Reconstr Surg* 2004;113(03):28e–31e
- Casey WJ III, Connolly KA, Nanda A, Rebecca AM, Perdakis G, Smith AA. Indocyanine green laser angiography improves deep inferior epigastric perforator flap outcomes following abdominal suction lipectomy. *Plast Reconstr Surg* 2015;135(03):491e–497e
- May JW Jr, Silverman RP, Kaufman JA. Flap perfusion mapping: TRAM flap after abdominal suction-assisted lipectomy. *Plast Reconstr Surg* 1999;104(07):2278–2281
- İnceoğlu S, Özdemir H, İnceoğlu F, Demir H, Önal B, Çelebi C. Investigation of the effect of liposuction on the perforator vessels using color Doppler ultrasonography. *Eur J Plast Surg* 1998;21(01):38–42
- Ribuffo D, Marcellino M, Barnett GR, Houseman ND, Scuderi N. Breast reconstruction with abdominal flaps after abdominoplasties. *Plast Reconstr Surg* 2001;108(06):1604–1608
- Akdeniz Doğan ZD, Saçak B, Yalçın D, Pilancı Ö, Tuncer FB, Çelebilier Ö. Assessment of tissue perfusion following conventional

- liposuction of perforator-based abdominal flaps. *Arch Plast Surg* 2017;44(02):109–116
- 24 Brauman D, van der Hulst RRWJ, van der Lei B. Liposuction assisted abdominoplasty: an enhanced abdominoplasty technique. *Plast Reconstr Surg Glob Open* 2018;6(09):e1940
- 25 Xia Y, Zhao J, Cao DS. Safety of lipoabdominoplasty versus abdominoplasty: a systematic review and meta-analysis. *Aesthetic Plast Surg* 2019;43(01):167–174
- 26 Khansa I, Momoh AO, Patel PP, Nguyen JT, Miller MJ, Lee BT. Fat necrosis in autologous abdomen-based breast reconstruction: a systematic review. *Plast Reconstr Surg* 2013;131(03):443–452