




# Imaging to Identify Delayed Mesh Infection Masquerading as Acute Appendicitis

Abhishek Mishra<sup>1</sup> Ankit Mathur<sup>1</sup> Shalendra Singh<sup>2</sup>  Anushree Mishra<sup>3</sup>

<sup>1</sup>Department of Radiology, Command Hospital (NC), Udhampur, Jammu and Kashmir, India

<sup>2</sup>Department of Anaesthesiology and Critical Care, Command Hospital (NC), Udhampur, Jammu and Kashmir, India

<sup>3</sup>Department of Ophthalmology, Command Hospital (NC), Udhampur, Jammu and Kashmir, India

Address for correspondence Shalendra Singh, DM, DrNB, Department of Anaesthesiology and Critical Care, Command Hospital (NC), Udhampur 182101, Jammu and Kashmir, India (e-mail: drsinghafmc@gmail.com).

Indian J Radiol Imaging 2024;34:571–572.

There are significant differences in the way that appendicitis is investigated globally. Most of this variation is balanced against concerns regarding computed tomography (CT) radiation exposure, sensitivity to ultrasonography (USG) diagnosis, and imaging delays. We present a case of delayed mesh infection in a patient who was clinically diagnosed with acute appendicitis and later diagnosed with mesh infection by radio imaging.

A 36-year-old male with no comorbidities reported high-grade fever, episodes of vomiting, and abdominal pain in the right iliac fossa for the past 2 days. The patient underwent surgery laparoscopically for a right inguinal hernia 8 months before admission. The abdomen was soft, with rebound tenderness in the right lower quadrant. Hematological parameters revealed a raised leucocyte count of 12,000 cells/mm<sup>3</sup> and a raised C-reactive protein level of 8.6 mg/dL. He was admitted with a clinical diagnosis of acute appendicitis and was started on intravenous ceftriaxone, metronidazole, and amikacin. An urgent appendectomy was planned. However, an urgent USG of the abdomen to confirm the diagnosis showed poorly defined hypoechoic soft tissue thickening along with low-level echoes and minimal thick collection around the hernial mesh in the anterior abdominal wall in the right lower quadrant (→**Fig. 1A**). There was no peri-enteric inflammation. In view of these sonological findings, the decision for urgent appendectomy was deferred, and contrast-enhanced CT of the abdomen revealed enhanced heterogeneous linear soft tissue thickening immediately related to the underlying mesh (→**Fig. 1B**). The appendix was delineated normally. Thus, a solid radiological suspicion of hernial mesh infection was raised. With these

results, it was decided to continue managing the patient conservatively with antibiotics and symptomatic treatment. He became afebrile on the 4th day of his hospital stay and was discharged on the 14th day.

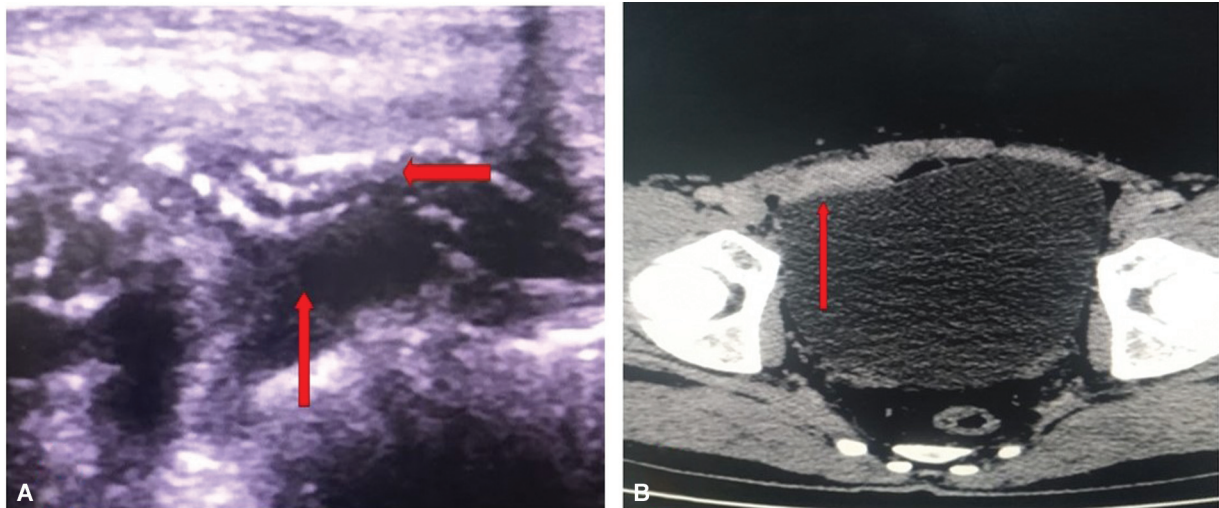Problems such as hernia recurrence, mesh migration or mesh infection, and neuralgia at the surgical site are known as delayed or late complications. Surgical site infection after hernia repair occurs in approximately 3 to 5% of patients, and the risk of deep surgical site infection is much lower, ranging from 0.3 to 0.5%.<sup>1</sup> Hernial mesh infection is an uncommon complication, and its prevalence is unknown. It may appear in the early postoperative period or months or years after surgery. Delayed onset of deeper infections involving the mesh has been recorded in the literature, even years after surgery. Any deviation from the standard method of asepsis during surgery or possibly bacterial transgression from the gut or secondary to sepsis are the many possible explanations for mesh infections.<sup>2</sup> The nature of the synthetic material used to make a mesh, the size of the filament pores, or the type of suture material employed were all addressed in recent studies as probable causes.<sup>3</sup> Mesh infections may present with infected loculated collections, abscesses, sinus formation, or an enteric or a cutaneous fistula. There is evidence of late-onset mycobacterial mesh infections, which are followed by secondary infections that result in pus discharge but the absence of any tuberculosis symptoms excluded that. Among these methods, wound therapy with negative pressure is helpful for encouraging healing.<sup>4</sup>

Imaging diagnostics, clinical scores, inflammatory serum markers, and laboratory test results should all be used to diagnose appendicitis based on the clinical context. With a

article published online  
March 23, 2024

DOI <https://doi.org/10.1055/s-0044-1781469>.  
ISSN 0971-3026.

© 2024. Indian Radiological Association. All rights reserved.  
This is an open access article published by Thieme under the terms of the Creative Commons Attribution-NonDerivative-NonCommercial-License, permitting copying and reproduction so long as the original work is given appropriate credit. Contents may not be used for commercial purposes, or adapted, remixed, transformed or built upon. (<https://creativecommons.org/licenses/by-nc-nd/4.0/>)  
Thieme Medical and Scientific Publishers Pvt. Ltd., A-12, 2nd Floor, Sector 2, Noida-201301 UP, India



**Fig. 1** (A) Ultrasound revealing thickened inflamed hypoechoic soft tissue (vertical red arrow) posterior to a linear interrupted hyperechoic structure (horizontal red arrow) representing a crumpled mesh. (B) Contrast-enhanced computed tomography of the abdomen. An axial section at the level of the urinary bladder showing well-defined linear inhomogeneous enhancing soft tissues in the anterior abdominal wall at the hernia repair site on the right side (vertical red arrow).

negative appendectomy rate of more than 20%, the most commonly used score, the Alvarado score, is not sensitive enough to diagnose acute appendicitis. Despite its inaccuracy, this score is frequently used for the clinical diagnosis of appendicitis. A negative appendectomy is thought to have occurred in 15 to 39% of patients, and research has shown that imaging is the best way to overcome this problem.<sup>5</sup> In addition to diagnosis, imaging can rule out other differential diagnoses. In our case, the infection was a delayed mesh infection, which is not often documented in the literature.

Thus, it is recommended that imaging should be considered for all patients with suspected appendicitis, and mesh infections should be considered as a possible differential diagnosis for patients presenting with clinical appendicitis in the appropriate clinical setting.

#### Funding

None.

#### Conflict of Interest

None declared.

#### References

- 1 Wilson RB, Farooque Y. Risks and prevention of surgical site infection after hernia mesh repair and the predictive utility of ACS-NSQIP. *J Gastrointest Surg* 2022;26(04):950–964
- 2 Cai LZ, Foster D, Kethman WC, Weiser TG, Forrester JD. Surgical site infections after inguinal hernia repairs performed in low and middle human development index countries: a systematic review. *Surg Infect (Larchmt)* 2018;19(01):11–20
- 3 Kohno S, Hasegawa T, Aoki H, et al. Analysis of risk factors for surgical site infection and postoperative recurrence following inguinal and femoral hernia surgery in adults. *Asian J Surg* 2022;45(04):1001–1006
- 4 Narkhede R, Shah NM, Dalal PR, Mangukia C, Dholaria S. Postoperative mesh infection—still a concern in laparoscopic era. *Indian J Surg* 2015;77(04):322–326
- 5 Noureldin K, Hatim Ali AA, Issa M, Shah H, Ayantunde B, Ayantunde A. Negative appendectomy rate: incidence and predictors. *Cureus* 2022;14(01):e21489