

Received: 2018.10.21  
Accepted: 2018.11.14  
Published: 2019.02.09

## Bronchiolitis Obliterans After Cefuroxime-Induced Stevens-Johnson Syndrome

Authors' Contribution:  
Study Design A  
Data Collection B  
Statistical Analysis C  
Data Interpretation D  
Manuscript Preparation E  
Literature Search F  
Funds Collection G

ABCDE 1 **Mohammed Shabrawishi**  
BCDEF 2 **Sultan A. Qanash**

1 Department of Internal Medicine, King Faisal Specialist Hospital and Research Center, Jeddah, Saudi Arabia  
2 Department of Internal Medicine, King Saud Bin Abdulaziz University for Health Sciences, King Abdulaziz Medical City, Jeddah, Saudi Arabia

**Corresponding Authors:** Mohammed Shabrawishi, e-mail: [shabrawishi.m@gmail.com](mailto:shabrawishi.m@gmail.com), Sultan A. Qanash, e-mail: [sultangan@hotmail.com](mailto:sultangan@hotmail.com)  
**Conflict of interest:** None declared

**Patient:** Female, 41  
**Final Diagnosis:** Bronchiolitis obliterans after SJS  
**Symptoms:** Dyspnea  
**Medication:** —  
**Clinical Procedure:** —  
**Specialty:** Pulmonology





**Objective:** Rare disease  
**Background:** Bronchiolitis obliterans is the term used to describe a clinical syndrome of irreversible airflow obstruction. Among the etiologies linked to this entity is the rarely reported association with Stevens-Johnson syndrome, which has had a poor outcome in most of the previously published cases. The optimum management of bronchiolitis obliterans as a complication of Stevens-Johnson syndrome is not well defined.

**Case Report:** A 41-year-old woman developed significant shortness of breath 3 months after recovering from Stevens-Johnson syndrome precipitated by a second-generation cephalosporin. She was found to have severe irreversible airway obstruction on physiology studies, and computed tomography scans of the inspiratory and expiratory phases of respiration showed air trapping that was more prominent on expiratory films. The patient was diagnosed with bronchiolitis obliterans, for which bronchodilators and long-term macrolide therapy were administered. Although she did not recover completely, her follow-up physiology studies showed that the bronchiolitis obliterans was stable.

**Conclusions:** Bronchiolitis obliterans secondary to Stevens-Johnson syndrome is a rare entity that is progressive and can lead to functional impairment. Identifying the disease at an early stage might stabilize or slow its progression. Herein, we describe a case of bronchiolitis obliterans as a complication of Stevens-Johnson syndrome and review the literature to raise awareness of this condition, highlight its course, and discuss the available treatments.

**MeSH Keywords:** Bronchiolitis Obliterans • Case Reports • Stevens-Johnson Syndrome

**Full-text PDF:** <https://www.amjcaserep.com/abstract/index/idArt/913723>

 1483   2  16



## Background

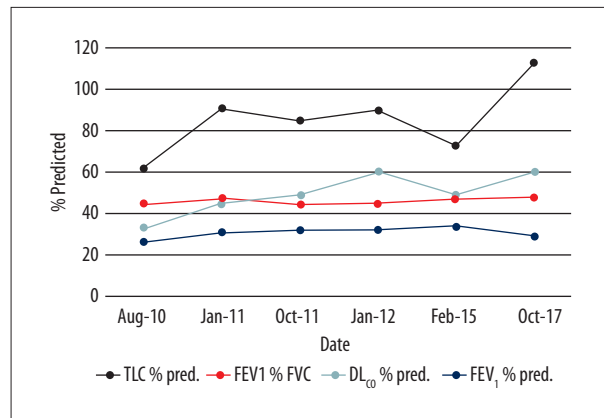
Bronchiolitis is the term used to describe diseases confined to the small airways that lead to progressive and irreversible airflow obstruction. Bronchiolitis obliterans (BO) is one of the primary bronchiolitic diseases and is characterized by peribronchiolar and submucosal fibrosis that circumferentially and externally compresses the bronchiolar lumen, leading to narrowing and eventual obliteration of the respiratory bronchioles [1]. BO has a number of causes, the most common being lung transplantation, allogenic stem cell transplantation, and connective tissue disease, particularly rheumatoid arthritis. Other rare causes include Stevens-Johnson syndrome (SJS)/toxic epidermal necrolysis (TEN) and systemic lupus erythematosus (SLE). Herein, we report on a patient who developed BO after recovery from SLE. We also review the literature to highlight awareness of the most common clinical presentation, disease course, and management of this uncommon entity.

## Case Report

The patient was a 41-year-old woman with SLE that had been diagnosed when she was 18 years of age and had manifested as arthritis, oral ulcers, and a skin and facial rash. And supported by positive serologic markers of SLE while other autoimmune markers such as rheumatoid factor and Anti-CCP were negative. Early in the course of the disease, she had been treated with oral steroids followed by azathioprine and cyclosporine. The patient denied any chemical or occupational exposure.

The patient remained in remission for 5 years, and was then admitted to another hospital with a progressive extensive rash that manifested as peeling and sloughing of the skin on the face and neck and blistering lesions. Corneal ulcers were present in both eyes. A diagnosis of SJS was made and attributed to cefuroxime, a second-generation cephalosporin. The patient was hospitalized in the intensive care unit and treated with steroids.

Three months later, she noticed significant shortness of breath that affected her ability to perform normal activities of daily living. She also developed a productive cough and episodic wheezing. Initial pulmonary function tests (PFTs) revealed severe obstruction, with a forced expiratory volume in 1 second ( $FEV_1$ ) of 0.77 L (26% predicted), a forced vital capacity (FVC) of 1.72 L (50% predicted), and an  $FEV_1/FVC$  ratio of 45%. Her total lung capacity was 2.92 L (60% predicted), her residual volume was 1.2 L (83% predicted), and her diffusing capacity of the lung for carbon monoxide was 8.5 mL/mmHg/min (31% predicted). On a six-minute walk test, she was able to walk for only 120 m without oxygen desaturation. Computed tomography (CT) of the chest showed multiple areas of focal



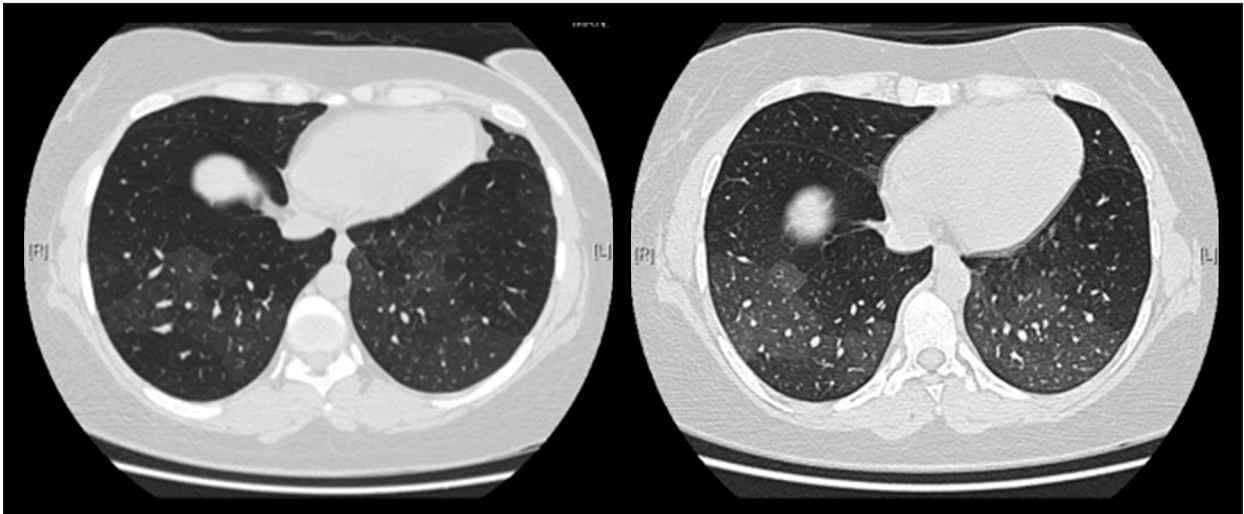
**Figure 1.** Results of pulmonary function tests at regular follow-up visits. % pred – percent of predicted;  $DL_{CO}$  – diffusing capacity of the lungs for carbon monoxide;  $FEV_1$  – forced expiratory volume in 1 second; FVC – forced vital capacity; RV – residual volume; TLC – total lung capacity.

bronchiectasis with bilateral scattered mosaic attenuation (Figure 1). A diagnosis of BO secondary to SJS was made. Treatment with an inhaled steroid, long-acting  $\beta_2$ -agonist, and long-acting anti-muscarinic agent was started, with azithromycin three times weekly. A diagnosis of lupus nephritis was also made at that time based on the finding of sub-nephrotic proteinuria. Mycophenolate was started, along with a tapering steroid. Follow-up PFTs showed stable airflow but progressive worsening of lung volumes (Figure 2). The patient's diffusing capacity of the lung for carbon monoxide increased from 31% predicted to 47% predicted and her performance on the six-minute walk test improved (262 m, 44% predicted). There were no significant changes in her symptoms during 10 years of regular follow-up. She was compliant with the same regimen and had no admissions to hospital during that time. There were no significant changes in  $FEV_1$ , FVC, or the  $FEV_1/FVC$  ratio on spirometry. There was mild worsening of lung volumes, whereby both total lung capacity and residual volume became progressively more elevated when compared with the previous tests.

## Discussion

Lung involvement is not uncommon in patients with SJS/TEN, and both acute and (to a lesser extent) chronic complications have been reported. Chronic pulmonary complications of SJS are rare, but mostly manifest as chronic bronchitis/bronchiolitis with obstructive impairment (including BO and BO organizing pneumonia), bronchiectasis, and obstruction of the respiratory tract [2,3].

An association between SJS and development of BO has been recognized since the 1980s when Reyes de la Rocha et al. [4]



**Figure 2.** Inspiratory and expiratory computed tomography.

first reported a case of persistent severe obstructive pulmonary disease following an episode of SJS. Since then, 19 cases of BO secondary to SJS/TEN have been reported in the English literature, nine of which were in adult patients [3–11].

Progressive dyspnea at rest or during exertion, cough, and wheeze were clues to the diagnosis of BO in the previous cases. The interval between SJS and onset of BO was unclear, but varied between 3 weeks [10] and 3 months, as in our patient. Nearly half of the patients, including our present case, did not have early respiratory complications, so early respiratory symptoms do not seem to predict development of BO. The mean patient age was 34.2 years, suggesting that BO secondary to SJS occurs in relatively young people. Although both SJS [12] and BO [13] are linked to autoimmune conditions, a thorough search of the relevant literature did not identify coexistence of SJS and BO with autoimmune disease except in one patient with Behçet's disease [6]. Our patient has SLE, but according to the presentation it is unlikely that either SJS or BO was a consequence of SLE.

Since the first descriptions of the association between SJS and BO at autopsy, and perhaps because of better understanding of BO and improved imaging methods, the more recently reported cases, including our patient, were diagnosed clinically and on imaging, either by CT or ventilation perfusion scans and physiological studies. In the reported cases, CT scans were characterized by air trapping and areas of mosaic attenuation [3,5–7,11] and bronchiectasis [3,11] or bronchiolectasis [7]. In the older cases, ventilation and perfusion scintigraphy showed multiple ventilation and perfusion defects without mismatch [9] or marked retention during washout phase in multiple areas [4]. Bronchoscopic examination of the airway was performed in a few cases and showed occlusion or obliteration of many segmental bronchi [9–11];

in one case, only mild erythema was detected [4]. PFTs were performed in most patients and were characterized by severe airflow obstruction, which was irreversible with a bronchodilator, and air trapping. Our patient showed progressive airflow obstruction with gas trapping, hyperinflation, and significant improvement in diffusing capacity of the lung for carbon monoxide, which is typical of a diagnosis of BO.

The pathogenesis of BO secondary to SJS is not well understood. At autopsy, lungs from patients with BO secondary to SJS showed loss of the bronchial epithelium and proliferation of granulation tissue distal to the obstruction, leading to narrowing of the lumen of the airway that was macroscopically evident as extensive occlusion of the third to fifth branches of the bronchi [8]. Moreover, Sugino et al. [7] suggested that BO secondary to SJS may be a consequence of epithelial and mucosal damage at the level of the bronchioles, where a combination of an abnormal immune response and respiratory tract infection may play an important role.

BO secondary to SJS is usually progressive and has a poor prognosis. Half of the reported cases died from respiratory failure, with the longest recorded survival being 17 years after SJS [7]. Six patients, including our present case, did not recover completely and were found to have severe chronic obstruction with stable or only mild improvement in symptoms and PFTs [3–5,9]. Interestingly, pneumothorax and respiratory infection had an impact on mortality, mainly when occurring at an early stage [6,7,11].

Treatment for BO is generally challenging and the response to a bronchodilator and/or a corticosteroid is poor. In certain subtypes, i.e., BO post-lung or post-bone marrow transplant, changing or augmenting the immunosuppressive medication might result in a better outcome. In addition to its effect on

survival in patients with diffuse panbronchiolitis [14], macrolide therapy has been shown to slow or even reverse the decline in lung function in patients with BO after lung transplantation [15]. Corticosteroids had no major effect on SJS or BO in most of the patients reviewed here, and bronchodilators achieved only mild improvement. In our patient, mycophenolate was administered as part of the treatment for SLE and azithromycin three times weekly was included in the therapeutic regimen, which might have contributed to her clinical stability. Weber et al. [13] reported successful administration of cyclophosphamide in a patient with SLE who had features of BO as a late manifestation; this might support the role of an immune complex in this entity. Other therapeutic modalities included a trial of dilatation of the occluded bronchi with

a balloon catheter in one patient, which was followed rapidly by restenosis of the bronchi [10]. Finally, living donor lobar lung transplantation was performed in one pediatric case with good results [16]. Although the diagnosis of our case was based on clinical, physiological, and radiological findings, unobtained lung biopsy is considered as a limitation of our report.

## Conclusions

BO secondary to SJS is an uncommon disorder with broad non-specific manifestations that necessitate a high index of suspicion to diagnose. Continuous monitoring of the disease and prompt management are essential to prevent progression.

## References:

1. Garibaldi BT, Illei P, Danoff SK: Bronchiolitis. *Immunol Allergy Clin North Am*, 2012; 32: 601–19
2. Kamada N, Kinoshita K, Togawa Y et al: Chronic pulmonary complications associated with toxic epidermal necrolysis: Report of a severe case with anti-Ro/SS-A and a review of the published work. *J Dermatol*, 2006; 33: 616–22
3. Nuo X, Chen X, Wu S et al: Chronic pulmonary complications associated with toxic epidermal necrolysis: A case report and literature review. *Exp Ther Med*, 2018; 16: 2027–31
4. Reyes de la Rocha S, Leonard JC, Demetriou E: Potential permanent respiratory sequela of Stevens-Johnson syndrome in an adolescent. *J Adolesc Health Care*, 1985; 6: 220–23
5. Pannu BS, Egan AM, Iyer VN: Phenytoin induced Steven-Johnson syndrome and bronchiolitis obliterans – case report and review of literature. *Respir Med Case Rep*, 2016; 17: 54–56
6. Park H, Ko YB, Kwon HS, Lim CM: Bronchiolitis obliterans associated with Stevens-Johnson syndrome: A case report. *Yonsei Med J*, 2015; 56: 578–81
7. Sugino K, Hebisawa A, Uekusa T et al: Bronchiolitis obliterans associated with Stevens-Johnson syndrome: Histopathological bronchial reconstruction of the whole lung and immunohistochemical study. *Diagn Pathol*, 2013; 8: 134
8. Tsunoda N, Iwanaga T, Saito T et al: Rapidly progressive bronchiolitis obliterans associated with Stevens-Johnson syndrome. *Chest*, 1990; 98: 243–45
9. Yatsunami J, Nakanishi Y, Matsuki H et al: Chronic bronchobronchiolitis obliterans associated with Stevens-Johnson syndrome. *Intern Med*, 1995; 34: 772–75
10. Minamihaba O, Nakamura H, Sata M et al: Progressive bronchial obstruction associated with toxic epidermal necrolysis. *Respirology*, 1999; 4: 93–95
11. Woo T, Saito H, Yamakawa Y et al: Severe obliterative bronchitis associated with Stevens-Johnson syndrome. *Intern Med*, 2011; 50: 2823–27
12. Lee HY, Tey HL, Pang SM, Thirumoorthy T: Systemic lupus erythematosus presenting as Stevens-Johnson syndrome and toxic epidermal necrolysis: A report of three cases. *Lupus*, 2011; 20: 647–52
13. Weber F, Prior C, Kowald E et al: Cyclophosphamide therapy is effective for bronchiolitis obliterans occurring as a late manifestation of lupus erythematosus. *Br J Dermatol*, 2000; 143: 453–55
14. Kudoh S, Azuma A, Yamamoto M et al: Improvement of survival in patients with diffuse panbronchiolitis treated with low-dose erythromycin. *Am J Respir Crit Care Med*, 1998; 157(6 Pt 1): 1829–32
15. Kingah PL, Muma G, Soubani A: Azithromycin improves lung function in patients with post-lung transplant bronchiolitis obliterans syndrome: A meta-analysis. *Clin Transplant*, 2014; 28: 906–10
16. Date H, Sano Y, Aoe M et al: Living-donor lobar lung transplantation for bronchiolitis obliterans after Stevens-Johnson syndrome. *J Thorac Cardiovasc Surg*, 2002; 123: 389–91