

Noninvasive Management of an Odontoid Process Fracture in a Toddler: Case Report

Woosung Kim¹ Mike O'Malley¹ David Christopher Kieser¹

¹ Southern District Health Board, Invercargill, New Zealand

Global Spine J 2015;5:59–62.

Address for correspondence Dr. David Kieser, MBChB, PGDipSurgAnat, P.O. Box 6458, Dunedin, New Zealand 9016 (e-mail: kieserdavid@gmail.com).

Abstract

Study Design Case report.

Objective Odontoid process fractures represent an uncommon injury in small children, with their optimal management remaining unclear. We present a case of conservatively managed displaced type 2 odontoid process fracture in a small child.

Methods We analyzed clinical and radiographic outcomes of a restrained 2-year-old girl involved in a motor vehicle accident who sustained a displaced type 2 odontoid process fracture and was treated conservatively in a semirigid Aspen collar.

Results The fracture progressively healed with callus formation evident at 6 weeks. By 12 weeks, the patient was asymptomatic and had regained head control and a full range of movement. Radiographic remodeling of the fracture was seen to improve over the 6-month follow-up.

Conclusion This case illustrates that displaced type 2 odontoid process fractures can be successfully managed conservatively in small children.

Keywords

- ▶ odontoid peg
- ▶ dens
- ▶ pediatric
- ▶ cervical spine
- ▶ fracture

Introduction

Spinal injuries in small children are rare with a reported incidence of 0.2 to 0.5% of all fractures or dislocations and 1.5 to 3% of all lesions in the spine.¹ It has been shown that the younger the child at the time of injury, the more likely the upper cervical spine is affected, with over 50% of spinal injuries in small children affecting this region. This relates to the child's greater head-to-body ratio, where more forces are centered around the junction between the large head and the smaller body.²

A subset of cervical spine fractures is the odontoid process fracture. In small children, this fracture typically involves the cartilaginous plate that separates the odontoid process from the body of the axis. The most common mechanism of such an injury is a head-on motor vehicle accident with a toddler restrained in a backseat by a four-point children's seat harness.

Previous biomechanical investigations using simulation have shown vehicle speed greater than 40 km/h is sufficient to create the shearing forces required to cause such injuries in children under the age of 3.³ However, despite the increasing

numbers of motor vehicle accidents occurring annually, resulting in increasing numbers of pediatric fractures, the optimal management of odontoid process fractures in small children remains undetermined. The current literature reports these fractures can be successfully treated with nonoperative management including cervical spine immobilization as well as operative interventions ranging from closed reduction and external fixation to posterior fixation or fusion of C1/C2.⁴

We present a case of a conservatively managed type 2 displaced odontoid process fracture in a 2-year-old girl.

Case Report

A 2-year-old girl who was previously healthy re-presented to the emergency department following a motor vehicle accident 6 days earlier. The parents describe a head-on motor vehicle accident at 90 km/h, with the toddler restrained in the backseat by a four-point child seat harness. The fracture was missed on initial presentation to the emergency department, which included a cervical spine X-ray; however, she remained reluctant to move her head and became distressed when not lying flat. On repeat presentation, she was comfortable at rest

received

February 10, 2014

accepted after revision

May 24, 2014

published online

July 30, 2014

© 2015 Georg Thieme Verlag KG
Stuttgart · New York

DOI <http://dx.doi.org/10.1055/s-0034-1384817>.
ISSN 2192-5682.

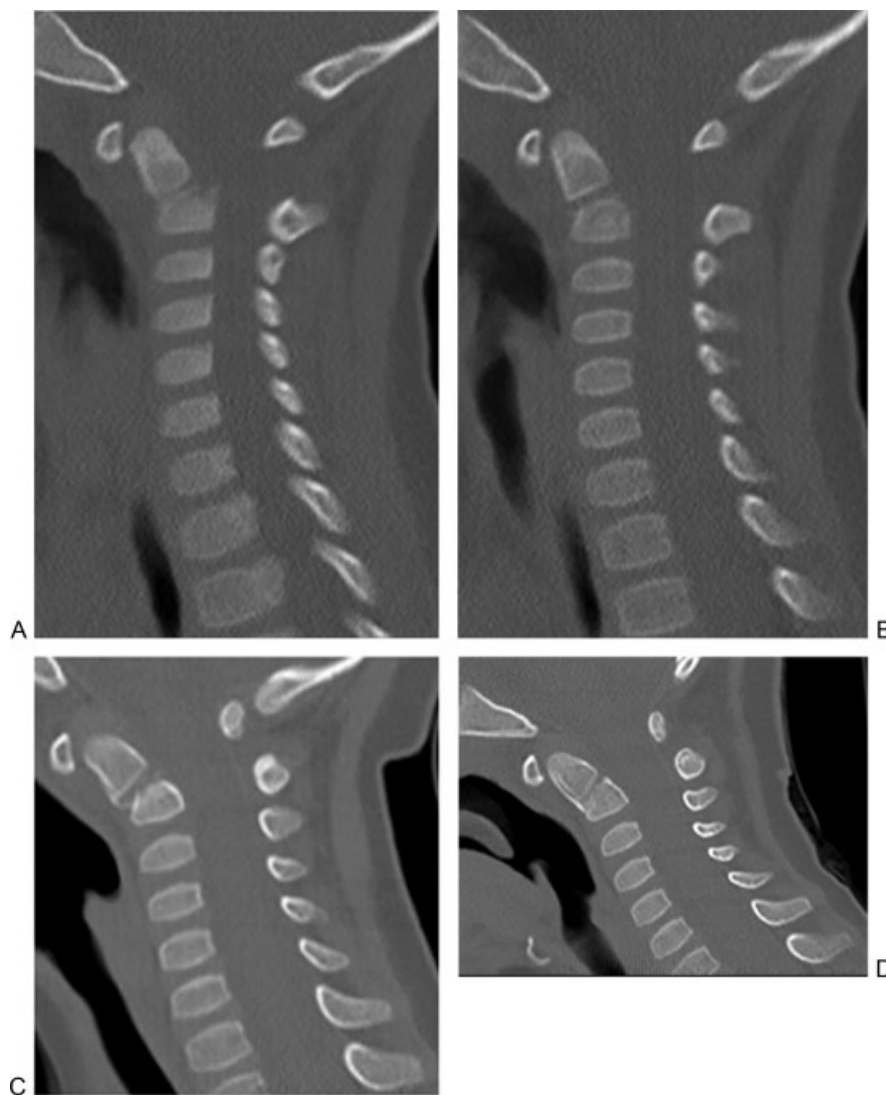


Fig. 1 Serial sagittal computed tomography images of a conservatively managed odontoid process fracture in a 2-year-old: (A) 45 degrees at initial presentation; (B) 45 degrees at 6 weeks postinjury with callus formation; (C) 40 degrees at 10 weeks postinjury; (D) 25 degrees at 6 months postinjury.

but lacked head control. Interestingly, her cervical spine was nontender and revealed no posterior swelling or bruising. Her neurologic examination was unremarkable, but a cervical spine computed tomography (CT) revealed a 45-degree flexed type 2 odontoid process fracture.

The patient was managed conservatively in Aspen collar for a total of 10 weeks. She remained neurologically intact throughout and by 12 weeks had regained head control and a full range of movement without pain. Repeat CT scans were performed at 6 weeks, 10 weeks, and 6 months postinjury. These revealed callus formation at 6 weeks, followed by remodeling toward normal alignment by 6 months (→ Fig. 1).

Discussion

This case represents the common mechanism of injury for this fracture in the pediatric population. Furthermore, it illustrates the difficulties in diagnosis, where patients may

present without neck pain but rather a feeling of instability. In the pediatric population, reports of these symptoms are often very difficult to attain from the patient and therefore clinicians should maintain a high index of suspicion in a child who becomes distressed with movement or the requirement of head control and who has a significant mechanism of injury. If plain film X-rays are difficult to discern on initial presentation, further imaging is required. We utilized a CT scan to further delineate the bony injury, and due to the difficulty in interpreting the plain film X-rays in this child, we used limited upper cervical CT scans to monitor fracture healing. However, such scans should be used with caution in children due to the concerns of the ionizing radiation dose delivered.^{5,6} Although limited scans deliver a low dose, they should nonetheless be avoided where possible.^{5,6}

Within the adult population, displaced type 2 odontoid process fractures can be treated operatively or nonoperatively, depending on the patient age, comorbidities, fracture

pattern, and displacement.^{7,8} However, the management of such fractures in the pediatric population remains unclear. To our knowledge, there has only been one other case describing the management of a displaced type 2 odontoid process fracture in a small child. In this publication, Bhagat and coauthors described operative intervention of a displaced type 2 odontoid process fracture in a 2-year-old girl.⁹ Although they did not describe when union occurred, they noted marked remodeling of the fracture over a 30-month period. With such paucity of literature on this topic, it is unknown whether operative intervention aids fracture union and functional outcome in the small child.

However, our case illustrates that odontoid process fractures in small children can be successfully managed without operative intervention despite significant angulation. In this case, developing union, with callus formation, was noted at 6 weeks postinjury, and progressive remodeling was seen to occur by the 6-month follow-up.

We utilized a semirigid Aspen collar rather than a rigid cervical spine orthosis, such as a halo vest traction, because of the higher rate of complications, such as pin site infections, pin loosening, brain abscesses, skin breakdown, and stiffness, associated with halo traction.^{10,11} Furthermore, the bulk and size of halo traction in small children limits their mobilization and, due to their poor head control and crawling rather than upright gait, risks progressive loss of spinal alignment if the brace is not tightly fitted. The concern, however, with non-rigid immobilization is that of poor compliance, with the brace able to be removed by the patient or parents. In addition, within the adult population, higher union rates are reported with rigid halo vest immobilization compared with nonrigid immobilization, although this is debated and has not been analyzed in the pediatric population.^{12,13}

In conclusion, this case illustrates that displaced type 2 odontoid process fractures in small children can be successfully treated conservatively in a semirigid cervical orthosis. Furthermore, one can expect significant remodeling of the fracture within this population.

Disclosures

Woosung Kim, none

Mike O'Malley, none

David Christopher Kieser, none

References

- 1 Patel JC, Tepas JJ III, Mollitt DL, Pieper P. Pediatric cervical spine injuries: defining the disease. *J Pediatr Surg* 2001;36(2):373–376
- 2 Fesmire FM, Luten RC. The pediatric cervical spine: developmental anatomy and clinical aspects. *J Emerg Med* 1989;7(2):133–142
- 3 Blauth M, Schmidt U, Otte D, Krettek C. Fractures of the odontoid process in small children: biomechanical analysis and report of three cases. *Eur Spine J* 1996;5(1):63–70
- 4 Mueller OM, Gasser T, Hellwig A, Dohna-Schwake C, Sure U. Instable cervical spine injury in a toddler: technical note. *Childs Nerv Syst* 2010;26(11):1625–1631
- 5 Scaife ER, Rollins MD. Managing radiation risk in the evaluation of the pediatric trauma patient. *Semin Pediatr Surg* 2010;19(4):252–256
- 6 Brenner D, Elliston C, Hall E, Berdon W. Estimated risks of radiation-induced fatal cancer from pediatric CT. *AJR Am J Roentgenol* 2001;176(2):289–296
- 7 Singh V, Banerjee S, Onukaogu S, Singh P, Leitao J. Nonoperative treatment of displaced type II odontoid peg fractures with a Philadelphia collar. *Orthopedics* 2012;35(4):e538–e542
- 8 Shears E, Armitstead CP. Surgical versus conservative management for odontoid fractures. *Cochrane Database Syst Rev* 2008;(4):CD005078
- 9 Bhagat S, Brown J, Johnston R. Remodelling potential of paediatric cervical spine after type II odontoid peg fracture. *Br J Neurosurg* 2006;20(6):426–428
- 10 Maak TG, Grauer JN. The contemporary treatment of odontoid injuries. *Spine* 2006;31(11, Suppl):S53–S60, discussion S61
- 11 Ochoa G. Surgical management of odontoid fractures. *Injury* 2005;36(Suppl 2):B54–B64
- 12 Platzer P, Thalhammer G, Sarahrudi K, et al. Nonoperative management of odontoid fractures using a halothoracic vest. *Neurosurgery* 2007;61(3):522–529, discussion 529–530
- 13 Polin RS, Szabo T, Bogaev CA, Replogle RE, Jane JA. Nonoperative management of types II and III odontoid fractures: the Philadelphia collar versus the halo vest. *Neurosurgery* 1996;38(3):450–456, discussion 456–457