



Case report

Nivolumab-induced immune thrombocytopenia in a patient with malignant pleural mesothelioma



Jun Sakakibara-Konishi^{a,*}, Mineyoshi Sato^a, Michiko Takimoto Sato^a, Kohei Kasahara^b, Masahiro Onozawa^b, Hidenori Mizugaki^a, Eiki Kikuchi^a, Hajime Asahina^a, Naofumi Shinagawa^a, Satoshi Konno^a

^a First Department of Medicine, Hokkaido University Hospital, Sapporo, Japan

^b Department of Hematology, Hokkaido University Hospital, Sapporo, Japan

ARTICLE INFO

Keywords:

Malignant pleural mesothelioma

Nivolumab

Immune thrombocytopenia

ABSTRACT

Malignant pleural mesothelioma (MPM) is a rare and highly aggressive tumor. Nivolumab showed durable antitumor effect in patients with recurrent MPM and was approved for those patients in Japan in 2018. Immune related adverse event (irAE) is occurred in various organs and is suggestive to be related to better outcome of nivolumab. Frequency of hematological irAE is low and there are few reports about hematological irAE and association between irAE and outcome of nivolumab in patients with MPM. We present a case of recurrent MPM who responded to nivolumab treatment and experienced nivolumab-induced immune thrombocytopenia (ITP). Although high dose dexamethasone was administered and platelet count increased transiently, re-administration of dexamethasone was required to maintain normal count of platelet. The careful and intensive management of ITP treatment is necessary in cases who show no response or relapse to initial glucocorticoids treatment. This is the first report about nivolumab-induced ITP and association with response to nivolumab in MPM.

1. Introduction

Malignant pleural mesothelioma (MPM) is a rare and aggressive disease that arises from mesothelioma cells in the thoracic cavity [1]. MPM is mostly associated with exposure to asbestos, and the incidence of MPM is increasing in many countries because of the long latency period between the exposure to asbestos and occurrence of the disease [2]. Patients with MPM are often diagnosed at advanced stage and are treated with pemetrexed (PEM) plus cisplatin, which are the currently approved first-line therapy [3]. However, the median overall survival is approximately one year, and there is a vital need to identify new treatment options that can improve the outcome of patients with MPM [3].

Recently, immune check point inhibitors (ICIs) have demonstrated durable antitumor effects and have been shown to prolong survival in patients with many different types of malignant tumors [4–7]. Nivolumab is a fully human immunoglobulin (Ig) G4 monoclonal antibody that binds to the negative immunoregulatory human cell surface receptor programmed death-1 (PD-1) and has immune checkpoint inhibitory activity [8]. Nivolumab has shown promising efficacy in patients with

recurrent MPM in several clinical trials [9–11] and was approved for those patients in Japan in 2018.

Immune related adverse events (irAEs) often occur in patients with ICI therapy and may necessitate the interruption or discontinuation of ICI treatment [12]. In clinical trials involving patients with refractory MPM who were treated with nivolumab, irAEs have been observed; however, hematological irAEs have not been reported [9–11].

We present a case of a patients with recurrent MPM who was treated with nivolumab and showed a clinical response to nivolumab. Subsequently, he experienced nivolumab-induced immune thrombocytopenia (ITP) and received repeated treatment with glucocorticoids.

2. Case presentation

A 60-year-old man was diagnosed with MPM and underwent extrapleural pneumonectomy in March 2013. The histological subtype was epithelioid, and the pathological stage was pStageIII (pT3N0M0) (Union for International Cancer Control TNM Classification of Malignant Tumors, 7th edition). He had no severe complications and no history of autoimmune disease. He received adjuvant chemotherapy containing

* Corresponding author. First Department of Medicine, Hokkaido University Hospital, North 15, West 7, Kita-ku, Sapporo, 060-8638, Japan.

E-mail address: konishj@med.hokudai.ac.jp (J. Sakakibara-Konishi).

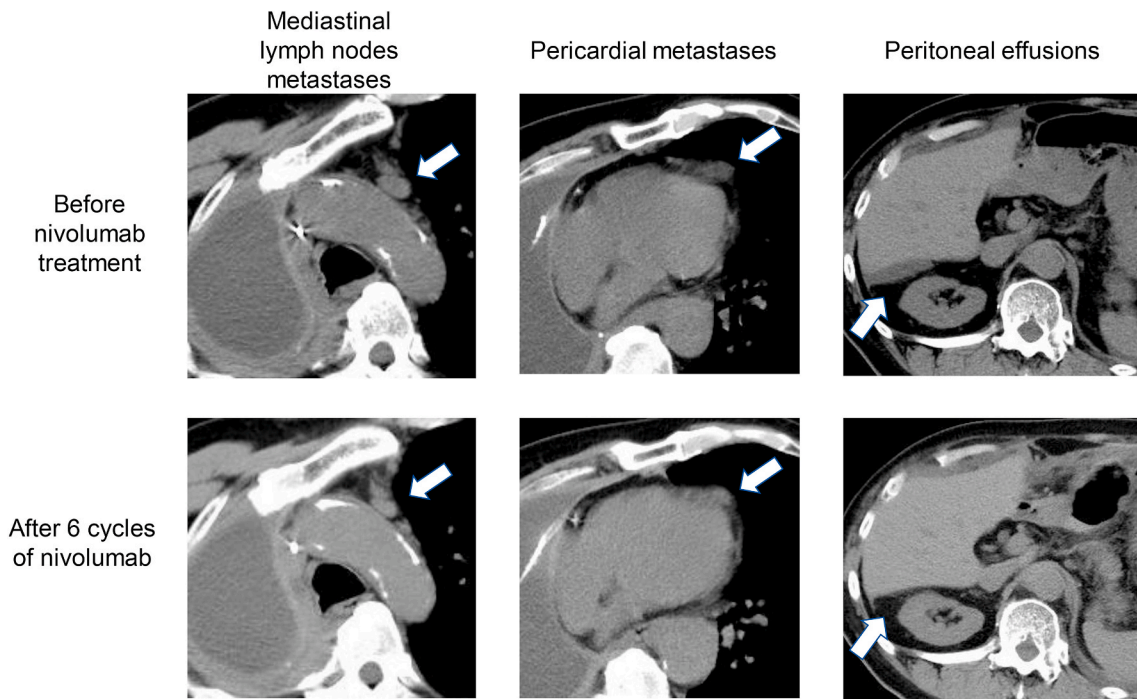


Fig. 1. Computed tomography images of mediastinal lymph nodes, pericardial metastases, and peritoneal effusion before and after treatment with nivolumab. Shrinkage of mediastinal lymph nodes and pericardial metastases and a decrease in peritoneal effusion were observed after nivolumab administration.

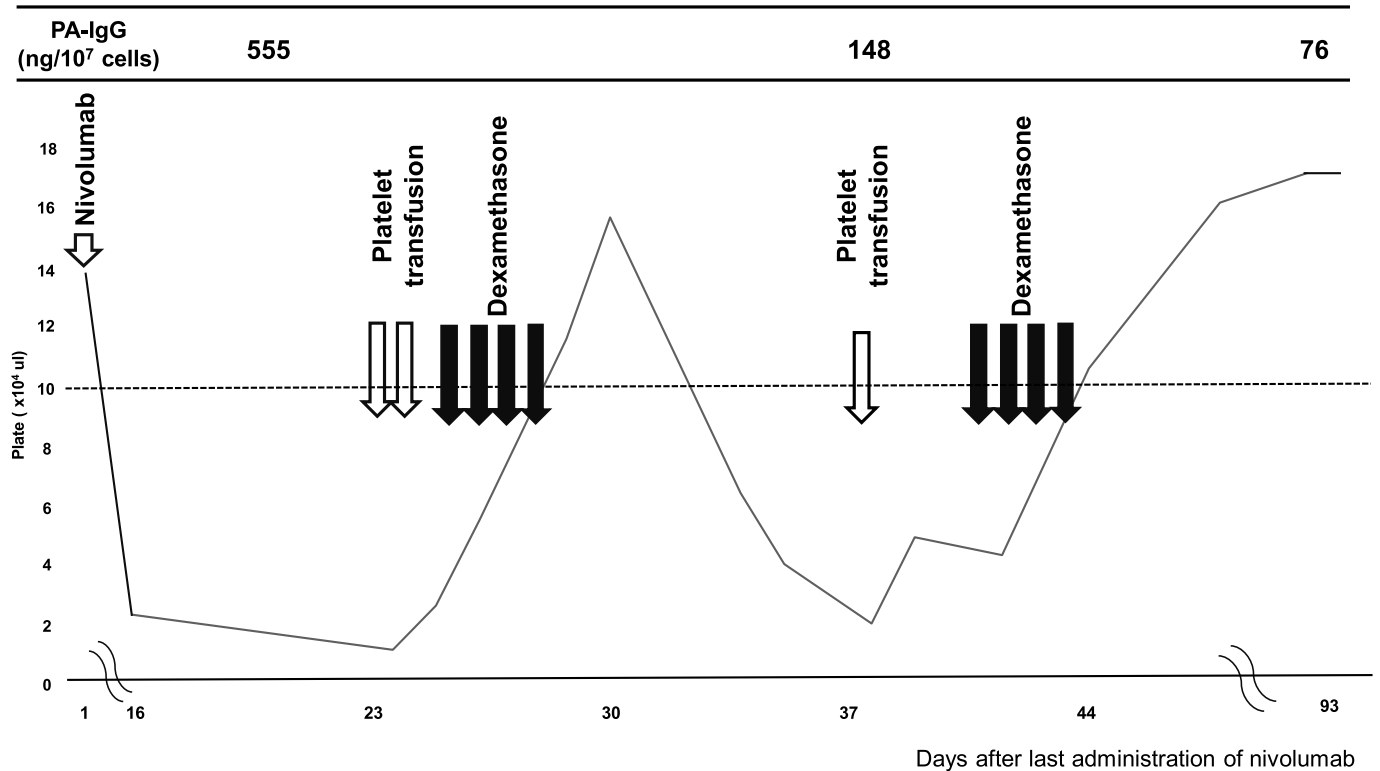


Fig. 2. Platelet counts after six cycles of nivolumab treatment.

carboplatin and PEM for one cycle; however, chemotherapy was discontinued because of a Grade 2 increase in his creatinine level. After the discontinuation of the adjuvant chemotherapy, his creatinine level decreased but remained slightly high (1.2 mg/dL). In December 2016, peritoneal dissemination was observed. Consequently, he was treated with vinorelbine (25mg/m²) for 11 cycles, and stable disease (SD) was

achieved. In December 2017, new metastases were identified in left pleural region. At this time, the use of PEM was a concern because the creatinine level had increased during the previous treatment with adjuvant chemotherapy. However, PEM was administered in accordance with the patient's request. After receiving four cycles of PEM treatment with SD, he experienced disease progression and was treated with

nivolumab (240 mg, every 2 weeks) in September 2018. Following treatment with nivolumab, shrinkage of the mediastinal lymph nodes and pericardial metastases and a decrease in peritoneal effusion were observed (Fig. 1). Response to nivolumab continued without any adverse events until six cycles of nivolumab were administered. In January 2019, after six cycles of nivolumab, his platelet count suddenly decreased to 24000/ μL ; there was no change in his hemoglobin level and his white blood cell count. Fig. 2 shows the platelet count after six cycles of nivolumab treatment. He had no liver dysfunction, and there were no symptoms of infection. His creatinine level was slightly high (1.28 mg/dL) and remained unchanged during treatment with nivolumab. Although nivolumab was discontinued, his platelet count decreased to 12000/ μL , and he developed subcutaneous bleeding. Platelet transfusions were administered for 2 days; however, the platelet count remained low. The serum antinuclear antibody test was positive and the platelet-associated immunoglobulin G (PA-IgG) antibody level increased to 555 ng/ 10^7 cell (normal range is below 46 ng/ 10^7 cell). Increased number of megakaryocytes with normal morphology and normal development of erythroid and myeloid cells were observed on bone marrow aspiration. Serological assessment was negative for hepatitis B or C, and a serum *helicobacter pylori* antibody test was negative. Other than nivolumab, no other drugs known to induce thrombocytopenia were not administered. Based on the above findings, we determined that thrombocytopenia was induced by nivolumab. Administration of 33mg of dexamethasone for 4 days resulted in a temporary recovery of his platelet count (158000/ μL). However, 7 days after treatment with dexamethasone, his platelet count decreased again to 21000/ μL . Dexamethasone 33 mg was re-administered for 4 days followed by platelet transfusions. Subsequently, his platelet count increased, and a sustained response was observed. PA-IgG level decreased to 148 ng/ 10^7 cell after initial administration of dexamethasone. Approximately 3 months after the last treatment with nivolumab, PA-IgG level was 76 ng/ 10^7 cells, and his platelet count remained within the normal range. Four months after the last treatment with nivolumab, he experienced progression of his MPM.

3. Discussion

We report the case of a patient with recurrent MPM who developed nivolumab-induced ITP. The patient experienced a clinical response to nivolumab treatment before he developed ITP. Dexamethasone had to be administered twice to treat the ITP.

Although many types of irAE are developed in various organs, the frequency of the occurrence of hematological irAEs is relatively low [12]. In an observational study of 948 patients who were treated with anti-PD-L1 or anti-PD-1 immunotherapies, 35 patients experienced grade 2 or worse hematological irAEs [13]. In a review of 19 large clinical trials of ICIs, such as anti-PD-L1, anti-PD-1, and anti-cytotoxic T-lymphocyte-associated antigen 4 antibodies, used for the treatment of melanoma, lung cancer, bladder cancer, etc., the frequency of the occurrence of hematological irAE was estimated to be 3.6% cases for all grades and 0.7% cases for grades 3 or 4¹⁴. ITP was reported to be one of the most frequent type of hematological irAEs [13,14]. To the best of our knowledge, this is the first case report of ITP induced by nivolumab in a patient with MPM.

It is recommended that ICI-induced ITP is treated with glucocorticoids initially based on the standard therapy algorithms of classical ITP as described in American Society of Clinical Oncology Clinical Practice Guideline [15,16]. In the observational study, all nine patients with ICI-induced ITP were treated with glucocorticoids, and six patients received additional intravenous immunoglobulin. Two patients showed no response to initial therapy and received thrombopoietin agonists or rituximab [13]. In other reports, 4 of 11 patients with ICI-induced ITP received glucocorticoids and 2 patients required rituximab or re-administration of glucocorticoids [17]. In our patient, a response was observed to initial glucocorticoid therapy; however, he subsequently

relapsed and re-administration of glucocorticoids was required. This suggests that careful and intensive management of ITP treatment is necessary in patients demonstrating no response or who relapse following initial treatment.

Although the pathogenesis of ITP induced by ICI remains unknown, the production of antiplatelet antibodies is considered a key event in the development of classical ITP [15,18]. In our patient, the serum antinuclear antibody test was positive. In the observational study, three of nine patients showed positive results in serum antinuclear antibody assay [13]. In our patient, the PA-IgG level increased when ITP occurred and then decreased after ITP treatment was initiated. In several case reports, elevated PA-IgG levels have been observed in patients with ICI-induced ITP [19,20]. Although further investigation regarding the frequency of occurrence and the clinical impact of antinuclear antibodies and PA-IgG levels in ICI-induced ITP is required, the presence of these antibodies might be related to the cause of ICI-induced ITP.

Our patient showed a clinical response to nivolumab. An association between the efficacy of ICI treatment and the occurrence of irAEs has been reported in several cancers, especially melanoma and non-small cell lung cancer (NSCLC) [21–23]; however, such an association has not been observed in patients with MPM. Although any type of irAE was related to better outcomes of ICI treatment, analyses of the efficacy of ICIs in patients who develop hematological irAEs are limited. In a previous case report, tumor regression was observed in a patient with NSCLC who was treated with nivolumab and who developed nivolumab-induced ITP [24], which is comparable to the results in our case. The mechanism of the correlation between the outcome of ICI treatment and development of irAEs remains unknown; however, the shared antigen between tumor cells and normal cells might be responsible for the relationship between the outcome of ICI therapy and the development of irAEs [23]. To our knowledge, this is the first report of an association between the response to nivolumab treatment and nivolumab-induced ITP in a patient with MPM.

4. Conclusion

Although ITP induced by nivolumab is rare, systematic diagnosis and treatment are required. Glucocorticoids are administered in most cases. Careful management and follow-up should be considered in patients who relapse or exhibit resistance to initial glucocorticoids treatment.

Declaration of competing interest

The authors state that they have no Conflict of Interest.

References

- [1] B.W.S. Robinson, A.W. Musk, R.A. Lake, Malignant mesothelioma, *Lancet* 366 (2005) 397–408.
- [2] J. LaDou, B. Castleman, A. Frank, et al., The case for a global ban on asbestos, *Environ. Health Perspect.* 118 (2010) 897–901.
- [3] G. Zalcman, J. Mazieres, J. Margery, et al., Bevacizumab for newly diagnosed pleural mesothelioma in the Mesothelioma Avastin Cisplatin Pemetrexed Study (MAPS): a randomised, controlled, open-label, phase 3 trial, *Lancet* 387 (2016) 1405–1414.
- [4] J.D. Wolchok, H. Kluger, M.K. Callahan, et al., Nivolumab plus ipilimumab in advanced melanoma, *N. Engl. J. Med.* 369 (2013) 122–133.
- [5] H. Borghaei, L. Paz-Ares, L. Horn, et al., Nivolumab versus docetaxel in advanced nonsquamous non-small-cell lung cancer, *N. Engl. J. Med.* 373 (2015) 1627–1639.
- [6] J. Brahmer, K.L. Reckamp, P. Baas, et al., Nivolumab versus docetaxel in advanced squamous-cell non-small-cell lung cancer, *N. Engl. J. Med.* 373 (2015) 123–135.
- [7] R.J. Motzer, B. Escudier, D.F. McDermott, et al., Nivolumab versus everolimus in advanced renal-cell carcinoma, *N. Engl. J. Med.* 373 (2015) 1803–1813.
- [8] C. Wang, K.B. Thudium, M. Han, et al., In vitro characterization of the anti-PD-1 antibody nivolumab, BMS-936558, and in vivo toxicology in non-human primates, *Canc. Immunol. Res.* 2 (2014) 846–856.
- [9] J. Quispel-Janssen, V. van der Noort, J.F. de Vries, et al., Programmed death 1 blockade with nivolumab in patients with recurrent malignant pleural mesothelioma, *J. Thorac. Oncol.* 13 (2018) 1569–1576.
- [10] A. Scherpereel, J. Mazieres, L. Greillier, et al., Nivolumab or nivolumab plus ipilimumab in patients with relapsed malignant pleural mesothelioma (IFCT-1501

- MAPS2): a multicentre, open-label, randomised, non-comparative, phase 2 trial, *Lancet Oncol.* 20 (2019) 239–253.
- [11] M. Okada, T. Kijima, K. Aoe, et al., Clinical efficacy and safety of nivolumab: results of a multicenter, open-label, single-arm, Japanese phase II study in malignant pleural mesothelioma (MERIT), *Clin. Canc. Res.* 25 (2019) 5485–5492.
- [12] C.F. Friedman, T.A. Proverbs-Singh, M.A. Postow, Treatment of the immune-related adverse effects of immune checkpoint inhibitors: a review, *JAMA Oncol.* 2 (2016) 1346–1353.
- [13] N. Delanoy, J.-M. Michot, T. Comont, et al., Haematological immune-related adverse events induced by anti-PD-1 or anti-PD-L1 immunotherapy: a descriptive observational study, *Lancet Haematol.* 6 (2019) e48–e57.
- [14] J.M. Michot, J. Lazarovici, A. Tieu, et al., Haematological immune-related adverse events with immune checkpoint inhibitors, how to manage? *Eur. J. Canc.* 122 (2019) 72–90.
- [15] N. Cooper, W. Ghanima, Immune thrombocytopenia, *N. Engl. J. Med.* 381 (2019) 945–955.
- [16] J.R. Brahmer, C. Lachetti, B.J. Schneider, et al., Management of immune-related adverse events in patients treated with immune check point inhibitor therapy: american society of clinical oncology clinical practice guideline, *J. Clin. Oncol.* 38 (2018) 1714–1767.
- [17] E. Shiuan, K.E. Beckermann, A. Ozgun, et al., Thrombocytopenia in patients with melanoma receiving immune checkpoint inhibitor therapy, *J. Immunother. Canc.* 5 (2017) 8.
- [18] A. Zufferey, R. Kapur, J.W. Semple, Pathogenesis and therapeutic mechanisms in immune thrombocytopenia (ITP), *J. Clin. Med.* 6 (2017).
- [19] T. Hasegawa, Y. Ozaki, T. Inoue, et al., Nivolumab-related severe thrombocytopenia in a patient with relapsed lung adenocarcinoma: a case report and review of the literature, *J. Med. Case Rep.* 13 (2019) 316.
- [20] C. Pfohler, H. Eichler, B. Burgard, N. Krecke, C.S.L. Muller, T. Vogt, A case of immune thrombocytopenia as a rare side effect of an immunotherapy with PD1-blocking agents for metastatic melanoma, *Transfus. Med. Hemotherapy* 44 (2017) 426–428.
- [21] K. Haratani, H. Hayashi, Y. Chiba, et al., Association of immune-related adverse events with nivolumab efficacy in non-small-cell lung cancer, *JAMA Oncol.* 4 (2018) 374–378.
- [22] D. Maillet, P. Corbaux, J.J. Stelmes, et al., Association between immune-related adverse events and long-term survival outcomes in patients treated with immune checkpoint inhibitors, *Eur. J. Canc.* 132 (2020) 61–70.
- [23] H.E. Teulings, J. Limpens, S.N. Jansen, et al., Vitiligo-like depigmentation in patients with stage III-IV melanoma receiving immunotherapy and its association with survival: a systematic review and meta-analysis, *J. Clin. Oncol.* 33 (2015) 773–781.
- [24] H. Mori, C. Sakai, M. Iwai, et al., Immune thrombocytopenia induced by nivolumab in a patient with non-small cell lung cancer, *Respir. Med. Case Rep.* 28 (2019) 100871.