

CASE REPORT

Serratia liquefaciens Infection of a Previously Excluded Popliteal Artery Aneurysm

A. Coelho^{*}, M. Lobo, V. Martins, R. Gouveia, P. Sousa, J. Campos, R. Augusto, N. Coelho, A. Canedo

Centro Hospitalar de Vila Nova de Gaia e Espinho, Porto, Portugal

Introduction: Popliteal artery aneurysms (PAAs) are rare in the general population, but they account for nearly 70% of peripheral arterial aneurysms. There are several possible surgical approaches including exclusion of the aneurysm and bypass grafting, or endoaneurysmorrhaphy and interposition of a prosthetic conduit. The outcomes following the first approach are favorable, but persistent blood flow in the aneurysm sac has been documented in up to one third of patients in the early post-operative setting. Complications from incompletely excluded aneurysms include aneurysm enlargement, local compression symptoms, and sac rupture. Notably infection of a previously excluded and bypassed PAA is rare. This is the third reported case of PAA infection after exclusion and bypass grafting and the first due to *Serratia liquefaciens*.

Methods: Relevant medical data were collected from the hospital database.

Results: This case report describes a 54 year old male patient, diagnosed with acute limb ischaemia due to a thrombosed PAA, submitted to emergency surgery with exclusion and venous bypass. A below the knee amputation was necessary 3 months later. Patient follow-up was lost until 7 years following surgical repair, when he was diagnosed with aneurysm sac infection with skin fistulisation. He had recently been diagnosed with alcoholic hepatic cirrhosis Child–Pugh Class B. The patient was successfully treated by aneurysm resection, soft tissue debridement and systemic antibiotics.

Conclusion: PAA infection is a rare complication after exclusion and bypass procedures but should be considered in any patient with evidence of local or systemic infection. When a PAA infection is diagnosed, aneurysmectomy, local debridement, and intravenous antibiotic therapy are recommended. The “gold standard” method of PAA repair remains controversial. PAA excision or endoaneurysmorrhaphy avoids complications from incompletely excluded aneurysms, but is associated with a high risk of neurological damage.

© 2016 The Author(s). Published by Elsevier Ltd on behalf of European Society for Vascular Surgery. This is an open access article under the CC BY-NC-ND license (<http://creativecommons.org/licenses/by-nc-nd/4.0/>).

Article history: Received 1 September 2016, Revised 17 September 2016, Accepted 16 October 2016,

Keywords: Popliteal artery, Aneurismatic disease, Infection, Hepatic cirrhosis, Popliteal aneurysm exclusion

INTRODUCTION

Popliteal artery aneurysms (PAAs) are rare in the general population but can cause significant morbidity and mortality, being the commonest cause of non-traumatic leg amputation. Despite their rarity, PAA are the most common peripheral arterial aneurysms and many of those affected have concomitant abdominal aortic aneurysms (33%) and contralateral PAA disease (50%).¹

There are several possible surgical approaches including exclusion of the aneurysm and bypass grafting or endoaneurysmorrhaphy and interposition of a prosthetic conduit, usually through a posterior approach. However, the “gold

standard” method of repair remains controversial, as both methods have unique merits and risks.^{2,3}

The most common complication after elective PAA surgical repair is late bypass failure, independent of the approach. Outcomes following PAA exclusion are favorable, but persistent blood flow in the aneurysm sac has been documented in up to one third of patients in the early post-operative setting. Complications from incompletely excluded aneurysms include aneurysm enlargement, local compressive symptoms, and sac rupture. Notably infection of a previously excluded and bypassed PAA is rare.⁴

This paper describes one case of *Serratia liquefaciens* infection of a previously excluded popliteal aneurysm 7 years after initial surgical repair. This is the third reported case of PAA infection after exclusion and bypass grafting and the first reported case due to *S. liquefaciens*.^{2,5}

CASE REPORT

The patient was a 54 year old male with a previous history of smoking and heavy drinking (mean 70 grams of alcohol

^{*} Corresponding author. Rua de Campolide, 90 2.^o Esquerdo, 4200-149 Porto, Portugal.

E-mail address: andreiasmpcoelho@gmail.com (A. Coelho).

2405-6553/© 2016 The Author(s). Published by Elsevier Ltd on behalf of European Society for Vascular Surgery. This is an open access article under the CC BY-NC-ND license (<http://creativecommons.org/licenses/by-nc-nd/4.0/>).

<http://dx.doi.org/10.1016/j.ejvsr.2016.10.002>

per day). He was chronically medicated with acetylsalicylic acid and simvastatin.

In 2009 he was referred to the emergency department with acute limb ischaemia. A thrombosed popliteal artery aneurysm was discovered during the diagnostic workup. The runoff was poor, and no distal tibial vessel was identified. The patient was submitted to emergency surgery with aneurysm exclusion and bypass with a venous conduit (great saphenous vein). Owing to an adverse clinical outcome, below the knee amputation was necessary 3 months later. A contralateral PAA was diagnosed, but abdominal aortic aneurysm was excluded.

The patient was lost to follow-up until 7 years later, when he was admitted to the emergency department with a 2 day history of pain and inflammatory signs over the supra-articular incision for the PAA repair. There was no history of local trauma. When specifically asked, he denied pulmonary, urinary or any other symptoms. He had been diagnosed with alcoholic hepatic cirrhosis Child–Pugh B during the lost follow-up period.

Physical examination included hemodynamic stability, apyrexia, and exuberant inflammatory signs over the supra-articular incision with hematoma mixed with purulent drainage. No signs of cirrhosis decompensation were evident on examination.

Investigations revealed no leukocytosis ($8.19 \times 10^3/\mu\text{L}$), and marginal elevation in ultra-sensitive C-reactive protein (5.30 mg/dL). Liver workup revealed no cirrhosis decompensation.

Given the patient's clinical findings, computed tomography angiography (CTA) was performed, which revealed a liquid collection 79×62 mm with a thin wall in the postero-medial left thigh. There were no clear limits between the vascular structures and the inflammatory collection, so communication with the aneurysmal sac could not be excluded. Persistent aneurysm perfusion and rupture signs were not identified, but could not be excluded (Fig. 1).

The patient was submitted to urgent surgery, with a medial approach over the previous incision. Intra-operative findings included abundant liquefied hematoma mixed with

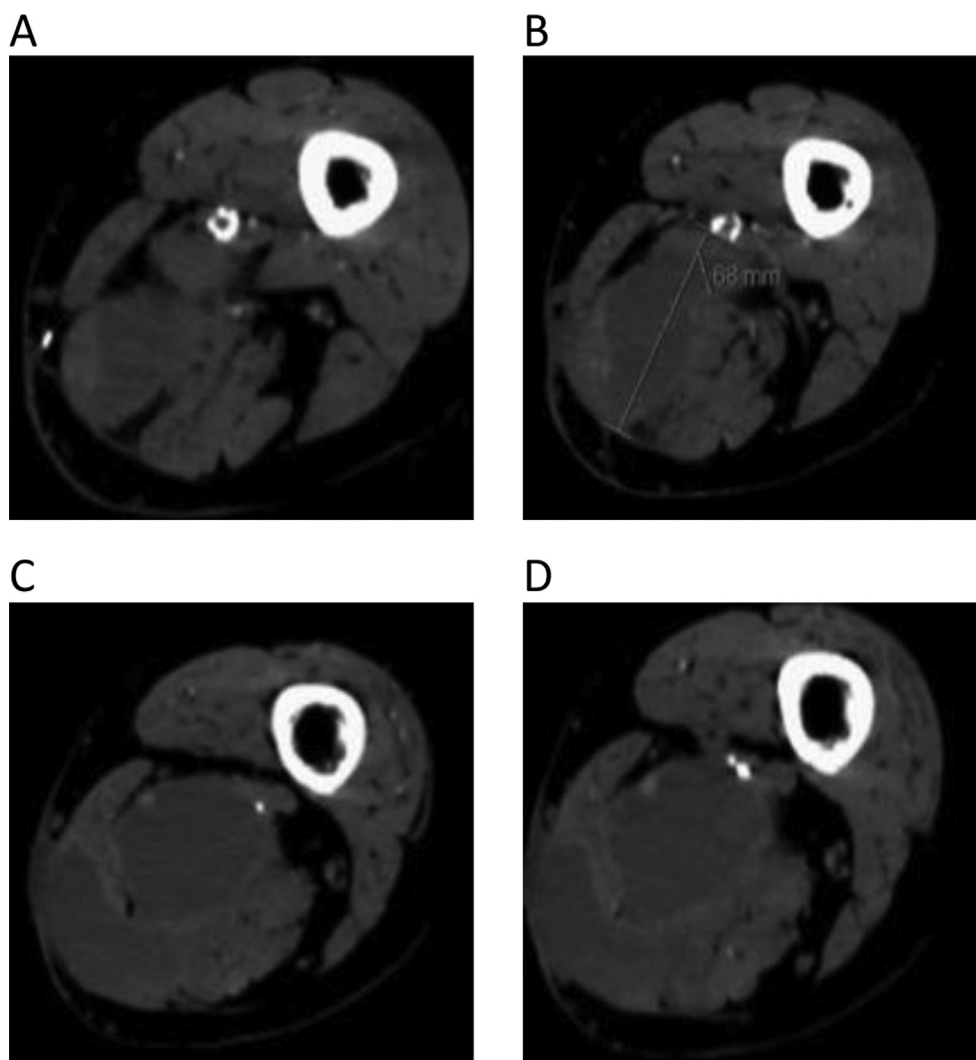


Figure 1. Computed tomography angiography at admission. Autogenous bypass occlusion (A), aneurysmal sac rupture (B) with hematoma formation (C), and skin fistulisation (D).

purulent drainage, identification of the open aneurysmal sac, and no areas of active bleeding into the sac. The surgical procedure included hematoma and purulent content drainage, debridement of the peri-aneurysmal soft tissue, and aneurysm sac excision. The popliteal artery inflow and outflow were oversewn. The operative field was irrigated and the wound was closed with a negative pressure wound system.

The patient was treated empirically with vancomycin and piperacillin/tazobactam. Blood cultures were negative, but microbiological analysis of the purulent content revealed *S. liquefaciens* infection. The antibiogram revealed resistance to amoxicillin, amoxicillin with clavulanic acid, and cefuroxime, but sensitivity to multiple other antibiotics; hence, he started specific antibiotic treatment with ceftazidime.

Clinical recovery during hospital admission was favorable. He returned to the operating room 3 and 8 days after the first procedure for local debridement and exchange of the negative pressure wound system. Sixteen days after the index procedure, the surgical wound was closed, and the patient was discharged 2 days later with no further complications.

DISCUSSION

The “gold standard” method of PAA repair remains controversial, but the most commonly performed surgical procedure for PAA is exclusion and bypass, which involves proximal and distal ligation of the aneurysm sac in combination with a reversed saphenous vein bypass graft. A number of recent reports have highlighted the risk of persistent blood flow in the “excluded” aneurysm sac following exclusion and bypass.⁶ More recently, endovascular repair of a PAA has proven to be a viable treatment option. This option exists even for rupture of an excluded PAA.⁷

The largest review of follow-up of PAA repair published to date included 717 legs and revealed a 33% risk of aneurysm sac expansion in the medial approach group and 8.3% in the posterior approach group. About 88% of patients with aneurysm sac expansion were symptomatic, and 5% underwent surgical re-intervention.⁴

Results from other series in the literature were similar, raising long-term follow-up imaging controversy and routine — surveillance of the excluded aneurysm sac recommendations were issued.^{6,8}

Primary mycotic popliteal aneurysms are rare, with an estimated incidence of less than 2% of all popliteal aneurysms.⁹ The pathogens most commonly implicated in the infection of popliteal aneurysms are Gram positive cocci such as *Staphylococcus* and *Streptococcus*. Gram-negative bacilli such as *Proteus*, *Escherichia coli*, *Salmonella*, and *Campylobacter* species have occasionally been reported.^{10,11} The source and mechanism of spread is presumably haematogenous.

There are only two case reports in the literature of PAA infection after surgical exclusion. In both procedures the

great saphenous vein was used as a conduit, and infectious complications occurred more than 10 years after PAA repair. In both cases clinical presentation included fever, pain, and swelling in the popliteal fossa. The bacteria were *Staphylococcus aureus* and *Campylobacter fetus*.^{2,9}

The *Serratia* genus, as a whole, is responsible for about 2% of nosocomial infections, including urinary tract infections, bloodstream infections, sepsis, pneumonia, meningoen- cephalitis, and other debilitating infections. However, it is not reported as an agent responsible for mycotic aneurysms. In this specific case, the patient presented with hepatic cirrhosis Child—Pugh class B. Cirrhosis is considered an immunocompromised state; therefore, unusual bacteria are frequently observed and more virulent in patients with cirrhosis relative to those without liver disease.¹²

As a conclusion, PAA infection rarely occurs after an exclusion and bypass procedure but should be considered in any patient with evidence of local or systemic infection. When a PAA infection is diagnosed, aneurysm excision, debridement, and intravenous antibiotic therapy are recommended. Reconstruction with autogenous conduit should be considered if the bypass remained patent.

CONFLICT OF INTEREST

None.

FUNDING

None.

REFERENCES

- Phair A. Meta-analysis of posterior versus medial approach for popliteal artery aneurysm repair. *J Vasc Surg* 2016;**64**. 1141–50.e1.
- Funk LM, Robinson WP, Menard MT. Surgical treatment of an infected popliteal artery aneurysm 12 years after aneurysm exclusion and bypass. *Ann Vasc Surg* 2010;**24**. 553.e9–e11.
- Bisdas T, Paraskevas KI, Pichlmaier M, Wilhelmi M, Haverich A, Teebken OE. Dorsal (posterior) versus medial approach for the surgical repair of popliteal artery aneurysms. *Angiology* 2010;**61**:248–52.
- Ravn H, Wanhainen A, Björck M. Swedish Vascular Registry (Swedvasc). Surgical technique and long-term results after popliteal artery aneurysm repair: results from 717 legs. *J Vasc Surg* 2007;**46**:236–43.
- Lozano P, Rimbau EM, Martínez S, Ribas MA, Gómez FT. *Campylobacter fetus* infection of a previously excluded popliteal aneurysm. *Eur J Vasc Endovasc Surg* 1999;**18**:86–8.
- Mehta M, Champagne B, Darling 3rd RC, Roddy SP, Kreienberg PB, Ozsvath KJ. Outcome of popliteal artery aneurysms after exclusion and bypass: significance of residual patent branches mimicking type II endoleaks. *J Vasc Surg* 2004;**40**: 886–90.
- Bush RL, Bianco CC, Lin PH, Lumsden AB. Endovascular treatment of an endoleak causing rupture of a previously bypassed popliteal aneurysm. A case report. *Vasc Endovasc Surg* 2004;**38**:257–61.
- Deglise S, Qanadli SD, Rizzo E, Ducrey N, Doenz F, Haller C. Long-term follow-up of surgically excluded popliteal artery

- aneurysms with multi-slice CT angiography and Doppler ultrasound. *Eur Radiol* 2006;**16**:1323–30.
- 9 Bonds Jr JW, Fabian TC. Surgical treatment of mycotic popliteal artery aneurysm: a case report and review of the literature. *Surgery* 1985;**98**:979–82.
 - 10 Wilson P, Fulford P, Abraham J, Smyth JV, Dodd PD, Walker MG. Ruptured infected popliteal artery aneurysm. *Ann Vasc Surg* 1995;**9**:497–9.
 - 11 Montero A, Corbella X, López JA, Santín M, Ballón IH. *Campylobacter fetus*-associated aneurysms: report of a case involving the popliteal artery and review of the literature. *Clin Infect Dis* 1997;**24**:1019–21.
 - 12 Mahlen SD. *Serratia* infections: from military experiments to current practice. *Clin Microbiol* 2011:755–91.