

## CASE REPORT

# A Case of Iliopsoas Hematoma Caused by Prophylactic Anticoagulation against COVID-19

Shoichi Masaki, MD <sup>a</sup> Tadashi Takahashi, RPT <sup>b</sup> Toshinori Sahara, MD <sup>c</sup> Ryo Endo, MD <sup>b</sup>  
and Masayoshi Obana, MD <sup>b</sup>

**Background:** COVID-19 is associated with an increased risk of venous thromboembolism (VTE), and prophylactic anticoagulation is recommended for the prevention of VTE in COVID-19 patients. We encountered a patient with COVID-19 who developed iliopsoas hematoma (IPH) that was likely caused by prophylactic anticoagulation against VTE; we report the case here because IPH is an important risk in rehabilitation treatment. **Case:** The patient was a 73-year-old man with severe COVID-19 who received anticoagulation therapy from the time of admission (day 0). On day 22, decreased hemoglobin levels, muscle weakness in the left lower extremity, and pain on passive movement of the left hip joint were noted. On day 29, computed tomography (CT) was performed and revealed a mass lesion suspicious of a hematoma in the left iliopsoas muscle. On day 36, magnetic resonance imaging (MRI) was carried out to re-evaluate the mass lesion and revealed a multicystic lesion that could also have been an abscess. CT-guided puncture drainage was performed, but no pus-like material was collected; this finding led to a diagnosis of IPH. Subsequent exercise loads were gradually increased while the status of the hematoma was assessed. **Discussion:** The prevalence of IPH in COVID-19 patients has been reported to be 7.6 cases per 1000 admissions, and the use of anticoagulation is likely to increase the risk of IPH. Because rehabilitative interventions can lead to the discovery or aggravation of IPH, the possibility of IPH should be kept in mind when providing rehabilitation treatment for COVID-19 patients.

**Key Words:** abnormal coagulation; exercise load; heparin; infectious diseases; rehabilitation risk management

## INTRODUCTION

The novel coronavirus disease COVID-19 was first reported in China at the end of 2019 and continues to spread worldwide. Our hospital has been accepting COVID-19 patients since January 2020. COVID-19 is associated with an increased risk of venous thromboembolism (VTE), with one study reporting a high incidence of deep venous thrombosis (58%) and pulmonary embolism as the direct cause of death.<sup>1)</sup> Prophylactic anticoagulation is recommended for the prevention of VTE in COVID-19 patients,<sup>2)</sup> although its side effects and complications have not been

fully investigated. We encountered a COVID-19 patient who developed iliopsoas hematoma (IPH) that was likely caused by prophylactic anticoagulation against VTE; we report the case here because IPH in COVID-19 is an important risk in rehabilitation.

## CASE

The patient was a 73-year-old man who developed fever 16 days before hospitalization (day -16), but he did not seek medical attention because the fever resolved spontaneously. On day -7, he again had a fever of 38°C and was placed un-

Received: June 10, 2021, Accepted: December 28, 2021, Published online: February 4, 2022

<sup>a</sup> Department of Rehabilitation Medicine, National Hospital Organization Tokyo National Hospital, Tokyo, Japan

<sup>b</sup> Department of Rehabilitation Medicine, Tokyo Metropolitan Health and Hospitals Corporation Ebara Hospital, Tokyo, Japan

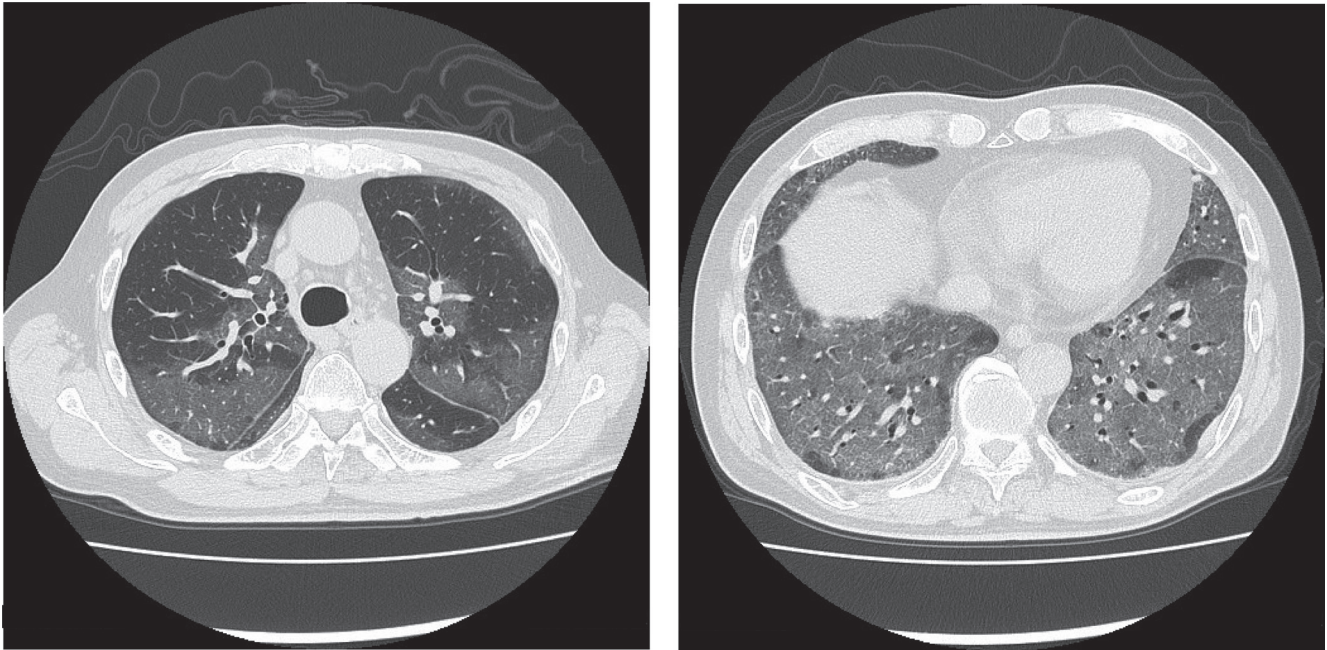
<sup>c</sup> Department of Infectious Diseases, Tokyo Metropolitan Health and Hospitals Corporation Ebara Hospital, Tokyo, Japan

Correspondence: Shoichi Masaki, MD, Department of Rehabilitation Medicine, National Hospital Organization Tokyo National Hospital, 3-1-1 Takeoka, Kiyose-shi, Tokyo 204-8585, Japan, E-mail: [mksyo+prm@gmail.com](mailto:mksyo+prm@gmail.com)

Copyright © 2022 The Japanese Association of Rehabilitation Medicine



This is an open-access article distributed under the terms of the Creative Commons Attribution Non-Commercial No Derivatives (CC BY-NC-ND) 4.0 License. <http://creativecommons.org/licenses/by-nc-nd/4.0/>



**Fig. 1.** Plain chest CT findings at admission showing panlobular ground-glass opacities in both lungs.

der observation by a local physician. He did not recover from the fever and consulted another local physician on day 0. Chest computed tomography (CT; **Fig. 1**) revealed extensive ground-glass opacities in the bilateral lungs. With a positive COVID-19 antigen test result, the patient was admitted to our hospital. He had a history of diabetes, diabetic nephropathy, and hypertension and was already severely ill; on admission, he had a body temperature of 37.9°C, a blood pressure of 138/70 mmHg, a pulse rate of 103 beats/min, a respiratory rate of 32 breaths/min, and an SpO<sub>2</sub> of 87% with a reservoir mask at an oxygen flow rate of 15 L/min. The laboratory test results are shown in **Table 1**.

The patient was admitted to the intensive care unit (ICU) immediately after hospital admission. Because of a low arterial oxygen partial pressure to fraction of inspired oxygen (P/F) ratio of 80.6, a high-flow nasal cannula (HFNC) was started at a flow rate of 40 L/min and a fraction of inspired oxygen of 90%. In addition, drug therapy was initiated with 1000 mg/day of methylprednisolone succinate sodium, remdesivir was started at 200 mg and reduced to 100 mg the next day, and 10,000 units/day of heparin sodium (by injection). The time course of drug and oxygen therapies is shown in **Fig. 2**, and that of the laboratory test results is shown in **Table 2**. On day 3, the patient's respiratory condition deteriorated to a P/F ratio of 60.9, and he was intubated and placed on a ventilator. On the same day, rehabilitation treatment was started to improve the patient's respiratory condition. The

**Table 1.** Laboratory test results at admission

WBC (10 <sup>3</sup> /μL)	8.2	Na (mEq/L)	136
NEUT (%)	85.6	K (mEq/L)	4.6
LYMPH (%)	5.5	BUN (mg/dL)	49
MONO (%)	8.8	Cre (mg/dL)	2.13
EOSINO (%)	0	eGFR	24.8
BASO (%)	0.1	TP (g/dL)	6.5
Hb (g/dL)	14.8	Alb (g/dL)	2.9
PLT (10 <sup>3</sup> /μL)	200	CRP (mg/dL)	21.68
PT-INR	1.02	CK (U/L)	314
APTT (s)	32.4	BNP (pg/mL)	63.1
D-dimer (μg/mL)	2.39	BS (mg/dL)	206
AST (U/L)	78	HbA1c (%)	9.6
ALT (U/L)	38		

course of rehabilitative treatment is shown in **Fig. 2**, and the time course of the Functional Independence Measure (FIM) scores is shown in **Table 3**. First, the patient was placed in the forward-leaning prone position for 2–3 h/session, once or twice a day. On day 15, because the P/F ratio had improved to 257.5, the patient was extubated and placed on HFNC, and bed-up and respiratory muscle stretching were performed as rehabilitation treatment. On day 17, exercise involving sitting on the edge of bed was started initially for 20 min/session, once a day. The rehabilitation treatment time was gradually increased to 40 min/day. Persistent fever and a

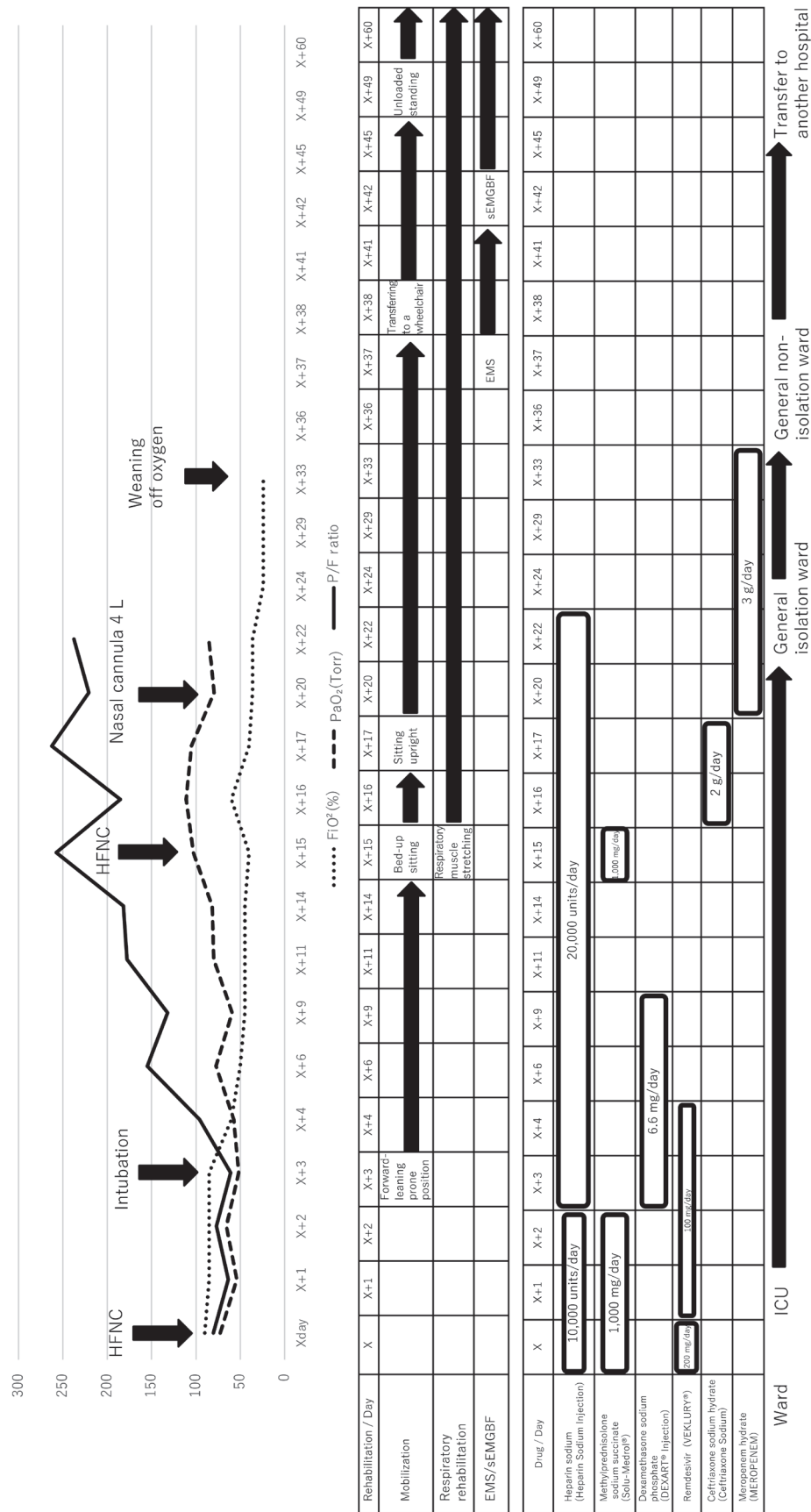


Fig. 2. Time course of respiratory support, rehabilitation treatment, and drug therapy. HFNC: high-flow nasal cannula.

**Table 2.** Time course of laboratory test results

	Day											
	X+4	X+6	X+11	X+15	X+16	X+20	X+22	X+24	X+29	X+36	X+41	X+45
WBC (10 <sup>3</sup> /μL)	12.2	11.4	13.7	15.3	18.8	17.3	16.2	10.5	14.3	8.3	10.4	10
Hb (g/dL)	13.5	13.7	13	13.4	12.3	11.2	7.7	8.5	10.6	11.3	12.2	12.2
PLT (10 <sup>3</sup> /μL)	264	242	161	141	174	312	401	493	497	295	229	209
PT-INR			1.09			1.13				1.08		
APTT (s)	>100	34.6	31.4	51.2	46.3	38.2	41			40.1		
D-dimer (μg/mL)	6.76	19.12	9.25	5.18	2.9	1.85	1.81			5.83	7.16	
Alb (g/dL)	2	1.7	1.4			1.9	1.6	1.9	2.3	2.6		
CRP (mg/dL)	8.68	5.55	9.08	10.43	10.2	10.33	16.03	6.14	3.28	1.74	1.13	1.05
HbA1c (%)												6.4

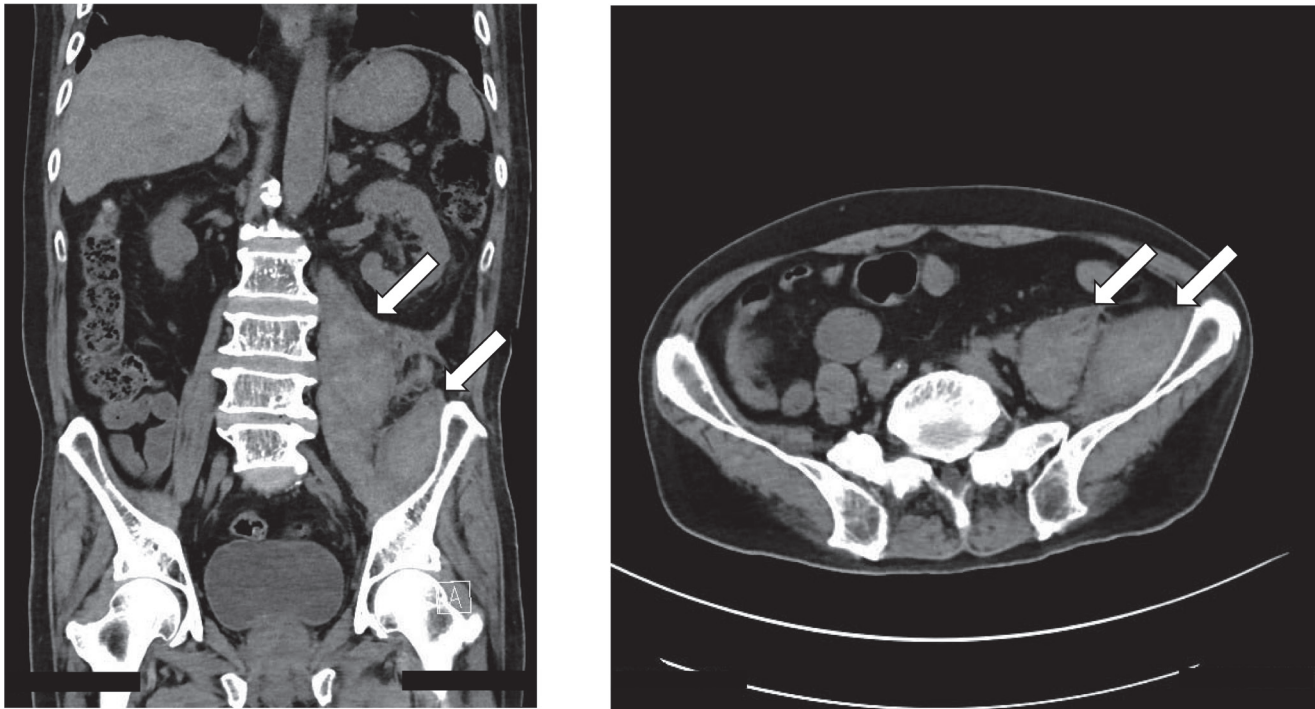
**Table 3.** Time course of FIM scores

		At admission to ICU (Day 3)	At discharge from ICU (Day 22)	At discharge from hospital (Day 60)
Motor items	Eating	1	1	7
	Grooming	1	2	5
	Bathing	1	1	3
	Dressing – upper body	1	1	4
	Dressing – lower body	1	1	3
	Toileting	1	1	2
	Bladder management	1	1	7
	Bowel management	1	4	7
	Transfer to bed	1	1	4
	Transfer to toilet	1	1	3
	Transfer to bathroom	1	1	1
	Wheelchair	1	1	5
	Stairs	1	1	1
	Motor items total	13	17	52
Cognitive items	Understanding	1	5	7
	Expression	1	5	7
	Social interaction	1	5	7
	Problem solving	1	2	7
	Memory	1	2	7
	Cognitive items total	5	19	35
Total	18	36	87	

high inflammatory response were noted, leading to a strong suspicion of bacterial pneumonia or urinary tract infection. Hypervirulent *Klebsiella pneumoniae* (hvKp) was detected by sputum culture, and extended-spectrum β-lactamase-producing *Escherichia coli* was identified on urine culture, prompting the initiation of antibiotic therapy (Fig. 2).

On day 22, without undergoing polymerase chain reaction (PCR) testing to determine infectivity, the patient was trans-

ferred from the ICU to the general isolation ward. Laboratory tests performed on the same day showed a rapid drop in hemoglobin (Hb) to 7.7 g/dL. Also on day 22, during a rehabilitative examination, the Richmond Agitation-Sedation Scale score was 0 and manual muscle testing revealed muscle weakness in the left lower extremity, with scores (right/left) of 3/2 for the iliopsoas and 3/2 for the quadriceps; the ICU Medical Research Council Score (ICU MRC score-J) was

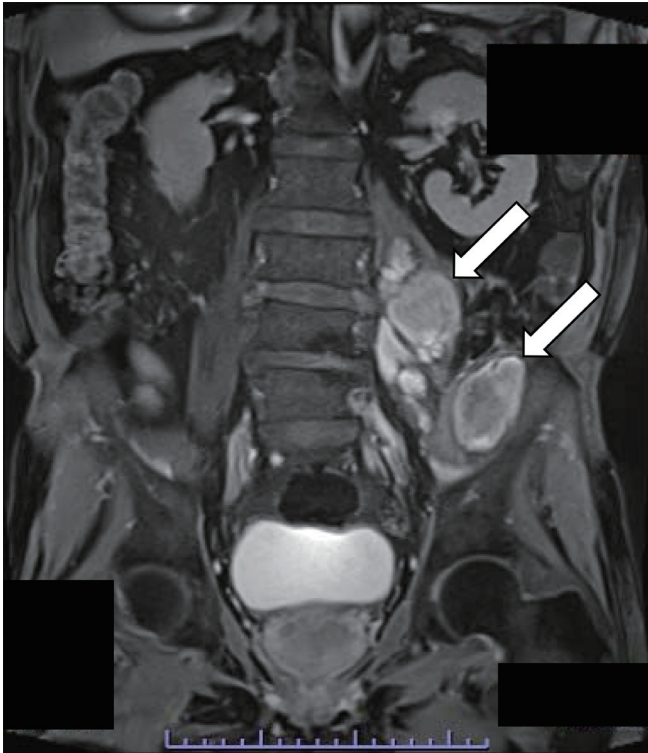


**Fig. 3.** Abdominal CT images taken on day 29 showing enlargement of the left iliopsoas and psoas major muscles containing multiple masses.

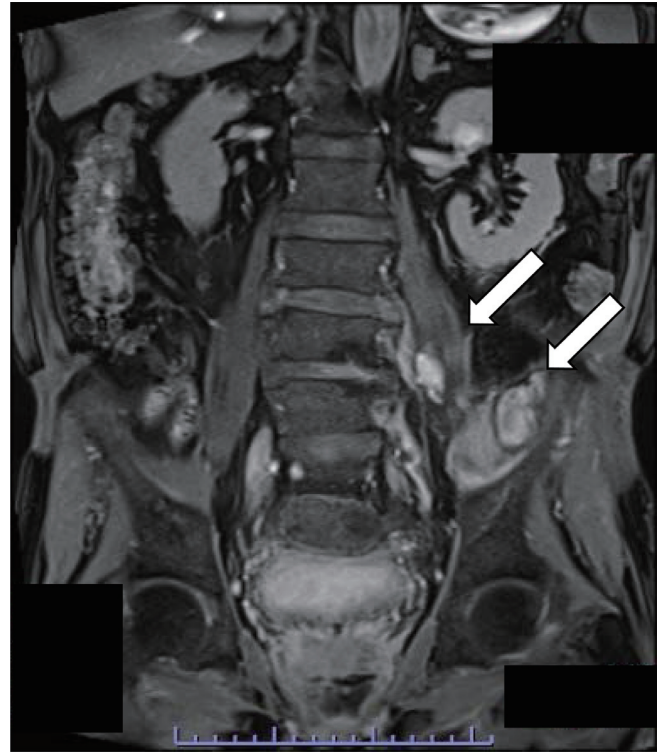
42 points. Because the patient still had impaired respiratory function, it was decided to continue exercise involving sitting on the edge of the bed. Until the cause of the muscle weakness in the left lower extremity could be determined, it was decided to introduce exercises such as upper limb strength training and calf raises while sitting on the edge of bed with upper limb support, i.e., exercises that would avoid placing an excessive load on the iliopsoas muscle. During range of motion exercises for rehabilitation treatment, the patient complained of mild pain in the left hip joint. After consulting the attending physician, even though the presence of hemorrhagic lesions or central/peripheral neuropathy was suspected, it was decided to continue follow-up without immediate imaging studies, given the need to ensure infection control and the absence of abnormal changes in vital signs. On day 24, although no further worsening of anemia was observed with a Hb level of 8.3 g/dL, there was no improvement in lower limb muscle weakness. On day 29, CT was performed to detect any central/peripheral neuropathy, and this revealed a mass lesion suspicious of hematoma in the left iliopsoas muscle (**Fig. 3**). To prevent the hematoma from becoming enlarged due to exercise load, the maximum exercise load for rehabilitation was limited to sitting on the edge of the bed with upper limb support. The patient's respiratory

status gradually improved and oxygen therapy was terminated on day 33.

On day 36, it was judged that the patient was no longer infectious for COVID-19 and he was transferred to a general non-isolation ward without PCR testing. Magnetic resonance imaging (MRI) to re-evaluate the mass lesion in the left iliopsoas muscle revealed a multicystic lesion that could also have been an abscess (**Fig. 4**). On day 38, CT-guided puncture drainage was performed, but no pus-like material was collected, which further indicated the likelihood of a hematoma. To improve the muscle strength of the left lower extremity, electrical stimulation (ES) was introduced as a rehabilitation treatment that could be performed while sitting on the edge of bed. ES was applied to the quadriceps muscle using an NM-F1 electrostimulator (ITO, Saitama, Japan) at a frequency of 50 Hz, a pulse width of 200  $\mu$ s, a duration of 30 min, and an on:off time of 8:12 h. However, the patient complained of pain on ES and, despite modification of the stimulation intensity and pulse width, he eventually refused to undergo further ES sessions. Therefore, electromyographic biofeedback (EMGBF) using surface electromyography was introduced from day 42. EMGBF was delivered using the TS-MYO surface electromyograph (Trunk Solution, Tokyo, Japan) through electrodes attached to the quadriceps using a



**Fig. 4.** MRI (gadolinium contrast-enhanced, T1-weighted, fat-suppressed image) taken on day 37 showing multiple cysts in the left iliopsoas and psoas major muscles.



**Fig. 5.** MRI (gadolinium contrast-enhanced, T1-weighted, fat-suppressed image) taken before transfer to another hospital (day 58) showing that the hematoma in the left iliopsoas and psoas major muscles had decreased in size.

protocol consisting of 5 s of contraction and 5 s of relaxation.

Because the patient was gradually recovering muscle strength in the left lower extremity, it was judged that the hematoma had decreased in size; as a result, standing without loading on the left lower extremity was started on day 48. On day 58, a second MRI was performed and confirmed that the IPH had decreased in size (**Fig. 5**). The manual muscle testing scores (right/left) of the left lower limb recovered to 4/3 for the iliopsoas and 4/3 for the quadriceps, and the patient was able to move between the wheelchair and bed with light assistance. On day 60, the patient was transferred to another hospital that had a recovery rehabilitation ward. Written informed consent was obtained from the patient for publication of this report.

## DISCUSSION

The iliopsoas muscle is the prime mover for hip flexion and plays an important role in walking and maintaining standing posture. The causes of IPH can be roughly divided into traumatic and idiopathic. Idiopathic IPH is often associated with coagulation disorders such as hemophilia and liver cirrhosis,

antiplatelet therapy, and anticoagulation therapy.<sup>3-5</sup> IPH can be life-threatening due to hemorrhagic shock, and lesion growth often leads to femoral nerve palsy that requires long-term rehabilitation. Therefore, IPH is an important lesion that should not be overlooked. In the present case, however, a diagnosis was obtained 7 days after the manifestation of muscle weakness. Diagnosis was delayed because there are few reports of IPH in COVID-19 patients in Japan, and we did not have it in mind as a complication of COVID-19. Also, the need to ensure infection control prevented us from performing CT immediately, because such imaging was not considered to be urgent.

In retrospect, the decreased Hb level observed on day 22 suggested a hemorrhagic event, but because the patient had normal vital signs and a negative fecal occult blood test, he was placed under observation, with no worsening of Hb levels evident on retesting on day 24. Therefore, it was judged that there was no urgent need for a closer examination of anemia. The muscle weakness in the left lower extremity was considered to be attributable to prolonged bed rest. However, because of the absence of recovery of muscle strength in the

left lower extremity, CT was performed on day 29 for close examination, and this revealed a lesion suspicious for IPH.

IPH is often associated with symptoms such as pain on hip joint movement and muscle weakness due to femoral nerve palsy.<sup>6)</sup> One study reported that IPH occurred in 3.8 patients per 1000 admissions to the ICU, that 95% of IPH patients were on anticoagulation therapy for thromboprophylaxis or therapeutic purposes, and that IPH patients had a mortality rate of 50%.<sup>7)</sup> Vergori et al. reported seven cases of IPH in COVID-19 patients, with a prevalence of 7.6 cases per 1000 hospital admissions, which was twice the previously reported prevalence of IPH in the ICU. They also reported that five of the seven patients were on low-molecular-weight heparin and that anemia, pain on hip motion, and paresthesia in the lower extremities were the most common symptoms of IPH.<sup>8)</sup> Therefore, during rehabilitation treatment of COVID-19 patients who are on anticoagulation therapy, special attention should be paid to any symptoms suggestive of IPH, such as pain on hip motion and femoral nerve palsy. In the present case, the long-term use of unfractionated heparin, decreased Hb levels, and muscle weakness in the left lower extremity detected on day 22 strongly suggested IPH and warranted closer examination, but the need to ensure infection control prevented us from performing CT. An MRI performed on day 36 also revealed a multicystic lesion with a ring-like contrast enhancement pattern along its margin, which, in combination with the detection of hvKp, suggested an iliopsoas abscess. However, the cyst puncture results ruled out an active abscess. Although a multicystic lesion is an atypical appearance for hematoma, cyst formation resulting from multiple hemorrhagic events has been reported in hemophilia.<sup>9)</sup> It is also likely that in the present case, multiple hemorrhagic events occurred in the iliopsoas muscle due to anticoagulation therapy, resulting in the formation of a multicystic lesion.

IPH can be treated either surgically or conservatively, although there are no established criteria for treatment selection.<sup>10,11)</sup> One study found that femoral nerve palsy caused by compression secondary to a post-traumatic hematoma of the iliopsoas muscle should be treated conservatively if diagnosed early and if the palsy is partial. However, if the diagnosis is delayed, especially in the case of complete paralysis, surgery is mandatory regardless of the length of the delay.<sup>12)</sup> In light of this, we believe that any femoral nerve palsy suggestive of IPH should prompt an urgent CT scan.

For rehabilitation, it is recommended that IPH patients maintain absolute rest in the acute period of the first 5–7 days after hematoma formation, with gradual re-introduction of

movement thereafter.<sup>6)</sup> In our patient, assuming that day 22 was the day of IPH onset (when decreased Hb and muscle weakness in the left lower extremity were first noted), more than 7 days had already passed since the onset of IPH when CT was performed on day 29. Because anticoagulation therapy had already been completed, the Hb level was recovering, and the quadriceps muscle strength was improving, it was considered that active bleeding was unlikely to be present. This consideration justified the continuation of rehabilitation with the same exercise load, i.e., the maximum load was limited to sitting on the edge of the bed. Standing and walking puts high stress on the iliopsoas muscle and may enlarge the hematoma and thereby worsen neurological symptoms. We therefore decided to carefully determine the time to start rehabilitation involving transfer to a wheelchair and practicing standing up. One study reported the detailed exercise load of rehabilitation for patients with IPH, in which the introduction of muscle strength training, ES, and gait practice was guided by the assessment of IPH using ultrasound echography.<sup>13)</sup> In the present case, an MRI scan performed on day 36 revealed a suspected iliopsoas abscess, which suggested the need for additional testing. CT-guided puncture was then performed on day 38, and based on the results and the clinical course, the possibility of hematoma growth or an abscess was ruled out. This led us to introduce ES and EMGBF and to have the patient start practicing standing up without loading of the left lower extremity. ES was not tolerated by the patient and was ultimately discontinued, with only EMGBF continued thereafter. An MRI performed on day 58 showed that the hematoma was decreasing in size, which, along with the improvement in muscle strength, indicated the appropriateness of the exercise load that was applied until the second MRI.

In the present case, muscle weakness primarily affecting the proximal muscles was also observed in the right lower extremity, which showed no evidence of IPH. IPH can cause peripheral and localized muscle weakness of the ipsilateral lower extremity but is unlikely to directly affect the muscle strength of the contralateral lower extremity. ICU acquired weakness (ICU-AW) is characterized by symmetrical limb muscle weakness that can occur after treatment of a severe illness requiring ventilator support in the ICU.<sup>14)</sup> The ICU MRC score-J, which is used as a diagnostic tool for ICU-AW, was 42 in the present case, which met the diagnostic criterion for ICU-AW (score <48). Disuse syndrome was another possible cause of the right lower extremity muscle weakness in the current case. Disuse syndrome is a general term for secondary disability caused by physical inactivity, and it has no widely used diagnostic criteria. Although the

patient started rehabilitation treatment immediately after admission to the ICU, he might have had disuse syndrome when he was discharged from the ICU due to long-term inactivity. Consequently, the muscle weakness in the right lower extremity observed in the present severely ill patient who required long-term ventilator support in the ICU could be attributed to either ICU-AW or disuse syndrome, and it is difficult to differentiate between them. The present patient was likely to have had a combination of ICU-AW and disuse syndrome with localized symptoms caused by IPH in the left lower extremity.

To summarize, it took 7 days from the time when the sudden drop in Hb level and muscle weakness in the left lower extremity were noted to detection of the mass lesion in the iliopsoas muscle on imaging. This delay resulted from the need to ensure infection control. The infectivity of COVID-19 needs to be evaluated based on each patient's disease severity and immune status as well as being informed by the many reports on the duration of viral shedding. In severe cases of COVID-19, it is known that PCR results can remain positive even after infectivity has ended.<sup>15)</sup> In the present case, PCR was not used as a criterion for lifting isolation, and the patient was judged to be non-infectious and transferred to a general non-isolation ward 72 h after weaning from supplemental oxygen. At our hospital, we do not perform non-urgent imaging studies for patients who are still considered infectious. Although there are no fixed criteria for determining urgency, we believe that imaging evaluation should be proactively performed in COVID-19 patients with lower limb muscle weakness or an unexplained decrease in Hb levels, as occurred in our patient, bearing in mind the possible complications and the management of risks associated with rehabilitation treatment in such patients. It is not uncommon for severely ill COVID-19 patients to receive rehabilitation after being admitted to the ICU.<sup>16)</sup> One study has reported the occurrence of IPH after physical therapy.<sup>17)</sup> Given that the symptoms of IPH, including pain on hip motion and muscle weakness, can be easily detected during voiding care and during exercise involving sitting on the edge of the bed, range of motion exercises, and muscle strength training, and that symptoms can be aggravated by rehabilitation, special attention should be paid to any symptoms of IPH when providing rehabilitation for COVID-19 patients receiving anticoagulation therapy. Furthermore, periodic laboratory tests should be performed for anemia and associated vital abnormalities. If femoral nerve palsy due to IPH is suspected, imaging studies should be performed as early as possible for diagnosis and treatment of IPH, with

consideration of infection control.

## ACKNOWLEDGMENTS

The authors thank the staff of Ebara Hospital.

None of the authors involved in the creation of this case report has any competing interests. This project was not funded by any organization, and there is no financial incentive for any of the authors.

## CONFLICTS OF INTEREST

The authors declare that there are no conflict of interests.

## REFERENCES

1. Wichmann D: Autopsy findings and venous thromboembolism in patients with COVID-19. *Ann Intern Med* 2020;173:1030. DOI:10.7326/L20-1206, PMID:33316197
2. Massachusetts General Hospital: COVID-19 Anticoagulation Algorithm. . Accessed 4 April 2021.
3. Ayako SA, Masahiro OH, Tetsuya KA, Hirokazu NA, Youichi YA, Shigeki GO, Tadashi IW, Kaoru AS, Kouhei HA, Akitomo GO, Yasutaka KA, Tsuneo OH: Incidence of iliopsoas muscle hematoma during treatment of acute myocardial infarction with antiplatelet and anticoagulant agents [in Japanese]. *J Jpn Assoc Rural Med* 2013;61:636–642.
4. Willbanks OL, Willbanks SE: Femoral neuropathy due to retroperitoneal bleeding. A red herring in medicine complicates anticoagulant therapy and influences the Russian Communist Revolution (Crown Prince Alexis, Rasputin). *Am J Surg* 1983;145:193–198. DOI:10.1016/0002-9610(83)90060-0, PMID:6297326
5. Kim SJ, Park HS, Lee DW: Iliacus hematoma syndrome: a systematic review of recent literature and case report. *Injury* 2020;51:1744–1750 PMID:6297326
6. Fernandez-Palazzi F, Hernandez SR, De Bosch NB, De Saez AR: Hematomas within the iliopsoas muscles in hemophilic patients: the Latin American experience. *Clin Orthop Relat Res* 1996;328:19–24. DOI:10.1097/00003086-199607000-00005, PMID:8653955



7. Artzner T, Clere-Jehl R, Schenck M, Greget M, Merdji H, De Marini P, Tuzin N, Helms J, Meziani F: Spontaneous ilio-psoas hematomas complicating intensive care unit hospitalizations. *PLoS One* 2019;14:e0211680. DOI:10.1097/00003086-199607000-00005, PMID:8653955
8. Vergori A, Pianura E, Lorenzini P, D'Abramo A, Di Stefano F, Grisetti S, Vita S, Pinnetti C, Donno DR, Marini MC, Nicastri E, Ianniello S, Antinori A, ReCOVeRI Study Group: Spontaneous ilio-psoas hematomas (IPHs): a warning for COVID-19 inpatients. *Ann Med* 2021;53:295–301. DOI:10.1080/07853890.2021.1875498, PMID:33491498
9. Torres GM, Cernigliaro JG, Abbitt PL, Mergo PJ, Hellein VF, Fernandez S, Ros PR: Iliopsoas compartment: normal anatomy and pathologic processes. *Radiographics* 1995;15:1285–1297. DOI:10.1148/radiographics.15.6.8577956, PMID:8577956
10. Tosun A, İnal E, Keleş I, Tulmaç M, Tosun Ö, Aydın G, Orkun S: Conservative treatment of femoral neuropathy following retroperitoneal hemorrhage: a case report and review of literature. *Blood Coagul Fibrinolysis* 2014;25:769–772. DOI:10.1097/MBC.000000000000110, PMID:24686104
11. Parmer SS, Carpenter JP, Fairman RM, Velazquez OC, Mitchell ME: Femoral neuropathy following retroperitoneal hemorrhage: case series and review of the literature. *Ann Vasc Surg* 2006;20:536–540. DOI:10.1007/s10016-006-9059-2
12. Lefevre N, Bohu Y, Klouche S, Chemla N, Herman S: Complete paralysis of the quadriceps secondary to post-traumatic iliopsoas hematoma: a systematic review. *Eur J Orthop Surg Traumatol* 2015;25:39–43. DOI:10.1007/s00590-013-1305-z, PMID:23996110
13. Endo S, Kurita S, Harada T, Obana M: A case of iliopsoas hematoma with femoral nerve palsy who had useful ultrasound assessment to adjust exercise load [in Japanese]. *J Clin Rehabil* 2017;26:816–820.
14. Stevens RD, Marshall SA, Cornblath DR, Hoke A, Needham DM, de Jonghe B, Ali NA, Sharshar T: A framework for diagnosing and classifying intensive care unit-acquired weakness. *Crit Care Med* 2009;37:S299–S308. DOI:10.1097/CCM.0b013e3181b66ef7
15. Centers for Disease Control and Prevention: Duration of isolation and precautions for adults with COVID-19. 14 Sep 2021. <https://www.cdc.gov/coronavirus/2019-ncov/hcp/duration-isolation.html> Accessed 1 Oct 2021.
16. Ceravolo MG, Arienti C, de Sire A, Andrenelli E, Negrini F, Lazzarini SG, Patrini M, Negrini S: Rehabilitation and COVID-19: the Cochrane Rehabilitation 2020 rapid living systematic review. *Eur J Phys Rehabil Med* 2020;56:642–651. DOI:10.23736/S1973-9087.20.06501-6
17. Nakamura H, Ouchi G, Miyagi K, Higure Y, Otsuki M, Nishiyama N, Kinjo T, Nakamatsu M, Tateyama M, Kukita I, Fujita J: Case Report: Iliopsoas hematoma during the clinical course of severe COVID-19 in two male patients. *Am J Trop Med Hyg* 2021;104:1018–1021. DOI:10.4269/ajtmh.20-1507, PMID:33534775