

Spontaneous Hemothorax in a Patient with von Recklinghausen's Disease: A Case Report and Review of the Literature

Authors' Contribution:
Study Design A
Data Collection B
Statistical Analysis C
Data Interpretation D
Manuscript Preparation E
Literature Search F
Funds Collection G

ADEF 1 **Floriane D.A. Degbelo**
EF 1 **Giovanni Cito**
EF 1 **Boumédiène Guendil**
EF 2 **Michel Christodoulou**
ADEF 3 **Ziad Abbassi**

1 Department of Surgery, Sion Hospital, Sion, Switzerland
2 Division of Thoracic Surgery, Department of Surgery, Sion Hospital, Sion, Switzerland
3 Department of Surgery, University Hospitals of Geneva, Geneva, Switzerland

Corresponding Author: Floriane D.A. Degbelo, e-mail: Floriane.Degbelo@hopitalvs.ch
Conflict of interest: None declared

Patient: Male, 45
Final Diagnosis: Spontaneous hemorhorax
Symptoms: Cough • worsened dyspnea • yellow expectoration
Medication: —
Clinical Procedure: Chest tube application
Specialty: Surgery





Objective: Rare co-existence of disease or pathology
Background: Von Recklinghausen's disease, also known as Type 1 neurofibromatosis (NF1), is a genetic disorder characterized by skin tumors, neurofibromas of multiple organs and vascular abnormalities. Spontaneous thoracic hemorrhage is a rare but potentially fatal consequence of this disorder. After a review of the literature over the last 10 years and on the basis of a case study, the aim of this study was to report the challenges of management of this pathology.

Case Report: We report a rare case of a 45-years-old male with a medical history of neurofibromatosis who complained of a 3-day history of progressive dyspnea. At his admission to the Emergency Department, the patient was hemodynamically stable. A chest computed tomography (CT) scan showed a large left hemothorax with mediastinal shift to the right without active bleeding. A chest tube was introduced, and conservative treatment was followed. Another CT scan performed 2 days later revealed a middle lobar pulmonary embolism on the opposite side. A full treatment of anticoagulation was administered, and the patient was released after 8 days of hospitalization. Three weeks later, a new chest CT scan indicated the absence of vascular aneurysm or source for hemothorax.

Conclusions: Our systematic literature review found 15 articles which were described as early as 2005. To our knowledge, endovascular treatment produces the best immediate successful result (100%) and may be used in adjunction with video-assisted thorax surgery (VATS) or thoracic drainage to optimize outcomes. In the present case, conservative treatment showed a good result despite anticoagulation for pulmonary embolism. The endovascular approach seems to be the most promising, but treatment needs to be tailored to each individual patient.

MeSH Keywords: Chest Tubes • Hemothorax • Neurofibromatosis 1 • Pulmonary Embolism

Full-text PDF: <https://www.amjcaserep.com/abstract/index/idArt/915810>

 1540  —  4  20



Background

Von Recklinghausen's disease (NF1) is the most common neurofibromatosis. It is an autosomal dominant disorder, and occurs *de novo* approximately half of the time [1]. This disease results in peripheral nerve sheath tumors but also presents in other organs attempts such as musculoskeletal abnormalities (e.g., generalized osteopenia/scoliosis/long bones dysplasia); pigmentary abnormalities; other skin disorders such as Lisch nodules; cutaneous neurofibromas and vascular disorders [1,2].

Vascular abnormalities in NF1 account for 3.6% of cases and they can present as stenosis, aneurysm formation, arteriovenous fistula, MoyaMoya syndrome, vascular proliferation and invasion, or compression by neural tumors. They can result in spontaneous bleeding in different organs [1–6], such as spontaneous hemothorax. Symptoms can range from dyspnea or chest pain to a catastrophic scenario leading to death. Finding the source of bleeding can be challenging and the treatment may be complex.

Case Report

A 45 years-old male with a medical history of neurofibromatosis was sent by his general practitioner to our clinic for persistent dyspnea. Indeed, he consulted 3 days before admission for mild dyspnea with cough and yellow sputum without fever. He was treated with antibiotics as an outpatient without success.

On his admission to the Emergency Department, the patient was complaining of worsened dyspnea. The physical status evaluation found hemodynamic stability with left pulmonary hypoventilation and dullness on percussion. The blood analysis revealed mild anemia with hemoglobin at 116 g/L and a low hematocrit at 35%.

A chest computed tomography (CT) scan (Figure 1A, 1B) was performed showing a large left hemothorax with mediastinal shift to the right with no active bleeding and no proximal pulmonary embolism.

A chest tube was inserted (Figure 2). Approximately 2 liters of a hematic liquid was removed, and the patient was admitted to the Intermediate Care Unit for follow-up. He remained hemodynamically stable and his hemoglobin level did not fall under the previous value.

A new CT scan performed 2 days after admission, looking for the source of bleeding, showed some few thoracic fluids remaining. The examination didn't reveal any source of bleeding, but it exhibited a middle right lobar pulmonary embolism

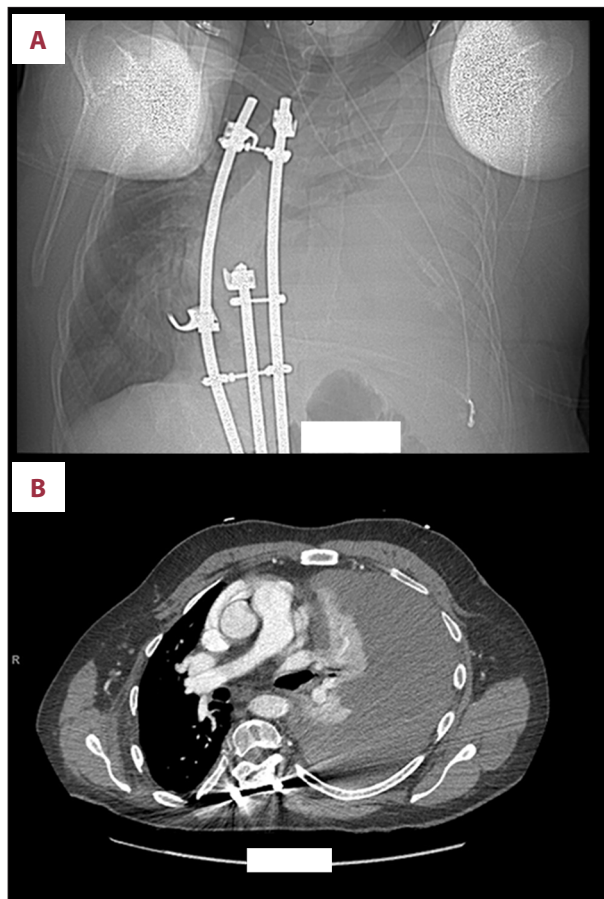


Figure 1. (A, B) Admission computed tomography scan: large left hemothorax without central pulmonary embolism.

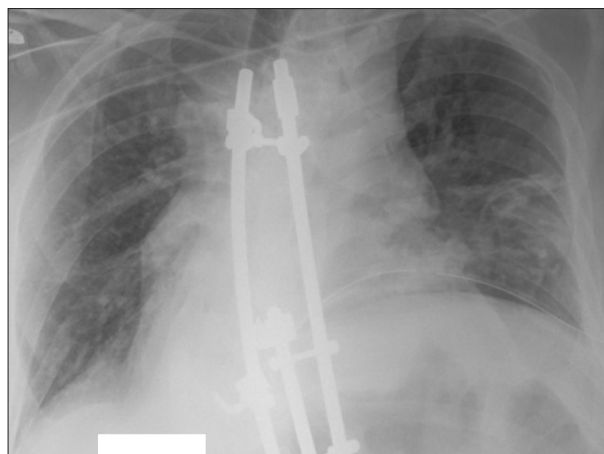


Figure 2. Chest x-ray with chest tube.

(Figure 3). Therapeutic anticoagulation was started with unfractionated heparin.

The chest tube was removed 4 days after admission. An oral anticoagulation was introduced.

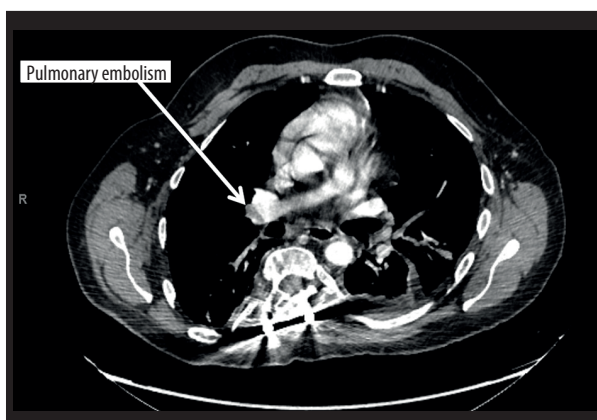


Figure 3. Computed tomography scan with middle right lobar pulmonary embolism.

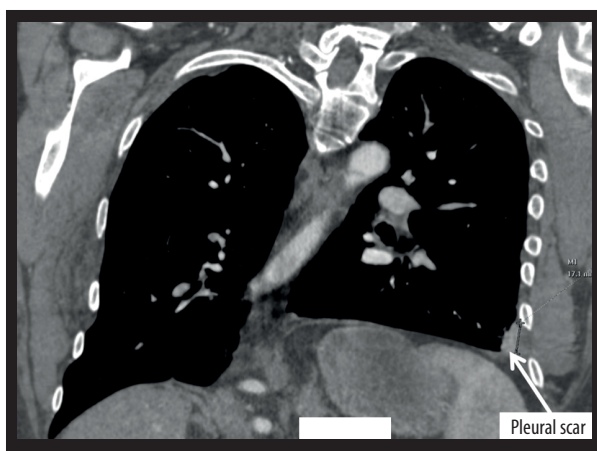


Figure 4. Pleural scar on the computed tomography scan 1 month after event.

The patient was discharged after 8 days of hospitalization.

Another CT scan (Figure 4) performed 1 month after the event, revealed a post-drainage pleural scar. No vascular aneurysm nor any source for hemothorax was found.

At 6 weeks follow-up, the patient has fully recovered.

Discussion

Vascular abnormality is one of the manifestations of NF1. Some of the arteries affected are the aorta, renal, mesenteric, carotid-vertebral, intracerebral, subclavian, axillary, and ilio-femoral arteries [6]. Some pathological findings include fibromuscular dysplasia with neointimal thickening and proliferation of Schwann cells and fibroblasts [6].

Some of these abnormalities can lead to spontaneous hemothorax. Some authors have reported that the rupture of the fragilized vessels is favored by scoliosis [5].

As mentioned earlier, spontaneous hemothorax can present through different clinical presentations.

In order to have a better understanding of this pathology, we did a literature search for articles published during the last 10 years in “PubMed” using the words “spontaneous hemothorax neurofibromatosis”. We found 21 items out of which we excluded 6 articles; 3 because of the language of the publication (one in Czech, one in Portuguese and one in Spanish), and 3 were excluded because they were outside of our study subject area. One article presented a contralateral recurrence [3]. Adding our present case, we had a total of 17 patient cases that we analyzed.

The mean age of these patients at occurrence was 44.13 years old and there were more women than men with a ratio of male: female at 1: 2.2. The left side was slightly the most involved: 9 out of 17 events.

Acute chest pain and dyspnea were the most frequent symptoms mentioned by 53% and 59% of patients, respectively. Hemodynamic instability was found in 53% of cases showing the severity of this pathology [7–14]. We also found that some patients may remain hemodynamically stable several days after the beginning of symptoms and suddenly may become hemodynamically unstable [7,15]. This supposes that the bleeding may occur in several stages and that there is a need for early care to avoid a catastrophic scenario. It is important to mention that hemodynamic instability may also occur after thoracic drainage [16].

Other rarer symptoms mentioned by these patients were arm, shoulder, and back pain as well as syncope.

Concerning the diagnosis of hemothorax, it is easily made on chest CT scan. However, the bleeding source may be difficult to locate. CT-scan, video-assisted thorax surgery (VATS), or thoracotomy may be helpful. Chest CT scan (mainly contrast enhanced CT scan) could determinate the exact localization of the source of bleeding in 59% of cases. Repeat CT-scan may be useful in this goal, up to 1 month after a primary event. For example, in the Misao et al. case report in 2011, the aneurysm of the right tenth intercostal artery was visualized only on the third CT scan performed on day 30 of hospitalization [3]. In 3 case reports (18%), the source of bleeding was found only during surgery; 2 during VATS and the remaining 1 during thoracotomy [7,16]. Nevertheless, the bleeding source was not always easily discovered even through surgery, as reported in the Fördhng et al. case study where the precise bleeding

point could not be found despite anterolateral thoracotomy, due to proximity with a large meningocele [12]. Pulivarthi et al. as did not find a precise site of bleeding, but a neurofibroma with a sentinel clot was visualized during thoracoscopy [17].

Until now, there has been no consensus for the treatment of spontaneous hemothorax in patients with NF1. Three options of treatment exist: conservative treatment with only thoracic drainage, surgical treatment through VATS or thoracotomy, and endovascular treatment. These options may be used together to optimize the outcomes.

Conservative treatment was used in 2 patients (12% of all cases), including the present case. Fdil et al. made a resuscitation and thoracic drainage. Nevertheless, they had to perform a thoracotomy due to a subsequent pleural infection [8]. In the present case, we only performed thoracic drainage since the patient was hemodynamically stable and there was neither vascular abnormality nor any other source of bleeding on imaging. Furthermore, no decrease in hemoglobin occurred during patient follow-up and the last CT scan 1 month later was inconclusive.

In the 17 cases, surgical treatment was applied as a first treatment in 9 patients (53%); 4 with VATS and 5 with thoracotomy. The purpose of surgical treatment was to stop the bleeding and to avoid infection by evacuation of blood clots.

VATS helped to successfully stop bleeding in 2 patients through electrocoagulation and the use of fibrin tissue-adhesive collagen fleece; conversion to thoracotomy was made by Jeong et al. due to the close relation of the neurofibroma to the aorta [14–18].

Concerning the open approach, 2 out of 5 patients had bleeding completely stopped through thoracotomy but not without adverse effects [14,15]. Unfortunately, the use of absorbable oxidized cellulose packing led to compression of the spinal cord with paraplegia in the case reported by Aizawa et al. [15]. However, Yusuf et al. showed a clear advantage of using thoracotomy for the treatment of meningocele. Faruque et al. were able to stop thoracic artery bleeding by stapling, but left vertebral venous plexus bleeding was controlled only by endovascular embolization and sclerosing [7]. One patient died

due to the inability to locate the site of bleeding because of contact with a large meningocele [12].

Endovascular treatment was applied in 5 patients (29%) as first choice [3,13]. Immediate successful results were achieved in all of these patients. This approach met the highest rate of success by stopping the bleeding. However, there was a recurrence of bleeding from the same aneurysm in 1 case after hardly having controlled by injection of polyvinyl alcohol particles following embolization with 63 coils [11]; the bleeding could not be controlled with thoracotomy and the patient finally died. Outcomes after endovascular treatment can be optimized with thoracic drainage or VATS to confirm the full control of bleeding and avoid infection.

There were 3 out of 16 patients who died (19%) during care in the cases reviewed. Two died during thoracotomy and 1 patient died before any treatment [9,11,12].

Two recurrence of bleeding occurred. One case immediate from the same aneurysm after endovascular treatment as mentioned earlier, and 1 case on the contralateral side, 7 months after embolization [11,3].

Clinical or radiological follow-up were performed in 5 patients between 6 months and 1 year after discharge [3,13,16,18,20]. Hongsakul et al. found a recurrence of an arteriovenous fistula on CT angiography at 1-year follow-up [13]. No treatment was established due to opposition of the patient who was asymptomatic. We would, however, recommend follow-up of such patients.

Conclusions

Spontaneous hemothorax is a very rare but potentially fatal event in patients with NF1, that should be taken seriously when taking care of such patients. Endovascular approach seems to be the best initial treatment option when vascular abnormality is found, but conservative treatment can also be successfully applied in specific situations. Treatment should be tailored to each individual patient separately.

References:

1. Cimino PJ, Gutmann DH (eds.), Neurofibromatosis type 1; Handbook of clinical neurology. Neurogenetics, Part II (Vol 148). 3rd ed. New York, Elsevier Press, 2018
2. Friedman JM: Neurofibromatosis 1; GeneReviews®, NCBI Bookshelf, Initial Posting October 2, 1998; Last Revision May 17, 2018
3. Misao T, Yoshikawa T, Aoe M et al: Recurrent rupture of intercostal artery aneurysms in neurofibromatosis type 1. Gen Thorac Cardiovasc Surg, 2012; 60: 179–82
4. Miura H, Taira O, Uchida O et al: Spontaneous haemothorax with von Recklinghausen's disease: Review of occurrence in Japan. Thorax, 1997; 52: 577–78
5. Miura T, Kawano Y, Chujo M et al: Spontaneous hemothorax in patients with von Recklinghausen's disease. Jpn J Thorac Cardiovasc Surg, 2005; 53: 649–52
6. Oderich GS, Sullivan TM, Bower TC et al: Vascular abnormalities in patients with neurofibromatosis syndrome type I: clinical spectrum, management, and results. J Vasc Surg, 2007; 46: 475–84

7. Faruque MO, Davidson F: Clinical challenges and serious vascular complications in neurofibromatosis. *Emerg Med Australas*, 2009; 21: 518–20
8. Fdil S, Bouchikhi S, Bourkadi JE: [Hémothorax spontané: Complication rare de la neurofibromatose type 1.] *Pan Afr Med J*, 2017; 28: 85 [in French]
9. D'Errico S, Martelloni M, Cafarelli FP, Guglielmi G: Neurofibromatosis 1 and massive hemothorax: A fatal combination. *Foresnic Sci Med Pathol*, 2018; 14: 377–80
10. Saad SB, Abdenadher M, Attia M et al: [Un hemithorax blanc chez une jeune portant des tâches café au lait.] *Rev Pneumol Cli*, 2018; 74: 100–3 [in French]
11. Kim HJ, Seon HJ, Choi S, Jang NK: Ruptured aneurysm of intercostal arteriovenous malformation associated with neurofibromatosis type 1: A case report. *Cardiovasc Intervent Radiol*, 2011; 34: 74–77
12. Zacarias Föhrding L, Sellmann T, Angenendt S et al: A case of lethal spontaneous massive hemothorax in a patient with neurofibromatosis 1. *J Cardiothorac Surg*, 2014; 19: 172
13. Hongsakul K, Rookkapan S, Tanutit P et al: Spontaneous massive hemothorax in patient with neurofibromatosis type 1 with successful transarterial embolization. *Korean J Radiol*, 2013; 14(1): 86–90
14. Yusuf AS, Pillai A, Menon SK, Panikar D: Massive spontaneous hemothorax, giant intrathoracic meningocele, and kyphoscoliosis in neurofibromatosis type 1. *J Surg Tech Case Rep*, 2014;6 (1): 33–36
15. Aizawa K, Iwashita C, Saito T, Misawa Y: Spontaneous rupture of an intercostal artery in a patient with neurofibromatosis type 1. *Interact Cardiovascular Thoracic Surg*, 2010; 10: 128–30
16. Miyazaki T, Tsuchiya T, Tagawa T et al: Spontaneous hemothorax associated with von Recklinghausen's disease: report of a case. *Ann Thorac Cardiovasc Surg*, 2011; 17: 301–3
17. Pulivarthi S, Simmons B, Shearen J, Gurram MK: Spontaneous hemothorax associated with neurofibromatosis type 1: A review of the literature. *J Neurosci Rural Pract*, 2014; 5(3): 269–71
18. Jeong SC, Kim JJ, Choi SY et al: Successful surgical treatment of massive spontaneous hemothorax due to intrathoracic secondary degeneration of a neurofibroma from mediastinal involvement of type 1 neurofibromatosis. *J Thorac Dis*, 2018; 10(3): E203–6
19. Mydin MIM, Sharma A, Zia Z et al: A novel approach in managing right-sided haemothorax in neurofibromatosis type 1. *Asian Cardiovasc Thorac Ann*, 2015; 23(5): 573–75
20. Rodriguez-Guzman M, Gallegos-Carrera B, Vicente-Antunes S et al: Spontaneous hemothorax in a patient with von Recklinghausen's disease. *J Clin Med Res*, 2014; 6(2): 149–52